






# Reversible Cerebral Vasoconstriction Syndrome Presenting as Transient Vessel Wall Enhancement on Contrast-Enhanced Fluid-Attenuated Inversion Recovery Images: A Case Report and Literature Review

조영증강 유체감쇠반전회복기법 영상에서 일과성 혈관 벽 조영증강으로 나타나는 가역성 대뇌 혈관 수축 증후군: 증례 보고 및 문헌 고찰

Sun Ah Heo, MD , Eun Soo Kim, MD\* , Yul Lee, MD 

Department of Radiology, Hallym University Sacred Heart Hospital, Hallym University College of Medicine, Anyang, Korea




Received August 1, 2019  
 Revised December 3, 2019  
 Accepted January 14, 2020

\*Corresponding author  
 Eun Soo Kim, MD  
 Department of Radiology,  
 Hallym University Sacred Heart  
 Hospital, Hallym University  
 College of Medicine,  
 22 Gwanpyeong-ro 170beon-gil,  
 Dongan-gu, Anyang 14068, Korea.

Tel 82-31-380-5985  
 Fax 82-31-380-3878  
 E-mail silwater007@hallym.or.kr

This is an Open Access article distributed under the terms of the Creative Commons Attribution Non-Commercial License (<https://creativecommons.org/licenses/by-nc/4.0>) which permits unrestricted non-commercial use, distribution, and reproduction in any medium, provided the original work is properly cited.

## ORCID iDs

Sun Ah Heo   
<https://orcid.org/0000-0001-5111-7135>  
 Eun Soo Kim   
<https://orcid.org/0000-0001-9173-5755>  
 Yul Lee   
<https://orcid.org/0000-0003-4410-4357>

Reversible cerebral vasoconstriction syndrome (RCVS) is a clinical and radiological syndrome with primary features that include hyperacute onset of severe headache and segmental vasoconstriction of the cerebral arteries, which resolve within 3 months. Vessel wall enhancement has been reported in some cases of RCVS; however, its pathophysiological and diagnostic implications remain unclear. We review a case of RCVS in a patient with transient vessel wall enhancement on contrast-enhanced fluid-attenuated inversion recovery images, focusing on the pathophysiological and diagnostic implications.

**Index terms** Vasoconstriction; Cerebrovascular Disease; Magnetic Resonance Imaging; Brain; Headache

## INTRODUCTION

Reversible cerebral vasoconstriction syndrome (RCVS) is a clinical and radiological syndrome whose primary features include the hyperacute onset of severe headache and segmental vasoconstriction of the cerebral arteries that resolves in 3 months (1). RCVS is not uncommon and is potentially devastating because it is associated with a high risk of complication, such as posterior reversible encephalopathy syndrome, ischemic stroke, intracerebral hemorrhage, and cortical subarachnoid hemorrhage (SAH) (2). Additionally, vessel wall enhancement has been reported in RCVS patients in literature (3). Vessel wall imaging is not routine evaluation for RCVS patients, so it is difficult to encounter RCVS cases showing vessel wall enhancement in real practice. There is no report about vessel wall enhancement in RCVS patients on conventional contrast-enhanced fluid-attenuated inversion recovery (CE-FLAIR). Furthermore, vessel wall enhancement has uncertain pathophysiological and diagnostic implications. We report a patient with RCVS, showing vessel wall enhancement on conventional CE-FLAIR and review literature on this topic, focused on diagnostic and pathophysiologic implications.

## CASE REPORT

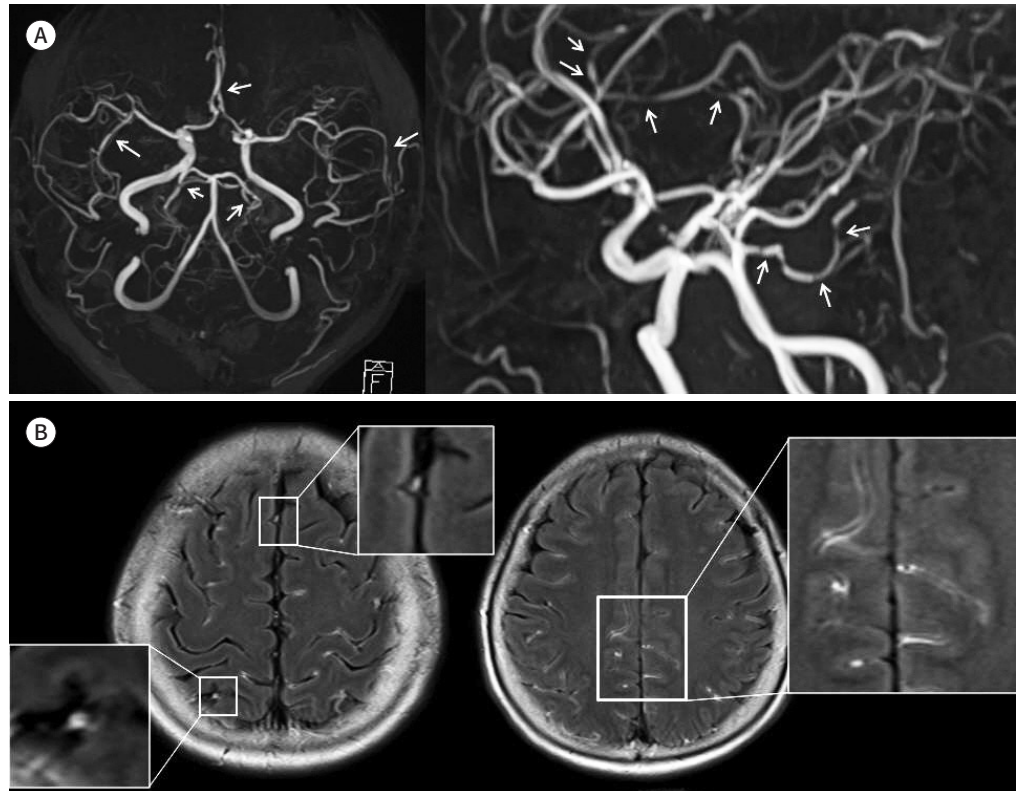
A 64-year-old woman presented to our institution with a severe headache that she had never experienced. Her headache began 6 days ago and presented as a pulsatile pain in the bilateral frontal area, several times a day and lasting for minutes to hours. She had no underlying disease. She was on corticosteroid and antihistamine from 3 days before the onset of headache due to scalp rash after dyeing her hair. Neurological examination and brain CT findings were normal.

She underwent MR imaging using a 3T MR scanner (Skyra; Siemens Healthcare, Erlangen, Germany). In this study, MRI protocol consisted of diffusion-weighted imaging, time-of-flight (TOF) MR angiography (MRA), FLAIR imaging, T1-weighted imaging, T2-weighted imaging, susceptibility-weighted imaging, CE-T1WI, and CE-FLAIR imaging. CE-FLAIR MRI was acquired 1 minutes after the first injection of contrast agents using the same protocol as in the non contrast FLAIR sequence. Gadovist (gadobutrol; Bayer Inc., Toronto, Canada), 0.1 mmol/kg body weight, was used as a contrast agent and injected by a power injector. FLAIR protocol is as follows: repetition time/echo time = 9000/106 ms, inversion time = 2800 ms, field of view = 230 mm, acquisition matrix = 320 × 249, echo spacing = 10.6 ms, number of signal averages = 2, slice thickness = 5 mm, interslice gap = 2 mm, scanning time = 198 seconds.

Brain TOF MRA showed multifocal segmental stenosis of both the anterior cerebral arteries, middle cerebral arteries, posterior cerebral arteries, and superior cerebellar arteries (Fig. 1A). CE-FLAIR image of brain showed diffuse contrast enhancement along the cortical surfaces in the bilateral cerebral hemisphere (Fig. 1B). On closer inspection of CE-FLAIR images, there were multiple contrast-enhancing tubular structures in sulcus, slight away from cortical surfaces and some shows nodular appearance like end-on vessels (Fig. 1B). As a result, we can presume the contrast-enhancing structures on CE-FLAIR images are vessel walls. Cerebrospinal fluid (CSF) analysis showed normal results (red blood cell count: 0/μL,

**Fig. 1.** Reversible cerebral vasoconstriction syndrome in a 64-year-old woman.

**A.** Initial MRA scans show multifocal segmental stenosis of both ACA, MCA, PCA, and SCA vessels (arrows).  
**B.** Initial CE-FLAIR image show diffuse vessel wall enhancement along the cortical surfaces of the bilateral cerebral hemispheres. Magnified views show more definitive visualization of vascular wall enhancement. ACA = anterior cerebral arteries, CE-FLAIR = contrast-enhanced fluid-attenuated inversion recovery, MCA = middle cerebral arteries, MRA = magnetic resonance angiography, PCA = posterior cerebral arteries, SCA = superior cerebellar arteries



white blood cell count:  $2/\mu\text{L}$ , protein level: 25.70 ml/dL, and normal glucose level). The headache was improved only after treatment with nimodipine and stopping the dermatological drugs. The follow-up brain MRA and MRI after 1 month showed reversibility of not only the angiographic abnormalities but also vessel wall enhancement on CE-FLAIR (Fig. 1C, D). Finally, the patient was diagnosed with RCVS.

## DISCUSSION

RCVS is a unifying term for a variety of clinical and radiological syndrome characterized by recurrent thunderclap headaches and reversible multifocal cerebral vasoconstriction (1). The key diagnostic criteria for RCVS include severe acute headache, multifocal segmental cerebral artery vasoconstriction on angiography with reversibility on follow-up studies within 12 weeks, normal or near-normal finding in CSF analysis, and no evidence of other conditions, such as aneurysmal SAH, vasculitis, intracranial atherosclerosis (2). Our case has satisfied all these criteria.

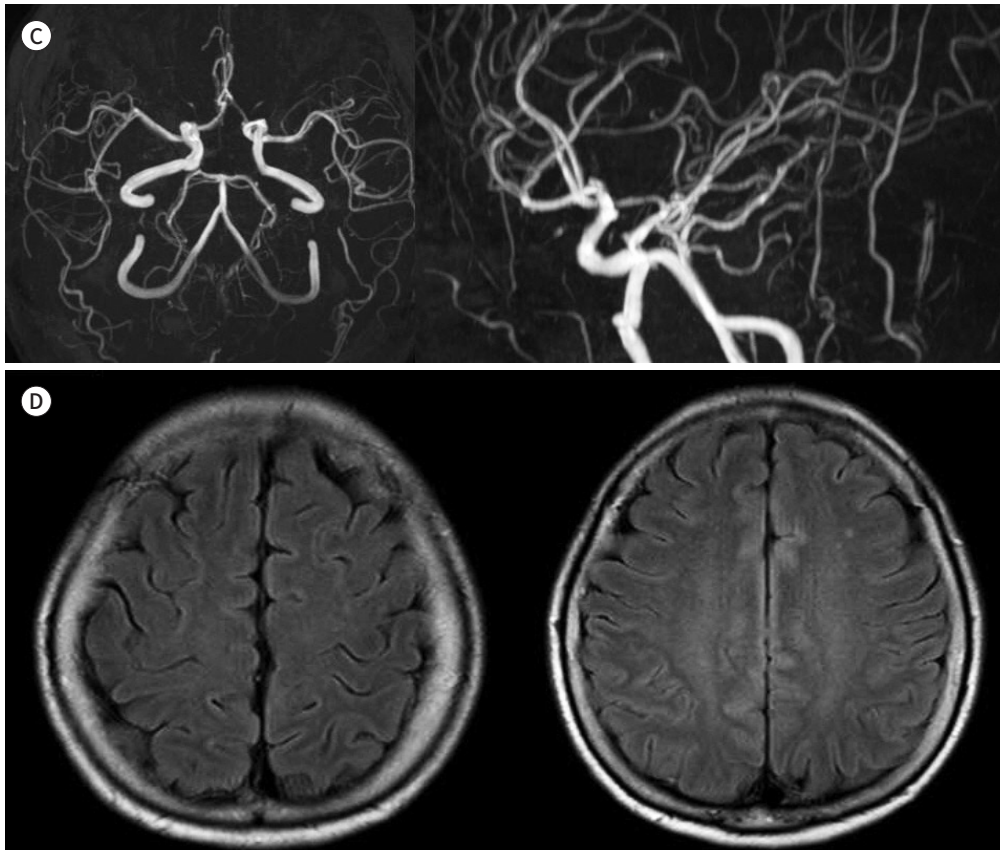
A diverse group of possible exogenous factors triggering secondary RCVS has been pro-

**Fig. 1.** MRA and CE-FLAIR images showing reversible cerebral vasoconstriction syndrome in a 64-year-old woman.

**C.** Follow-up MRA scans after one months show normalization of the vessels.

**D.** Follow-up CE-FLAIR images show resolution of the vessel wall enhancement visualized on prior scans.

CE-FLAIR = contrast-enhanced fluid-attenuated inversion recovery, MRA = magnetic resonance angiography



posed, including vasoactive drug use and postpartum state (1). The possible triggers of our case were corticosteroids and antihistamines that the patient received because of her dermatological problem. However, these drugs are not reported in the historical triggers of RCVS. No report has been published arguing that antihistamines could trigger RCVS, but corticosteroids have been reported as a deteriorating factor in RCVS (4) and a potential cause of RCVS associated with posterior reversible encephalopathy syndrome (1). Therefore, it is somewhat reasonable to deduce that it can be the trigger in our case.

The important point of the case we have interest in is vessel wall enhancement on CE-FLAIR images. Vessel wall enhancement on CE-FLAIR in our study is definitely different from leptomeningeal enhancement. Actually, vessel wall imaging is not routine nor essential for the diagnosis, but CE-FLAIR is frequently obtained in real practice. And most of the reports on vessel wall enhancement was based on T1WI (3).

Vessel wall enhancement on CE-FLAIR in our case, cause diagnostic challenging to distinguish RCVS from differential diagnosis such as vasculitis. Mandell et al. (5) suggested that patients with RCVS do not have arterial wall enhancement on 3T T1-weighted high-resolution vessel wall MRI, but recently many case series have reported vascular wall enhancement in

RCVS patients. Thus, we cannot conclude that vessel wall enhancement imply diagnosis of vasculitis, as in our case. Furthermore, the diagnosis is supported by the fact that vessel wall enhancement disappeared on follow up images. Obusez et al. (6) suggested that the enhancement of diseased vessels in RCVS is reversible on 3T T1-weighted high-resolution vessel wall MRI. However, unlike our case, a recent study by Chen et al. (3) reported that almost half of the patients with RCVS exhibited contrast enhancement of the diseased vessels, and it was persistent in approximately one-third of those patients on the follow-up imaging on 3T high-resolution vessel wall MRI, thereby making differentiation from vasculitis difficult. So, the diagnostic implications of vascular wall enhancement are undetermined, but radiologists should be familiar with that vessel wall enhancement is quite frequent imaging finding in RCVS, and it can be seen even on conventional CE-FLAIR.

There are two ways to explain pathophysiological cause of vascular wall enhancement in RCVS patients. First, according to Chen et al. (3), vascular wall enhancement was probably due to an inflammatory component of the RCVS pathology. Although inflammation in the pathogenesis of RCVS has not been supported by histopathological findings, studies have suggested that prolonged vasoconstriction could lead to secondary inflammation (7). In one case report, marked vascular wall enhancement was noted in a patient with cocaine vasculitis. Studies have demonstrated that cocaine has an apoptotic effect on cerebrovascular smooth muscle cells and a capacity to enhance leukocyte migration across the cerebral blood vessel walls (7), both of which can contribute to vessel wall inflammation. Because cocaine-induced vasculitis is considered a spectral disorder of RCVS, it is reasonable to deduce that vascular wall inflammation exists in at least some patients with secondary RCVS (3). Additionally, the pathogenesis of RCVS might share some pathological mechanisms with that of cerebral vasospasm in SAH (3). An inflammatory cascade has been reported in cerebral vasospasm in SAH (2). In it, oxidative stress and endothelial dysfunction, which contribute to the vascular wall inflammation, have also been noted in patients with RCVS (2).

According to Lee et al. (8), the other cause is the disruption of the integrity of the blood-brain barrier (BBB) in RCVS patients. Because of the frequent association of posterior reversible encephalopathy syndrome with RCVS, it is possible that endothelial dysfunction has a role in both these disorders, and endothelial dysfunction can affect disruption of the BBB (1). CE-FLAIR MRI has been used in this study because it is highly effective in visualizing the disruption of the BBB (9). Disrupted BBB allows contrast leakage from the vessels into the CSF and parenchyma, resulting in hyperintense CSF. Disrupted BBB was frequently present in patients with imaging-proven RCVS even without concomitant posterior reversible encephalopathy syndrome and, it was independently associated with increased risk of neurological complications (8). The role of BBB disruption in the pathophysiology of RCVS can be hypothesized in two ways. First, the integrity of BBB can be affected by an ischemic or hypoxic injury resulting from vasoconstriction (8). Conversely, the impairment of BBB integrity may precede and determine the vulnerability of developing vasoconstriction (8). BBB can be disrupted directly by vasoactive drugs and temperature changes, which are the typical triggers of RCVS (1).

Actually, there is a limitation on our report. Vessel wall enhancement on CE-FLAIR image has not been validated. Because FLAIR image is sensitive to slow-flow (10), there is a possibility that hyperintense vessel due to slow-flow may mimic vessel wall enhancement. However,

tubular or rim enhancement on our image strongly support that it is vessel wall enhancement rather than artifact. To make sure, further investigation including correlation with vessel wall imaging is required for cases showing vessel wall enhancement on CE-FLAIR image.

In conclusion, we report a case of RCVS showing transient vessel wall enhancement on CE-FLAIR images. The proposed pathophysiology of vascular wall enhancement in RCVS patients includes inflammation or disruption of the integrity of BBB, but the nature of it remains to be elucidated. And radiologists should know that sometimes, differentiation between RCVS and CNS vasculitis may be challenging in case of vascular wall enhancement.

### Author Contributions

Conceptualization, K.E.S.; project administration, K.E.S.; resources, K.E.S.; supervision, K.E.S.; visualization, H.S.A.; writing—original draft, K.E.S., H.S.A.; and writing—review and editing, all authors.

### Conflicts of Interest

The authors have no potential conflicts of interest to disclose.

## REFERENCES

1. Miller TR, Shivashankar R, Mossa-Basha M, Gandhi D. Reversible cerebral vasoconstriction syndrome, part 1: epidemiology, pathogenesis, and clinical course. *AJNR Am J Neuroradiol* 2015;36:1392-1399
2. Miller TR, Shivashankar R, Mossa-Basha M, Gandhi D. Reversible cerebral vasoconstriction syndrome, part 2: diagnostic work-up, imaging evaluation, and differential diagnosis. *AJNR Am J Neuroradiol* 2015;36:1580-1588
3. Chen CY, Chen SP, Fuh JL, Lirng JF, Chang FC, Wang YF, et al. Vascular wall imaging in reversible cerebral vasoconstriction syndrome - a 3-T contrast-enhanced MRI study. *J Headache Pain* 2018;19:74
4. Singhal AB, Topcuoglu MA. Glucocorticoid-associated worsening in reversible cerebral vasoconstriction syndrome. *Neurology* 2017;88:228-236
5. Mandell DM, Matouk CC, Farb RI, Krings T, Agid R, TerBrugge K, et al. Vessel wall MRI to differentiate between reversible cerebral vasoconstriction syndrome and central nervous system vasculitis: preliminary results. *Stroke* 2012;43:860-862
6. Obusez EC, Hui F, Hajj-Ali RA, Cerejo R, Calabrese LH, Hammad T, et al. High-resolution MRI vessel wall imaging: spatial and temporal patterns of reversible cerebral vasoconstriction syndrome and central nervous system vasculitis. *AJNR Am J Neuroradiol* 2014;35:1527-1532
7. Han JS, Mandell DM, Poubanc J, Mardimae A, Slessarev M, Jaigobin C, et al. BOLD-MRI cerebrovascular reactivity findings in cocaine-induced cerebral vasculitis. *Nat Clin Pract Neurol* 2008;4:628-632
8. Lee MJ, Cha J, Choi HA, Woo SY, Kim S, Wang SJ, et al. Blood-brain barrier breakdown in reversible cerebral vasoconstriction syndrome: implications for pathophysiology and diagnosis. *Ann Neurol* 2017;81:454-466
9. Lee EK, Lee EJ, Kim S, Lee YS. Importance of contrast-enhanced fluid-attenuated inversion recovery magnetic resonance imaging in various intracranial pathologic conditions. *Korean J Radiol* 2016;17:127-141
10. Sanossian N, Saver JL, Alger JR, Kim D, Duckwiler GR, Jahan R, et al. Angiography reveals that fluid-attenuated inversion recovery vascular hyperintensities are due to slow flow, not thrombus. *AJNR Am J Neuroradiol* 2009;30:564-568

## 조영증강 유체감쇠반전회복기법 영상에서 일과성 혈관 벽 조영증강으로 나타나는 가역성 대뇌 혈관 수축 증후군: 증례 보고 및 문헌 고찰

허선아 · 김은수\* · 이 열

가역성 대뇌 혈관 수축 증후군(reversible cerebral vasoconstriction syndrome)은 벼락두통과 함께 3개월 안에 소실되는 뇌혈관의 다발성 협착을 특징으로 하는 임상적 영상의학적 증후군이다. 해당 환자 중 일부에서 혈관 벽 조영증강이 보고되고 있으나 그 병태생리학적 의미와 진단적 가치는 불분명하다. 이에 혈관 벽 조영증강을 동반한 가역성 대뇌 혈관 수축 증후군의 증례를 보고하고 병태생리학적 의미와 진단적 가치를 고찰하고자 한다.

한림대학교 의과대학 한림대학교성심병원 영상의학과