

Original article

# Clinical results of arthroscopic polyglycolic acid sheet patch graft for irreparable rotator cuff tears

Yu Mochizuki <sup>a,\*</sup>, Mitsuo Ochi <sup>b</sup>

<sup>a</sup> Hiroshima Prefectural Hospital, Ujina-Knada, Minami-Ku, Hiroshima, Japan

<sup>b</sup> Hiroshima University, Hiroshima, Japan

Received 15 June 2014; revised 28 September 2014; accepted 24 November 2014

Available online 9 February 2015

## Abstract

The high retear rates after surgery for irreparable rotator cuff tears can be explained by the healing capacity potential of tendons and the native rotator cuff enthesis characterised by complex morphological structures, called direct insertion. Many experimental researches have focused on biologically augmenting the rotator cuff reconstruction and improving tendon–bone healing of the rotator cuff. The results of the experimental study showed that the polyglycolic acid sheet scaffold material allows for the regeneration of not only tendon-to-tendon, but also tendon-to-bone interface in an animal model. We performed a clinical study of the arthroscopic polyglycolic acid sheet patch graft used for the repair of irreparable rotator cuff tears. One-year clinical results of the repair of irreparable rotator cuff tears by arthroscopic patch graft with a polyglycolic acid sheet demonstrated improved shoulder function and a significantly lower retear rate, compared with patients treated with a fascia lata patch.

Copyright © 2014, Asia Pacific Knee, Arthroscopy and Sports Medicine Society. Published by Elsevier (Singapore) Pte Ltd. This is an open access article under the CC BY-NC-ND license (<http://creativecommons.org/licenses/by-nc-nd/4.0/>).

**Keywords:** artificial biomaterials; irreparable rotator cuff tears; operative results

## Introduction

Rotator cuff tears represent the most common cause of shoulder pain in patients older than 60 years. Surgical repair of rotator cuff tears has become a common procedure with good clinical results.<sup>1–4</sup> Failure of the repair of massive rotator cuff tears occurs in 20–68% of patients, depending on tear size, patient age, muscle atrophy, muscle fatty degeneration, and chronicity.<sup>5–11</sup> In addition, high retear rates after surgery can be attributed to the quality of the residual tendon and the healing capacity potential of residual tendons.

Native rotator cuff enthesis is characterised by complex morphological structures and is called direct insertion. This

complex morphological structure of bone tendon insertion is difficult to repair.

When the primary repair of the massive rotator cuff tear is impossible, the lesion is called an irreparable rotator cuff tear. Treatment of the irreparable rotator cuff tear was difficult due to many factors.

Patients with irreparable rotator cuff tears can present with a variety of manifestations. They may have no or mild symptoms, or they may be completely disabled and in severe pain. The true incidence of irreparable rotator cuff tears is not known; however, anatomical studies on cadavers and imaging studies of asymptomatic patients have demonstrated rotator cuff tears in 30–50% of older patients, especially in those older than 70 years.<sup>12–14</sup>

Tempelhof et al<sup>15</sup> studied 411 asymptomatic individuals and found that 38% of those older than 70 years had full-thickness rotator cuff tears.

\* Corresponding author. Hiroshima Prefectural Hospital, 1-5-54, Ujina-Knada, Minami-Ku, Hiroshima 734-8530, Japan.

E-mail address: [yumochi@hph.pref.hiroshima.jp](mailto:yumochi@hph.pref.hiroshima.jp) (Y. Mochizuki).

Rotator cuff tears with an increased degree of fatty infiltration and muscle atrophy, in association with a high-riding humeral head to the acromion, are at high risk of becoming irreparable.

Goutallier et al<sup>9</sup> used computed tomography scans to evaluate fatty infiltration, but magnetic resonance imaging (MRI) is probably more sensitive.<sup>4</sup>

Irreparable rotator cuff tears occur in two physiologically distinct patient groups, but they can be present in all age and activity groups. Most often, these tears occur in physiologically older, lower-demand patients (older than 70 years and usually female) who have been asymptomatic until minor trauma created symptoms. The second group consists of physiologically younger, more active patients, often in the 6<sup>th</sup> decade of life, who present with dramatic symptoms of pain and disability after an acute event or with a history of rotator cuff surgery or chronic rotator cuff injury.

We hypothesised that it would be better to repair the defect of the rotator cuff by the patch graft technique using a polyglycolic acid (PGA) sheet without sacrificing the autologous tissues such as fascia lata, and the minimally invasive operative procedure, arthroscopic patch graft, should be selected.

The purpose of this study was to investigate the short-term clinical results of arthroscopic PGA sheet patch graft for irreparable rotator cuff tears.

## Materials and methods

We defined the irreparable rotator cuff tears as those that, because of their size and retraction, cannot be repaired primarily to the site of their insertion onto the tuberosities, despite conventional techniques of mobilisation and soft-tissue releases.

This study involved 62 patients selected from 336 patients who were evaluated by the shoulder surgery section of our department for shoulder pain in the years 2011–2013. The study was performed according to our hospital ethics committee guidelines and approved by our hospital ethics committee. These patients (21 women and 41 men), with a mean age of 65.5 years (range, 57–77 years), were diagnosed with irreparable rotator cuff tears.

Patients were assigned to surgical treatment of repair with a PGA sheet (Neoveil, Gunze, Japan) patch graft (PGA group, 30 patients), or with a fascia lata patch graft (PG group, 32 patients). Informed consent was obtained from all patients. The kind of patch to be used was selected randomly. Patients were treated by the same surgical team.

The exclusion criteria were as follows: (1) osteoarthritis of the glenohumeral joint; (2) inflammatory arthritis or any rheumatic condition; (3) labral lesions requiring additional procedures such as type 2 superior labrum anterior–posterior or Bankart lesions; (4) biceps lesions requiring tenodesis; and (5) injuries of the contralateral shoulder.

The surgical procedure for all patients was performed arthroscopically. Partial bursectomy, minimal acromioplasty, and adhesion release were performed. The size of the defect was measured, and a graft of the same size as the defect was

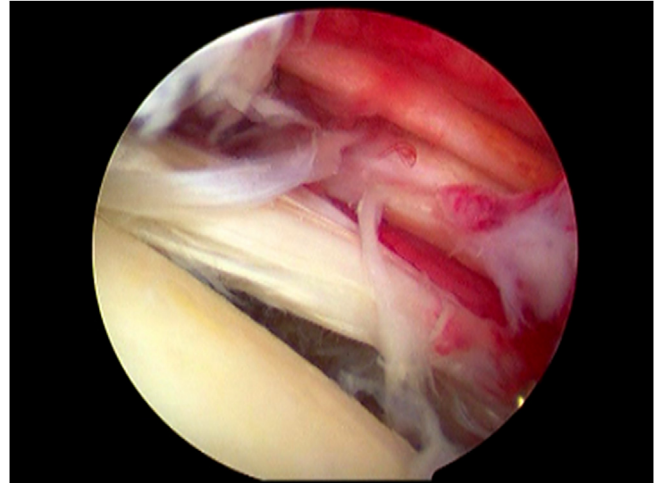


Fig. 1. Arthroscopic finding. The irreparable rotator cuff injury was found arthroscopically.

made using a PGA sheet (PGA group) or a fascia lata (PG group). The graft was placed underneath and overlapped with the edge of the torn tendons of >5 mm width to protect the superior migration of the humeral head. The sutures on the graft were passed through the tendon and tied up on the surface of the tendon. The fascia lata was harvested from the lateral side of the thigh just distal to the great trochanter. The footprint was prepared with a rasp, and two or three suture anchors were used in a single-row fashion (Figs. 1 and 2).

All patients followed the same rehabilitation regimen, which included the use of a rigid brace for 3 weeks and passive movement exercises under the supervision of a physical therapist for 5 additional weeks. Active movement exercises were commenced at 3 weeks with the limitation of the elevation angle. A strengthening exercise program started at 12 weeks postoperatively.

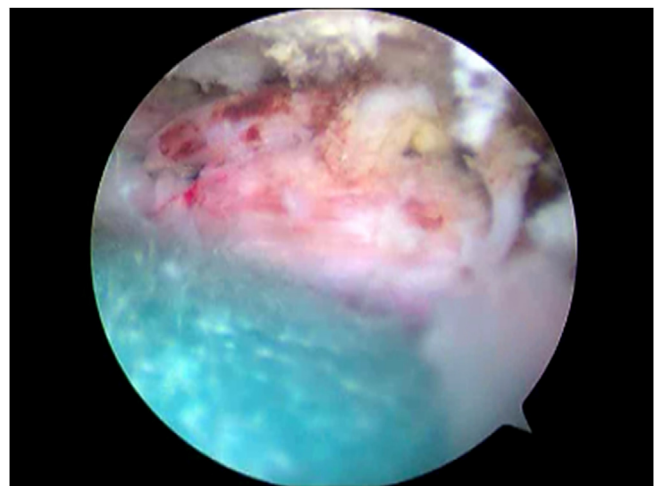


Fig. 2. Arthroscopic finding. Arthroscopic polyglycolic acid sheet patch graft was performed for an irreparable rotator cuff injury.

Patients were clinically evaluated pre- and postoperatively at 1 month, 3 months, 6 months, and 12 months. The Japanese Orthopaedic Association (JOA) shoulder rating scale was used to evaluate patients preoperatively and at 12 months postoperatively. The MRI examination was performed at 1 year postoperatively in all patients. The intensity of the grafted patch was graded as high, iso, and low intensity. The patients were classified as high-intensity, iso-intensity, and low-intensity groups. The patients whose grafted patch contained a large amount of high-intensity area were assigned to the high-intensity group, those with a large amount of iso-intensity area in the grafted patch to the iso-intensity group, and those with a large amount of low-intensity area in the grafted patch to the low-intensity group. The high-intensity area was thought to contain poorly matured tissues and the low-intensity area was thought to contain well-matured tissues. The rate comparing the high-intensity group and the others was defined as the high-intensity rate. No second-look arthroscopic surgeries or biopsies were performed.

Statistical analysis was conducted by the Mann–Whitney *U* test among treatment groups. When comparing a pre–post treatment, a paired *t* test was performed. When comparing high-intensity rates, a Pearson Chi-square test was used. A *p* value <0.05 was considered as statistically significant.

## Results

The follow-up analysis showed that each group benefitted from the surgical treatment of irreparable rotator cuff tears.

The mean JOA scores improved from  $54.9 \pm 1.1$  points preoperatively to  $90.7 \pm 1.0$  points at the 12-month follow-up ( $p < 0.01$ ) in the PGA group and from  $52.6 \pm 1.5$  points preoperatively to  $91.7 \pm 1.2$  points at the 12-month follow-up ( $p < 0.01$ ) in the PG group (Table 1).

MRI findings at 1 year showed a high-intensity rate of 13.3% (4/30 patients) in the PGA group and 31.2% (10/32 patients) in the PG group (Figs. 3 and 4). The high-intensity rate was significantly lower for the PGA group ( $p = 0.001$ ). The type of implanted patch was the only factor affecting the retear rate. No major complications occurred. No adverse events were related to patch application, including the absence of local inflammation, fibrosis, and subacromial adhesions affecting joint function.

Table 1  
JOA score of each group (points).<sup>a</sup>

	Prior to surgery	12 mo after surgery
PGA group	$54.9 \pm 1.1$	$90.7 \pm 1.0^*$
PG group	$52.6 \pm 1.5$	$91.7 \pm 1.2^*$

\* $p < 0.01$ .

JOA = Japanese Orthopaedic Association; PG group = patient group assigned to repair with a fascia lata patch graft; PGA group = patient group assigned to repair with polyglycolic acid.

<sup>a</sup> The mean JOA scores improved from  $54.9 \pm 1.1$  points preoperatively to  $90.7 \pm 1.0$  points at the 12-month follow-up ( $p < 0.01$ ) in the PGA group and from  $52.6 \pm 1.5$  points preoperatively to  $91.7 \pm 1.2$  points at the 12-month follow-up ( $p < 0.01$ ) in the PG group.

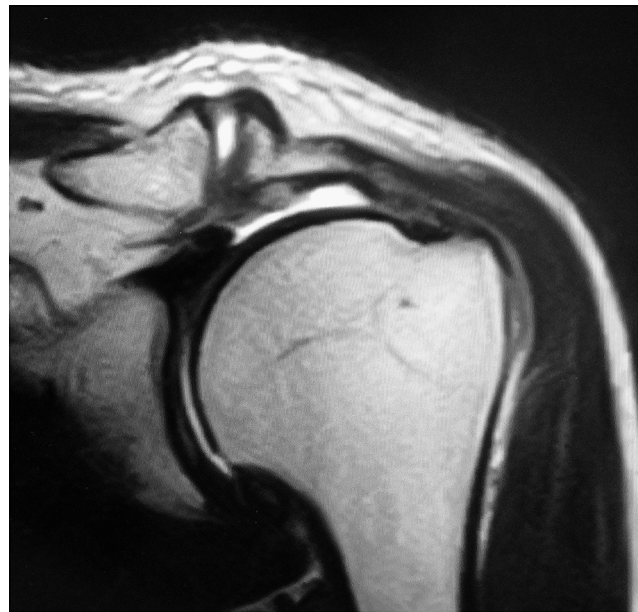


Fig. 3. Magnetic resonance imaging finding prior to surgery.

## Discussion

It was shown that a patch graft with a PGA sheet, an artificial biomaterial, can improve the results of repair of irreparable rotator cuff tears in terms of postoperative pain control and short-term outcome. The use of patches, either biological or artificial biomaterial, has been advocated to reduce the high-intensity rate, which is supported by the rationale that collagenous scaffolds may improve tendon resiliency after

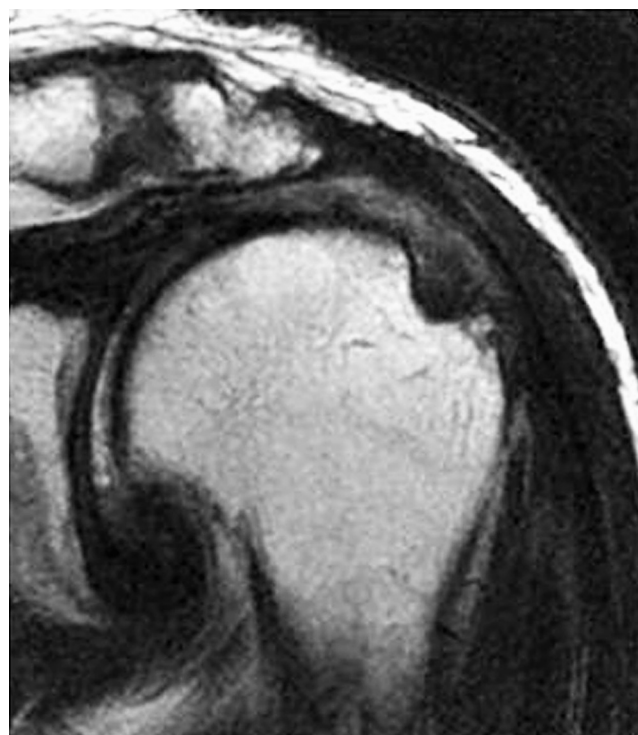


Fig. 4. Magnetic resonance imaging finding 1 year after surgery.



repair, even if they are typically absorbed within a few weeks of implantation.<sup>16</sup>

On the one hand, biological patches are mechanically weak<sup>17</sup> and are also rapidly resorbed upon implantation. On the other hand, biological patches provide a suitable environment for tissue repair,<sup>18,19</sup> while artificial biomaterials are biologically inert and thought not to provide regenerative stimuli that support the healing process.

Theoretically, the ideal patch for the repair of rotator cuff should combine the features of both biological and artificial biomaterial patches, serving as an inductive template to carry signals supporting tissue regeneration.<sup>19</sup> The quality of tendons has considerable limitations regarding torn rotator cuff tendons.

Tissue-engineering techniques using a biodegradable scaffold offer potential alternatives for recreating valid tendon-to-tendon and tendon-to-bone interfaces. An implant consisting of a PGA sheet, a rapidly absorbable material, was used to replace a completely resected infraspinatus tendon insertion in 33 adult Japanese white rabbits, and a well-arranged fibrocartilage layer could be found in the regenerated tendon insertions; however, these tendon insertions were mainly regenerated by type III collagen.<sup>20</sup> From the results of this experimental study, we concluded that the PGA sheet scaffold material allows for the regeneration of not only tendon-to-tendon, but also tendon-to-bone interface, in an animal model. A PGA sheet was a possible alternative scaffold material for tendon regeneration in rotator cuff repair.

In an effort to augment the deficient rotator cuff tissue, and at the same time to maintain the anatomic integrity of the shoulder, some surgeons are incorporating biological tissue scaffolds into the cuff deficiency.<sup>21–24</sup> A porcine submucosa subintestinal graft, named Restore (DePuy, Warsaw, IN, USA), was found to increase pain and lead to poor tendon healing. Its clinical outcome in humans was in contrast to the outcomes of many preclinical animal studies. This suggests that Restore may not be suitable for human rotator cuff repair.<sup>25</sup>

GraftJacket (Wright Medical Group, Memphis, TN, USA) is derived from human dermis, and has been used as an interpositional graft in case of massive and irreparable RCT. An improvement in UCLA shoulder scores at the 2-year follow-up has been demonstrated. Furthermore, magnetic resonance has demonstrated tissue incorporation into the graft.<sup>26</sup>

Synthetic scaffolds include polytetrafluoroethylene (PTFE) felts and polyester grafts. PTFE improved pain scores in 30 patients with massive rotator cuff tears.<sup>27</sup> Teflon (PTFE graft) provided satisfactory functional results and strength in 23 out of 25 patients, again with massive rotator cuff tears.<sup>28</sup> Gore-Tex (PTFE graft) improved the mean JOA score of 27 patients from 57.7 to 88.7.<sup>29</sup> Dacron (polyester) improved the Constant score in 15 of 17 patients. The Leeds-Keio graft (polyester) used in subscapular transposition augmentation showed superior clinical results to those with augmentation grafts.<sup>30</sup>

Chemical and physical properties of synthetic grafts can be controlled, although the trade-off is a lack of

biocompatibility, which usually makes the graft nonabsorbable. In addition, a high rate of immune and inflammatory response has been reported.<sup>31</sup> For these reasons, a PGA sheet may be an ideal patch, being absorbable and regenerative at this point. However, the satisfactory results reported here, extensive clinical experience, and successful outcomes prompt further studies.

Limitations of this study include the following: (1) the retrospective design, requiring further randomised prospective studies to ultimately assess the value of patch graft in rotator cuff repair; (2) the lack of an *a priori* power analysis; and (3) the fact that no second-look arthroscopic surgery was performed, nor was biopsy of the repair tissue performed.

## Conclusion

One-year clinical results of the repair of irreparable rotator cuff tears by arthroscopic patch graft with a PGA sheet demonstrated improved shoulder function and a significantly lower high-intensity rate, compared with patients treated with a fascia lata patch. A PGA sheet, an absorbable artificial biomaterial, may be an ideal patch, being absorbable and regenerative at this point.

The satisfactory results reported here, extensive clinical experience, and successful outcomes prompt further studies.

## Conflicts of interest

The authors, their families, and any research foundations to which they are affiliated did not receive any financial payments or other benefits from any commercial entity related to the subject matter of this article.

## References

1. Kamath G, Galatz LM, Keener JD, et al. Tendon integrity and functional outcome after arthroscopic repair of high-grade partial-thickness supraspinatus tears. *J Bone Joint Surg Am.* 2009;91:1055–1062.
2. Nho SJ, Shindle MK, Adler RS, et al. Prospective analysis of arthroscopic rotator cuff repair: subgroup analysis. *J Shoulder Elbow Surg.* 2009;18:697–704.
3. Verma NN, Bhatia S, Baker III CL, et al. Outcomes of arthroscopic rotator cuff repair in patients aged 70 years or older. *Arthroscopy.* 2010;26:1273–1280.
4. Warrender WJ, Brown OL, Abboud JA. Outcomes of arthroscopic rotator cuff repairs in obese patients. *J Shoulder Elbow Surg.* 2011;20:961–967.
5. Boileau P, Brassart N, Watkinson DJ, et al. Arthroscopic repair of full-thickness tears of the supraspinatus: does the tendon really heal? *J Bone Joint Surg Am.* 2005;87:1229–1240.
6. Cole BJ, McCarty III LP, Kang RW, et al. Arthroscopic rotator cuff repair: prospective functional outcome and repair integrity at minimum 2-year follow-up. *J Shoulder Elbow Surg.* 2007;16:579–585.
7. Coleman SH, Fealy S, Ehteshami JR, et al. Chronic rotator cuff injury and repair model in sheep. *J Bone Joint Surg Am.* 2003;85:2391–2402.
8. Galatz LM, Ball CM, Teefey SA, et al. The outcome and repair integrity of completely arthroscopically repaired large and massive rotator cuff tears. *J Bone Joint Surg Am.* 2004;86:219–224.
9. Goutallier D, Postel JM, Lavau L, et al. [Impact of fatty degeneration of the supraspinatus and infraspinatus muscles on the prognosis of surgical repair of the rotator cuff]. *Rev Chir Orthop Reparatrice Appar Mot.* 1999;85:668–676.

10. Harryman 2nd DT, Mack LA, Wang KY, et al. Repairs of the rotator cuff: correlation of functional results with integrity of the cuff. *J Bone Joint Surg Am.* 1991;73:982–989.
11. Klepps S, Bishop J, Lin J, et al. Prospective evaluation of the effect of rotator cuff integrity on the outcome of open rotator cuff repairs. *Am J Sports Med.* 2004;32:1716–1722.
12. Depalma AF, Callery G, Bennett GA. Variational anatomy and degenerative lesions of the shoulder joint. *Instr Course Lect.* 1949;6:255–281.
13. Codman EA. Rupture of the supraspinatus. *Am J Surg.* 1938;42:603–606.
14. Sher JS, Uribe JW, Posada A, et al. Abnormal findings on magnetic resonance images of asymptomatic shoulders. *J Bone Joint Surg Am.* 1995;77:10–15.
15. Tempelhof S, Rupp S, Seil R. Age-related prevalence of rotator cuff tears in asymptomatic shoulders. *J Shoulder Elbow Surg.* 1999;8:296–299.
16. Badylak SF, Tullius R, Kokini K, et al. The use of xenogeneic small intestinal submucosa as a biomaterial for Achilles tendon repair in a dog model. *J Biomed Mater Res.* 1995;29:977–985.
17. Badylak S, Kokini K, Tullius B, et al. Strength over time of a resorbable bioscaffold for body wall repair in a dog model. *J Surg Res.* 2001;99:282–287.
18. Beattie AJ, Gilbert TW, Guyot JP, et al. Chemoattraction of progenitor cells by remodeling extracellular matrix scaffolds. *Tissue Eng Part A.* 2009;15:1119–1125.
19. Derwin KA, Badylak SF, Steinmann SP, et al. Extracellular matrix scaffold devices for rotator cuff repair. *J Shoulder Elbow Surg.* 2010;19:467–476.
20. Yokoya A, Mochizuki Y, Nagata Y, et al. Tendon-bone insertion repair and regeneration using polyglycolic acid sheet in the rabbit rotator cuff injury model. *Am J Sports Med.* 2008;36:1298–1309.
21. Ahmad Z, Henson F, Wardale J, et al. Review article: regenerative techniques for repair of rotator cuff tears. *J Orthop Surg.* 2013;21:226–231.
22. Bond JL, Dopirak RM, Higgins J, et al. Arthroscopic replacement of massive, irreparable rotator cuff tears using a Graft-Jacket allograft: technique and preliminary results. *Arthroscopy.* 2008;24:403–409.
23. Cho NS, Yi JW, Rhee YG. Arthroscopic biceps augmentation for avoiding undue tension in repair of massive rotator cuff tears. *Arthroscopy.* 2009;25:183–191.
24. Rhee YG, Cho NS, Lim CT, et al. Bridging the gap in immobile massive rotator cuff tears: augmentation using the tenotomized biceps. *Am J Sports Med.* 2008;36:1511–1518.
25. Iannotti JP, Codsi MJ, Kwon YW, et al. Porcine small intestine submucosa augmentation of surgical repair of chronic two-tendon rotator cuff tears. A randomized, controlled trial. *J Bone Joint Surg Am.* 2006;88:1238–1244.
26. Wong I, Burns J, Snyder S. Arthroscopic GraftJacket repair of rotator cuff tears. *J Shoulder Elbow Surg.* 2010;19(Suppl):104–109.
27. Kimura A, Okamura K, Fukushima S, et al. Clinical results of rotator cuff reconstruction with PTFE felt augmentation for irreparable massive rotator cuff tears. *Shoulder Joint.* 2000;24:485–488.
28. Ozaki J, Fujimoto S, Masuhara K, et al. Reconstruction of chronic massive rotator cuff tears with synthetic materials. *Clin Orthop Relat Res.* 1986;202:173–183.
29. Hirooka A, Yoneda M, Wakaitani S, et al. Augmentation with a Gore-Tex patch for repair of large rotator cuff tears that cannot be sutured. *J Orthop Sci.* 2002;7:451–456.
30. Nada AN, Debnath UK, Robinson DA, et al. Treatment of massive rotator-cuff tears with a polyester ligament (Dacron) augmentation: clinical outcome. *J Bone Joint Surg Br.* 2010;92:1397–1402.
31. Chen J, Xu J, Wang A, et al. Scaffolds for tendon and ligament repair: review of the efficacy of commercial products. *Expert Rev Med Devices.* 2009;6:61–73.