

# Anterior Inferior Iliac Spine Deformity as a Cause for Extra-articular Hip Impingement in Young Athletes After an Avulsion Fracture: A Case Report

Eduardo N. Novais, MD,<sup>†</sup> Mark F. Riederer, MD,<sup>\*\*</sup> and Aaron J. Provance, MD<sup>§</sup>

Extra-articular hip impingement from prior traumatic injury to the anterior inferior iliac spine (AIIS) is an uncommon cause of groin pain in young athletes. Currently, the most common treatment for this injury is arthroscopic decompression. However, hip arthroscopy is not universally available and requires advanced skills. We report 2 cases of the development of extra-articular hip impingement from unusual bony exostoses off the AIIS after traumatic injury in 2 young athletes who underwent open surgical resection. The multidisciplinary sports medicine team should be aware of the development of extra-articular impingement from traumatic injury to the AIIS and that open surgical resection is a viable alternative to arthroscopic decompression.

**Keywords:** anterior inferior iliac spine; extra-articular hip impingement; young athletes

Over the past several years, much attention has been directed toward femoroacetabular impingement (FAI) as a frequent cause of mechanical hip pain.<sup>6</sup> Typically, FAI is caused by abnormal contact between the femur against the acetabular rim secondary to intra-articular abnormalities in the femoral head-neck junction (cam lesion), acetabulum (pincer lesion), or a combination of both.<sup>1</sup> Extra-articular causes of hip impingement, including psoas impingement,<sup>8</sup> greater trochanteric–pelvic impingement,<sup>14,17</sup> anterior inferior iliac spine (AIIS) impingement,<sup>7,13,18</sup> and ischiofemoral impingement,<sup>22</sup> have been described.<sup>2</sup>

Extra-articular FAI secondary to abnormal contact between the distal aspect of the femoral neck and a prominent AIIS may result from an abnormal morphology of the AIIS after an apophyseal avulsion fracture. A recent study showed that 49% of all pediatric pelvic avulsion fractures involve the AIIS, and these injuries have an increased risk of developing future pain and nonunion.<sup>21</sup> Although previous case reports described excision of the prominent bone mass<sup>20</sup> and a combined anterior approach to the hip with arthroscopy,<sup>18</sup> currently, the most common treatment for extra-articular FAI caused by an

abnormally shaped AIIS is arthroscopic decompression of the subspine space.<sup>2,7,11,13,16</sup> Hip arthroscopy, however, is not a universally available surgical procedure, and the use of hip arthroscopy for the treatment of extra-articular subspine FAI may require advanced skills and a steep learning curve.

We report 2 cases of extra-articular FAI secondary to abnormal morphology of the AIIS after malunion of a traumatic injury. Both cases were in 2 adolescent athletes, one of whom had a classic avulsion injury with typical radiographic findings and the other with a more unusual presentation with atypical radiographic findings. They were both treated using an open anterior approach to the hip.

## PATIENT 1

A 13-year-old male football player presented to clinic with a 3-month history of right hip pain. He recalled being struck in the anterior right hip while playing football 3 months prior, which initiated his pain. He rated his pain as a 4 on a 10-point scale (0, no pain; 10, most pain imaginable). Running and jumping aggravated the pain, as well as sitting for a long period

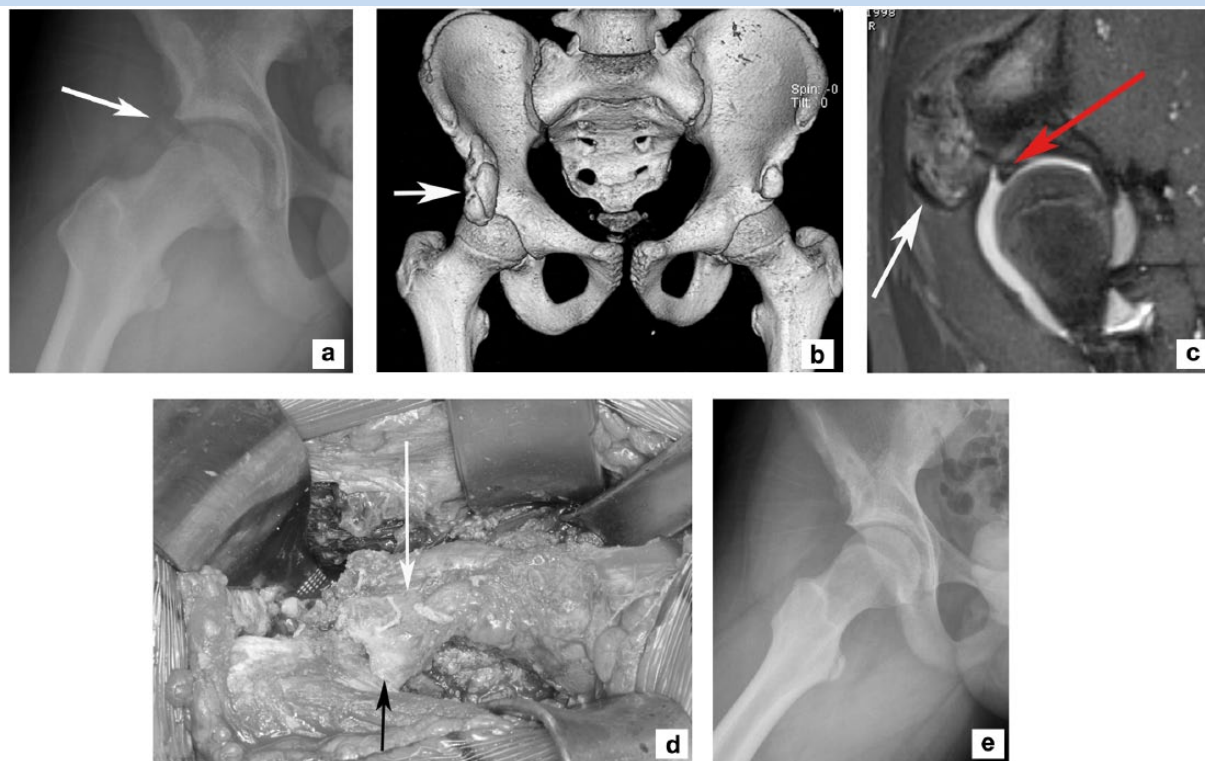
From the <sup>†</sup>Department of Orthopaedics, Boston Children's Hospital, Boston, Massachusetts, <sup>‡</sup>Department of Pediatrics and Orthopaedic Surgery, Nemours/Alfred I. duPont Hospital for Children, Wilmington, Delaware, and <sup>§</sup>Department of Orthopedics, Children's Hospital Colorado, Aurora, Colorado

\*Address correspondence to Mark F. Riederer, MD, Department of Pediatrics and Orthopaedic Surgery, Nemours/Alfred I. duPont Hospital for Children, 1600 Rockland Road, Wilmington, DE 19803 (email: mark.riederer@nemours.org).

The authors report no potential conflicts of interest in the development and publication of this article.

DOI: 10.1177/1941738117744547

© 2017 The Author(s)



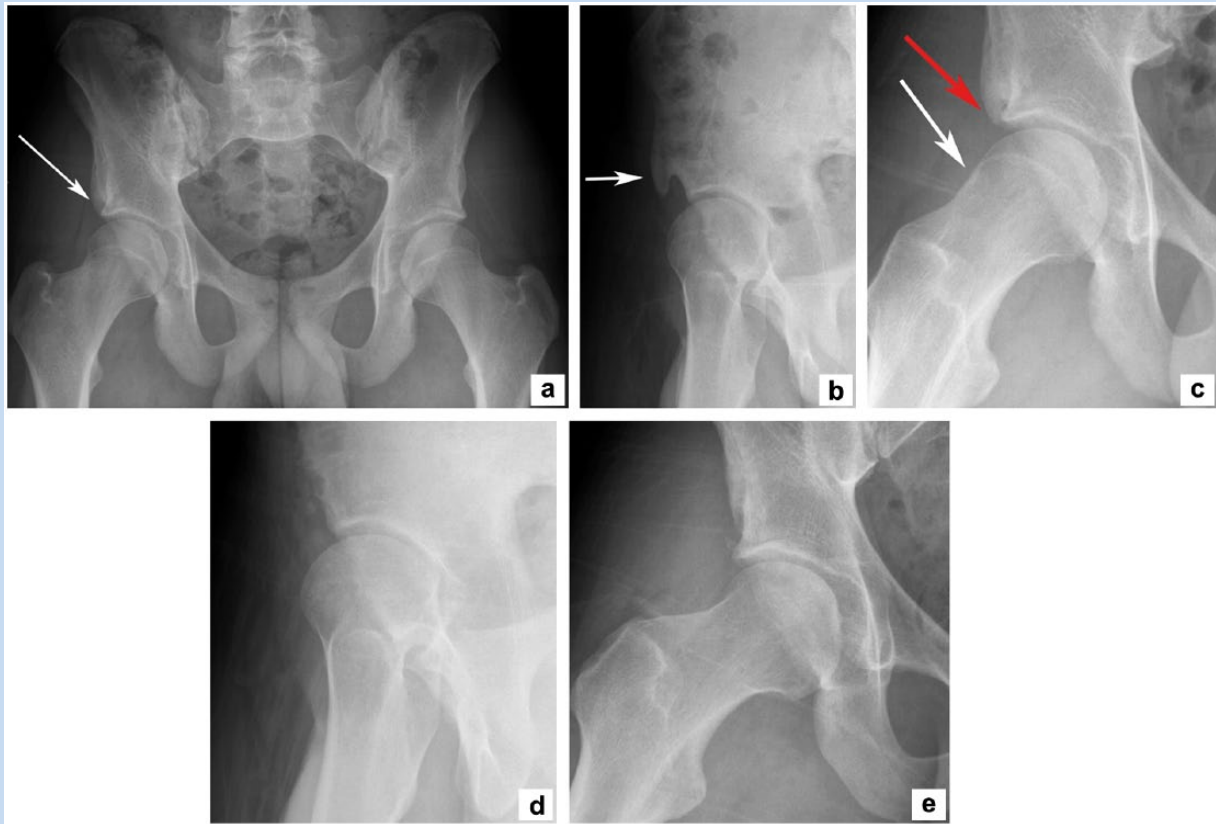
**Figure 1.** A 13-year-old male football player presented to clinic with a 3-month history of right hip pain that started when he was tackled while playing football. (a) A frog leg lateral radiograph of the right hip revealed a normal femoral shape with an irregular area of calcification protruding toward the femoral neck (arrow). (b) A 3-dimensional computed tomography scan revealed a large bone mass at the level of the anterior inferior iliac spine (AIIS). (c) An axial magnetic resonance arthrogram revealed a large osteocartilaginous mass protruding from the AIIS toward the hip joint (white arrow). The acetabular labrum is intact, with no evidence of a full-thickness tear (red arrow). (d) Final intraoperative photograph showing the rectus femoris direct head sutured back to its insertion through a small wafer of bone (white arrow) and the indirect head sutured back to its stump (black arrow). (e) A frog leg lateral radiograph 2 years after surgery showing no recurrence of the AIIS impingement lesion and normal femoral head-neck offset.

of time. On examination, there was tenderness to palpation over the AIIS. Range of motion of the right hip was limited to 90° of flexion compared with 120° on the contralateral side. Pure flexion on the right caused worsening pain. Internal rotation with the hip flexed to 90° was also limited to 10° compared with the contralateral hip, which measured 30°. Initial standing anteroposterior (AP), Dunn lateral, and false-profile radiographs were obtained. Radiographs demonstrated an irregular bone formation at the level of the AIIS (Figure 1a). Further imaging included a computed tomography (CT) scan that showed a severe hypertrophic chronically avulsed AIIS (Figure 1b). Magnetic resonance imaging (MRI) revealed that there was a cartilaginous component of the hypertrophic AIIS, which was further displaced distally in proximity to the joint (Figure 1c). In addition, there was no intra-articular abnormality. The patient underwent surgical treatment as described without capsulotomy because he was found to have no abnormality of the labrum and normal femoral head-neck junction morphology (Figure 1d).

He returned to football practice 4 months after surgery and to high school football games 6 months postoperatively. At his most recent clinic visit, 26 months after surgery, he was pain free with improved hip motion, with flexion to approximately 100° with no pain and 30° of internal rotation, which was symmetrical to the left hip. Radiographs during his visit show no recurrence of his AIIS impingement (Figure 1e).

## PATIENT 2

A 16-year-old male soccer and baseball athlete presented to the clinic for evaluation of right anterior hip pain lasting 6 months. The pain began after being struck by a car while riding his bicycle and landing on his right hip. He located his pain within his groin and anterior right hip. He rated his pain, which was sharp in nature, as a 6 out of 10. The pain was worse with activities such as running and with prolonged sitting. The patient had received physical therapy for 3 months before being



**Figure 2.** A 16-year-old male soccer and baseball athlete presented to clinic for evaluation of right anterior hip pain lasting for 6 months. The pain began after being struck by a car while riding his bicycle and landing on his right hip. (a) Anteroposterior pelvic radiograph reveals an abnormal sclerotic calcification at the level of the anterior inferior iliac spine (AIIS) (arrow). (b) The false-profile view reveals the extension of the bone prominence toward the anterior aspect of the hip joint (arrow). (c) The frog leg lateral radiograph revealed the prominent AIIS (red arrow) as well as an abnormal femoral head-neck junction with a cam-type femoroacetabular impingement morphology (white arrow). (d) A false-profile radiograph revealed decompression of the AIIS 2 years postsurgery. (e) A frog leg lateral radiograph showing a normalized femoral head-neck junction after 2-year follow-up.

seen by an orthopaedic surgeon. On examination, he was found to have focal tenderness over the AIIS. His range of motion on the affected right hip was limited to 100° of flexion compared with 120° on the contralateral side. The patient felt pain with pure flexion. Internal rotation of the right hip was also limited compared with the contralateral side. The anterior impingement sign was positive on the right hip. Initial radiographs included standing AP, Dunn laterals, and false-profile views. Imaging showed an exostosis off the right AIIS and cam-type FAI (Figure 2, a-c). The patient underwent surgical treatment as described with addition of a hip arthrotomy to correct the abnormal femoral head-neck junction cam-FAI morphology. Postoperative radiographs were obtained (Figure 2, d and e). The patient had returned to full level of competitive high school baseball but not soccer at 6 months postoperatively. At his 2-year follow-up visit, 28 months after surgery, he was extremely satisfied with his surgery. He was running and going to the gym but was not playing competitive baseball because of his college duties. His

range of motion improved to 120° of flexion and 35° of internal rotation without pain during the anterior impingement maneuver.

## SURGICAL TECHNIQUE

An incision was made just distal and lateral to the anterior superior iliac spine and extended beyond the AIIS. Dissection was made down to the indirect head of the rectus femoris and was transected. At this point, the hypertrophic bone mass could be palpated at the level of the AIIS and was taken down using a high-speed burr. If correction of a cam-FAI deformity is necessary, an H-shaped capsulotomy can be formed to expose the femoral neck. An osteochondroplasty was performed with the use of a high-speed burr. Fluoroscopic imaging was used to confirm adequate resection of the hypertrophic bone off the AIIS as well as cam-type FAI, if present. Additionally, the hip was moved in flexion and internal rotation to confirm

impingement-free motion. The hip capsule was then closed and the rectus femoris was reattached.

Postoperatively, patients are allowed toe-touch weightbearing for 6 weeks, with progressive weightbearing thereafter. Range of motion of the hip was begun immediately with a continuous passive motion machine, used during the first month in patient 2 who required an intra-articular femoral head-neck osteochondroplasty performed via an arthrotomy. Physical therapy for hip range of motion and strengthening was prescribed at the 6-week visit for a minimum of 12 weeks. Return to full activities was allowed once evidence of bone healing was present on radiographs, typically at the 6-month visit. Both patients received naproxen for the first 3 weeks for heterotopic ossification prophylaxis and aspirin (81 mg daily) for venous thromboprophylaxis.

## DISCUSSION

Abnormal morphology of the AIIS has been recently described as a cause of extra-articular FAI.<sup>7,13,18,20</sup> In the adolescent population, hypertrophy of the AIIS may result from nonunion or malunion after an acute avulsion fracture or may be secondary to repetitive traction injury leading to apophysitis.<sup>5,23</sup> Although pelvic avulsion fractures typically heal uneventfully after conservative treatment, AIIS avulsions may become complicated with persistent pain and nonunion.<sup>21</sup> In this study, we described 2 cases of AIIS hypertrophy secondary to traumatic injury leading to extra-articular subspine FAI. One patient presented with the typical avulsion mechanism and radiographic findings, and the other with more atypical historical and radiographic findings. Both were treated using an open anterior approach to the hip, with return to sports after 6 months and an excellent clinical outcome at a minimum of 2 years.

Historically, avulsion fractures of the AIIS have been thought to happen after contraction of the direct head of the rectus femoris associated with running sports.<sup>5</sup> Although surgical treatment by means of open reduction with internal fixation has been recommended for fractures displaced more than 2 cm,<sup>12,15,20</sup> conservative treatment with protected weightbearing and pain management is typically the first line of choice for an acute avulsion of the AIIS.<sup>3,10</sup> However, in a recent large series of pelvic avulsion fractures, Schuett et al<sup>21</sup> found that there is a high risk of persistent pain and nonunion after fractures of the AIIS. The 2 patients in our series represent the formation of a large protuberant bone mass at the level of the AIIS after an acute avulsion fracture.

The formation of an exostosis after fracture of the AIIS is a rare but well-recognized phenomenon<sup>12</sup>; however, recently it has gained more attention because of its association with persistent pain after conservative treatment.<sup>7,13,15,16,20,21</sup> The etiology of pain after a nonunion or malunion of an AIIS avulsion fracture is not clear. Previous studies have hypothesized a tear of the anterior-superior acetabular labrum to be associated with avulsion of the rectus femoris.<sup>4,9</sup> Other studies, however, described pain secondary to extra-articular

impingement between the prominent AIIS and the femoral neck.<sup>7,13,16,18</sup> There was no evidence of labrum tear on preoperative MRI in both patients. In 1 patient, however, we believed there was an association with an abnormal femoral head-neck junction leading to intra-articular impingement that was treated with an osteochondroplasty, and at the time of surgery, the labrum was found to be intact. In an anatomic study, Philippon et al<sup>19</sup> showed that the direct head of the rectus femoris is not a contiguous structure with the acetabular labrum. The inferolateral corner of the footprint of the direct head of the rectus femoris was found to be located 19 mm from the acetabular rim. We believe that the reason for persistent pain in both patients was secondary to subspine extra-articular FAI, as described by Larson et al.<sup>13</sup>

Although as many as 22% of patients with AIIS avulsion fracture develop pain 3 months or more after the initial injury,<sup>21</sup> there are only isolated case reports of surgical treatment of adolescent patients with subspine FAI secondary to a hypertrophic AIIS.<sup>7,13,16</sup> Surgical treatment via hip arthroscopy has gained attention in the past couple of years.<sup>2,7,11,13,16</sup> Hip arthroscopy has the advantage of exposure and treatment of intra-articular pathology, including labral tears when present; however, it is a technically challenging procedure with a long learning curve. Previous studies that have reported surgical treatment of hypertrophic AIIS described excision of the exuberant bone mass using an anterior approach to the hip.<sup>18,20</sup> We favor the technique described here using a modified Smith Petersen small anterior approach for adolescents with a large hypertrophic bone mass anterior to the hip joint. This approach is widely known by most pediatric orthopaedic surgeons and allows for full exposure of the AIIS as well as to the femoral head-neck junction if treatment of a cam-FAI deformity is required.

## CONCLUSION

We report a rare cause of extra-articular subspine hip impingement after a traumatic avulsion of the AIIS. The practicing orthopaedist or primary care physician should consider this condition in his or her differential diagnosis with a previous history of avulsion fracture of the AIIS. A patient diagnosed with AIIS avulsion fracture should undergo a trial of conservative treatment and return to sport after the fracture is healed and the patient is asymptomatic. Vague anterior hip pain aggravated by flexion of the hip and restricted hip flexion as compared with the contralateral side should raise suspicion of subspine impingement after avulsion of the AIIS. The diagnosis may be delayed for several weeks to months without proper medical imaging or lack of awareness of the condition. We believe that the false-profile view of the pelvis on the affected side allows for initial diagnosis. Once the exostosis is identified on plain radiographs, we favor advanced imaging. Although CT scanning allows for further evaluation of the size and shape of the exostosis as well as surgical planning, it has the disadvantage of ionizing radiation exposure. MRI of the hip

allows for evaluation of the bone mass size and determination of whether there is an associated labral tear. Persistent symptoms after acute avulsion of the AIIS are rare but a potential source of dysfunction in the adolescent athlete. We demonstrate good outcomes and return to sports at a minimum of 2 years in 2 adolescent male athletes after open surgical treatment. When extra-articular impingement from a prominent AIIS after an avulsion injury is identified, the combined open surgical treatment and rehabilitation described herein may be considered as the treatment of choice.

## REFERENCES

1. Beck M, Kalhor M, Leunig M, Ganz R. Hip morphology influences the pattern of damage to the acetabular cartilage: femoroacetabular impingement as a cause of early osteoarthritis of the hip. *J Bone Joint Surg Br.* 2005;87:1012-1018.
2. de Sa D, Alradwan H, Cargnelli S, et al. Extra-articular hip impingement: a systematic review examining operative treatment of psoas, subspine, ischiofemoral, and greater trochanteric/pelvic impingement. *Arthroscopy.* 2014;30:1026-1041.
3. Dunn AW, Morris HD. Fractures and dislocations of the pelvis. *J Bone Joint Surg Am.* 1968;50:1639-1648.
4. Foote CJ, Maizlin ZV, Shrouder J, Grant MM, Bedi A, Ayeni OR. The association between avulsions of the reflected head of the rectus femoris and labral tears: a retrospective study. *J Pediatr Orthop.* 2013;33:227-231.
5. Gallagher JR. Fracture of the anterior inferior spine of the ileum: sprinter's fracture. *Ann Surg.* 1935;102:86-88.
6. Ganz R, Parvizi J, Beck M, Leunig M, Notzli H, Siebenrock KA. Femoroacetabular impingement: a cause for osteoarthritis of the hip. *Clin Orthop Relat Res.* 2003;417:112-120.
7. Hetsroni I, Larson CM, Dela Torre K, Zbeda RM, Magennis E, Kelly BT. Anterior inferior iliac spine deformity as an extra-articular source for hip impingement: a series of 10 patients treated with arthroscopic decompression. *Arthroscopy.* 2012;28:1644-1653.
8. Heyworth BE, Shindle MK, Voos JE, Rudzki JR, Kelly BT. Radiologic and intraoperative findings in revision hip arthroscopy. *Arthroscopy.* 2007;23:1295-1302.
9. Hosalkar HS, Pennock AT, Zaps D, Schmitz MR, Bomar JD, Bittersohl B. The hip antero-superior labral tear with avulsion of rectus femoris (HALTAR) lesion: does the SLAP equivalent in the hip exist? *Hip Int.* 2012;22:391-396.
10. Howard FM, Piha RJ. Fractures of the apophyses in adolescent athletes. *JAMA.* 1965;192:842-844.
11. Hufeland M, Hartwig T, Krüger D, Perka C, Haas NP, Schröder JH. Arthroscopic correction of extra-articular subspinal impingement in the hip joint [in German]. *Orthopade.* 2013;42:879-883.
12. Irving MH. Exostosis formation after traumatic avulsion of the anterior inferior iliac spine. Report of two cases. *J Bone Joint Surg Br.* 1964;46:720-722.
13. Larson CM, Kelly BT, Stone RM. Making a case for anterior inferior iliac spine/subspine hip impingement: three representative case reports and proposed concept. *Arthroscopy.* 2011;27:1732-1737.
14. Macnicol MF, Makris D. Distal transfer of the greater trochanter. *J Bone Joint Surg Br.* 1991;73:838-841.
15. Mader TJ. Avulsion of the rectus femoris tendon: an unusual type of pelvic fracture. *Pediatr Emerg Care.* 1990;6:198-199.
16. Matsuda DK, Calipusan CP. Adolescent femoroacetabular impingement from malunion of the anteroinferior iliac spine apophysis treated with arthroscopic spinoplasty. *Orthopedics.* 2012;35:e460-e463.
17. Novais EN, Clohisy J, Siebenrock K, Podeszwa D, Sucato D, Kim YJ. Treatment of the symptomatic healed Perthes hip. *Orthop Clin North Am.* 2011;42:401-417.
18. Pan H, Kawanabe K, Akiyama H, Goto K, Onishi E, Nakamura T. Operative treatment of hip impingement caused by hypertrophy of the anterior inferior iliac spine. *J Bone Joint Surg Br.* 2008;90:677-679.
19. Philippon MJ, Michalski MP, Campbell KJ, et al. An anatomical study of the acetabulum with clinical applications to hip arthroscopy. *J Bone Joint Surg Am.* 2014;96:1673-1682.
20. Rajasekhar C, Sampath Kumar K, Bhamra MS. Avulsion fractures of the anterior inferior iliac spine: the case for surgical intervention. *Int Orthop.* 2001;24:364-365.
21. Schuett DJ, Bomar JD, Pennock AT. Pelvic apophyseal avulsion fractures: a retrospective review of 228 cases. *J Pediatr Orthop.* 2015;35:617-623.
22. Torriani M, Souto SC, Thomas BJ, Ouellette H, Bredella MA. Ischiofemoral impingement syndrome: an entity with hip pain and abnormalities of the quadratus femoris muscle. *AJR Am J Roentgenol.* 2009;193:186-190.
23. Vandervliet EJ, Vanhoenacker FM, Snoeckx A, Gielen JL, Van Dyck P, Parizel PM. Sports-related acute and chronic avulsion injuries in children and adolescents with special emphasis on tennis. *Br J Sports Med.* 2007;41:827-831.

For reprints and permission queries, please visit SAGE's Web site at <http://www.sagepub.com/journalsPermissions.nav>.