



Surgical Outcomes of Cor Triatriatum Sinister: A Single-Center Experience

Donghee Kim, M.D.¹, Bo Sang Kwon, M.D.², Dong-Hee Kim, M.D., Ph.D.², Eun Seok Choi, M.D., Ph.D.²,
Tae-Jin Yun, M.D., Ph.D.², Chun Soo Park, M.D., Ph.D.²

¹Department of Thoracic and Cardiovascular Surgery and ²Division of Pediatric Cardiac Surgery, Asan Medical Center, University of Ulsan College of Medicine, Seoul, Korea

ARTICLE INFO

Received November 2, 2021

Revised December 20, 2021

Accepted December 29, 2021

Corresponding author

Chun Soo Park

Tel 82-2-3010-3583

Fax 82-2-3010-6966

E-mail hopang1974@hanmail.net;

chunsoo@amc.seoul.kr

ORCID

<https://orcid.org/0000-0001-8718-8904>

Background: We investigated surgical outcomes after the surgical repair of cor triatriatum sinister (CTS).

Methods: Thirty-two consecutive patients who underwent surgical repair of CTS from 1993 through 2020 were included in this study. The morphological characteristics, clinical features, and surgical outcomes were described and analyzed.

Results: The median age and body weight at operation were 9 months (interquartile range [IQR], 3–238 months) and 7.5 kg (IQR, 5.8–49.6 kg), respectively. There were 16 males (50%). According to the modified Lucas classification, type IA (classical CTS) was most common (n=20, 62.5%). Atrial septal defect was associated in 22 patients (68.8%) and anomalous pulmonary venous return in 8 patients (25%). Pulmonary hypertension was preoperatively suspected with a high probability in 18 patients (56.3%). There was 1 early death (3.1%) after emergent membrane excision and hybrid palliation in a high-risk hypoplastic left heart syndrome patient. There were no late deaths. The overall survival rate was 96.9% at 15 years post-repair. No early survivors required reoperation during follow-up. Most survivors (31 of 32 patients, 96.9%) were in New York Heart Association functional class I at a median follow-up of 74 months (IQR, 39–195 months). At the latest echocardiography performed at a median of 42 months (IQR, 6–112 months) after repair, no residual lesion was observed except in 1 patient who had moderate pulmonary hypertension (mean pulmonary arterial pressure of 36 mm Hg).

Conclusion: Surgical repair of cor triatriatum could be performed safely and effectively with an extremely low risk of recurrence.

Keywords: Cor triatriatum, Surgery, Outcomes

Introduction

Cor triatriatum is a rare congenital cardiac anomaly that accounts for 0.1% to 0.4% of all congenital cardiac malformations [1]. In the first description of this anomaly by Church [2] in 1868, the atrial chamber was divided by an accessory membrane. Although this membrane can be found in the right atrium (cor triatriatum dexter), it is more commonly identified in the left atrium (cor triatriatum sinister [CTS]) [1]. In CTS, the posterior proximal pulmonary chamber into which the pulmonary veins enter is separated from the anterior distal chamber, which contains the left atrial appendage and the mitral valve, by a fi-

bromuscular membrane. Multiple theories have been proposed regarding the embryological basis of this disease, but none of them are absolutely conclusive. Based on the degree of intra-atrial obstruction and associated cardiac anomalies, the severity of congestive heart failure and pulmonary hypertension can vary. Resection of the obstructing membrane using cardiopulmonary bypass is the definitive treatment for CTS. It has been reported that the majority of cases of CTS were associated with other congenital cardiac anomalies [3-6], and the surgical outcomes depended upon the complexity of the associated congenital cardiac anomalies [7-9]. However, there is a lack of data regarding the nature and surgical outcomes of CTS due to its rarity.



Therefore, we sought to investigate the outcomes after surgical repair of CTS.

Methods

Patient selection and definition

From April 1993 to June 2020, 34 consecutive patients with cor triatriatum were surgically treated in our center. After exclusion of 2 patients who had a membrane in the right atrium (cor triatriatum dexter), 32 patients were enrolled and analyzed in this study. All the data, including patients' demographics, presenting symptoms, echocardiographic findings, surgical details, perioperative outcomes, and follow-up information, were collected and collated by reviewing electronic medical records. Other imaging modalities such as computed tomography (n=10), magnetic resonance imaging (n=3), and cardiac catheterization (n=2), were also used to better delineate the anatomical details of CTS or to evaluate operability or the coronary arteries. The morphological nature of CTS was described [10,11] and classified based on the modified classification of Lucas [12].

In transthoracic echocardiography (TTE), the echocardiographic probability of pulmonary hypertension was judged by measuring the peak tricuspid regurgitation (TR) velocity or early diastolic pulmonary regurgitation (PR) velocity. Pulmonary hypertension was highly suspected when the peak TR velocity was >3.5 m/sec or the early diastolic PR velocity was >2.5 m/sec on Doppler echocardiography [13]. Right ventricular (RV) function was categorized semi-quantitatively (normal, mild RV dysfunction, or moderate to severe RV dysfunction) using 2-dimensional echocardiographic data obtained from TTE by attending cardiologists [14]. Early death was defined as death before discharge after surgical repair or within 30 days after surgery if the patient was discharged.

This study was approved by the Institutional Review Board of Asan Medical Center (IRB approval no., 2021-1756), and the requirement for informed consent was waived because of the retrospective nature of the study design.

Surgical technique

With standard aortic and bicaval venous cannulation, moderate hypothermic cardiopulmonary bypass was used for the repair of CTS and associated cardiac anomalies. Median sternotomy was used in all except 2 patients. If the patient or guardian makes a strong request to avoid the standard midline incision, another surgical approach (e.g.,

right thoracotomy or submammary incision) could be selected at the surgeon's discretion, although our approach of choice is median sternotomy. In our series, 2 patients underwent repair through right thoracotomy. Repeated doses of antegrade cold crystalloid or blood cardioplegia were administered indirectly. The membrane could usually be resected through an oblique right atrial incision and interatrial septal incision, although an additional left atrial incision was also used to identify an accurate margin for resection in some patients. The pulmonary venous orifices and mitral valve were thoroughly inspected throughout the procedure. Concurrent surgical procedures were performed depending on the accompanying cardiac anomalies. After the discontinuation of cardiopulmonary bypass, intraoperative transesophageal echocardiography was performed to evaluate whether any significant residual lesion was present.

Follow-up

Serial transthoracic echocardiographic images and follow-up data such as New York Heart Association (NYHA) functional class, currently prescribed medications, and any reoperation after the initial surgery were reviewed. Patients who had not visited the outpatient clinic within the last 2 years were contacted by telephone. If the patient could not be reached, survival status was confirmed through the National Insurance Database.

Statistical analysis

Categorical variables were presented as frequencies and percentages of the relevant denominators, and continuous variables were presented as medians with interquartile ranges (IQRs). Due to the limited number of patients and events, analysis for identifying factors associated with events could not be performed. Survival was analyzed using the Kaplan-Meier method. Statistical analysis was performed using IBM SPSS ver. 22.0 (IBM Corp., Armonk, NY, USA).

Results

Baseline characteristics

Table 1 describes the baseline characteristics of the patients. The median age and body weight at operation were 8.5 months (IQR, 3.3–238 months) and 7.5 kg (IQR, 5.8–49.6 kg), respectively. Repair of CTS was performed in infancy (younger than 1 year) in 19 patients (59.4%), among

which 5 neonates (15.6%) were included. Non-cardiovascular anomalies were also present in 5 patients (15.6%), including unilateral pulmonary hypoplasia in 2, congenital tracheal stenosis in 1, facial dysmorphism in 1, congenital hearing loss in 1, ectopic thyroid in 1, and finger anomaly in 1. One patient had Klippel-Feil syndrome.

Table 1. Baseline characteristics

Characteristic	Value
Sex	
Male	16 (50.0)
Female	16 (50.0)
Age (mo)	8.5 (3.3–238.0)
Neonate (<30 days)	5 (15.6)
Infant (1–12 mo)	14 (43.8)
Child or adolescent (1–18 yr)	5 (15.6)
Adult (>18 yr)	8 (25.0)
Body weight (kg)	7.5 (5.8–49.6)
Co-anomalies	
Non-cardiovascular anomaly	5 (15.6)
Klippel-Feil syndrome	1 (2.8)
Presenting symptoms	20 (62.5)
Dyspnea	13 (40.6)
Poor oral intake	5 (15.6)
Cyanosis	4 (12.5)
Failure to thrive	4 (12.5)
Shock	3 (9.4)
Palpitation	2 (6.3)

Values are presented as number (%) or median (interquartile range).

Table 2. Morphological characteristics

Characteristic	Value
Associated cardiac anomalies	28 (87.5)
Atrial septal defect	22 (68.8)
Secundum	18 (56.3)
Sinus venosus	4 (12.5)
Coronary sinus	1 (3.1)
Anomalous pulmonary venous return	8 (25.0)
Partial	6 (18.8)
Total	2 (6.3)
Patent ductus arteriosus	5 (15.6)
Ventricular septal defect	2 (6.3)
Partial atrioventricular septal defect	2 (6.3)
Others ^{a)}	2 (6.3)
Preoperative echocardiography	
Mean pressure gradient across the membrane (mm Hg)	8 (2.7–17.5)
High probability of pulmonary hypertension ^{b)}	18 (56.3)
≥Moderate right ventricle dysfunction	3 (9.4)
Left ventricular ejection fraction (%)	65.0 (60.0–74.5)

Values are presented as number (%) or median (interquartile range).

^{a)}Hypoplastic left heart syndrome in 1 patient, levoatriocardinal vein in 1 patient. ^{b)}Peak tricuspid regurgitation velocity >3.5 m/sec or early diastolic pulmonary regurgitation velocity >2.5 m/sec.

Twenty patients (62.5%) had symptoms at presentation. The most common associated symptom was dyspnea in 13 patients (40.6%), followed by poor oral intake in 5 patients (15.6%), cyanosis in 4 patients (12.5%), and failure to thrive in 4 patients (12.5%). Twelve patients (37.5%) were incidentally diagnosed with murmur or cardiomegaly on a chest radiograph at a routine check-up.

Morphological details and classification

Table 2 depicts the morphological characteristics of the patients. The most common associated cardiac anomaly was atrial septal defect (ASD) in 22 patients (68.8%), followed by anomalous pulmonary venous return in 8 patients (25%; partial form in 6 patients [18.8%] and total form in 2 patients [6.3%]), and patent ductus arteriosus in 5 patients (15.6%). One patient (3.1%) had mitral cleft associated with a partial atrioventricular defect. The mean pressure gradient across the cor triatriatum membrane was measured in 13 patients and had a median value of 8 mm Hg (IQR, 2.7–17.5 mm Hg). Pulmonary hypertension was suspected with high probability in 18 patients (56.3%). Three patients (9.4%) had RV dysfunction of a moderate degree or higher prior to repair. One patient was diagnosed as having single ventricular physiology (hypoplastic left heart syndrome [HLHS]).

Cases of cor triatriatum were morphologically classified using the modified Lucas classification (Table 3). The most common type was classic cor triatriatum, in which an ac-

Table 3. Modified Lucas classification of cor triatriatum

Type	No. (%)
I. Accessory atrial chamber receives all pulmonary veins and communicates with the left atrium	
A. No other connections (classic cor triatriatum)	20 (62.5)
B. Other anomalous connections	
1. To the right atrium directly	4 (12.5)
2. With totally anomalous pulmonary venous connection	2 (6.3)
II. Accessory atrial chamber receives all pulmonary veins and does not communicate with the left atrium	
A. Anomalous connection to the right atrium directly (cardiac totally anomalous pulmonary venous connection with all pulmonary veins first draining to a venous confluence)	0
B. With totally anomalous pulmonary venous connection (supracardiac or infracardiac totally anomalous pulmonary venous connection)	1 (3.1)
III. Subtotal cor triatriatum	
A. Accessory atrial chamber receives part of the pulmonary veins and connects to the left atrium	
1. Remaining pulmonary veins connect normally	0
2. Remaining pulmonary veins connect anomalously (partial cor triatriatum with partially anomalous pulmonary venous connection)	3 (9.4)
B. Accessory atrial chamber receives part of the pulmonary veins and connects to the right atrium	
1. Remaining pulmonary veins connect normally (partially anomalous pulmonary venous connection with anomalously connected pulmonary veins first draining to a venous confluence)	0
2. Remaining pulmonary veins connect anomalously (mixed totally anomalous pulmonary venous connection)	0

Two patients could not be classified.

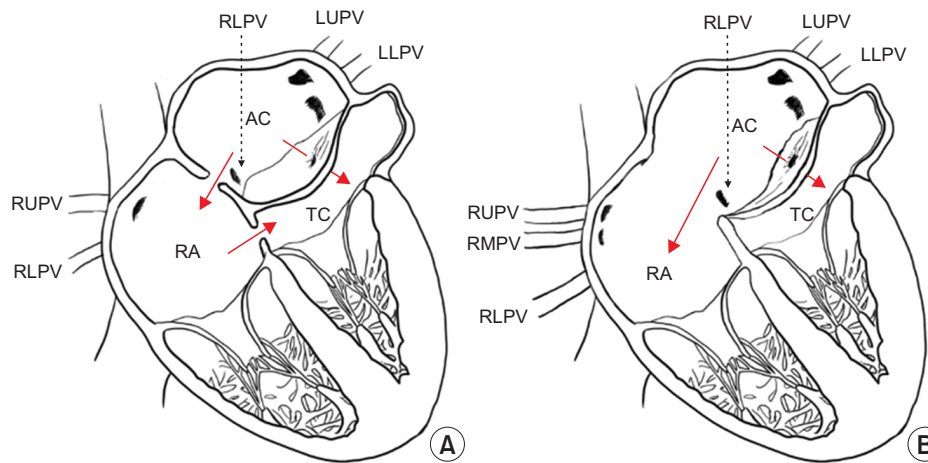


Fig. 1. Schematic diagrams of cardiac anatomy in 2 patients who could not be classified by the modified Lucas classification. Red arrows indicate flow direction. (A) Diagram of patient with cor triatriatum, secundum atrial septal defect (ASD), sinus venosus ASD and partial anomalous pulmonary venous return (PAPVR) (right lower pulmonary vein [RUPV] to right atrium [RA]). The accessory left atrial chamber (AC) that received part of the pulmonary veins was connected to both the left and right atria through the ASD and membranous opening. The true chamber was connected to the right atrium through another ASD. (B) Diagram of patient with cor triatriatum, nearly common atrium, and PAPVR (RUPV and right middle pulmonary vein [RMPV] to RA). The accessory atrial chamber that received part of the pulmonary veins was connected to both left and right atrium through ASD and membranous opening. LLPV, left lower pulmonary vein; LUPV, left upper pulmonary vein; RUPV, right upper pulmonary vein; TC, true left atrial chamber.

cessory atrial chamber receives all pulmonary veins and communicates with the left atrium without another anomalous connection. We presented the anatomical details of 2 patients who could not be classified according to the modified Lucas classification (Fig. 1).

Surgical and perioperative outcomes

The median cardiopulmonary bypass time was 68.5 minutes (IQR, 57.8–99.3 minutes), and the median aortic cross-clamp time was 40.0 minutes (IQR, 24.5–54.5 min-)

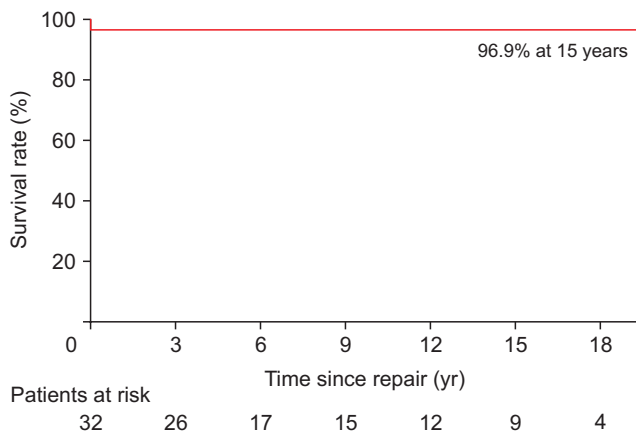


Fig. 2. Overall survival after repair of cor triatriatum sinister. One early death occurred, and there were no late deaths during a median of 74 months of follow-up. The 15-year overall survival rate was 96.9%.

utes). Twenty-nine patients (90.6%) underwent concomitant operative procedures. The most common concomitant procedure was repair of ASD in 26 patients (81.3%). One patient, with high-risk HLHS, underwent hybrid palliation comprising bilateral pulmonary artery banding and implantation of a ductal stent for palliation.

There was 1 early death (3.1%). This patient underwent emergent hybrid palliation (atrial septectomy and cor triatriatum membrane excision with bilateral pulmonary artery banding and ductal stent implantation) for high-risk HLHS. Significant postoperative complications occurred in 4 patients (12.5%); the sternum was left open in 2 patients (6.3%), mechanical circulatory support was required in 1 patient (3.1%), an acute kidney injury requiring renal replacement therapy occurred in 2 patients (6.3%), and postoperative bleeding took place in 1 patient (3.1%). The median length of hospital stay was 7 days (IQR, 6–8 days).

Follow-up

The median follow-up duration was 73.5 months (IQR, 39–195 months). The completeness of follow-up (Clark's C) was 69.2% [15,16]. Including patients who were lost to follow-up, all patients were confirmed to be alive through searching the national insurance database. There were no late deaths. The 15-year overall survival rate was 96.9% (Fig. 2). There were no reoperations or reinterventions during follow-up.

At the latest follow-up echocardiography, which was performed at a median of 42 months (IQR, 6.3–111.5 months) after repair, residual or recurrent lesions could not be identified. In a 19-year-old patient who underwent membrane

resection with ASD closure and intra-atrial baffling to repair partial anomalous pulmonary venous return, the PR velocity was 2.5 m/sec on color Doppler echocardiography performed 11 years after repair. On cardiac catheterization, a moderate degree of pulmonary hypertension (mean pulmonary artery pressure of 36 mm Hg) was confirmed. Three patients (9.4%) were readmitted due to atrial fibrillation, supraventricular tachycardia, and pericardial effusion, respectively.

Discussion

CTS is a rare congenital cardiac anomaly that is usually considered surgically correctable. The presence of an abnormal membrane dividing the left atrium into 2 chambers could hamper the inflow toward the left ventricle. If the obstruction at the level of the membrane is significant, the consequent pulmonary venous obstruction results in pulmonary hypertension and cardiac failure. Patients' clinical manifestation depends upon the degree of hemodynamic obstruction of cor triatriatum itself and associated other structural defects such as partial or total anomalous pulmonary venous drainage. Based on the effective size of the membranous opening, and the presence and location of the ASD, the timing and severity of symptom presentation could differ [17,18]. If the membranous opening is restrictive and ASD is absent or restrictive, symptoms could be present earlier; however, if the opening is non-restrictive or communication between the proximal chamber and the right atrium exist, then subsequent decompression of the proximal chamber might delay symptom presentation [19].

In the severe form of this condition, patients can present with pulmonary edema, pulmonary hypertension, respiratory failure, and cardiogenic shock [20–22]. In addition, most deaths occurred in patients who presented in a critically ill condition combined with complex associated cardiac anomalies [5,9]. In our study, there was 1 early death; this baby was born with HLHS and CTS, representing a high-risk combination, and collapsed immediately after birth, which led us to perform emergent hybrid palliation consisting of excision of the membrane, atrial septectomy, bilateral pulmonary artery banding, and implantation of a ductal stent. Despite the hybrid intervention and subsequent mechanical circulatory support, the patient died of myocardial failure 12 days after the operation.

The classification system of CTS was developed to better understand the anatomical details of the disease and its relationship with associated defects [10–12]; however, there seems to be a lack of power for predicting the hemody-

dynamic consequences of CTS, which might be attributable to the fact that the degree of obstruction through all the communications could not be evaluated in depth using this system (Fig. 1). In our study, we could not identify any difference in echocardiographic findings, presenting age, or degree of symptoms according to the type of defect in both systems. If further information regarding the degree of obstruction through any opening could be incorporated into the current classification system, it might be helpful to predict the hemodynamic status and prognosis following surgical intervention.

The surgical resection of CTS can effectively eliminate the anatomical barrier in the atrium with a very low risk of recurrence [9,23]. In our study, no early survivors required reoperation or reintervention during follow-up. No patients had confirmed pulmonary vein stenosis during follow-up. In addition, we could not observe any finding suggestive of the presence of pulmonary hypertension on TTE in most patients, regardless of age at repair or degree of obstruction prior to repair. In 1 patient, who had a TR velocity of 4.9 m/sec and associated partial anomalous pulmonary venous return on preoperative TTE, a residual moderate degree of pulmonary hypertension (mean pulmonary artery pressure of 36 mm Hg) was confirmed in cardiac catheterization performed 11 years after repair; her NYHA functional class was 2 at the latest follow-up with medication for pulmonary hypertension.

This study was limited by the inherent disadvantages of a retrospective observational study from a single center. Due to the small sample size and the small number of events, a detailed analysis could not be accomplished. Because of all these limitations, the readers should be careful when interpreting the results of this study.

In conclusion, surgical correction of cor triatriatum offers good outcomes with extremely low risk of residual lesion or recurrence. The presence of an accompanying complex cardiac anomaly might be associated with an adverse outcome.

Conflict of interest

No potential conflict of interest relevant to this article was reported.

ORCID

Donghee Kim: <https://orcid.org/0000-0003-2797-4553>
 Bo Sang Kwon: <https://orcid.org/0000-0002-0365-4339>
 Dong-Hee Kim: <https://orcid.org/0000-0002-4021-8712>

Eun Seok Choi: <https://orcid.org/0000-0002-0618-4686>
 Tae-Jin Yun: <https://orcid.org/0000-0002-0336-1720>
 Chun Soo Park: <https://orcid.org/0000-0001-8718-8904>

References

- Jegier W, Gibbons JE, Wiglesworth FW. *Cor triatriatum: clinical, hemodynamic and pathological studies surgical correction in early life*. Pediatrics 1963;31:255-67.
- Church WS. *Congenital malformation of heart-abnormal septum in left auricle*. Trans Pathol Soc Lone 1868;19:188-90.
- Humpl T, Reineker K, Manlhiot C, Dipchand AI, Coles JG, McCrindle BW. *Cor triatriatum sinistrum in childhood: a single institution's experience*. Can J Cardiol 2010;26:371-6.
- Yaroglu Kazanci S, Emani S, McElhinney DB. *Outcome after repair of cor triatriatum*. Am J Cardiol 2012;109:412-6.
- Alphonso N, Norgaard MA, Newcomb A, d'Udekem Y, Brizard CP, Cochrane A. *Cor triatriatum: presentation, diagnosis and long-term surgical results*. Ann Thorac Surg 2005;80:1666-71.
- Saxena P, Burkhart HM, Schaff HV, Daly R, Joyce LD, Dearani JA. *Surgical repair of cor triatriatum sinister: the Mayo Clinic 50-year experience*. Ann Thorac Surg 2014;97:1659-63.
- Salomone G, Tiraboschi R, Bianchi T, Ferri F, Crippa M, Parenzan L. *Cor triatriatum: clinical presentation and operative results*. J Thorac Cardiovasc Surg 1991;101:1088-92.
- Rodefeld MD, Brown JW, Heimansohn DA, et al. *Cor triatriatum: clinical presentation and surgical results in 12 patients*. Ann Thorac Surg 1990;50:562-8.
- Nagao H, Tanaka T. *Mid-term outcomes of cor triatriatum repair: comparison of biventricular physiology and univentricular physiology*. Cardiol Young 2021;31:186-90.
- Lam CR, Green E, Drake E. *Diagnosis and surgical correction of 2 types of triatrial heart*. Surgery 1962;51:127-37.
- Krabill KA, Lucas RV. *Abnormal pulmonary venous connections*. In: Emmanouilides GC, Riemenschneider TA, Allen HD, Gutgesell HP, editors. *Heart disease in infants, children, and adolescents: including the fetus and young adult*. Baltimore (MD): Williams and Wilkins; 1995. p. 838-74.
- Herlong JR, Jagers JJ, Ungerleider RM. *Congenital Heart Surgery Nomenclature and Database Project: pulmonary venous anomalies*. Ann Thorac Surg 2000;69(4 Suppl):S56-69.
- Augustine DX, Coates-Bradshaw LD, Willis J, et al. *Echocardiographic assessment of pulmonary hypertension: a guideline protocol from the British Society of Echocardiography*. Echo Res Pract 2018; 5:G11-24.
- Naksuk N, Tan N, Padmanabhan D, et al. *Right ventricular dysfunction and long-term risk of sudden cardiac death in patients with and without severe left ventricular dysfunction*. Circ Arrhythm Electrophysiol 2018;11:e006091.

15. Clark TG, Altman DG, De Stavola BL. *Quantification of the completeness of follow-up*. Lancet 2002;359:1309-10.
16. Wu Y, Takkenberg JJ, Grunkemeier GL. *Measuring follow-up completeness*. Ann Thorac Surg 2008;85:1155-7.
17. Gheissari A, Malm JR, Bowman FO Jr, Bierman FZ. *Cor triatriatum sinistrum: one institution's 28-year experience*. Pediatr Cardiol 1992; 13:85-8.
18. Kirklin J, Barratt-Boyes B. *Cor triatriatum*. In: Kouchoukos NT, Blackstone EH, Doty DB, Hanley FL, Karp RB, editors. *Cardiac surgery*. Philadelphia (PA): Churchill Livingstone; 2003. p. 781-9.
19. Takeuchi Y, Kurogane K, Nishimura Y, Kajiura T, Nakata H. *Asymptomatic cor triatrium in an elderly patient: observation by biplanar transesophageal Doppler echocardiography*. Jpn Circ J 1997;61:189-91.
20. Burger C. *A rare case of cor triatriatum leading to respiratory failure and shock in an 8-month-old boy*. Pediatr Emerg Care 2019;35:e6-8.
21. Baek MJ, Kim WH, Na CY, et al. *Cor triatriatum with infracardiac total anomalous pulmonary venous drainage*. Korean J Thorac Cardiovasc Surg 2002;35:52-5.
22. Lee JO, Park CS. *Cor triatriatum associated with total anomalous pulmonary venous connection: a rare but plausible combination*. J Chest Surg 2021;54:143-5.
23. Fuchs MM, Connolly HM, Said SM, Egbe AC. *Outcomes in patients with cor triatriatum sinister*. Congenit Heart Dis 2018;13:628-32.