



# Life-Threatening Intracerebral Hemorrhage in Adult with ITP: Challenging Entity

Batuk Diyora<sup>1</sup> Anup Purandare<sup>1</sup> Kavin Devani<sup>1</sup> Pramod Kale<sup>2</sup> Vikrant Shah<sup>3</sup> Roy Patankar<sup>4</sup>

<sup>1</sup>Department of Neurosurgery, LTMG Hospital, Sion, Mumbai, Maharashtra, India

<sup>2</sup>Department of Anaesthesia, Zen Hospital and Research Center, Chembur, Mumbai, Maharashtra, India

<sup>3</sup>Department of Medicine, Zen Hospital and Research Center, Chembur, Mumbai, Maharashtra, India

<sup>4</sup>Department of Surgery, Zen Hospital and Research Center, Chembur, Mumbai, Maharashtra, India

Address for correspondence Batuk Diyora, DNB, Department of Neurosurgery, LTMG Hospital, Second Floor, College Building, Sion, Mumbai, 400022, India  
(e-mail: bddiyora@gmail.com; batuk73@yahoo.co.in).

AJNS 2023;18:391–395.

## Abstract

Intracerebral hemorrhage (ICH) is a rare and fatal complication of immune thrombocytopenia. ICH is more common in children than in the adult population. A 30-year-old male patient, a known case of immune thrombocytopenia, presented with sudden onset severe headache and vomiting. Computed tomography scan showed a large right frontal intracerebral hematoma. His platelet counts were low, and he received multiple transfusions. Though he was initially conscious, his neurological condition progressively deteriorated, so the decision was taken for an emergency craniotomy. Despite multiple transfusions, his platelet counts were 10,000/ $\mu$ L, so craniotomy was very risky. He underwent an emergency splenectomy and received one unit of single donor platelets. Subsequently, his platelets count increased a few hours after, and he underwent successful evacuation of intracerebral hematoma. He eventually had an excellent neurological outcome. Though intracranial hemorrhage carries significant morbidity and mortality, a timely decision of emergency splenectomy followed by craniotomy can result in an excellent clinical outcome.

## Keywords

- ▶ intra cerebral hemorrhage
- ▶ ITP
- ▶ craniotomy
- ▶ splenectomy

## Introduction

Intracerebral hemorrhage (ICH) is a life-threatening complication of immune thrombolytic purpura (ITP). ITP results in cerebral hemorrhage in only 0.1 to 1% of cases.<sup>1</sup> Spontaneous nontraumatic ICH is uncommon in the adult population compared with the pediatric population.<sup>2</sup> Management of ICH in these patients is highly challenging due to deranged hematology. Also, there is limited literature about managing life-threatening ICH due to ITP, especially in the adult population. In literature search, we found only five adult cases of intracranial hemorrhage in ITP<sup>3–8</sup> (–**Table 1**).

The decision about the emergency craniotomy in a patient with signs and symptoms raised intra-cranial tension (ICT) is often deferred due to very low platelet counts.<sup>2</sup> The availability of modern drugs to improve the platelet count takes time to enhance platelet function before the surgery. In this tricky situation, a timely splenectomy can rapidly improve platelet functions.<sup>9</sup> It can help decide safe and early craniotomy, which can change the overall outcome in these patients. We described a life-threatening spontaneous ICH in an adult patient with chronic ITP who underwent emergency splenectomy followed by craniotomy to evacuate hematoma with an excellent clinical outcome.

article published online  
June 16, 2023

DOI <https://doi.org/10.1055/s-0043-1769891>.  
ISSN 2248-9614.

© 2023. Asian Congress of Neurological Surgeons. All rights reserved.

This is an open access article published by Thieme under the terms of the Creative Commons Attribution-NonDerivative-NonCommercial-License, permitting copying and reproduction so long as the original work is given appropriate credit. Contents may not be used for commercial purposes, or adapted, remixed, transformed or built upon. (<https://creativecommons.org/licenses/by-nc-nd/4.0/>)

Thieme Medical and Scientific Publishers Pvt. Ltd., A-12, 2nd Floor, Sector 2, Noida-201301 UP, India

**Table 1** Registries of patient with ITP who had developed intracerebral hematoma

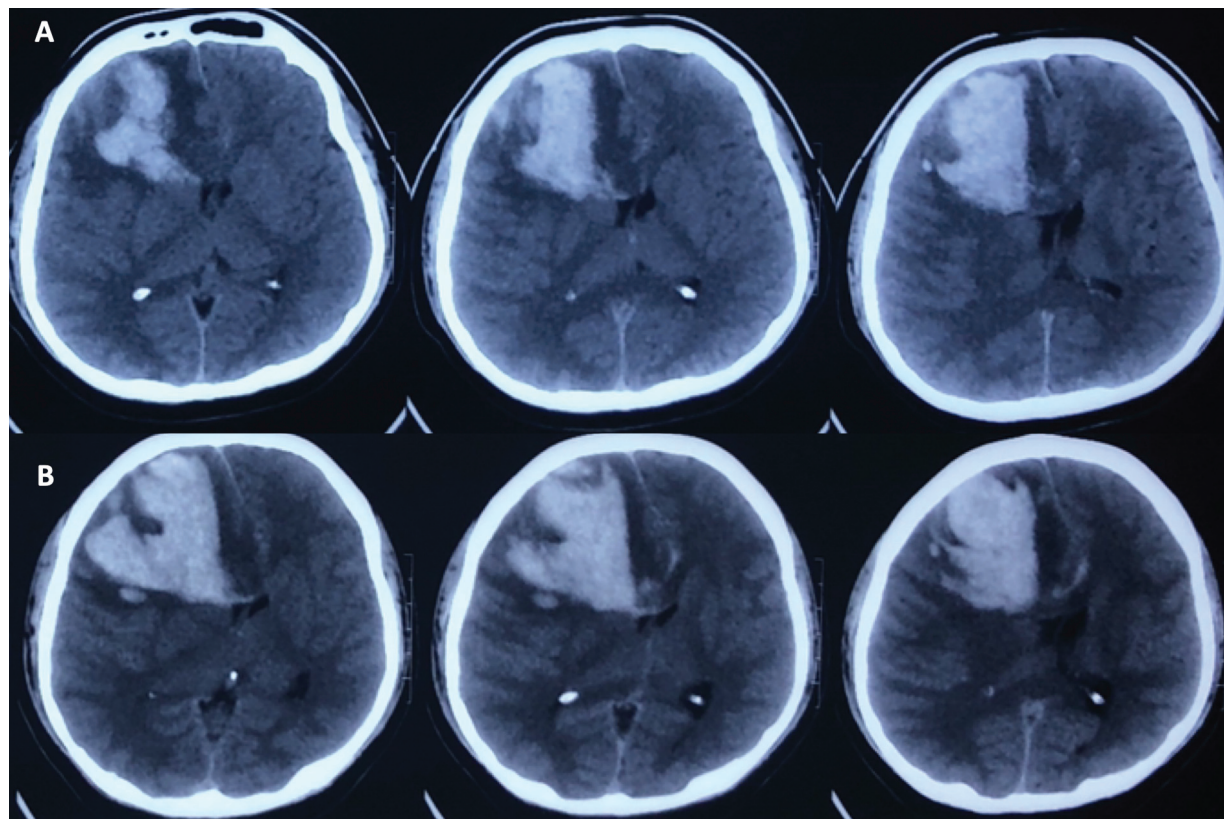
Sr. no.	Author (year)	No. of adult patients	Age/sex	Medical Mx	Splenectomy	Neurosurgical management	Outcome
1	Carpenter et al (1959) <sup>3</sup>	2	Age not specified	Plt/S	No	No	Death
2	Nagler et al (1986) <sup>4</sup>	1	32/M	Plt/S	No	No	Survived
3	Awerbuch and Sandyk (1987) <sup>5</sup>	1	26/F	Plt/S/IVIG	No	No	Survived
4	Brenner et al (1988) <sup>6</sup>	2	25/F 32/M	S/Plt S/Plt	Yes Yes	No No	Death Survived
5	Lee and Kim (1998) <sup>7</sup>	3	28/F 81/F 22/F	Plt/S S Plt/S/IVIG	Yes No Yes	Yes No No	Survived Died Survived
6	Gellens et al(2018) <sup>8</sup>	1	29/M	Plt/R	No	Yes	Survived

Abbreviations: IVIG, intravenous immunoglobins; Plt, platelets; S, splenectomy.

### Case Report

A 30-year-old male patient was brought to emergency medical services (EMS) with a sudden severe headache with vomiting. He was a known case of ITP diagnosed a few years back and was not taking any medication. At the time of arrival to EMS, he was fully conscious and well-oriented to time, place, and person. His pupils were bilaterally 3 mm in size and briskly reacting to the light. His

Glasgow coma scale was 15/15, and his power was an MRC (Medical Research Council) scale of 5/5 in all four limbs. Emergency computed tomography (CT) scan revealed a large right frontal ICH with significant perilesional edema, mass effect, and midline shift of approximately 13 mm (► **Fig. 1A**). Hematological investigation revealed a platelet count of approximately 2,000/ $\mu$ L and a low hemoglobin level. Ultrasonography scan of the abdomen revealed splenomegaly. Because of preserved neurology and abnormal



**Fig. 1** Computed tomography (CT) scan of the brain plain study showing large right frontal intracerebral hematoma with perilesional edema, mass effect, and midline shift (A). Repeat CT scan brain plain study after 36 hours showing increase size of the hematoma, perilesional edema, mass effect and midline shift (B).

hematological parameters, the patient was initially treated conservatively in the form of intravenous antiepileptics, anti-edema measures, diuretics, and steroids. He received one unit of single donor platelets (SDP), and the count increased from 2,000/ $\mu$ L to 3,000/ $\mu$ L. However, after 36 hours of treatment, he became progressively drowsy and developed left-sided weakness. A repeat CT scan brain revealed an increase in perilesional edema, mass effect, and midline shift (**Fig. 1B**). Due to progressive neurological deficit and increased perilesional edema, decompressive surgery was imminent. However, surgery was out of the question because of meager abnormal platelets count of 3,000/ $\mu$ L. After consultation with a physician, hematologist, and general surgeon, the decision was taken about emergency splenectomy. The patient underwent an emergency open splenectomy under general anesthesia with an SDP cover. During surgery, no abnormal bleeding was observed. Six hours later, the platelet count was 85,000/ $\mu$ L, so craniotomy was decided.

He underwent cranial surgery under general anesthesia. The right-extended hemicoronal incision was taken, the scalp flap was elevated, and the left frontoparietal craniotomy was performed. The brain was full and weakly pulsatile. The intracerebral hematoma was evacuated out. The brain became completely lax and nicely pulsatile at the end. Dura closed primarily, the bone flap kept back, and the wound closed in layers.

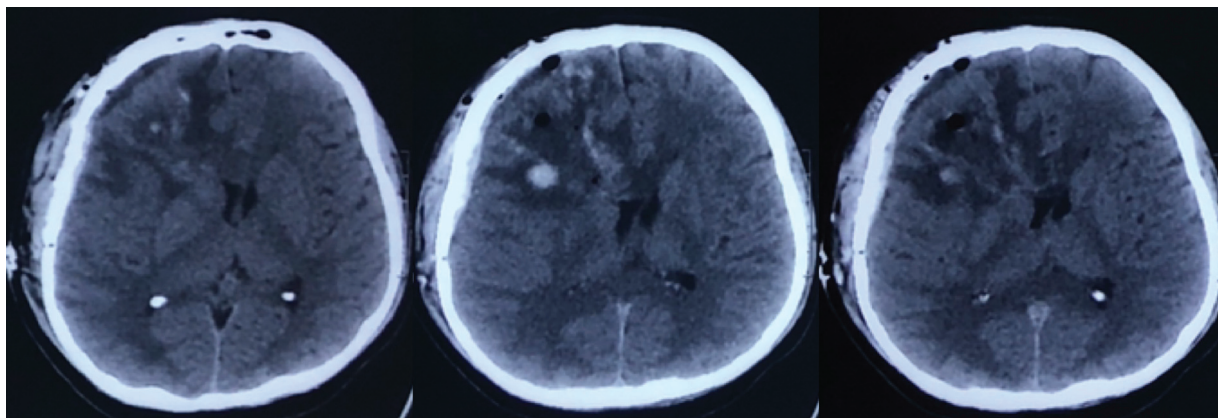
Postoperatively, the patient was extubated after 24 hours. His consciousness improved, and his left limb power improved to an MRC scale of 5/5. On the seventh postoperative day, he was fully conscious and well-oriented to time, place, and person without neurological deficits. His platelet counts progressively increased from 85,000 to 600,000/ $\mu$ L. His repeat CT scan brain revealed significant resolution in the mass effect and midline shift (**Fig. 2**). At 6 months of follow-up, he was neurologically intact.

## Discussion

ITP is an uncommon hematological condition in adults and pediatric age groups. The incidence in adults and children is

approximately 0.2 to 0.4 new cases per 10,000/annum and 0.2 to 0.7 new cases per 10,000/annum, respectively.<sup>9</sup> Thrombocytopenia is defined as a platelet count below the lower limit of normal ( $< 150,000/\mu$ L for adults). Degrees of thrombocytopenia can be further subdivided into mild (platelet count 100,000–150,000/ $\mu$ L), moderate (50,000–99,000/ $\mu$ L), and severe ( $< 50,000/\mu$ L).<sup>10</sup> The acronym ITP stands for “immune thrombocytopenia” and has, by international agreement, replaced the term ITP. It is because ITP is no longer idiopathic. The cause of ITP is an autoimmune reaction against platelets and megakaryocytes.<sup>11,12</sup> The immune response involves different pathogenetic mechanisms. The most common causes include (1) the formation of autoantibodies against platelets and their precursor, megakaryocytes. Autoantibodies binding to the platelet membrane proteins leads to direct damage and promotes the removal of these platelets from circulation by phagocytosis in the liver and spleen.<sup>13–15</sup> (2) Megakaryocyte depletion impairs the production of new platelets in the bone marrow, and relative thrombopoietin deficiency leads to impaired thrombopoiesis.<sup>16–19</sup> (3) Reduced regulatory T lymphocytes lead to immune dysregulation causing direct damage to the platelets.<sup>20</sup>

Based on international consensus again, ITP should only be diagnosed if the platelet counts are repeatedly below 100,000/ $\mu$ L. The therapy and therapeutic goals change with the duration and severity of the disease. Therefore, the traditional distinction of “acute” and “chronic” ITP was abandoned, and a new division into three condition and treatment phases was developed and adopted from the guidelines into newly diagnosed ( $< 3$  months), persistent (3–12 months), and chronic ( $> 12$  months).<sup>21</sup> Treatment of ITP depends on the severity of the bleeding. Numerous bleeding scores have been developed to assess the bleeding severity.<sup>22</sup> The World Health Organization (WHO) bleeding scale or the National Cancer Institute Common Terminology Criteria for Adverse Events (NCI-CTCAE) is often used.<sup>23–25</sup> They are well-established in clinical practice and familiar to most physicians, including nonhematological specialists.



**Fig. 2** Postoperative computed tomographic scan of the brain showing almost near complete evacuation of the hematoma with operative changes.



ICH is a fatal complication of this pathology. Spontaneous nontraumatic ICH is uncommon in the adult population compared with the pediatric population. Due to deranged hematology, managing ICH in these patients is highly challenging. The severity of bleeding in adults should be graded according to the NCI-CTCAE and classified into four grades.<sup>9</sup> Our patient had grade 4 severity of bleed, which was life-threatening, so surgical intervention was considered. There is a clear indication for splenectomy for all patients with persistent or chronic thrombocytopenia and severe bleeding (WHO III, IV) who do not respond sufficiently to all other treatment modalities. In emergencies (e.g., life-threatening bleeding that does not respond to steroids and intravenous immunoglobulins), splenectomy is even the therapy of choice because treatment with thrombopoietin receptor agonist (TRAs) or rituximab is not immediately effective but needs some time to increase the platelet counts and stop the bleeding (often > 1 week). There is no compelling indication for splenectomy.<sup>26,27</sup> Neurosurgical intervention in ITP is usually craniotomy with evacuation of the bleed. It is usually warranted when the patient's platelet counts are greater than 70,000/ $\mu\text{L}$ .<sup>9</sup> Also, other factors that should be considered are hemorrhage in an accessible location for evacuation, level of consciousness deterioration, and new-onset neurological deficit.<sup>5</sup>

Very few adult cases of ITP with ICH have been reported in the literature, as it is more common in children. Carpenter et al<sup>3</sup> reported the first case of this kind in 1959, where the patient was treated with platelets and splenectomy. However, no neurosurgical intervention resulted in the patient's death. Later in 1998, a case report published by Lee and Kim.<sup>7</sup> showed that neurosurgical intervention was done after splenectomy when the platelets increased and the patient survived. A recent case report by Gellens et al<sup>8</sup> in 2018 mentions splenectomy and drug romiplostim as a second-line measure for rapid increase in platelets prior to neurosurgical intervention. In our case report, the patient underwent craniotomy and bleed evacuation after splenectomy after his platelets count improved.

The presence of an intracranial hemorrhage in ITP has devastating mortality rates, with estimations of 25 to 55%.<sup>28</sup> It was a challenging neurosurgical and hematological case. It required the combined efforts and decision-making of neurosurgeons, hematologists, physicians, and anesthetists. Due to active efforts from a multidisciplinary team, the patient recovered completely without any neurological deficit.

The spleen derived autoantibodies bind with antigen, primarily gpIIb/IIIa and gp1b/IX on the surface of the platelets. Fc $\gamma$ R expressing splenic macrophages internalize antibody-coated platelets, degrade them, and present them to autoreactive CD4 + T cells. These activated cells interact with B cells through the CD40/CD40L interaction leading to somatic hypermutation and class switching. Auto reactive B cells then differentiate into antiplatelets antibody producing plasma cells that either stay in the spleen or migrate to the blood and bone marrow. Megakaryocytes in the bone marrow express platelets glycoprotein such as gpIIb/IIIa and gp1b/IX and autoantibodies against these antigens impair platelet production and contribute megakaryocytes apopto-

sis that leads to thrombocytopenia. Thus, splenectomy immediately halts destruction of platelets and production of plasma cells results in improved platelets counts.<sup>29</sup>

## Conclusion

ICH is a devastating complication of ITP, both in adults and children. Management of such cases is equally challenging. It carries significant morbidity and mortality. In a life-threatening situation, a timely decision of emergency splenectomy followed by craniotomy can result in an excellent clinical outcome. Our case advocates the importance of a multidisciplinary team approach and aggressive decision-making in a clinical scenario.

### Note

This work should be attributed to L.T.M. Medical College and Sion General hospital, Mumbai, India.

### Funding

None.

### Conflict of Interest

None declared.

## References

- Jordan LC, Hillis AE. Hemorrhagic stroke in children. *Pediatr Neurol* 2007;36(02):73–80
- Calderon C, Perez A. Immune thrombocytopenic purpura and intracranial haemorrhage a formidable medical challenge. *Open Access Journal of Neurology & Neurosurgery*. 2020;14(02):28–31
- Carpenter AF, Wintrobe MM, Fuller EA, Haut A, Cartwright GE. Treatment of idiopathic thrombocytopenic purpura. *J Am Med Assoc* 1959;171(14):1911–1916
- Nagler A, Brenner B, Hayek T, Brook JG. Subdural hemorrhage in a 32-year-old man with chronic idiopathic thrombocytopenic purpura. *Acta Haematol* 1986;75(03):186–187
- Awerbuch G, Sandyk R. Intracranial haemorrhage in a 26 year-old woman with idiopathic thrombocytopenic purpura. *Postgrad Med J* 1987;63(743):781–783
- Brenner B, Guilburd JN, Tatarsky I, Doron Y, Goldsher D. Spontaneous intracranial hemorrhage in immune thrombocytopenic purpura. *Neurosurgery* 1988;22(04):761–764
- Lee MS, Kim WC. Intracranial hemorrhage associated with idiopathic thrombocytopenic purpura: report of seven patients and a meta-analysis. *Neurology* 1998;50(04):1160–1163
- Gellens R, Habchi S, Freppel S, Couret D, Iacobelli S. Romiplostim for the emergency management of severe immune thrombocytopenia with intracerebral hemorrhage. *Front Neurol* 2018; 8:737
- Matzdorff A, Meyer O, Ostermann H, et al. Immune thrombocytopenia - current diagnostics and therapy: recommendations of a joint working group of DGHO, ÖGHO, SGH, GPOH, and DGTI. *Oncol Res Treat* 2018;41(Suppl 5):1–30
- Williamson DR, Albert M, Heels-Ansdell D, et al; PROTECT collaborators, the Canadian Critical Care Trials Group, and the Australian and New Zealand Intensive Care Society Clinical Trials Group. Thrombocytopenia in critically ill patients receiving thromboprophylaxis: frequency, risk factors, and outcomes. *Chest* 2013;144(04):1207–1215
- Cines DB, Bussel JB, Liebman HA, Luning Prak ET. The ITP syndrome: pathogenic and clinical diversity. *Blood* 2009;113(26): 6511–6521

- 12 Cines DB, Blanchette VS. Immune thrombocytopenic purpura. *N Engl J Med* 2002;346(13):995–1008
- 13 Cines DB, Cuker A, Semple JW. Pathogenesis of immune thrombocytopenia. *Presse Med* 2014;43(4 Pt 2):e49–e59
- 14 Zufferey A, Kapur R, Semple JW. Pathogenesis and therapeutic mechanisms in immune thrombocytopenia (ITP). *J Clin Med* 2017;6(02):16
- 15 Harrington WJ, Minnich V, Hollingsworth JW, Moore CV. Demonstration of a thrombocytopenic factor in the blood of patients with thrombocytopenic purpura. *J Lab Clin Med* 1951;38(01):1–10
- 16 Grozovsky R, Begonja AJ, Liu K, et al. The Ashwell-Morell receptor regulates hepatic thrombopoietin production via JAK2-STAT3 signaling. *Nat Med* 2015;21(01):47–54
- 17 Grozovsky R, Giannini S, Falet H, Hoffmeister KM. Regulating billions of blood platelets: glycans and beyond. *Blood* 2015;126(16):1877–1884
- 18 Emmons RV, Reid DM, Cohen RL, et al. Human thrombopoietin levels are high when thrombocytopenia is due to megakaryocyte deficiency and low when due to increased platelet destruction. *Blood* 1996;87(10):4068–4071
- 19 Fielder PJ, Gurney AL, Stefanich E, et al. Regulation of thrombopoietin levels by c-mpl-mediated binding to platelets. *Blood* 1996;87(06):2154–2161
- 20 Olsson B, Andersson PO, Jernås M, et al. T-cell-mediated cytotoxicity toward platelets in chronic idiopathic thrombocytopenic purpura. *Nat Med* 2003;9(09):1123–1124
- 21 Rodeghiero F, Stasi R, Gernsheimer T, et al. Standardization of terminology, definitions and outcome criteria in immune thrombocytopenic purpura of adults and children: report from an international working group. *Blood* 2009;113(11):2386–2393
- 22 Rodeghiero F, Michel M, Gernsheimer T, et al. Standardization of bleeding assessment in immune thrombocytopenia: report from the International Working Group. *Blood* 2013;121(14):2596–2606
- 23 Miller AB, Hoogstraten B, Staquet M, Winkler A. Reporting results of cancer treatment. *Cancer* 1981;47(01):207–214
- 24 Heddle NM, Cook RJ, Tinmouth A, et al; SToP Study Investigators of the BEST Collaborative. A randomized controlled trial comparing standard- and low-dose strategies for transfusion of platelets (SToP) to patients with thrombocytopenia. *Blood* 2009;113(07):1564–1573
- 25 National Cancer Institute. NCI Common Terminology Criteria for Adverse Events CTCAE. v4.03; 2010
- 26 Rodeghiero F, Ruggeri M. Short- and long-term risks of splenectomy for benign haematological disorders: should we revisit the indications? *Br J Haematol* 2012;158(01):16–29
- 27 Kojouri K, Vesely SK, Terrell DR, George JN. Splenectomy for adult patients with idiopathic thrombocytopenic purpura: a systematic review to assess long-term platelet count responses, prediction of response, and surgical complications. *Blood* 2004;104(09):2623–2634
- 28 Psaila B, Petrovic A, Page LK, Menell J, Schonholz M, Bussel JB. Intracranial hemorrhage (ICH) in children with immune thrombocytopenia (ITP): study of 40 cases. *Blood* 2009;114(23):4777–4783
- 29 Chaturvedi S, Arnold DM, McCrae KR. Splenectomy for immune thrombocytopenia: down but not out. *Blood* 2018;131(11):1172–1182