

# Left renal vein aneurysm in a young woman with renal nutcracker syndrome

Andrew Lazar, MD,<sup>a</sup> Kevin Kniery, MD,<sup>b</sup> and Nicholas Morrissey, MD,<sup>a</sup> New York, NY

## ABSTRACT

A 17-year-old girl presented to our institution with abdominal and pelvic pain found to be due to extrinsic compression of the left renal vein, causing a saccular aneurysm and renal vein dilation with varices consistent with nutcracker syndrome. She was managed with an open aneurysm resection and transposition of the left renal vein. (*J Vasc Surg Cases and Innovative Techniques* 2019;5:580-2.)

**Keywords:** Nutcracker syndrome; Renal vein aneurysm; Vascular anomalies; Renal vein transposition

## CASE REPORT

A 17-year-old girl with no medical problems was referred to the vascular surgery service after the finding of a left renal vein aneurysm in the setting of nutcracker syndrome (NCS). She initially presented to her pediatrician with vague lower abdominal and pelvic pain and was started on oral contraceptives (OCPs). In addition, her workup included abdominal duplex ultrasound and computed tomography (CT) scan, which demonstrated a left renal vein crossing anterior to the aorta that was noted to have extrinsic compression between the aorta and superior mesenteric artery (SMA; *Figs 1-3*). In addition, a saccular aneurysm measuring 2.2 × 1.9 × 2.7 cm was noted on the inferior portion of the left renal vein. She was prescribed OCPs with improvement in symptoms, and she noted no abdominal pain with food consumption or food fear, nausea, or vomiting. On urinalysis, she did not have hematuria or proteinuria. Follow-up venography performed to further evaluate drainage of the left renal and pelvic venous systems confirmed extrinsic compression of the left renal vein and a saccular aneurysm (*Fig 4*). A pressure gradient of 8 mm Hg was noted between the distal left renal vein and inferior vena cava (IVC).

Although her symptoms improved with medication, the aneurysm caused concern for future embolization to the systemic venous circulation as seen in two other reported renal vein aneurysms.<sup>1,2</sup> For this reason, she underwent exploratory laparotomy with complete resection of the left renal vein aneurysm. Before resection, the left renal and pelvic venous systems were noted to rapidly decompress when the bowel and mesentery were

lifted off them. The left adrenal and gonadal veins were divided and the distal IVC was mobilized. The left renal vein was transposed onto the IVC distal to its initial origin as similarly described by Reed et al.<sup>3</sup> Vascular Doppler ultrasound noted excellent flow after reconstruction. The specimen was sent for pathologic examination and demonstrated an aneurysm and varix. Postoperatively, the patient did well; she was monitored in the surgical intensive care unit overnight and then transferred to the pediatric floor. She was discharged on postoperative day 4 with minimal incisional pain. She has been observed with duplex ultrasound examination demonstrating no evidence of thrombosis or compression of the left renal vein or IVC at 4 months and 18 months postoperatively. Her symptoms have resolved, she has subsequently stopped her OCPs, and she is doing well. The patient consented to publication of all case details and images in this case report.

## DISCUSSION

NCS is a rare condition associated with nutcracker phenomenon (NCP), external compression of the left renal vein between the aorta and SMA. It was first reported clinically by El-Sadr and Mina.<sup>4</sup> NCP has been reported to occur when the left renal vein passes anterior or posterior to the aorta. Anterior NCP is primarily believed to be due to venous anatomic anomalies or an abnormally sharp angle of the SMA over the duodenum and left renal vein.<sup>5</sup> Posterior NCS is often caused by compression of the left renal vein between the aorta and the vertebral column.<sup>3,5</sup> Compression of the left renal vein is the predominant cause of symptoms and sequelae related to NCS, leading to development of dilation of the left renal vein and associated vessels. This can lead to renal varices causing flank or abdominal pain as well as hematuria.<sup>3</sup> NCS most commonly affects women over men and predominantly in the third decade of life, although the exact incidence is not known.<sup>6,7</sup> NCS is most commonly diagnosed by abdominal duplex ultrasound, CT angiography, or magnetic resonance angiography. Additional clinical data can be gathered with cystoscopy and angiography with phlebography and manometry. Specifically, the pressure gradient between the left renal vein and IVC

---

From the Division of Vascular Surgery, Columbia University Medical Center<sup>a</sup>, and the Division of Vascular Surgery, NewYork-Presbyterian Hospital.<sup>b</sup>

Author conflict of interest: none.

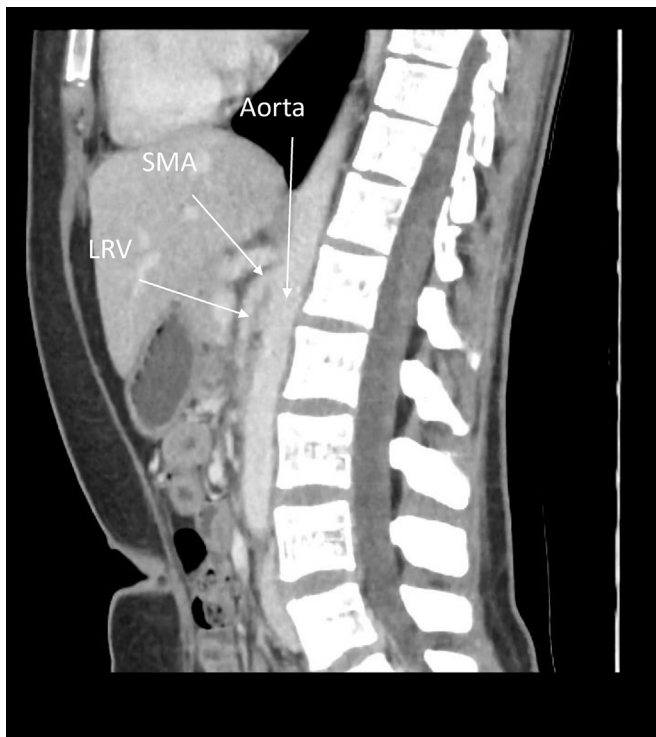
Correspondence: Andrew Lazar, MD, Division of Vascular Surgery, Columbia University Medical Center, 161 Fort Washington Ave, Rm 538, New York, NY 10032 (e-mail: [al4020@cumc.columbia.edu](mailto:al4020@cumc.columbia.edu)).

The editors and reviewers of this article have no relevant financial relationships to disclose per the Journal policy that requires reviewers to decline review of any manuscript for which they may have a conflict of interest.

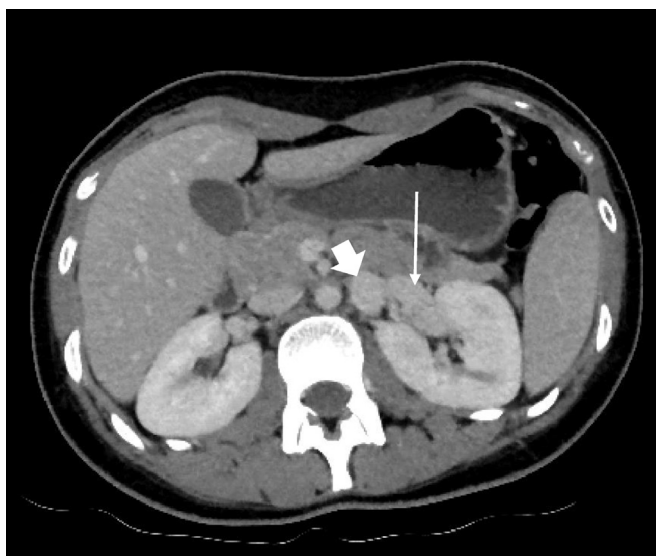
2468-4287

© 2019 The Authors. Published by Elsevier Inc. on behalf of Society for Vascular Surgery. This is an open access article under the CC BY-NC-ND license (<http://creativecommons.org/licenses/by-nc-nd/4.0/>).

<https://doi.org/10.1016/j.jvscit.2019.10.001>

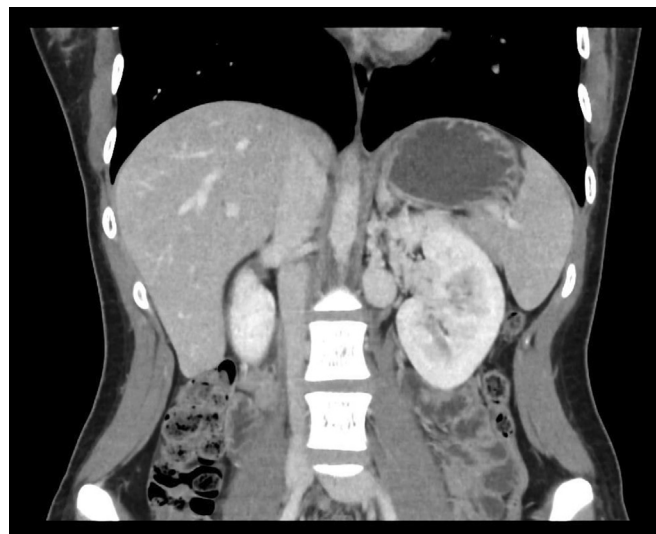

**Fig 1.** Preoperative computed tomography (CT) angiogram demonstrating extrinsic compression of the left renal vein (LRV) between the aorta and superior mesenteric artery (SMA).



**Fig 2.** Saccular aneurysm (arrowhead) noted on preoperative computed tomography (CT) angiogram measuring  $2.2 \times 2.2$  cm. The arrow indicates the left renal vein.

can be measured and is normally  $<1$  mm Hg.<sup>5,7,8</sup> In this specific case, a gradient of 8 mm Hg was noted. This represents a relatively high gradient greater than values reported in other published case series; one series noted a maximum of 6 mm Hg.<sup>3</sup> This potentially identifies the



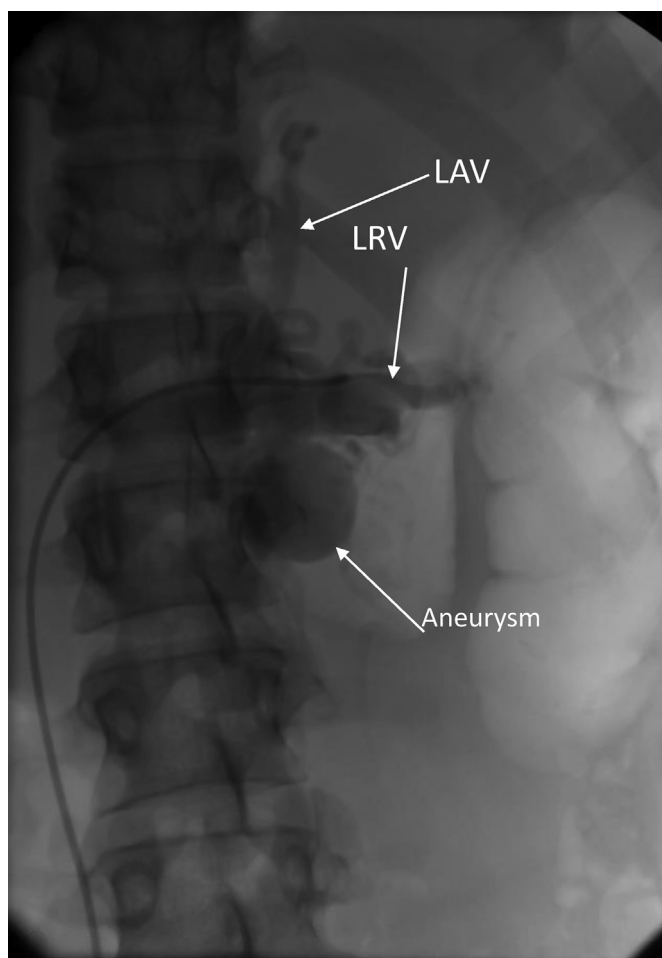
**Fig 3.** Coronal view of preoperative computed tomography (CT) angiogram demonstrating saccular aneurysm.

underlying mechanism of the saccular aneurysm noted in our adolescent patient.

Renal vein aneurysms are a rare phenomenon with few cases reported. Traditionally, these cases are incidentally found on imaging obtained for other clinical reasons and are usually congenital in nature.<sup>9</sup> For this reason, the left renal vein is more commonly involved as it has a more complex embryologic development.<sup>10</sup> Although NCS is associated with dilation of the renal pelvis and surrounding venous structures causing varices, to our knowledge, there has been only one other documented case of a distinct saccular left renal vein aneurysm in the setting of NCS.<sup>11</sup> Although the few renal vein aneurysm cases published often observed these patients, we thought that although the patient's symptoms improved with OCPs, there was an increased risk for embolization to the venous system and pulmonary vasculature as previously described.<sup>1,2</sup> We believed that as the patient's body position varied throughout the day, moving to prone or leaning forward, the small bowel and mesentery would relax on the retroperitoneum and allow thrombus in the aneurysm sac to embolize to the lungs.

Although treatment is more widely known for symptomatic NCS, less is known about renal vein aneurysms. In this case, we used an open surgical approach with excision of the aneurysm and left renal vein transposition with ligation of the left adrenal and gonadal veins.<sup>3</sup> Another method of treatment described is an endovascular approach that predominantly relies on placement of stents to rectify the extrinsic compression of the left renal vein. In suitable patients, embolization and exclusion have been described.<sup>11</sup>

Although NCS has been well described, there has been only one other reported case to our knowledge noting a saccular aneurysm of the left renal vein in the setting of



**Fig 4.** Visceral angiogram with cannulation of the left renal vein (*LRV*) demonstrating large *aneurysm* and corkscrew nature of left adrenal vein (*LAV*).

NCS. In combination with the young age of our patient and the significantly elevated gradient pressure, these factors make for a unique example of a renal vein aneurysm and NCS.

## CONCLUSIONS

Renal vein aneurysms and NCS are both rare anatomic findings normally, but the combination is unique. Renal vein aneurysms are often found incidentally, whereas NCS can also be asymptomatic or manifested with

chronic flank, lower abdominal, or pelvic pain. Diagnosis can be made by combining imaging (CT angiography, magnetic resonance angiography, or duplex ultrasound) with exclusion of other diagnoses. Treatment of NCS includes open or endovascular techniques that are usually tolerated well by patients. Renal vein aneurysms have been reported only a few times previously and have usually been observed. We present a unique case of a young adolescent with high renocaval pressure gradients and a 2.7-cm left renal vein aneurysm in the setting of anterior NCS. In addition, we make an argument for surgical intervention to prevent the risk of systemic and pulmonary thromboemboli.

## REFERENCES

1. Rios A, Parsa P, Eidt J, Pearl G. A novel surgical approach to symptomatic left renal vein aneurysm. *J Vasc Surg Venous Lymphat Disord* 2017;5:875-7.
2. Özyüksel A, Aktaş S, Çalis E, Erol C, Sevmiş Ş. Ex vivo resection and renal autotransplantation for the treatment of a large renal vein aneurysm causing recurrent pulmonary embolism and a coexisting vascular malformation: a case report. *Vasc Endovascular Surg* 2016;50:415-20.
3. Reed NR, Kalra M, Bower TC, Vrtiska TJ, Ricotta JJ, Gloviczki P. Left renal vein transposition for nutcracker syndrome. *J Vasc Surg* 2009;49:386-93.
4. El-Sadr AR, Mina E. Anatomical and surgical aspects in the operative management of varicocele. *Urol Cutaneous Rev* 1950;54:257-62.
5. Ahmed K, Sampath R, Khan MS. Current trends in the diagnosis and management of renal nutcracker syndrome: a review. *Eur J Vasc Endovasc Surg* 2006;31:410-6.
6. Kurklinsky AK, Rooke TW. Nutcracker phenomenon and nutcracker syndrome. *Mayo Clin Proc* 2010;85:552-9.
7. He Y, Wu Z, Chen S, Tian L, Li D, Li M, et al. Nutcracker syndrome—how well do we know it? *Urology* 2014;83:12-7.
8. Velasquez CA, Saeyeldin A, Zafar MA, Brownstein AJ, Erben Y. A systematic review on management of nutcracker syndrome. *J Vasc Surg Venous Lymphat Disord* 2018;6:271-8.
9. Kabaalioglu A, Yilmaz S, Apaydin A, Sindel T, Ozkaynak C, Lülecı E. Renal vein aneurysm: diagnosis with color Doppler sonography. *AJR Am J Roentgenol* 1997;168:645-6.
10. Yoneyama T, Baba Y, Fujiyoshi F, Hokotate H, Inoue H, Nakajo M. Left renal vein aneurysm: imaging findings. *Abdom Imaging* 2003;28:233-5.
11. Tan AP, Chua BS, Lim KB, Taneja M. Unusual clinical presentation of nutcracker phenomenon. *Ann Acad Med Singapore* 2017;46:470-1.

Submitted Aug 13, 2019; accepted Oct 13, 2019.