

Received: 2016.11.07  
Accepted: 2017.05.31  
Published: 2017.09.07

ISSN 1941-5923  
© Am J Case Rep, 2017; 18: 963-971  
DOI: 10.12659/AJCR.902271

## Biventricular Cardiac Hypertrophy in a Patient with Primary Aldosteronism and Atrial Septal Defect

Authors' Contribution:  
Study Design A  
Data Collection B  
Statistical Analysis C  
Data Interpretation D  
Manuscript Preparation E  
Literature Search F  
Funds Collection G

ABCDEG 1 **Tjokorda Gde Dalem Pemayun**  
ABCEFG 2 **Ridho M. Naibaho**  
BCD 3 **Muhammad Achmad Sungkar**

1 Subdivision of Endocrinology, Metabolism and Diabetes, Department of Medicine, Medical Faculty of Diponegoro University and Dr. Kariadi General Hospital, Semarang, Indonesia  
2 Department of Medicine, Medical Faculty of Diponegoro University and Dr. Kariadi General Hospital, Semarang, Indonesia  
3 Subdivision of Cardiovascular Medicine, Department of Medicine, Medical Faculty of Diponegoro University and Dr. Kariadi General Hospital, Semarang, Indonesia

**Corresponding Author:** Tjokorda Gde Dalem Pemayun, e-mail: [tjokdalem\\_smg@yahoo.com](mailto:tjokdalem_smg@yahoo.com)  
**Conflict of interest:** None declared

**Patient:** Female, 33  
**Final Diagnosis:** Primary aldosteronism • heart failure • atrial septal defect • biventricular cardiac hypertrophy  
**Symptoms:** Dyspneu • muscular weakness  
**Medication:** Spironolactone • ACE inhibitor  
**Clinical Procedure:** Captopril suppression test • adrenalectomy • right cardiac catheterization  
**Specialty:** Endocrinology and Metabolism • Cardiology


**Objective:** Rare co-existence of disease or pathology  
**Background:** Primary aldosteronism can be caused by adrenocortical adenoma and is usually associated with left ventricular hypertrophy. Biventricular cardiac hypertrophy and heart failure in the presence of a pre-existing atrial septal defect (ASD) are a rare association of primary aldosteronism.

**Case Report:** A 33-year-old woman with resistant hypertension and refractory hypokalemia presented with signs and symptoms of heart failure. She had previously been diagnosed having a right adrenal tumor and ostium secundum type ASD. Transthoracic echocardiography confirmed the location of the ASD, with a left-to-right cardiac shunt, moderate to severe tricuspid insufficiency, moderate pulmonary hypertension (60 mm Hg), four chamber dilatation and biventricular hypertrophy. The left ventricular ejection fraction was 17%. Endocrine function tests showed a raised plasma aldosterone concentration (PAC) to plasma renin activity (PRA) ratio, which supported a diagnosis of primary aldosteronism. A captopril suppression test failed to suppress the patient's PAC, which confirmed the diagnosis. The patient underwent a right adrenalectomy with subsequent normalization of hypokalemia, PAC, and PAC to PRA ratio and her hypertension was managed successfully with monotherapy. Surgical pathology examination of the tumor revealed an adrenocortical adenoma. At follow-up at 18 months, the patient had a normal potassium level, and her cardiac function and ventricular geometries were improved.

**Conclusions:** Reversible cardiac hypertrophy is rarely associated with primary aldosteronism, however, it should be recognized. Present findings suggest that aldosteronism contributes to cardiac remodelling and biventricular hypertrophic changes. Administering appropriate treatment in a timely manner, can reverse cardiac changes along with the other symptoms of primary aldosteronism.

**MeSH Keywords:** Adrenalectomy • Heart Failure • Hyperaldosteronism • Hypertrophy, Left Ventricular • Hypertrophy, Right Ventricular • Heart Septal Defects, Atrial

**Full-text PDF:** <https://www.amjcaserep.com/abstract/index/idArt/902271>

 2542

 2

 4

 18



## Background

Primary aldosteronism is defined as the autonomic aldosterone secretion from the glomerulosa zone of adrenal cortex, making an inappropriately high level of the hormone regardless of renin-angiotensin system and physiological requirements [1]. Primary aldosteronism is usually caused by the presence of aldosterone-producing adrenocortical adenoma (Conn's adenoma) or adrenal hyperplasia [2]. Health consequences of this adrenal syndrome are partly mediated by long-standing hypertension and refractory hypokalemia [2,3]. The other issue is related to the cardiac effects of aldosterone related to its receptor expression, i.e. mineralocorticoid receptor (MR), in cardiomyocytes and cardiac fibroblasts [4]. Their potential exposure to high circulating aldosterone leads to cardiac hypertrophy, myocardial fibrosis and endothelial dysfunction that is unrelated to blood pressure elevation. These emphasize the concept that excess activation of MR, rather than aldosteronism itself, is the key to increasing adverse outcomes whenever aldosterone secretion is overtly enhanced [5].

Cardiac involvement in primary aldosteronism is well documented, mostly in the form of left ventricular (LV) hypertrophy and diastolic dysfunction [6] while right ventricular (RV) abnormalities has not been revealed [7]. Herein we describe the case of a patient with primary aldosteronism due to Conn's adenoma who presented with biventricular cardiac hypertrophy, which reverses upon aldosterone normalization following adrenalectomy. The fact that the patient also exhibited ostium secundum-type atrial septal defect (ASD) made this case unique and provided interesting information regarding pathophysiologic role of aldosterone in cardiac sequelae, including its effect on the RV. We present this case to highlight the salient point of the biventricular manifestation of cardiac changes in patient with primary aldosteronism.

## Case Report

### Presentation, history, and physical examination on hospital admission

In March 2014, a 33-year-old Javanese woman presented with dyspnea and palpitations at rest and during the night. The patient denied any recent weight gain, peripheral edema, headache, chest pain, fever, or any other constitutional symptoms. She had suffered from hypertension since the age of 20 years, which had been treated intermittently.

On physical examination, she had dyspnea at rest, was alert, but anxious, and her blood pressure was 170/115 mmHg, with a heart rate of 112 beats per minute, and labored respiration at 32 breaths per minute. During her latest hospitalization, peaks of systolic blood pressure were noted of up to 210

mmHg, with elevated jugular venous pressure. Cardiac examination showed both LV and RV enlargement. Cardiac auscultation detected a fixed split S2 with a loud component and a grade 3/6 ejection systolic murmur which was audible at the upper left sternal border and a diastolic gallop that could be heard at the cardiac apex. The patient had bilateral fine crepitation in the lower zones of the lungs. Abdominal examination showed no organomegaly, no palpable mass, and no abdominal bruits. Neurological examination of the lower limbs showed muscular weakness in both legs with a reduced motor power of 3–4/5. The lower limbs showed symmetric palpable pulses, no pedal edema, and no muscular atrophy.

### Past medical history and previous investigations

In 2002, she had been diagnosed by echocardiography as having an ostium secundum ASD. Hypokalemia was first documented at a regional hospital in 2007 when she suffered from pre-eclampsia during pregnancy. She had been treated with potassium supplements and several antihypertension medications. However, neither satisfactory blood pressure control nor normal serum potassium levels were achieved during follow-up, and the patient began to complain of increasing weakness. The patient reported that among members of her family, only her mother had suffered from hypertension.

In 2008, the patient had initially sought a specialist endocrine consultation at our hospital when her hypokalemia resulted in disabling generalized muscle weakness and intense muscle cramps. On her admission in 2008, the following studies were performed, which confirmed a diagnosis of primary aldosteronism. The supine morning plasma aldosterone concentration (PAC) and plasma renin activity (PRA) were 56 ng/mL ( $N \leq 15$  ng/mL) and 0.13 ng/mL/hour ( $N = 0.5-3.3$  ng/mL/hour), respectively. The PAC to PRA ratio was calculated as 430.7 ng/dL per ng/mL/hour ( $N \leq 30$  ng/dL per ng/mL/hour) (Table 1). Ultrasound of the abdomen showed a mass (3.4×2.3×2.1 cm) in the right suprarenal area that was confirmed with computed tomography (CT) to be an adrenal tumor. The patient had been referred for adrenalectomy, but she initially declined surgery and preferred to remain on medication. She was discharged home with a blood pressure of 145/90 mmHg and a serum potassium level of 3.2 mmol/L with the medications that included spironolactone, captopril, amlodipine, bisoprolol, and potassium chloride tablets. The patient became lost to follow-up for six years, until March 2014. During the period between 2008 to 2014, she was admitted twice to two separate hospitals for episodes of heart failure.

### Investigations on current hospital admission

On admission of the patient to our hospital in March 2014, preliminary laboratory investigations showed severe hypokalemia

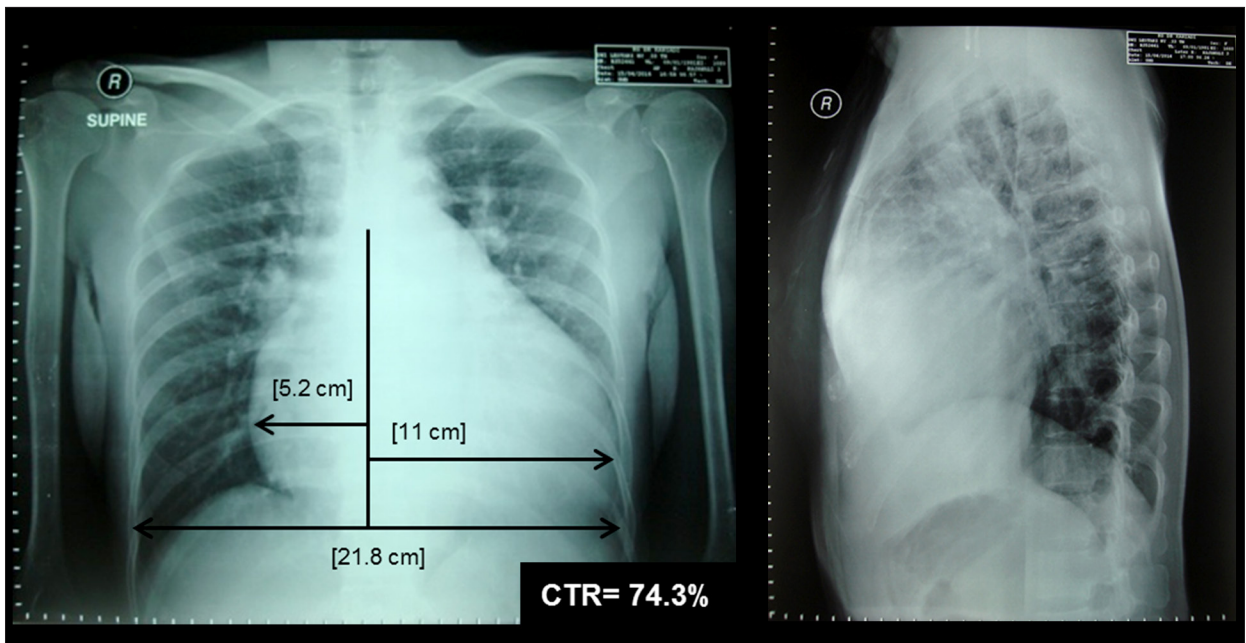
**Table 1.** Laboratory data and blood gas analysis.

	Results			Normal value
	Pre-operative	Post-Captopril test	Post-adrenalectomy	
<b>Laboratory examination</b>				
Hemoglobin, gr/dL	12.0	ND	11.6	12–15
Hematocrit, %	36.6	ND	34.5	35–37
Leukocyte, $\times 10^3/\text{mm}^3$	7.2	ND	8.4	5.0–10.0
Random blood glucose, mg/dL	104	ND	117	<200
Creatinine, mg/dL	0.98	ND	0.76	0.5–1.5
Sodium, mMol/L	143	ND	140	135–145
Potassium, mMol/L	2.2	ND	4.1	3.5–5.5
Calcium, mMol/L	2.1	ND	2.3	2.1–2.5
Magnesium, mMol/L	0.87	ND	0.85	0.74–0.99
CPK, U/L	1,257	ND	52	29–200
CKMB, U/L	221	ND	14	<15
Urinary sodium excretion, mMol/24 hours	167	ND	ND	40–220
Urinary potassium excretion, mMol/24 hours	43	ND	ND	<30
<b>Blood gas analysis</b>				
pH	7.57	ND	7.35	7.35–7.45
FiO <sub>2</sub> , %	32	ND	21	
PO <sub>2</sub> , mmHg	112	ND	97	83–108
PCO <sub>2</sub> , mmHg	33	ND	33	35–45
HCO <sub>3</sub> , mMol/L	34.1	ND	18.2	18–23
Base excess	+11.6	ND	-2.4	$\pm 2.5$
O <sub>2</sub> saturation, %	99	ND	99	95–100
<b>Endocrine evaluation</b>				
PAC, ng/mL (supine)	56	47	8.2	<15 <sup>a</sup>
PRA, ng/mL/hour	0.13	0.09	0.27	0.5–3.3 <sup>a</sup>
PAC-to-PRA ratio, ng/dL per ng/mL/hour	430.7	522.2	30.4	<30 <sup>a</sup>
24-hour urine free cortisol, nMol/day	13.8	ND	ND	11.2–80.3 <sup>b</sup>
Cortisol level after 1 mg DST, $\mu\text{g}/\text{dL}$ (8 A.M.)	17.6	ND	ND	5–25 <sup>b</sup>
24-hour urine VMA, mg/day	3.6	ND	ND	<11 <sup>b</sup>

CPK – creatine phosphokinase; CKMB – creatine-kinase isoenzyme-myocardial band; PAC – plasma aldosterone concentration; DST – dexamethasone suppression test; PRA – plasma renin activity; ND – not determined; VMA – vanilylmandelic acid. From reference: <sup>a</sup> Funder JW, et al. (J Clin Endocrinol Metab 2008); <sup>b</sup> Petersenn S, et al. (Ann NY Acad Sci 2006).

(2.2 mmol/L) which was refractory (range, 1.9–2.6 mmol/L) even with repeated potassium supplementation. Urinary potassium excretion was 43 mmol/24 h indicating a renal loss

of potassium. The serum magnesium level was normal, while the sodium concentrations were in the high normal limit (143 mmol/L). Serum creatine phosphokinase (CPK) was



**Figure 1.** Chest radiographs before surgery. Posterior-anterior (PA) and lateral chest X-radiograph showing an enlarged cardiac silhouette, with left ventricle (LV), left atrium (LA), right ventricle (RV), and right atrium (RA) enlargement and a cardiothoracic ratio > 55%.

elevated at 1,257 IU/L, and creatine kinase isoenzyme myocardial band (CKMB) was 221 IU/L. Arterial blood gas analysis showed metabolic alkalosis and ventilation-perfusion mismatch secondary to pulmonary edema. Renal function tests showed normal serum urea and creatinine. Urinalysis showed no proteinuria or myoglobinuria.

Chest X-ray showed cardiomegaly, with a cardiothoracic ratio of 74.3% (Figure 1), and right atrial (RA) and RV enlargement with pulmonary edema. The electrocardiogram (ECG) showed sinus tachycardia with a ventricular rate of 112 beats per minute, left axis deviation, LV hypertrophy with strain, and alteration in ventricular repolarization consistent with hypokalemia with nonspecific ST-T segment depression, and flattened T wave with a prominent U wave. Serum potassium level was 2.1 mmol/L.

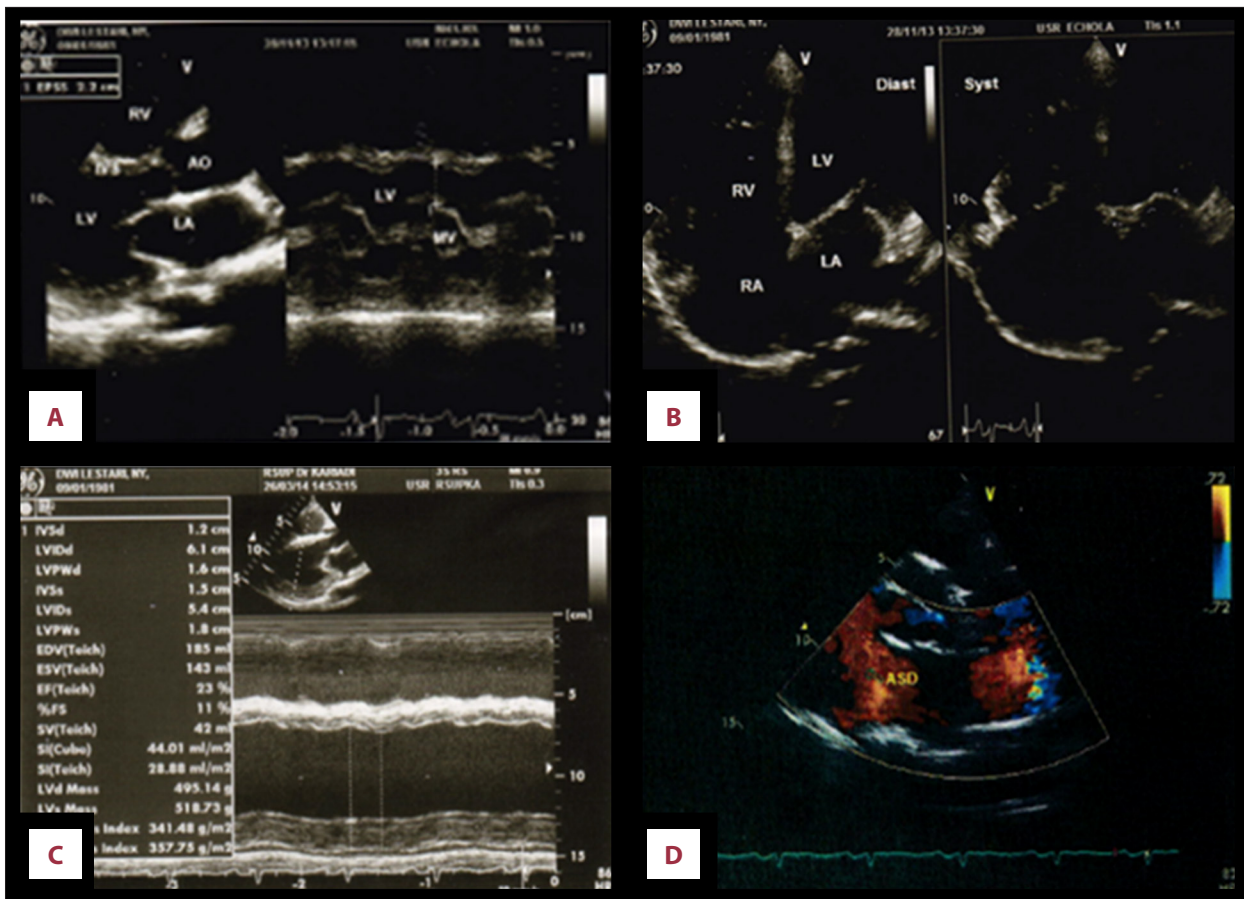
Based on initial findings, a diagnosis of acutely decompensated heart failure (ADHF) with hypokalemic myopathy was made, and the patient was immediately treated with oxygen therapy, intravenous isosorbide dinitrate, furosemide, and potassium replacement. Then, a conventional heart failure regimen was begun that included a non-selective  $\beta$ -receptor antagonist and  $\alpha$ 1-receptor antagonist (carvedilol), an angiotensin converting enzyme (ACE) inhibitor (ramipril), a dihydropyridine calcium antagonist (amlodipine), and an aldosterone receptor antagonist (spironolactone). A serum potassium level was maintained of at least >3 mmol/L with parenteral potassium infusion and tablets.

Transthoracic echocardiography was performed and showed concentric hypertrophy of the LV, with an interventricular septal (IVS) thickness of 14 mm (N=6–9 mm); LV posterior wall thickness in end diastole of 17 mm (N=6–11 mm); LV mass of 473.6 g (N=66–150 g); LV mass index of 284.4 g/m<sup>2</sup> (N=43–95 g/m<sup>2</sup>); and RV wall thickness of 8 mm in diastole (N $\leq$ 5 mm). There was four-chamber cardiac dilatation, global ventricular hypokinetic and LV systolic dysfunction, with an ejection fraction of 17% (Teichholz method). A large interatrial septum gap was present with a defect size of 2.4 $\times$ 2.7 cm, with a left-to-right shunt confirming the diagnosis of ostium secundum ASD. The RA and the RV were dilated, and the right ventricular systolic pressure (RVSP) of 60 mmHg indicated moderately severe pulmonary arterial hypertension (PAH). The echocardiography results are shown in Figure 2.

An abdominal CT scan (Figure 3A, 3B) was performed and compared with the previous scans, and showed an enlarged adrenal mass, from 3.4 cm in diameter in 2008 to approximately 4 cm in diameter in 2014. The tumor was minimally enhanced after contrast injection with low attenuation (+5 Hounsfield units). The absolute washout was calculated as 68%, and the mass was considered as a lipid-poor adenoma.

The investigations of endocrine function showed that her PAC failed to be suppressed after 120 minutes of captopril 50 mg, and the PAC-to-PRA ratio was still elevated further, which confirmed the diagnosis of primary aldosteronism [8]. Other adrenal hormone levels were within normal limits. The diagnoses





**Figure 2.** Transthoracic echocardiography measurements at initial admission in 2014. Left ventricle (LV) showed concentric hypertrophy (interventricular septal thickness 1.2 cm) in parasternal long-axis view (A), four chamber view (B), m-mode (C) and left-to-right flow across the secundum ASD in the apical four chamber view (D).

made at this time were of a right adrenal adenoma and biochemical diagnosis of primary aldosteronism, with acute heart failure, decreased LV systolic dysfunction, hypertensive heart disease, severe hypokalemia, rhabdomyolysis, left-to-right cardiac shunt due to a secundum ASD with moderate pulmonary hypertension (WHO functional class II). On this hospital admission, adrenalectomy was performed as the patient was willing to undergo surgery, and the blood pressure was adequately controlled before surgery.

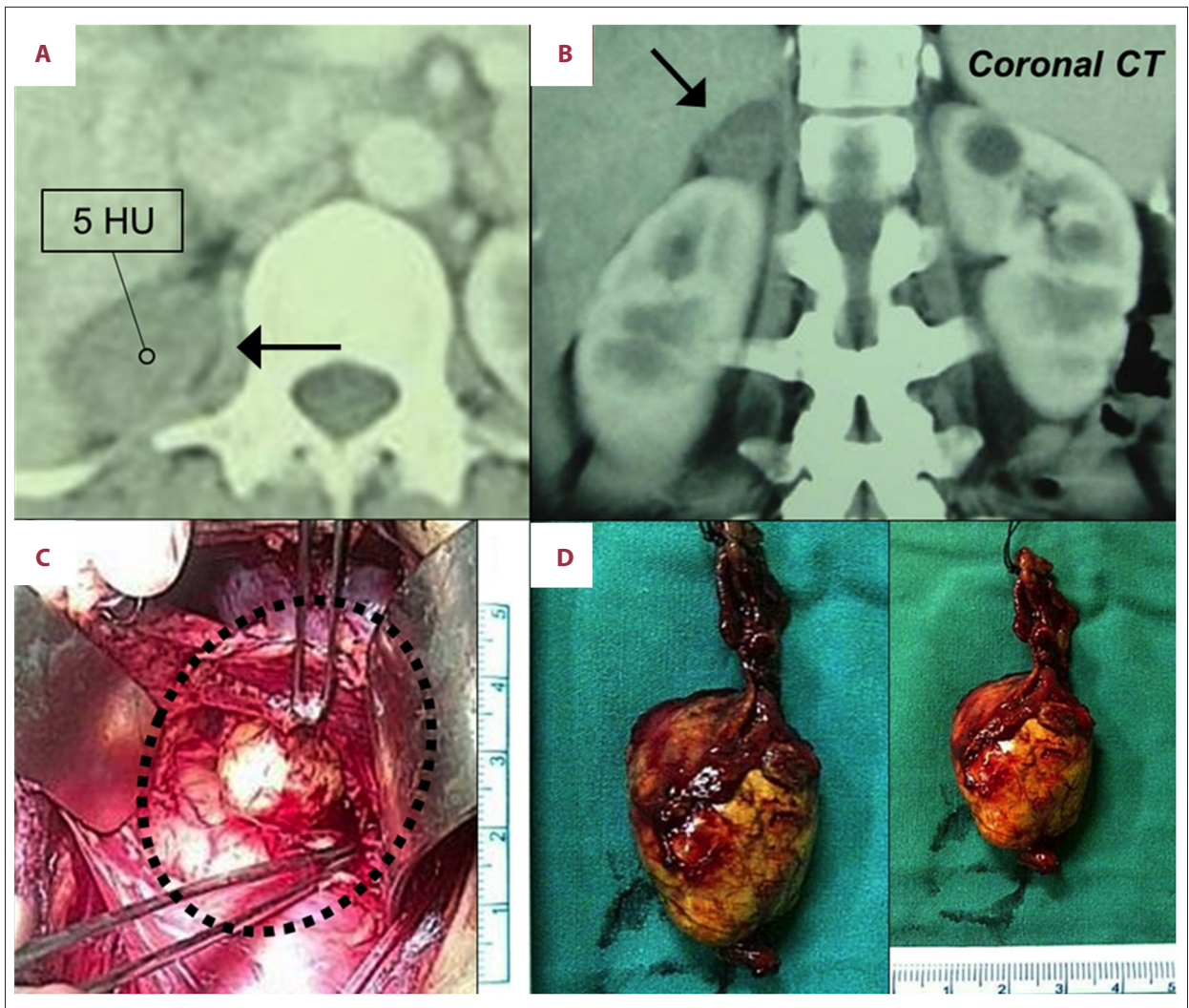
### Surgical management on current hospital admission

After sufficient pre-operative preparation, the patient underwent open adrenalectomy and exploration of the right adrenal mass via a posterior approach. The resected adrenal gland was a single, well defined and encapsulated yellowish nodule which weighed 27.9 g and measured 4.1×2.6×1.5 cm (Figure 3C, 3D). Histopathology examination confirmed a diagnosis of a benign adrenocortical adenoma (Figure 4).

### Patient follow-up and outpatient management

The patient made an uncomplicated recovery post-operatively. Immediately after the removal of the tumor, the PAC was found to be reduced to 8 ng/mL, and the PAC-to-PRA ratio dropped to nearly normal levels. Her serum potassium concentration was normalized without any supplementation. Approximately three days after surgery, the patient remained clinically stable and had adequate blood pressure control with ramipril 5 mg qd. Her postoperative biochemistry showed a serum potassium of 4.1 mmol/L and normal CPK and CKMB. The patient was discharged home and showed stable biochemical findings on follow-up outpatient visits.

Repeated echocardiography in September 2015 demonstrated improvement in the LV and RV size. Her LVEF had improved from 17% at presentation to 56% at 18 months after adrenalectomy (Table 2). Right cardiac catheterization showed a mean right atrial pressure (RAP) of 10 mm Hg, a pulmonary artery pressure (PAP) of 54/29 mmHg (mean 42 mmHg), pulmonary vascular resistance (PVR) of 597 dyn s/cm<sup>5</sup>, and a mean



**Figure 3.** Adrenal tumor visualization. Pre-operative view: (A) Axial and (B) coronal CT section of the abdomen showing a solitary tumor in the right adrenal topography (black arrows). (C) Intra-operative view and (D) Gross appearance of the specimen showing a 4×2.5 cm exophytic adrenal mass excised from right suprarenal area. The tumor is sharply circumscribed and is non-necrotic. The yellow color was thought to result from the abundant lipid content within the tumor.

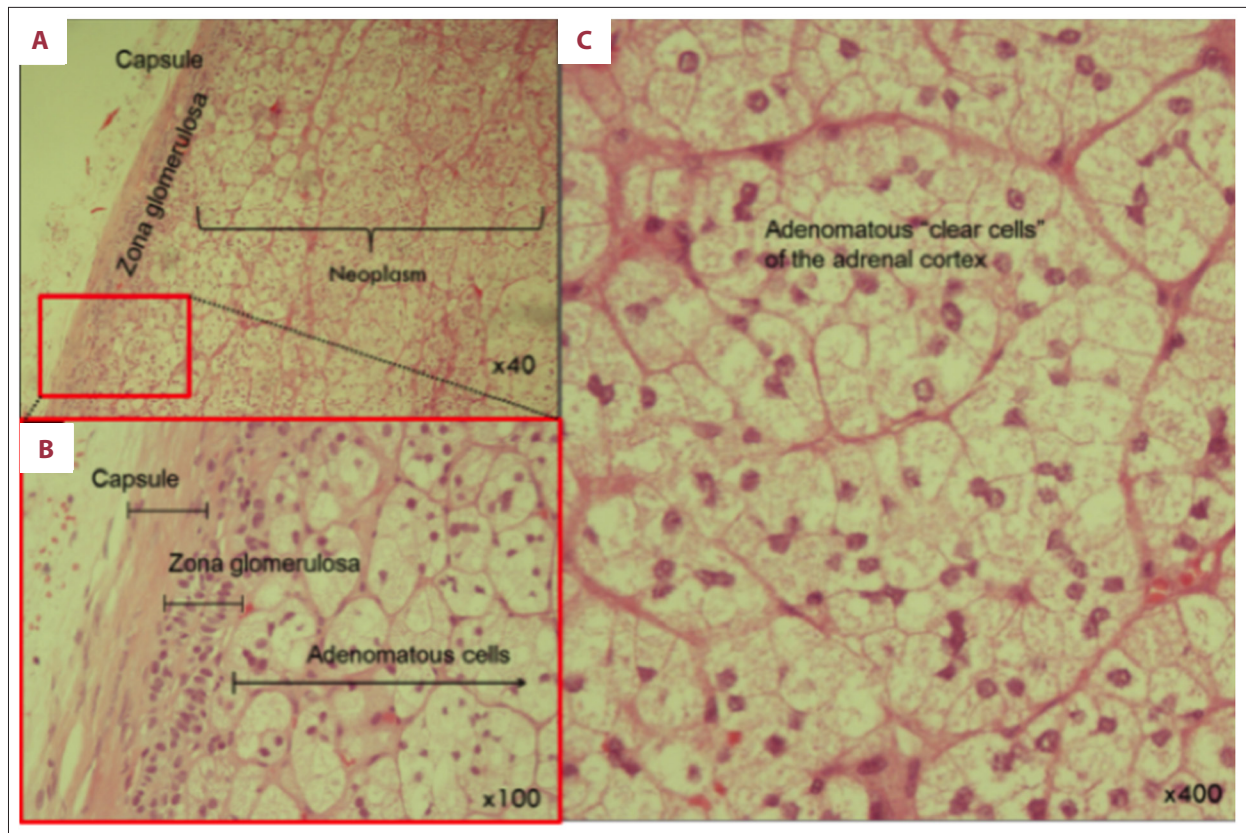
pulmonary capillary wedge pressure of 11 mmHg. The pulmonary artery blood flow (Qp) relative to systemic blood flow (Qs) was 3.8 (Qp/Qs >1.5). Given the significant ASD, particularly with a high PAP and PVR, she was referred for an open surgical closure of her ASD. However, she refused to undergo cardiac surgery because of financial constraints. At her last visit to the clinic in December 2015, the patient was still on ramipril 5 mg qd and remained symptom-free with a blood pressure of 130/80 mmHg and normal potassium level. Currently, her degree of heart failure is stable. At the time of writing this case report, surgical closure of the ASD remains to be undertaken.

## Discussion

This case report is of a 33-year-old woman with an adrenocortical adenoma and a history of primary aldosteronism and repeated hospital admissions with heart failure. Primary aldosteronism is a known cause of secondary hypertension with its sequelae [2,5]. The mineralocorticoid, aldosterone, is a hormone that when in excess can have adverse effects on the cardiovascular system [5]. Studies have shown that the effects on the heart include increased intercellular matrix and microvascular remodeling, as well as atrial and ventricular fibrosis [6,9,10].

In this case report, the echocardiography showed not only changes in the LV, but also biventricular cardiac hypertrophy, four chamber dilatation, and global hypokinetic cardiac





**Figure 4.** Adrenocortical adenoma comprising of lipid-laden cells arranged in an alveolar pattern. Hematoxyline and eosin stain, (A) magnification  $\times 40$  and (B)  $\times 100$ . (C) Tumor cells had clear cytoplasm, round and uniform nuclei, which favored adrenocortical adenoma ( $\times 400$ ).

function, resembling hypertrophic cardiomyopathy [11]. The patient in this case study was also diagnosed with an ostium secundum type ASD, which is a common form of congenital heart disease diagnosed in adults [12]. As an isolated lesion, ASD causes a left-to-right cardiac shunt and volume overload in the right heart chamber, leading to remodeling of the RV [13]. Pulmonary arterial hypertension, in this case, could have resulted in a pressure overload state to the RV, leading to concentric hypertrophy but the right ventricular venous pressure estimated by echocardiography was not high enough (60 mm Hg) to induce right-heart failure. In this case, the pre-existing ASD may have served to mitigate pulmonary congestion via a left-to-right shunt.

To our knowledge, there have been only three previously published cases in the literature of patients with primary aldosteronism and heart failure [14–16]. There have been no previous case reports of primary aldosteronism and heart failure accompanied by biventricular hypertrophy, and congenital heart disease, such as ASD. Of the previously reported cases, laparoscopic adrenalectomy was performed in two cases for unilateral adrenocortical adenoma, while the other case was treated pharmacologically [14–16]. These previously reported

cases showed an improvement in cardiac function and following treatment, either with surgery or with the use of a mineralocorticoid antagonist [14–16]. Sugishita et al. reported RV failure as the predominant feature associated with gross RV hypertrophy, and as the patient had significant LV involvement as well, they used the term ‘cardiomyopathy’ in their case [14]. A possible explanation for RV hypertrophy in primary aldosteronism is that the RV is the first cardiac chamber on which aldosterone can produce its effects. Experimental studies by Weber and Brilla in a rat model support our finding that aldosteronism can be associated with cardiac remodeling in both the LV and RV [17].

A follow-up echocardiography following adrenalectomy of this case report was performed at 18 months after complete biochemical remission from primary aldosteronism. The LV mass index was reduced by  $142.4 \text{ g/m}^2$  by 18 months, consistent with the changes in the LV and RV structure, mid-wall fractional shortening (FS), E/A ratio and E-wave deceleration time also improved at (Table 2). In the 4E-Left Ventricular Hypertrophy Study, LV mass reduction of  $27 \text{ g/m}^2$  was demonstrated at nine months in patients taking eplerenone and enalapril [18] through blockade of the renin-angiotensin-aldosterone system

**Table 2.** Serial measurements on echocardiography, before and after adrenalectomy.

Parameter	Before adrenalectomy		After adrenalectomy	Normal value
	2008	2014	2015	
LAD, mm	45	45	32	19–40
LVdD, mm	61	62	44	38–56
LVDs, mm	54	58	31	22–40
LVM, g	518.7	473.6	240	67–150
LVMI, g/m <sup>2</sup>	357.7	284.4	142	<105
IVSd, mm	14	12	12	6–9
LVPWd, mm	16	16	14	7–11
Ejection fraction, %	23	17	56	50–85
Fractional shortening, %	11	8	29	>25
E/A ratio	0.5	0.4	0.8	>1
E Desc time	283	277	150	<220
RA major, mm	57	58	49	29–45
RVDd, mm	32	34	17	7–26
RVD1, mm	46	ND	30	20–28
RVD2, mm	44	ND	35	27–33
RV EDWT, mm	8	9	6	≤5
RAP, mmHg	5	10	5	0–5
RVSP, mmHg	48	60	42	30–35
TAPSE, mm	26	27	27	>15

LAD – left atrial diameter; LVdD – left ventricular internal diameter end-diastole; LVDs – left ventricular internal end systole; LVM – left ventricular mass; LVMI – left ventricular mass index; IVSd – interventricular septal wall thickness at end-diastole; LVPWd – left ventricular posterior wall thickness at end diastole; LV FS – left ventricular fractional shortening; ND – not determined; RA – right atrial; RA major – right atrial major dimension; RVDd – right ventricular internal diameter at end-diastole; RVD1 – basal right ventricular diameter; RVD2 – mid right ventricular diameter; RV EDWT – right ventricular end diastolic wall thickness; RAP – right atrial pressure; RVSP – right ventricular systolic pressure; TAPSE – tricuspid annular plane systolic excursion.

(RAAS). Given this, treatment with an ACE inhibitor alone, cannot explain the regression of LV hypertrophy (and RV hypertrophy) in this patient. However, surgical closure of the ASD remains to be undertaken at the time of writing this case report.

We acknowledge that ASD and hypertension could have contributed to this patient's cardiac manifestations; these causes alone cannot explain the significant improvement in her cardiac function after surgery for her adrenal tumor. Vice versa, acute aggravation of hypertensive heart failure combined with ASD but not aldosterone could develop similar condition. It seems hard to estimate potential role of aldosterone for heart failure using only from this single case. However, the demonstration of inward regression of both LV and RV hypertrophy, as well as the decrement of RA diameter (regarded as an indicator of cardiac geometry) in repeated echocardiography after

adrenalectomy could provide an indirect proof of causal role in aldosterone excess.

## Conclusions

Patients with primary aldosteronism are known to be at risk of developing hypertensive heart disease and left ventricular hypertrophy. As this case report has shown, patients may present with heart failure due to aldosteronism-induced biventricular cardiac hypertrophy, either by direct aldosterone toxicity or hypokalemia. Both aldosteronism and hypokalemia can be normalized following adrenalectomy in a patient with adrenocortical adenoma.



In a patient with pre-existing ASD, this congenital defect may provide an initial stimulus to right ventricular and pulmonary vascular remodeling, and surgical closure of the ASD can await treatment of the cause of the primary aldosteronism. If an adrenocortical adenoma is identified on imaging, surgery should be planned as soon as possible. This case has demonstrated a mechanistic explanation for both the increased cardiovascular risk and improved prognosis for patients who undergo adrenalectomy for primary aldosteronism due to adrenal adenoma.

## References:

1. Conn JW: Primary aldosteronism: a new clinical syndrome. *J Lab Clin Med*, 1955; 45(1): 3–17
2. Funder JW, Carey RM, Fardella C et al: Case detection, diagnosis, and treatment of patients with primary aldosteronism: An endocrine society clinical practice guideline. *J Clin Endocrinol Metabolism*, 2008; 93(9): 3266–81
3. Conn JW, Knopf RF, Nesbit RM: Clinical characteristics of primary aldosteronism from an analysis of 145 cases. *Am J Surg*, 1964; 107(1): 159–72
4. Lombes M, Alfaidy N, Eugene E et al: Prerequisite for cardiac aldosterone action: Mineralocorticoid receptor and 11 beta-hydroxysteroid dehydrogenase in the human heart. *Circulation*, 1995; 92(2): 175–82
5. Gekle M, Grossmann C: Actions of aldosterone in the cardiovascular system: The good, the bad, and the ugly? *Pflug Arch – Eur J Physiol*, 2009; 458(2): 231–46
6. Milan A, Magnino C, Fabbri A et al: Left heart morphology and function in primary aldosteronism. *High Blood Press Cardiovasc Prev*, 2012; 19(1): 11–17
7. Rossi GP, Cesari M: Aldosterone and right ventricular dysfunction: More data to be collected with prospective cohort studies. *J Cardiovasc Med*, 2016; 17(2): 1–3
8. Petersenn S, Unger N, Walz MK, Mann K: Diagnostic value of biochemical parameters in the differential diagnosis of an adrenal mass. *Ann NY Acad Sci*, 2006; 1073(1): 348–57
9. Shigematsu Y, Hamada M, Okayama H et al: Left ventricular hypertrophy precedes other target-organ damage in primary aldosteronism. *Hypertension*, 1997; 29(3): 723–27
10. Young M, Fullerton M, Dille R, Funder J: Mineralocorticoids, hypertension and cardiac fibrosis. *J Clin Invest*, 1994; 93(6): 2578–83
11. Lopez-Cuenca D, Munoz-Esparza C, Penalver MN et al: Hypertrophic or hypertensive cardiomyopathy? *Int J Cardiol*, 2016; 203(1): 891–92
12. Konstantinides S, Geibel A, Kasper W, Just H: The natural course of atrial septal defect in adults – a still unsettled issue. *Klin Wochenschr*, 1991; 69(12): 506–10
13. Badran HM, Soltan GM, Atwa MAA: Atrial septal defects: Clinical presentation and recent approach in its diagnosis and treatment. *Menoufia Med J*, 2014; 27(1): 145–51
14. Sugishita K, Muraoka H, Kawana A et al: Primary aldosteronism with right-predominant heart failure. *Int Heart J*, 2010; 51(4): 293–97
15. Camargo JM, Mendoza FC, Gomez EA et al: [Heart failure and primary hyperaldosteronism: A case report.] *Rev Colomb Cardiol*, 2012; 19(3): 142–47 [in Spanish]
16. Savoriti S, Petramala L, Zinamosca L et al: Primary aldosteronism in a patient who exhibited heart failure. *J Clin Hypertens*, 2012; 14(8): 566–68
17. Brilla CG, Matsubara LS, Weber KT: Anti-aldosterone treatment and the prevention of myocardial fibrosis in primary and secondary hyperaldosteronism. *J Mol Cell Cardiol*, 1993; 25(5): 563–75
18. Pitt B, Reichek N, Willenbrock R et al: Effects of eplerenone, enalapril, and eplerenone/enalapril in patients with essential hypertension and left ventricular hypertrophy: The 4E-left ventricular hypertrophy study. *Circulation*, 2003; 108(15): 1831–38

## Competing interests

None.

## Acknowledgements

We wish to thank all of the health-care professionals (especially dr. Ardy Santosa as surgeon who performed the adrenal surgery and dr. Siti Amarwati that responsible for the histologic reporting of the adrenal tumor) who dedicated their expertise to the case of the patient described in the present report.