

Evaluating a magnetic resonance imaging of the third-trimester abdominal pregnancy

What the radiologist needs to know

Mei-xiang Deng, MM, Yu Zou, MD*

Abstract

Introduction: A 33-week abdominal pregnancy is an extremely rare type of ectopic pregnancy that is potentially life-threatening for the mother and fetus. Reports of using magnetic resonance imaging (MRI) in the third-trimester abdominal pregnancy are very few.

Patient concerns: A 24-year-old woman (gravida 2, para 1, living 0) at 33 weeks' gestation presented to local hospital complaining of vaginal bleeding for 2 months and lower abdominal pain for 2 days. Then, the woman was transferred to our hospital for suspected abdominal pregnancy, which was confirmed at our hospital on ultrasonography and further evaluated in detail on MRI.

Diagnoses: The woman was diagnosed as having abdominal pregnancy.

Interventions: The woman was managed surgically, the unviable fetus was removed, and the placenta was left in situ. Then, the woman was managed with fluids, blood transfusion, antibiotics, and systemic methotrexate after surgery.

Outcomes: At 42 days postoperatively, the affected woman was discharged in a good condition.

Conclusions: By using MRI, we can accurately diagnose an abdominal pregnancy. MRI provides more details than ultrasonography, and explains the possible mechanism of abdominal pregnancy. We advocate using MRI to help surgical planning and improve outcome in cases of abdominal pregnancy.

Abbreviations: AM = amniotic membrane, BPD = biparietal diameter, CT = computer tomography, FIESTA = fast imaging employing steady-state acquisition, FL = femur length, HCG = human chorionic gonadotropin, MRI = magnetic resonance imaging, POD = pouch of Douglas, SC = sigmoid colon, TE = echo time, TR = repetition time, UB = urinary bladder, UT = uterus.

Keywords: abdominal pregnancy, magnetic resonance imaging, placenta

1. Introduction

Abdominal pregnancy is an extremely rare type of ectopic pregnancy with an incidence ranging between 1:10000 and 1:30000 pregnancies, accounting for 1.3% to 1.4% of all ectopic pregnancies.^[1,2] Abdominal pregnancy can be classified as primary or secondary: Primary abdominal pregnancy occurs when the fertilized ovum implants directly into the peritoneal cavity; secondary abdominal pregnancy occurs when the fertilized ovum first implants in the fallopian tube or uterus

followed by rupture of the uterine or tube wall, leading to secondary implantation in the peritoneal cavity. Ovarian, tubal, and intraligamentary pregnancies are excluded from the definition of abdominal pregnancy.^[3,4] The affected woman may have no complaints, or only have some nonspecific signs and symptoms such as abdominal pain and vaginal bleeding, and the abdominal girth increases just as in a normally implanted pregnancy. Abdominal pregnancy can be easily missed in routine obstetric practice, even in routine antenatal ultrasonography. We present 1 case of abdominal pregnancy which continued into the third trimester and was evaluated by magnetic resonance imaging (MRI). We highlight the significance of MRI in abdominal pregnancies, which figures the exact anatomical relationships of the fetus, the placenta, and maternal intra-abdominal organs, thus contributing to surgical intervention. Finally, the affected woman was discharged in a good condition, but her baby was dead.

Editor: N/A.

Ethical Approval: All procedures performed in studies involving human participants were in accordance with the ethical standards of the institutional and/or national research committee and with the 1964 Helsinki declaration and its later amendments or comparable ethical standards.

The authors report no conflicts of interest.

Department of Radiology, Women's Hospital, School of Medicine, Zhejiang University, Hangzhou, Zhejiang, China.

* Correspondence: Yu Zou, Department of Radiology, Women's Hospital, School of Medicine, Zhejiang University, 1 Xueshi Road, Hangzhou 310006, Zhejiang, China (e-mail: zouyuzju@zju.edu.cn).

Copyright © 2017 the Author(s). Published by Wolters Kluwer Health, Inc. This is an open access article distributed under the Creative Commons Attribution-NoDerivatives License 4.0, which allows for redistribution, commercial and non-commercial, as long as it is passed along unchanged and in whole, with credit to the author.

Medicine (2017) 96:48(e8986)

Received: 30 September 2017 / Received in final form: 5 November 2017 /

Accepted: 8 November 2017

<http://dx.doi.org/10.1097/MD.0000000000008986>

2. Case presentation

A 24-year-old woman (gravida 2, para 1, living 0) at 33 weeks' gestation presented to local hospital complaining of vaginal bleeding for 2 months and lower abdominal pain for 2 days. Before that, the woman had never taken any prenatal examinations because of poverty. She had undergone a cesarean delivery removing a dead fetus in 2012. Local ultrasound scan showed an extrauterine intraabdominal fetus, and diagnosed with suspected abdominal pregnancy. Then, the patient was transferred to our hospital. On arrival, the patient's vital signs were stable. An emergency ultrasound scan at our institute

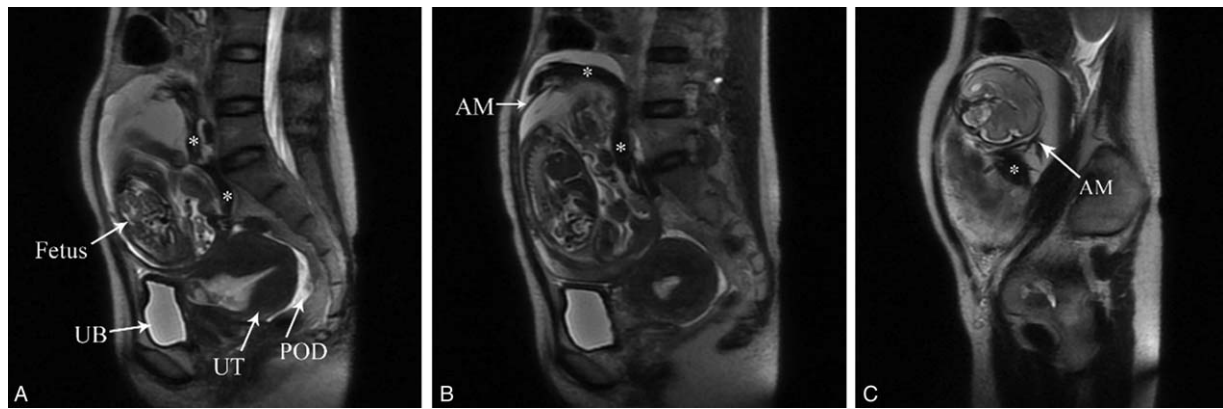


Figure 1. (A–C) Sagittal T2-weighted single shot fast spin echo images show a fetus in an intact hyper-intense amniotic cavity in the abdomen. The fetus is veiled by irregular amniotic membrane (B and C, AM). Large hypointense opacity (A–C, *) floating in the hyperintense amniotic fluid indicates old hemorrhage. The empty uterus (UT) and urinary bladder (UB) are seen in the pelvic cavity. Heterogeneous hyperintense fluid in the pouch of Douglas (A, POD) indicates hemorrhagic content.

revealed a single intra-abdominal extrauterine fetus which was in an amniotic sac with normal amniotic fluid volume. The fetal heart rate was 129 beats/minute, normal uterine wall around the fetus was not noted. The fetal growth parameters (biparietal diameter, 6.6 cm; femur length, 3.8 cm) were far lower than in normal fetus at 33 weeks of gestation. The placenta lied on the left of the fetus. A nonpregnant uterus equivalent to 50 gestational days was seen in the pelvic cavity. Eight hours later, ultrasound findings were further confirmed with an abdominal and pelvic MRI scan (GE 1.5T signa HDxt). Sagittal T2-weighted single-shot fast spin echo images (TR/TE, 2400/130 ms; field of view, 360 × 360 mm; slice thickness, 6.0 mm; echo train length, ∞) demonstrated a fetus in an intact hyperintense amniotic cavity in the abdomen outside the uterus, but the heartbeat of the fetus was not noted (Fig. 1). The fetus was veiled by irregular strip structures, which were postoperatively demonstrated to be amniotic membrane. Large hypointense opacity floating in the hyperintense amniotic fluid indicated old hemorrhage. The empty and enlarging uterus was seen in the pelvic cavity, and its surface is smooth. Axial, sagittal, and coronal T2-weighted fast imaging employing steady-state acquisition images (FIESTA) (TR/TE, 4.4/2.0 ms; field of view, 360 × 360 mm; slice thickness, 6.0 mm; echo train length, ∞) showed that the placenta was located on the

peritoneal surface of the left lateral pelvic and abdominal wall, and inferiorly extending over the peritoneal surface of the uterine front wall (Fig. 2). Large hypointense opacity of hemorrhage oozed from the edge of the placenta, and floated in the hyperintense amniotic fluid. Sigmoid colon surrounded the amniotic cavity without placental implantation. The fluid collections in the pelvic and abdominal cavity were slightly hypointense to amniotic fluid, indicating old hemorrhage.

At the same day, the patient underwent a laparotomy. Through a midline incision about 15 cm in length inferior to the level of the umbilicus, the abdomen was opened. The intraoperative findings further demonstrated the MRI observations. The amniotic cavity was in the abdominal cavity and covered by omentum majus. About 100 mL bloody fluid collection was drained out from the abdominal cavity. About 200 mL bloody amniotic fluid gushed out along with incising the fetal membrane. The dead fetus was removed, and it was veiled by irregular broken amniotic membrane. The umbilical cord was ligated and cut as close to the placenta as possible. A significant portion of the placenta had deeply implanted into the left lateral pelvic and abdominal wall. After delivery, continued bleeding was noted along with placental detachment. The surgeons sutured the bleeding wound of the placenta, and decided to give up exploring the uterus and

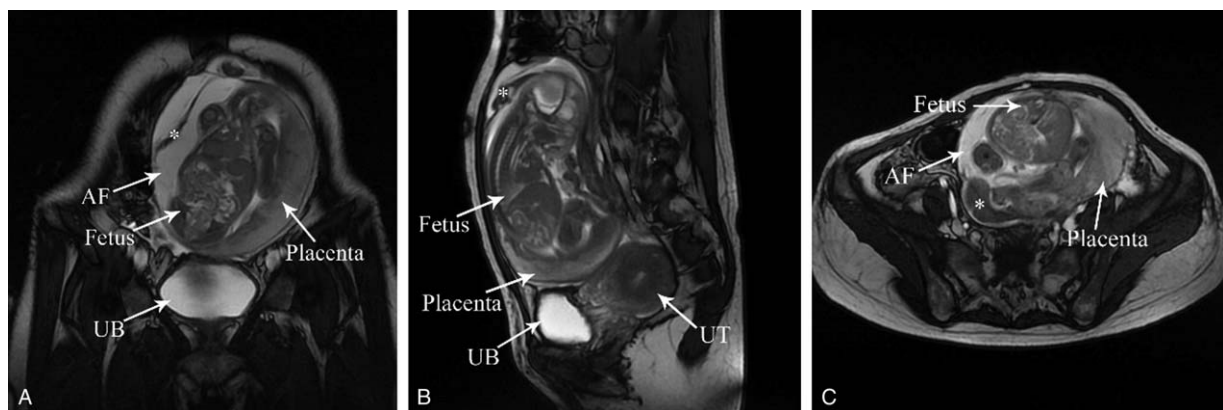


Figure 2. (AC) Coronal, sagittal, and axial T2-weighted fast imaging employing steady-state acquisition images show that the placenta is located on the peritoneal surface of the left lateral pelvic and abdominal wall, and inferiorly extending over the peritoneal surface of the uterine front wall (B, UT). Large hypointense opacity of hemorrhage (A–C, *) oozes from the edge of the placenta, and floats in the hyperintense amniotic fluid (A/C, AF).

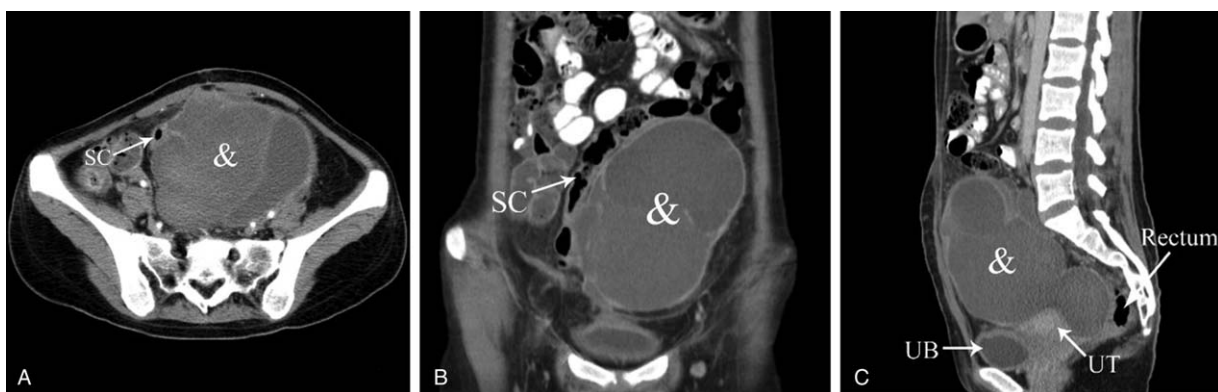


Figure 3. (A–C) At 25 days postoperatively, a CT scan shows that the placenta degenerates to a large cystic mass of encapsulated effusion (A–C, &). The sigmoid colon (A/B, SC) courses along the right lateral portion of the mass. Rectum borders the mass closely.

bilateral adnexa. The placenta was left in place because of deep implantation and to prevent further hemorrhage and organ damage. Blood loss during operation was about 700 mL. The abdomen was closed after repeated peritoneal lavages, and abdominal drainage was left in situ. The patient was managed with fluids, blood transfusion, antibiotics, and systemic methotrexate after surgery. At 25 days postoperatively, a CT scan showed that the placenta had degenerated to a large cystic mass of encapsulated effusion (Fig. 3). At 42 days postoperatively, the patient was discharged with human chorionic gonadotropin level in the normal range. But, a follow-up imaging examination was not obtained because of the patient not returning to our hospital. Informed consent was obtained from the patient. The study was approved by the patient and Women's Hospital, School of Medicine, Zhejiang University Service Ethics Committee (Zhejiang, China).

3. Discussion

Abdominal pregnancy carries a maternal mortality rate between 0.5 and 18%, and a perinatal mortality rate between 40% and 95%.^[5,6] In clinical scenarios, the most common complication of morbidity and mortality in abdominal pregnancies is hemorrhage because of deep placental implantation within important abdominal vascular structures. In abdominal pregnancy, there are no specific signs or symptoms, and the affected woman's abdomen enlarges just as in normal intrauterine pregnancy, so abdominal pregnancy can be easily missed in routine obstetric examination. Ultrasonography is the initial diagnostic test of choice for abdominal pregnancy, but this examination is limited by various factors, such as operator dependence, incomplete penetration in advanced pregnancy owing to oligohydramnios, ossification of fetal bones, fetal lie and position, maternal obesity, and bowel gas. Moreover, ultrasonography is unable to image the fetus in relation to the whole placenta and the uterine wall.^[7] In one retrospective study, only 45% of abdominal pregnancies were diagnosed preoperatively.^[8]

MRI is an alternative imaging modality, which has the advantages of multiplanar imaging, multiparameter imaging, excellent resolution in soft tissue, the absence of radiation, and so on. MRI can not only confirm the diagnosis, but also delineate the exact anatomical relationships of the fetus, the placenta, and maternal intraabdominal organs, and detail vascular and placental organ invasion for preoperative planning. The use of

fast imaging sequence, such as FIESTA, reduces the scan time and shows excellent details with a greatly increased signal–noise ratio.^[9] The identification of the site and extent of placenta on MRI can affect the decision whether to remove or leave the placenta in situ, and direct the operating obstetrician to open the abdomen via correct incision, thereby avoiding a catastrophic hemorrhage once the placental bed is incised. In one study, the implantation site was found to be virtually any structure in the peritoneal cavity.^[10] Uterine fundus and uterine fundus/adnexa are the most common location for abdominal pregnancies based on a comprehensive review of abdominal pregnancies before 20 weeks of pregnancy.^[4] Identification of source of placental blood supply on MRI images is extremely difficult, but the use of MR angiography for preoperative planning has been previously reported.^[11] Because many abdominal pregnancies progress into advanced gestational age, diagnosis of fetal severe congenital abnormalities is important; an MRI can help to exclude these abnormalities. The indications for an MRI in such case of suspected abdominal pregnancy by sonography would be as follows: nonvisualization of normal uterine wall around the fetus; an empty uterus; evaluating the site and extent of placenta; figuring the exact anatomical relationships of the fetus, the placenta, and maternal intra-abdominal organs.

The following are the most important elements that a radiologist must focus on when evaluating an MRI for cases of suspected abdominal pregnancy: Fetus: determination of intra-abdominal extrauterine fetal presence; lie, position, and relation to the uterus and maternal intra-abdominal organs; viability; congenital abnormalities; signs of fetal demise/ maceration/ hydrops. 2) Placenta: site and extent of implantation; most possible placental blood supply; bleeding of placental bed; placental infarction. 3) Amniotic sac: oligohydramnios; signs of rupture of membrane and leakage of amniotic fluid. 4) Uterus: integrity of cervix, uterine wall, and endometrial cavity; signs of uterine rupture and possible exit of the embryo/fetus. 5) Nature of the intra-abdominal fluid and amniotic fluid: hemorrhagic or clear. 6) Any maternal pathology detected by chance, such as uterine and ovarian neoplasms.

4. Conclusion

By using MRI, we can accurately diagnose an abdominal pregnancy. MRI provides more details than ultrasonography, and explains the possible mechanism of abdominal pregnancy.

We advocate using MRI to help surgical planning and improve outcome in cases of abdominal pregnancy.

References

- [1] Molinaro TA, Barnhart KT. Ectopic pregnancies in unusual locations. *Semin Reprod Med* 2007;25:123–30.
- [2] Trabert B, Holt VL, Yu O, et al. Population-based ectopic pregnancy trends, 1993-2007. *Am J Prev Med* 2011;40:556–60.
- [3] Masukume G, Sengurayi E, Muchara A, et al. Full-term abdominal extrauterine pregnancy complicated by post-operative ascites with successful outcome: a case report. *J Med Case Rep* 2013;7:10.
- [4] Poole A, Haas D, Magann EF, et al. Early abdominal ectopic pregnancies: a systematic review of the literature. *Gynecol Obstet Invest* 2012;74:249–60.
- [5] Adesiyun AG, Audu AI. Term extrauterine pregnancy in a Nigerian mother: a complication of uterine dehiscence. *Arch Gynecol Obstet* 2008;279:75–7.
- [6] Zhang J, Li F, Sheng Q. Full-term abdominal pregnancy: a case report and review of the literature. *Gynecol Obstet Invest* 2008;65:139–41.
- [7] Baffoe P, Fofie C, Gandau BN. Term abdominal pregnancy with healthy newborn: a case report. *Ghana Med J* 2011;45:81–3.
- [8] Nkusu Nunyalulendho D, Einterz EM. Advanced abdominal pregnancy: case report and review of 163 cases reported since 1946. *Rural Remote Health* 2008;8:1087.
- [9] Teng HC, Kumar G, Ramli NM. A viable secondary intra-abdominal pregnancy resulting from rupture of uterine scar: role of MRI. *Br J Radiol* 2007;80:134–6.
- [10] Sunday-Adeoye I, Twomey D, Egwuatu EV, et al. A 30-year review of advanced abdominal pregnancy at the Mater Misericordiae Hospital, Afikpo, southeastern Nigeria (1976-2006). *Arch Gynecol Obstet* 2011;283:19–24.
- [11] Malian V, Lee JH. MR imaging and MR angiography of an abdominal pregnancy with placental infarction. *AJR Am J Roentgenol* 2001;177:13.5–06.