

# Modified Retroperitoneal Access for Percutaneous Intervention after Pancreaticoduodenectomy

Uei Pua, MBBS, MMed, FRCR, FAMS, Lawrence H H Quek, MMed, FRCR

All authors: Department of Diagnostic Radiology, Tan Tock Seng Hospital, Singapore 308433, Singapore

Percutaneous access to the surgical bed after pancreaticoduodenectomy can be a challenge, due to the post-operative anatomy alteration. However, immediate complications, such as surgical bed abscess or suspected tumor recurrence, are often best accessed percutaneously, as open surgical or endoscopic approaches are often difficult, if not impossible. We, hereby, describe a safe approach that is highly replicable, in accessing the surgical bed for percutaneous intervention, following pancreaticoduodenectomy.

**Index terms:** Pancreaticoduodenectomy; Percutaneous; Retroperitoneal

## INTRODUCTION

Whipple operation or pancreaticoduodenectomy is a commonly performed curative surgery for pancreatic head and distal common bile duct cancers. While peri-operative mortality has improved over the past decades, the high peri-operative morbidity remains unchanged (1). Percutaneous image guided procedures plays an important role in patients with pancreaticoduodenectomy, with procedures ranging from percutaneous drainage of deep surgical bed abscesses in the early peri-operative period to image guided biopsy of suspected tumor recurrence (2-5). In our experience, percutaneous access to the region around the excised pancreatic head is particularly challenging. Besides the deep location of the area with numerous

surrounding structures, the post-surgical anatomy (e.g. Roux loops) sometimes precludes conventional percutaneous access. We, hereby, illustrate a retroperitoneal technique that is useful in accessing the pancreatic head region post-pancreaticoduodenectomy, where the conventional access is not possible.

## CASE REPORTS

### Case 1

A 61 year-old man developed a non-remitting fever, 7 days after pancreaticoduodenectomy. CT showed an abscess in surgical bed of the pancreaticoduodenectomy (excised pancreatic head) ("\*", Fig. 1A, B). Based on the CT findings, direct anterior approach was considered suboptimal with overlying bowel loop, liver and post-surgical drains and phlegmon. A retroperitoneal approach through the anterior pararenal space was elected (white line, Fig. 1B). With the patient in the left lateral decubitus position, under CT fluoroscopic guidance, a two-part 18 G Trocar needle (Cook Medical, Bloomington, IN, USA) (appendix 1) was inserted into the anterior pararenal space, between the ascending colon and the right kidney. To increase the margin of safety in the planned trajectory that is extremely

Received February 10, 2012; accepted after revision April 23, 2012.

**Corresponding author:** Uei Pua, MBBS, MMed, FRCR, FAMS, Department of Diagnostic Radiology, Tan Tock Seng Hospital, 11 Jalan Tan Tock Seng, Singapore 308433, Singapore.

• Tel: (65)81819490 • Fax: (65)62571400

• E-mail: druei@yahoo.com

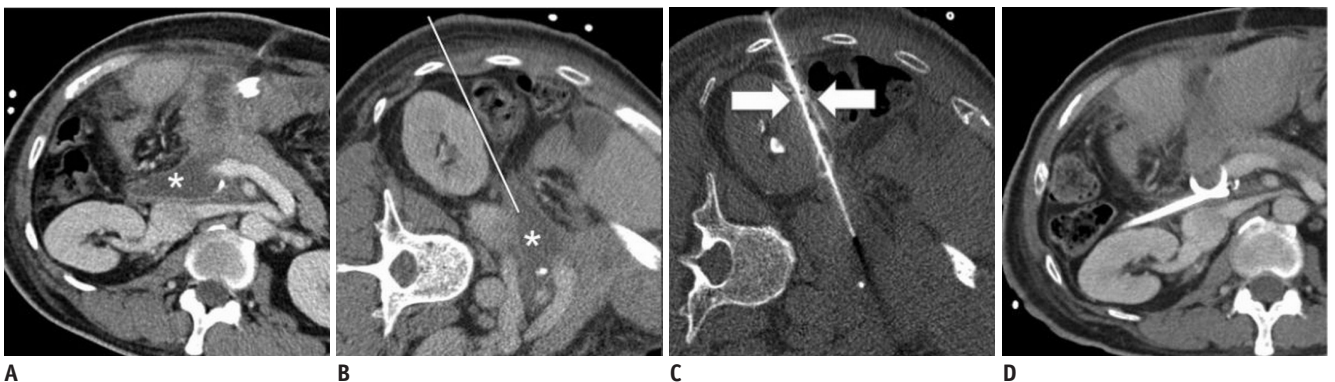This is an Open Access article distributed under the terms of the Creative Commons Attribution Non-Commercial License (<http://creativecommons.org/licenses/by-nc/3.0>) which permits unrestricted non-commercial use, distribution, and reproduction in any medium, provided the original work is properly cited.

narrow (white line, Fig. 1B), hydrodissection using 20 mL of diluted contrast (2% by volume; 1 mL of Omnipaque 350 in 50 mL of saline) was performed by continuous injection through the outer cannula of the Trocar needle (with stylet removed), during a small incremental advancement. The “salinoma” created displaces of the colon from the right kidney, creating a safe corridor for a needle passage (Fig. 1C). On reaching the abscess cavity, a 0.035 inch Rosen guidewire (Cook Medical, Bloomington, IN, USA) was inserted and the track dilated, using a 10 Fr Coons dilator (Cook Medical, Bloomington, IN, USA). A 10 Fr

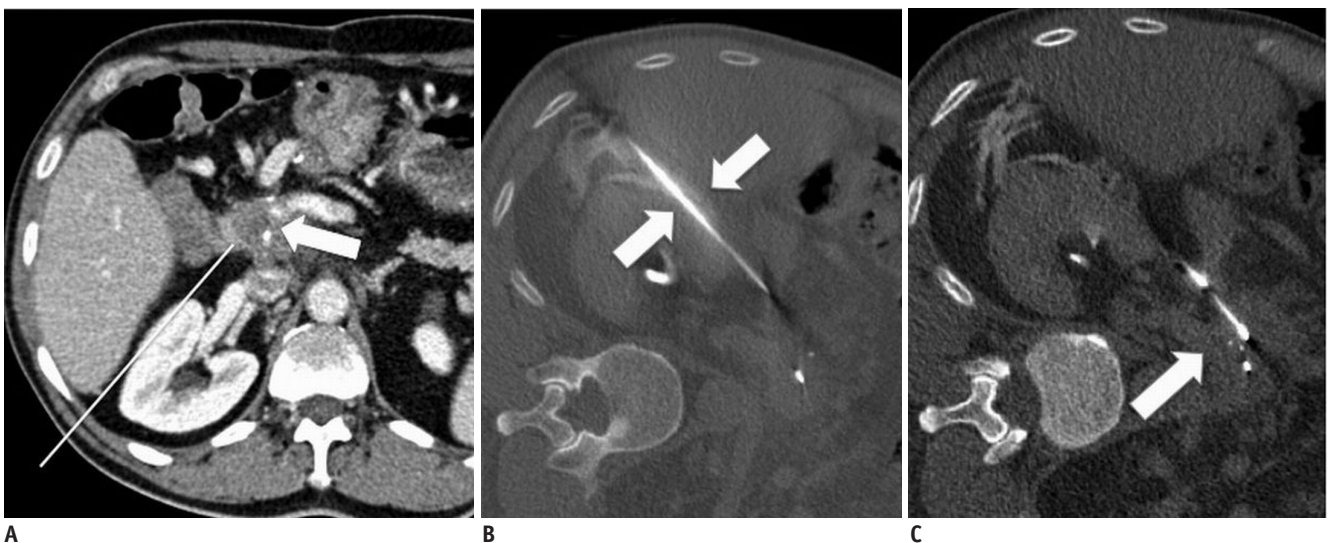
Navarre drainage catheter was inserted (Bard Peripheral Vascular, Tempe, AZ, USA), yielding a 20 mL of frank pus. The drainage catheter was removed 5 days later on the resolution of the abscess (Fig. 1D) and patient had an uneventful recovery period.

**Case 2**

A 57 year-old man, who had pancreaticoduodenectomy 3 years prior to the distal common bile duct cancer, was found with a small hypodense 1.5 cm enhancing mass in the surgical bed on surveillance CT (Fig. 2A). Due to overlying



**Fig. 1. Sixtyone year-old man with fever 7 days after pancreaticoduodenectomy.** Contrast enhanced CT images (A) diagnostic (B) prior to drainage with patient in left decubitus position, shows abscess (\*) in region of excised pancreatic head with overlying bowel loops and liver anteriorly. Planned trajectory in anterior pararenal space (white line) appeared narrow. (C) CT fluoroscopic image showing contrast-fluid hydrodissection (white arrows) widening space between right kidney and ascending colon to allow safe passage of needle. “Salinoma” was created by injecting contrast-fluid mixture continuously while advancing needle. (D) Contrast enhanced CT prior to drainage catheter removal, showing Cope loop of drainage catheter within surgical bed.



**Fig. 2. Fiftyseven year-old man with suspicious lesion in surgical bed 3 years after pancreaticoduodenectomy.** A. Contrast enhanced CT showed hypodense lesion in surgical bed, worrisome for tumor recurrence. Overlying bowel and vessels made anterior approach from biopsy unsuitable. Planned trajectory (white line) between segment VI of liver and right kidney is equivocal for needle passage without organ traversal. B. CT fluoroscopic image showing contrast-fluid hydrodissection (white arrows) used to create safe passage between liver and right kidney for guide needle. C. CT fluoroscopic image showing deployment of biopsy chamber into lesion (white arrow). Fine adjustments to biopsy location could be made by applying external torque on guide needle. Histology confirmed recurrent cholangiocarcinoma.

vascular structures and bowel loops, direct anterior approach was not possible. Using the similar technique, with the patient in the left lateral decubitus position, under a CT fluoroscopy, the 16 G guide needle of a QC biopsy set (Cook Medical, Bloomington, IN, USA) was inserted into the space between the segment VI of the liver and the right kidney (Fig. 2B). Hydrodissection was performed in a similar fashion, while advancing the guide needle, which created a safe passage. On reaching the region of interest, the biopsy needle was inserted in a co-axial fashion, obtaining 4 cores of tissue. By applying the external torque to the guide needle, the biopsy chamber could be deflected into different areas of the mass to increase a sampling yield. The patient was discharged after 4 hours of observation, and histology revealed a recurrent cholangiocarcinoma.

## DISCUSSION

Percutaneous imaged guided biopsy (FNAB) and drainage of pancreatic lesions, using a CT or US guidance, are well-described in the literature (2-5). Due to the retroperitoneal location of the pancreas, access to pancreatic lesions, however, often requires transgression of overlying structures, such as the bowel, liver and mesenteric vessels (1). Lesions in and around the pancreatic head region are perhaps the most challenging of all pancreatic lesions, owing to its deep-seated location with overlying structures. This is reflected in the novel approaches being devised, such as posterior transvenous route for FNAB of pancreatic head (6, 7).

Nevertheless, pancreatic intervention that involves the organ transgression is generally limited to FNAB, as transgression using the fine gauge needles (e.g. 18-22 G biopsy needles) is generally considered safe. With the exception of transgastric approach, organ transgression is usually avoided, and is not the preferred route for the placement of large-bore drainage catheters, and a direct percutaneous trajectory without organ transgression is usually preferred (2-5). In the context of patients who have undergone pancreaticoduodenectomy, however, access options is often limited, as the result of surgically refashioned small bowel anatomy and overlying major vasculature/organs that preclude the preferred anterior approaches. Additionally, the altered small bowel anatomy also makes alternatives, such as endoscopic intervention (e.g. endoscopic ultrasound guided drainage/biopsy), difficult if not impossible, and surgical reintervention tends

to be considered as a last resort in the post-operative setting.

An advantage that can be exploited in pancreaticoduodenectomy is the resection of the entire duodenum together with the pancreatic head. With the C-loop of the duodenum removed, the region over the excised pancreatic head is very amenable for the direct right lateral retroperitoneal approach. When combined with hydrodissection to create the potential space anterior to the right kidney, we find this approach to be a safe and an effective approach, even in the absence of straight-line needle trajectory in the anterior pararenal space on the planning CT study (white line, Figs. 1B, 2B). The technique of using a contrast-fluid for hydrodissection is an adaptation of that described in the literature by DeBenedictis et al. (8) for the renal radiofrequency ablation. Similar to that described by the authors, the 2% contrast-fluid mixture allows for an accurate visualization of the "salinoma" and the plane created between the adjacent organs, which will otherwise have similar attenuation during a CT fluoroscopy, at the same time, not obscuring the needle. Besides the fact that the prone positioning is difficult in the peri-operative period, the choice of lateral decubitus over the supine or prone positioning lies in that the intra-peritoneal structures, such as the liver, colon and hepatico-jejunoscopy loops are mobilized to a greater extent than the retroperitoneal structures (e.g. right kidney), creating a window for initiation of hydrodissection.

To conclude, we describe the right lateral retroperitoneal approach as a feasible access route for percutaneous intervention after pancreaticoduodenectomy.

## REFERENCES

1. Yeo CJ, Cameron JL, Sohn TA, Lillemoe KD, Pitt HA, Talamini MA, et al. Six hundred fifty consecutive pancreaticoduodenectomies in the 1990s: pathology, complications, and outcomes. *Ann Surg* 1997;226:248-257; discussion 257-260
2. Gervais DA, Fernandez-del Castillo C, O'Neill MJ, Hahn PF, Mueller PR. Complications after pancreatoduodenectomy: imaging and imaging-guided interventional procedures. *Radiographics* 2001;21:673-690
3. Maher MM, Gervais DA, Kalra MK, Lucey B, Sahani DV, Arellano R, et al. The inaccessible or undrainable abscess: how to drain it. *Radiographics* 2004;24:717-735
4. Brandt KR, Charboneau JW, Stephens DH, Welch TJ, Goellner JR. CT- and US-guided biopsy of the pancreas. *Radiology* 1993;187:99-104

5. vanSonnenberg E, Wittich GR, Chon KS, D'Agostino HB, Casola G, Easter D, et al. Percutaneous radiologic drainage of pancreatic abscesses. *AJR Am J Roentgenol* 1997;168:979-984
6. Gupta S, Ahrar K, Morello FA Jr, Wallace MJ, Hicks ME. Masses in or around the pancreatic head: CT-guided coaxial fine-needle aspiration biopsy with a posterior transcaval approach. *Radiology* 2002;222:63-69
7. Sofocleous CT, Schubert J, Brown KT, Brody LA, Covey AM, Getrajdman GI. CT-guided transvenous or transcaval needle biopsy of pancreatic and peripancreatic lesions. *J Vasc Interv Radiol* 2004;15:1099-1104
8. DeBenedictis CM, Beland MD, Dupuy DE, Mayo-Smith WW. Utility of iodinated contrast medium in hydrodissection fluid when performing renal tumor ablation. *J Vasc Interv Radiol* 2010;21:745-747

- APPENDIX -



**Appendix 1. Magnified photograph of tip of two part Trocar needle.** Note diamond tip with blunt outer cannula (white arrow). Blunt outer cannula is very useful for hydrodissection as it atraumatic.