

# Evaluation of complications of totally implantable central venous port system insertion

DONG HYUN KIM, DONG YEON RYU, HYUK JAE JUNG and SANG SU LEE

Department of Surgery, Vascular and Endovascular Division, Research Institute for Convergence of Biomedical Science and Technology, Pusan National University Yangsan Hospital, Yangsan, Gyeongsangnam 50612, Republic of Korea

Received July 3, 2017; Accepted February 8, 2018

DOI: 10.3892/etm.2019.7185

**Abstract.** The aim of the present study was to describe the procedure of totally implantable central venous port system (TICVPS) insertion performed at our center and investigate associated complications. The study retrospectively evaluated 827 patients who underwent a single-type TICVPS insertion from January 2013 to July 2015. The length of the procedure, long-term device function, angle (chamber-to-tip) and complications of TICVPS, including infection, skin erosion, occlusion, malposition and thrombosis, were analyzed from the patients' medical records. A total of 843 TICVPS insertions were performed in 827 patients. The TICVPS implantation was successful in all cases (100%). A total of 34 cases (4.0%) with complications were recorded. Complications at the chamber insertion site occurred in 11 patients (1.3%), including 5 infection (0.6%) and 6 erosion cases (0.7%). All patients with chamber insertion site infection were treated by administration of antibiotics and dressing. Of the patients in which chamber insertion site erosion occurred, 2 were subjected to TICVPS removal and reinsertion and 4 were treated with debridement, irrigation and resuture. The most common type of complication was catheter-associated (2.3%; n=19). Among these cases, 7 had catheter-associated infection (0.8%), 8 had catheter migration (1.0%) confirmed by chest radiography, 4 had catheter-associated thrombosis (0.5%) and 2 had chamber malposition (0.3%). The present retrospective study on TICVPS, which used a relatively large cohort, demonstrated a low complication rate (4.0%) compared with that reported in previous studies (5-20%). A well-designed procedure, experienced vascular surgeons, an aseptic operating room environment, ultrasound-guided puncture, a wide angle

(chamber-to-tip) and the use of fluoroscopy with contrast agent may reduce the complication rate of TICVPS insertion.

## Introduction

Niederhuber *et al* (1) reported on the first use of the totally implantable central venous port system (TICVPS) in 1982. Subsequently, the use of the TICVPS in patients undergoing chemotherapy, parenteral nutrition, intravenous injection, transfusion or repetitive laboratory analysis has increased (2,3). The TICVPS may reduce infection rates and thrombosis arising from recurrent puncture of the veins in patients with cancer (4,5). In addition, they also have no or only a minor impact on patients' daily activities, and cosmetic results after implantation are usually satisfactory (6-10). The TICVPS provides safe access to the central vein and long-term comfort and aesthetic satisfaction for patients who require long-term venous access.

The TICVPS is being implemented in >15 million patients per annum in the US, with associated complication rates ranging from 5-19% (11,12). Various types of TICVPS, which all provide venous access, are inserted by vascular surgeons, interventional radiologist and oncologists using a number of methods (13-19). Reported complications are mechanical complications during or directly after the insertion, including arterial puncture, nerve injury, hematoma and pneumothorax, and long-term complications, including infection and thrombosis (11). As the insertion techniques, management of the central venous port and catheter material are improved, the associated complications reduced, however when complications occur, the length of hospitalization and cost of medical care increase, and the rates of patient morbidity and mortality increase (20,21). Thus, it is important to reduce complications during or after TICVPS insertion.

The purpose of the present study was to describe the procedures for TICVPS insertion and to assess various post-operative complications associated with the TICVPS at our center. The present study also sought to determine how to reduce TICVPS-associated complications.

## Patients and methods

*Patients and data.* The present study retrospectively reviewed data from patients who underwent TICVPS insertion between

---

*Correspondence to:* Dr Sang Su Lee, Department of Surgery, Vascular and Endovascular Division, Research Institute for Convergence of Biomedical Science and Technology, Pusan National University Yangsan Hospital, 20 Geumo Road, Yangsan, Gyeongsangnam 50612, Republic of Korea  
E-mail: phoenixdr@naver.com

*Key words:* totally, implantable, central, venous port, system

January 2013 and July 2015 at Pusan National University Yangsan Hospital (Yangsan, Republic of Korea). Exclusion criteria were as follows: Patients without fluoroscopy image results or follow-up not completed at Pusan National University Yangsan Hospital after TICVPS insertion. A single-type TICVPS (Districath; Districlass Medical SA, Chaponnay, France) was used. All procedures were performed by 2 vascular surgeons at a single center. Patient data and surgical radiographic imaging were collected from electronic medical records and a picture archiving and communication system tool (Marosis 5.4.10.71 PACS viewer; Marotech, Inc., Seoul, Korea), including operative and progress notes, as well as nursing records, in order to identify and record complications.

**TICVP insertion.** The TICVP insertion procedures were performed in the operating room, and the surgeons constantly monitored the electrocardiogram (ECG), oxygen saturation and blood pressure of patients during the procedure. Antibiotics (2 g flomoxef sodium) were intravenously administered as a prophylaxis prior to the procedure. The patient was placed in the supine position, and the neck was slightly turned to the side opposite to that of the procedure. Betadine was applied around the procedure site, which was aseptically draped. The right internal jugular vein was primarily selected as the access vein. The left internal jugular vein was considered the second access vein if the right internal jugular vein had an anatomical abnormality or in cases of right breast cancer. The subclavian vein was used if the two internal jugular veins could not be accessed. Once the access vein was determined, venous puncture was performed under ultrasonography and the guide wire was placed in the needle. Although the needle was removed and the wire fixed into the vein with mosquito forceps, a skin incision of ~2 cm was created for the pocket of the chamber at the deltopectoral region, below the clavicle. After making the pocket wide enough to insert the chamber (semicircle, ~2 cm in diameter), a subcutaneous tunnel was created between the puncture and pocket sites with a tunneler, which was connected at the catheter end. The chamber was then placed at the pocket site, and the catheter was cut to place the tip of the catheter at the cavoatrial junction and into the puncture site. Finally, the function of the TICVPS was confirmed by aspirating a small amount of blood from the chamber with a non-coring needle. The blood flow through the catheter, the catheter angle and the catheter tip position were checked by injecting a small amount of contrast media under fluoroscopy with a mobile C-arm (OEC9900 Elite; GE Healthcare, Little Chalfont, UK; Figs. 1 and 2). The chamber was sutured on the fascia of the pectoralis major muscle for fixation of the chamber in the pocket after each checkpoint was confirmed. The skin incision was sutured subcutaneously with monocryl 5-0 and reinforced with Steri strips, and dressing was applied. The success of the procedure was due to the following features showcasing good clinical practice: i) All procedures were performed in a clean operating room with monitoring, ii) ultrasonography and fluoroscopy were used for guidance, iii) the procedure was performed by experienced surgeons, iv) selection of a wide catheter angle ( $>60^\circ$ ) and v) subcutaneous suture with Steri Strips.

Two surgeons had extensive experience with central venous catheterization (CVC) under ultrasonography

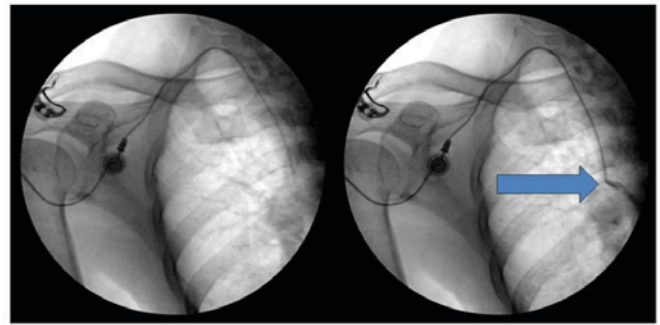


Figure 1. Caterer insertion. The insertion of the catheter tip using fluoroscopy. The blue arrow demonstrated the inspection of the catheter tip position with the injection of a small amount of contrast media.

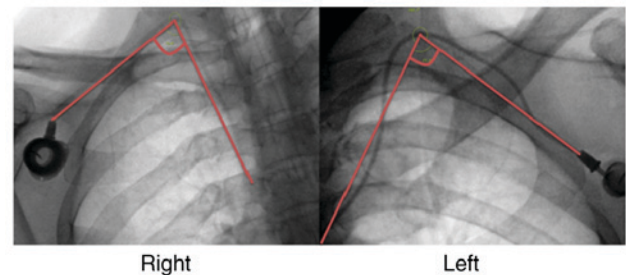


Figure 2. Intraoperative fluoroscopy. The catheter angle was measured using fluoroscopy with a mobile C-arm.

(>100 cases annually during 4 years) and also performed endovascular surgery (>200 cases annually) under ultrasonography and fluoroscopy, and a similar operative technique was used for TICVPS placement. A vascular surgeon experienced in TICVPS was defined as having performed >400 CVCs and 200 TICVPs.

**Post-insertion exam and follow-up.** After the insertion, the patient had a 1-day post insertion check-up by the Surgeon who had performed the TICVPS insertion and the wound site was examined for any immediate complications. The team of surgeons initiated the use of the TICVPS to check its patency. Subsequently, the patients were followed up over 30 days post-insertion and any observations were added to the patients' medical records.

Analyses of the present study were performed by reviewing the electronic medical records of the patients. The definition of periprocedural complications was classified into immediate, early and late complications. Immediate complications are intra-procedural. Early complications were defined as complications that arise within 24 h, which are mostly procedure-associated, and also complications that occur within 30 days after the procedure. Late complications are those that are detected beyond 30 days of insertion. The complication rates published in previous studies vary in their type. The present study focused on various important periprocedural complications.

## Results

A total of 843 TICVPS were inserted in 827 patients between January 2013 and July 2015. The procedure was successful in all

Table I. Demographics and clinical characteristics of the patients (n=827).

Variable	Value
Sex	
Male	351 (42.4)
Female	476 (57.6)
Age (years)	58.2±11.6 (18-86)
<60	448 (54.2)
≥60	379 (45.8)
Port implantation period (days)	275.4±146.5 (1-782)
<300	518 (61.4)
≥300	325 (38.6)
Anesthesia	
Local	715 (84.8)
General	128 (15.2)
Port implantation site	
Right internal jugular vein	724 (85.9)
Left internal jugular vein	113 (13.4)
Right subclavian vein	4 (0.5)
Left subclavian vein	2 (0.2)
Catheter angle (°)	72.5±20.0 (48.7-99.8)
Body mass index (kg/m <sup>2</sup> )	23.0±3.6 (13.2-44.4)
<17	24 (2.9)
≥17, <25	619 (74.4)
≥25	200 (23.7)
Underlying disease	
Malignant solid tumor	766 (90.9)
Breast cancer	182 (21.6)
Gastrointestinal cancer	470 (55.8)
Gynecological cancer	44 (5.2)
Lung cancer	32 (3.8)
Other	38 (4.5)
Hematologic malignancy	71 (8.4)
Benign disease	6 (0.7)
Metastatic cancer	343 (40.7)

Values are expressed as n (%) or the mean ± standard deviation (range).

cases. TICVPS insertion was performed twice in 16 patients in this study period. The demographic and clinical characteristics of the patients are listed in Table I. A total of 351 patients (42.4%) were males. The mean age of the patients was 58.2 years (range, 18-86 years), and 448 (54.2%) were below the age of 60 years. The average time the indwelling catheter was worn was 275.41 days (range, 1-782 days), and 325 patients (38.6%) had the indwelling catheter for >300 days. TICVPS insertion was performed under local and general anesthesia in 715 (84.8%) and 128 cases (15.2%), respectively. Patients under general anesthesia were simultaneously subjected to cancer surgery and TICVPS insertion. The most common TICVPS insertion sites were the right internal jugular, left internal jugular, right subclavian and left subclavian veins in 724 (85.9%), 113 (13.4%),

Table II. Complications of totally implantable central venous port system.

Type of complication	n (%)
Chamber site-associated	11 (1.3)
Infection	5 (0.6)
Erosion	6 (0.7)
Catheter-associated	19 (2.3)
Infection	7 (0.8)
Migration	8 (1.0)
Thrombosis	4 (0.5)
Other	4 (0.5)
Chamber malposition	2 (0.3)
Discomfort	1 (0.1)
Malfunction	1 (0.1)
Total	34 (4.0)

4 (0.5%) and 2 cases (0.2%), respectively. The mean catheter angle was 72.5° (range, 48.7-99.8°) and the mean body mass index of the patients was 23.0 kg/m<sup>2</sup> (range, 13.2-44.4).

Solid tumors, hematologic cancers and benign tumors were present in 766 (90.9%), 71 (8.4%), and 6 patients (0.7%), respectively, wherein TICVPS was inserted for fluid resuscitation, parental nutrition or transfusion.

TICVPS-associated complications are described in Table II. A total of 34 (4.0%) complications were recorded. Catheter-associated complications were the most common type of complication, occurring in 19 cases (2.3%). Among these patients, 7 patients with catheter-associated infection underwent TICVPS removal and received antibiotics based on the results of the catheter tip culture. Catheter migration occurred in 8 patients, which was confirmed by chest radiography. Catheter tip malposition occurred in the neck vein in 6 cases, and extravenous catheter migration in 2 cases. Of these patients, 3 underwent removal and re-insertion of the catheter and 5 were subjected to re-positioning, including the 2 patients with extravenous catheter migration. The other 4 patients with catheter thrombosis underwent catheter removal (n=3) and anticoagulation therapy (n=1), including 1 patient whose catheter function was preserved.

Complications of the chamber insertion site occurred in 11 cases (1.3%; 5 infections and 6 erosions). All infections were treated by administration of antibiotics and dressing. Of the 6 erosion cases, 2 underwent TICVPS removal and re-insertion, and 4 were treated with debridement, irrigation and restoration.

Chamber malposition occurred in 2 patients and they underwent chamber repositioning. One patient had discomfort at the insertion site and requested TICVPS removal. TICVPS malfunction occurred in 1 case. Repositioning was performed first, but malfunction was not resolved; hence, the TICVPS was removed and another one was inserted.

## Discussion

Insertion of the TICVPS is predominantly carried out by surgeons, who perform venous cut down or use anatomic

Table III. Comparison of the frequency of complications (%) between different studies.

Complication	Teichgräber <i>et al</i> (17) (n=3,160)	Babu <i>et al</i> (22) (n=180)	Kim <i>et al</i> (20) (n=179)	McGee and Gould (12) (review)	Present study (n=827)
Pneumothorax	0	3.7		<0.1-0.2	0
Bleeding Hematoma	0.2	7.4		<0.1-2.2	0.2
Malposition	0	5.6			0.1
Deep vein thrombosis	0.5	4.6	4.5	4.3	0.4
Pain	0.2				0.1
Allergic reaction	0.02				0
Catheter associated bloodstream infection	5.1	18.8	12.8	13.6	0.8
Pocket infection	0.3				0.6
Migration	0.6	10	10		1
Skin erosion	0.2	0	0	9.3	0.7
Accidental dislodgement	0.4	10.2	4.5	7.5	0.2
Malfunction	0.1			4.6	0.01

landmarks to identify a suitable entry site. However, certain interventional radiologists perform image-assisted percutaneous TICVPS insertion using ultrasound guidance with the Seldinger technique at the access site and fluoroscopy to check the catheter placement with good success rates comparable to those of the surgeons (11). No significant differences in the rate of infection between the angiographic suite and the operation theater, were reported, with  $P < 0.743$ . When intervention radiologists performed TICVPS, the infection rate was relatively high ( $>5\%$ ) (11). In the present study, the overall complication rate was 4.0%, with no mortality recorded in 843 cases of TICVPS insertion. In terms of the complication rate, the present results are superior to those reported in other studies (5-19%). A comparison of complications reported in various studies is presented in Table III (12,17,20,22). All patients of the present study underwent the insertion procedure performed according to good clinical practice, as mentioned above. Proper positioning of the catheter tip is important, as shortcomings thereof are associated with TICVPS malfunction and catheter-associated complications. In cases of catheter migration or catheter tip malposition, catheter malfunction, pain or swelling may occur. Son *et al* (23) reported that the risk for catheter thrombosis was high when the catheter tip was above the superior vena cava.

Schenck *et al* (24) recommended using intra-atrial ECG techniques to determine the catheter tip position. In this study, the electrical current transducer was connected to the catheter and the cable attached to lead II of a standard ECG monitor. The catheter was slowly advanced by monitoring the morphological changes of the P wave until the tip reached the desired position. The catheter tip is close to the sinoatrial node (i.e., in the upper part of the right atrium) when the P wave reaches its maximum height. One centimeter above this point, when the P wave is at half of its maximal height, the tip is close to the atriocaval junction. It may be justified to perform delayed postoperative chest radiography to confirm central venous catheter line tip placement.

The acceptable complication rate observed in the present study (4.0%) may be due to several factors. The position of the catheter tip was determined using fluoroscopy with contrast media during the procedure. The blood flow in the catheter, as well as the catheter angle and catheter tip position were checked using fluoroscopy with contrast media. Prior to the end of the procedure, the catheter tip position and angle were adjusted if it was not appropriately placed.

Complications at the chamber insertion site included infection and erosion. Infection of the chamber insertion site comprised erythema, tenderness and occasional discharge (25). In the present study, 5 patients with chamber insertion site infection presented with redness, swelling and pain, and they were administered antibiotics.

Skin erosion at the chamber insertion site is a rare long-term complication. The skin overlying the chamber generally breaks down, exposing the device in the subcutaneous space (26,27). Skin erosion is a gradual process, which results in infection. This may manifest systemically as a fever with chills and/or locally with discharge or abscess (28). However, erosion without infection has also been documented (29). Incision site tension, repeated abrasion or repeated needle puncture may also result in skin erosion.

A recent study suggested that the incidence of skin erosion was 1% (30). The incidence of skin erosion in the present study was 0.7% (6/843). The pocket was bigger than the chamber (semicircle, ~2 cm in diameter) to reduce the tension of the skin incision after chamber insertion. A thick skin flap was also created to withstand repeated puncture and weight loss. Patients undergoing chemotherapy are more likely to lose weight due to chemotherapy-associated side effects, and therefore, the use of a thick skin flap is appropriate in these patients. The subcutaneous skin incision site was sutured with monocril by a well-trained surgeon and reinforced with an aseptic Steri strip to reduce skin infections and dehiscence. A previous study reported that subcutaneous suture closure of the incision site reduced wound disruption (31). The methods mentioned above may have resulted

in a lower incidence of skin erosion and lower complication rates in the present study.

In the present study, all patients underwent TICVPS in a hybrid operation room, which fulfilled aseptic criteria for a standard surgical room and imaging equipment from a mobile C arm or angio suite (32), which may have contributed to reducing sources of infection.

Catheter-associated thrombosis may occur spontaneously or from a prothrombotic state associated with an underlying malignancy or treatment (25). The association between cancer and thrombosis arises as a consequence of cancer treatment and direct vessel trauma, which is a result of long-term central venous catheter placement (30). Thrombosis may cause several symptoms associated with loss of catheter function, including an increased risk of infection, pulmonary embolism and post-phlebotic syndrome; it is also associated with greater cost (33). Catheter-associated thrombosis has a reported incidence of 0.3-28.3% (17,34,35). In the present study, the incidence of catheter-associated thrombosis was 0.5% (4/843). At our center, the catheter angle was constantly checked using fluoroscopy and it was attempted to adjust the catheter angle to  $>60^\circ$  during the procedure. A sharp catheter angle causes poor blood flow in the catheter, and thrombosis may easily occur. At our center, the right internal jugular vein was primarily selected as the access vein, as the jugular vein has a lower risk for catheter-associated thrombosis than the subclavian vein (36), and the right internal jugular vein provides direct access to the superior vena cava (37). The left internal jugular vein was considered as the secondary access vein if the right internal jugular vein had an anatomical abnormality or in patients with right breast cancer, due to radical axillary lymph node dissection and postoperative radiotherapy (38). The creation of a catheter angle of  $>60^\circ$  and selection of the appropriate access vein during the procedure may have reduced the occurrence of catheter-associated thrombosis in our center.

Patients were diagnosed with catheter-associated infections if they had at least 2 positive blood culture results, obtained from at least 2 separate sites at different times, with evidence of colonization of the catheter with the same organism. The fulfillment of the latter part of the definition may only be determined by removing the catheter (25). In the present study, 7 (0.8%) cases of catheter-associated infection occurred. In a previous study, the overall incidence of catheter-associated infection was reported as 0-6.8% (39). To reduce infection-associated complications, TICVPS insertion was performed in the operating room under aseptic conditions. All healthcare professionals who participated in the procedure wore surgical gowns and it was attempted to minimize the length of the surgery.

In the present study, no periprocedural complication, e.g., pneumothorax, was recorded. Ultrasound-guided puncture reduces the rate of these complications. Port site discomfort was recorded in 1 patient, which may have been caused by nerve injury. Potential early complications, including pneumothorax, air embolism or arterial puncture may be fatal, but these did not occur in the present study (40,41).

In conclusion, low complication rates of TICVPS insertion were observed in the present, large, retrospective study. Complication rates may be reduced by using a well-designed procedure, experienced vascular surgeons, an aseptic

environment, ultrasound-guided puncture and fluoroscopy with contrast media.

### Acknowledgements

The content of this study was previously presented at the 17th Congress of the Asian Society for Vascular Surgery, 11th Asian Venous Forum, 20-23 October 2016 in Singapore. The abstract was published in the *Annals of Vascular Diseases*, Volume 9 (2016), issue supplement pages S1-S160.

### Funding

No funding received.

### Availability of data and materials

The datasets used and/or analyzed during the current study are available from the corresponding author on reasonable request.

### Authors' contributions

SSL and HJJ devised the project, the main conceptual ideas and proof outline. DHK and DYR collected and analyzed patients' data. DHK and DYR wrote the manuscript in consultation with SSL and HJJ. The final version of the manuscripts has been read and approved by all authors, and each author believes that the manuscript represents honest work.

### Ethics approval and consent to participate

Not applicable.

### Patient consent for publication

Not applicable.

### Competing interests

The authors declare that they have no competing interests.

### References

1. Niederhuber JE, Ensminger W, Gyves JW, Liepman M, Doan K and Cozzi E: Totally implanted venous and arterial access system to replace external catheters in cancer treatment. *Surgery* 92: 706-712, 1982.
2. Kock HJ, Pietsch M, Krause U, Wilke H and Eigler FW: Implantable vascular access systems: Experience in 1500 patients with totally implanted central venous port systems. *World J Surg* 22: 12-16, 1998.
3. Schenck M and Jäger T: What is practically important when carrying out a chemotherapy? *Urologe A* 45: 572, 574-576, 578-579, 2006 (In German).
4. Broviac JW, Cole JJ and Scribner BH: A silicone rubber atrial catheter for prolonged parenteral alimentation. *Surg Gynecol Obstet* 136: 602-606, 1973.
5. Hickman RO, Buckner CD, Clift RA, Sanders JE, Stewart P and Thomas ED: A modified right atrial catheter for access to the venous system in marrow transplant recipients. *Surg Gynecol Obstet* 148: 871-875, 1979.
6. Torramadé JR, Cienfuegos JA, Hernández JL, Pardo F, Benito C, González J, Balén E and de Villa V: The complications of central venous access systems: A study of 218 patients. *Eur J Surg* 159: 323-327, 1993.

7. Biffi R, de Braud F, Orsi F, Pozzi S, Mauri S, Goldhirsch A, Nolè F and Andreoni B: Totally implantable central venous access ports for long-term chemotherapy. A prospective study analyzing complications and costs of 333 devices with a minimum follow-up of 180 days. *Ann Oncol* 9: 767-773, 1998.
8. Funaki B and Zaleski GX: Re: Long-term follow-up of upper extremity implanted venous access devices in oncology patients. *J Vasc Interv Radiol* 10: 1281, 1999.
9. Teichgräber UK, Gebauer B, Benter T and Wagner J: Long-term central venous lines and their complications. *Rofo* 176: 944-952, 2004.
10. Yeste Sánchez L, Galbis Caravajal JM, Fuster Diana CA and Moledo Eiras E: Protocol for the implantation of a venous access device (Port-A-Cath System). The complications and solutions found in 560 cases. *Clin Transl Oncol* 8: 735-741, 2006.
11. Yaacob Y, Nguyen DV, Mohamed Z, Ralib AR, Zakaria R and Muda S: Image-guided chemoport insertion by interventional radiologists: A single-center experience on periprocedural complications. *Indian J Radiol Imaging* 23: 121-125, 2013.
12. McGee DC and Gould MK: Preventing complications of central venous catheterization. *N Engl J Med* 348: 1123-1133, 2003.
13. Beheshti MV: A concise history of central venous access. *Tech Vasc Interv Radiol* 14: 184-185, 2011.
14. Dede D, Akmangit I, Yildirim ZN, Sanverdi E and Sayin B: Ultrasonography and fluoroscopy-guided insertion of chest ports. *Eur J Surg Oncol* 34: 1340-1343, 2008.
15. Di Carlo I, Pulvirenti E, Mannino M and Toro A: Increased use of percutaneous technique for totally implantable venous access devices. Is it real progress? A 27-year comprehensive review on early complications. *Ann Surg Oncol* 17: 1649-1656, 2010.
16. Sakamoto N, Arai Y, Takeuchi Y, Takahashi M, Tsurusaki M and Sugimuta K: Ultrasound-guided radiological placement of central venous port via the subclavian vein: A retrospective analysis of 500 cases at a single institute. *Cardiovasc Intervent Radiol* 33: 989-994, 2010.
17. Teichgräber UK, Kausche S, Nagel SN and Gebauer B: Outcome analysis in 3,160 implantations of radiologically guided placements of totally implantable central venous port systems. *Eur Radiol* 21: 1224-1232, 2011.
18. Ahn SJ, Kim HC, Chung JW, An SB, Yin YH, Jae HJ and Park JH: Ultrasound and fluoroscopy-guided placement of central venous ports via internal jugular vein: Retrospective analysis of 1254 port implantations at a single center. *Korean J Radiol* 13: 314-323, 2012.
19. Goltz JP, Janssen H, Petritsch B and Kickuth R: Femoral placement of totally implantable venous power ports as an alternative implantation site for patients with central vein occlusions. *Support Care Cancer* 22: 383-387, 2014.
20. Kim HJ, Yun J, Kim HJ, Kim KH, Kim SH, Lee SC, Bae SB, Kim CK, Lee NS, Lee KT, *et al*: Safety and effectiveness of central venous catheterization in patients with cancer: Prospective observational study. *J Korean Med Sci* 25: 1748-1753, 2010.
21. Kumar AH, Srinivasan NM, Thakkar JM and Mathew S: A prospective observational study of the outcome of central venous catheterization in 100 patients. *Anesth Essays Res* 7: 71-75, 2013.
22. Babu KG, Suresh Babu MC, Lokanatha D and Bhat GR: Outcomes, cost comparison, and patient satisfaction during long-term central venous access in cancer patients: Experience from a Tertiary Care Cancer Institute in South India. *Indian J Med Paediatr Oncol* 37: 232-238, 2016.
23. Son JT, Min SY, Kim JI, Choi PW, Heo TG, Lee MS, Kim CN, Kim HY, Yi SY, Lee HR and Roh YN: Thrombolytic therapy using urokinase for management of central venous catheter thrombosis. *Vasc Specialist Int* 30: 144-150, 2014.
24. Schenck M, Schneider T, Rubben H and Eisenhardt A: Central venous port implantations via the cephalic vein applying an intravasal electrographic control of the catheter tip position: A single-center experience of 316 cases. *World J Urol* 30: 399-404, 2012.
25. Bishop L, Dougherty L, Bodenham A, Mansi J, Crowe P, Kibbler C, Shannon M and Treleaven J: Guidelines on the insertion and management of central venous access devices in adults. *Int J Lab Hematol* 29: 261-278, 2007.
26. Brothers TE, Von Moll LK, Niederhuber JE, Roberts JA, Walker-Andrews S and Ensminger WD: Experience with subcutaneous infusion ports in three hundred patients. *Surg Gynecol Obstet* 166: 295-301, 1988.
27. Whitman ED: Complications associated with the use of central venous access devices. *Curr Probl Surg* 33: 309-378, 1996.
28. Harish K: Chemoport-skin erosion: Our experience. *Int J Angiol* 23: 215-216, 2014.
29. Almhanna K, Pelley RJ, Thomas Budd G, Davidson J and Moore HC: Subcutaneous implantable venous access device erosion through the skin in patients treated with anti-vascular endothelial growth factor therapy: A case series. *Anticancer Drugs* 19: 217-219, 2008.
30. Lee AY: Cancer and thromboembolic disease: Pathogenic mechanisms. *Cancer Treat Rev* 28: 137-140, 2002.
31. Chelmow D, Rodriguez EJ and Sabatini MM: Suture closure of subcutaneous fat and wound disruption after cesarean delivery: A meta-analysis. *Obstet Gynecol* 103: 974-980, 2004.
32. Hertault A, Sobocinski J, Spear R, Azzaoui R, Delloye M, Fabre D and Haulon S: What should we expect from the hybrid room? *J Cardiovasc Surg (Torino)* 58: 264-269, 2017.
33. Frank DA, Meuse J, Hirsch D, Ibrahim JG and van den Abbeele AD: The treatment and outcome of cancer patients with thromboses on central venous catheters. *J Thromb Thrombolysis* 10: 271-275, 2000.
34. Verso M and Agnelli G: Venous thromboembolism associated with long-term use of central venous catheters in cancer patients. *J Clin Oncol* 21: 3665-3675, 2003.
35. Biffi R, Orsi F, Pozzi S, Pace U, Bonomo G, Monfardini L, Della Vigna P, Rotmensz N, Radice D, Zampino MG, *et al*: Best choice of central venous insertion site for the prevention of catheter-related complications in adult patients who need cancer therapy: A randomized trial. *Ann Oncol* 20: 935-940, 2009.
36. Saber W, Moua T, Williams EC, Verso M, Agnelli G, Couban S, Young A, De Cicco M, Biffi R, van Rooden CJ, *et al*: Risk factors for catheter-related thrombosis (CRT) in cancer patients: A patient-level data (IPD) meta-analysis of clinical trials and prospective studies. *J Thromb Haemost* 9: 312-319, 2011.
37. Di Carlo I, Cordio S, La Greca G, Privitera G, Russello D, Puleo S and Latteri F: Totally implantable venous access devices implanted surgically: A retrospective study on early and late complications. *Arch Surg* 136: 1050-1053, 2001.
38. Araujo C, Silva JP, Antunes P, Fernandes JM, Dias C, Pereira H, Dias T and Fougo JL: A comparative study between two central veins for the introduction of totally implantable venous access devices in 1201 cancer patients. *Eur J Surg Oncol* 34: 222-226, 2008.
39. Safdar N and Maki DG: Risk of catheter-related bloodstream infection with peripherally inserted central venous catheters used in hospitalized patients. *Chest* 128: 489-495, 2005.
40. Ballarini C, Intra M, Pisani Ceretti A, Cordovana A, Pagani M, Farina G, Perrone S, Tomirotti M, Scanni A and Spina GP: Complications of subcutaneous infusion port in the general oncology population. *Oncology* 56: 97-102, 1999.
41. Wolosker N, Yazbek G, Nishinari K, Malavolta LC, Munia MA, Langer M and Zerati AE: Totally implantable venous catheters for chemotherapy: Experience in 500 patients. *Sao Paulo Med J* 122: 147-151, 2004.



This work is licensed under a Creative Commons Attribution-NonCommercial-NoDerivatives 4.0 International (CC BY-NC-ND 4.0) License.