

Pedicle screw placement in patients with variant atlas pedicle

Qiang-Hua Zhang, Hai-Dong Li and Ji-Kang Min

Abstract

Objective: To investigate how the anatomy of variant atlas vertebra impacts on the strategy used to place pedicle screws used to treat atlantoaxial instability.

Methods: The study enrolled patients with cervical instability who had a posterior arch pedicle height <3.5 mm at the anchor point, a vertebral artery groove height <3.5 mm, or both. Pedicle screws were fitted according to the anatomy of the variant atlas vertebra. Patients were followed-up to evaluate accuracy of the screw placement and maintenance of cervical stability.

Results: A total of 28 patients were enrolled. The mean height of the atlas pedicle proximal section was >5.0 mm. For the vertebral artery groove, the height of the lateral region was significantly greater than that of the medial region. Approximately 60% of atlas vertebrae had lateral heights >3.5 mm (34 of 56). The majority of the posterior arch heights were <3.0 mm. There were no perioperative or postoperative complications observed.

Conclusions: Pedicle screw placement in the lateral pedicle region is the safest and most reliable strategy to treat variant atlas pedicles.

Keywords

Atlas, pedicle, screw, image, anatomy, cervical disorder

Date received: 29 November 2015; accepted: 15 March 2016

Introduction

Since the atlas pedicle screw fixation technique was first introduced, it has been widely applied in clinical practice to treat a variety of cervical instabilities.¹ The popularity of the technique is due to its various advantages compared with transarticular screw fixation, such as three-dimensional stability, short segment fixation, and elimination of preoperative anatomical reduction.^{2,3} The majority of inserted atlas pedicle screws have a diameter

of 3.5 mm, so this measurement was used in the current study as the standard to gauge which cases would be eligible for treatment.

Department of Orthopaedics, First People's Hospital of Huzhou City, Huzhou City, Zhejiang Province, China

Corresponding author:

Ji-Kang Min, Department of Orthopaedics, First People's Hospital of Huzhou City, Huzhou City, Zhejiang Province 313000, China.

Email: jikang.min@aol.com



Variant atlas occurs when the height of the atlas pedicle arch, the vertebral artery groove, or both measure less than 3.5 mm.⁴ Because the distance is less than the standard diameter of the pedicle screws, screw insertion would be very difficult for patients with variants in the atlas vertebra. Previous studies reported an incidence rate of 10.0%–32.7% for patients diagnosed with variant atlas.^{5,6} It has been suggested that atlas pedicle screws should not be used when the height of the posterior arch pedicle at the anchor point or the height of the vertebral artery groove and the atlas posterior arch is less than 4 mm.⁷ The ‘pedicle exposure method’ has been suggested as a suitable technique for patients with posterior arch heights that are less than 4 mm.⁸ However, screw placement in these cases is largely uncertain due to the lack of systematic research on the anatomy of variant atlas pedicles.

The present study used imaging techniques to investigate the anatomy of variant atlas vertebra where the posterior arch height and vertebral artery groove height were less than 3.5 mm. The imaging results facilitated the evaluation of both the feasibility of and the strategy to use when placing pedicle screws used to stabilize the vertebra in patients with atlantoaxial instability.

Patients and methods

Study population

This retrospective study considered all consecutive patients with cervical instability caused by a variety of reasons who were admitted to the Department of Orthopaedics, First People’s Hospital of Huzhou City, Huzhou City, Zhejiang Province, China between January 2005 and January 2011. X-ray and computed tomography (CT) imaging data were collected preoperatively and at final follow-up. The inclusion criteria were as follows: patients with cervical instability who had a posterior arch pedicle height <3.5 mm at the anchor

point, a vertebral artery groove height <3.5 mm, or both. Patients with previous cervical surgery were excluded.

All procedures performed in this study were undertaken in accordance with the Declaration of Helsinki. This study was approved by the Ethics Committee of the First People’s Hospital of Huzhou City (no. 2005–02). Verbal informed consent was obtained from all patients.

Atlas pedicle imaging methods

Cervical lateral X-ray (ProGrade; Philips, Amsterdam, the Netherlands), thin CT scan three-dimensional reconstruction, and vertebral artery CT angiography (CTA) (SOMATOM Sensation 64; Siemens, Erlangen, Germany) examinations were performed on each patient. Magnetic resonance imaging (Ingenia 1.5 T; Philips) was also used to evaluate cervical instability preoperatively. All radiographic parameters were evaluated on the preoperative, postoperative, and last follow-up radiographs. Postoperative X-ray and three-dimensional CT reconstruction were performed on all patients at 6 months postoperation. Patients were contacted directly by healthcare personnel in order to review their postoperative outcomes.

In the CT reconstruction images, the atlas pedicle was divided into three cross sections, from the back to the front based on the direction of the pedicle screw path: the surface of the atlas posterior arch (D1), the vertebral artery groove (D2), and the base of the pedicle proximal block (D3). Images of the coronal regions of each pedicle cross section were obtained in the reconstructed CT scans. The pedicle was divided into lateral and medial regions. The maximum pedicle medial height (H1) and lateral height (H2) were measured for these three sections taken from the coronal CT reconstruction images. Based on the measurements, the types of atlas pedicles were categorized by the height

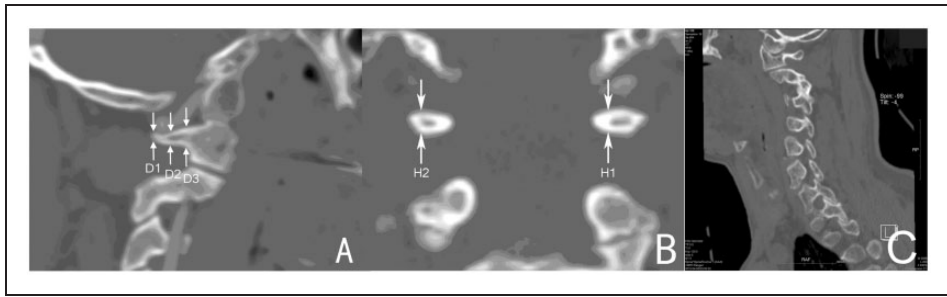


Figure 1. Representative reconstruction computed tomography (CT) scans of atlas pedicles and preoperative height measurements of each cross section. (A) Schematic diagram of the sagittal atlas pedicle division and the cross sections where height measurements were obtained. Arrows and labels indicate the following sections: the surface of the posterior arch (D1), the vertebral artery groove (D2), and the root of the proximal pedicle block (D3). (B) Schematic diagram of the coronal vertebral artery groove and the locations of the pedicle height measurements. Arrows and labels indicate the following structures: the maximum medial height of the cross section (H1) and the maximum lateral height of the cross section (H2). (C) Representative real CT image.

and morphologies of the different regions (Figure 1).

Classification of variant atlas pedicles and screw placement strategies

Depending on the preoperative height measurement of the various atlas pedicle regions, the variant atlas pedicles were divided into three types. Patients classified as type I had a posterior arch height <3.5 mm and a vertebral artery groove height >3.5 mm, and the screws were placed under the posterior arch. Specifically, the pedicle screws were inserted into the lateral mass through the vertebral artery groove and into the base of the pedicle proximal block. For patients classified as type II, both the posterior arch height and the vertebral artery groove height were <3.5 mm. Screws were placed at the junction of the pedicle lateral mass. The pedicle screws penetrated into the lateral mass through the junction of the pedicle proximal block. Patients with a type III placement, where the posterior arch height was >3.5 mm and the vertebral artery groove height was <3.5 mm, received an ‘in-out-in’ screw placement technique. The venous

plexus was pushed aside during nerve dissection, and the vertebral artery groove was clearly concave, so the posterior arch was drilled with a special mini-driller to line the screw channel up to the atlas lateral mass by the ‘notch’ technique. This process may cause perforation in the lower edge of the posterior arch, but the postoperative CT scan may not show this clearly due to the metal artefacts of the screw. The pedicle screws penetrated into the lateral mass at the junction of the pedicle proximal block, after going through the surface of the pedicle posterior arch and across the vertebral artery groove (Figure 2).

Statistical analyses

All statistical analyses were performed using the SPSS[®] statistical package, version 17.0 (SPSS Inc., Chicago, IL, USA) for Windows[®]. Atlas pedicle height measurements are expressed as mean \pm SD. Comparisons were made using the paired Student’s *t*-test. All data were fitted into normal distribution patterns using a normality test. A *P*-value <0.05 was considered statistically significant.

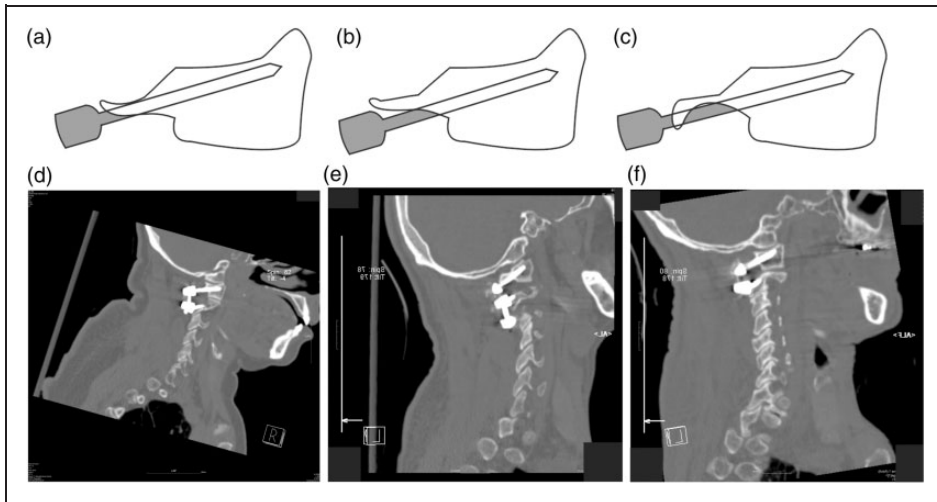


Figure 2. Pedicle height measurements identify three potential regions for atlas pedicle screw placement. Depending on the preoperative height measurements, atlas pedicle screws were placed under the posterior arch (type I) (A), at the junction of the pedicle lateral mass (type II) (B), or spanning the vertebral artery groove and penetrating into the pedicle lateral mass using an 'in-out-in' technique (type III) (C). The postoperative computed tomography scans corresponding to the three types of screw placement, (D–F), respectively.

Results

A total of 225 patients with cervical instability caused by a variety of reasons were admitted to the Department of Orthopaedics, First People's Hospital of Huzhou City during the study period. Of these, 28 (12.4%) had a posterior arch pedicle with a height at the anchor point <3.5 mm, a height of the vertebral artery groove <3.5 mm, or both. These 28 patients were enrolled in the study (11 men and 17 women; age range 18–75 years; mean \pm SD age 36.2 ± 15.5 years). Seventeen of the 28 patients had upper cervical congenital malformation, including 13 patients with congenital free dens, three patients with odontoid maldevelopment, and one patient with odontoid agenesis. Nine patients had old odontoid fractures with atlantoaxial dislocation and two patients had rheumatoid atlantoaxial dislocation. The clinical symptoms included varying degrees of occipital pain and movement limitation.

Sixteen patients had varying degrees of limb sensory and/or motor dysfunction.

Of the 28 patients enrolled in the study, a total of 56 variant atlas pedicles were reported. The variant atlas pedicles were divided into three types: 34 pedicles were classified as type I, 18 pedicles were classified as type II, and four pedicles were classified as type III.

Measurements were taken from the CT reconstructive images to design pedicle screw placement strategies. The atlas lateral mass near the root section (D3) was the thickest, with a mean pedicle height >5.0 mm. There were no significant differences between the pedicle heights of the medial and lateral regions (H1D3 versus H2D3) (Table 1). The atlas pedicle height at the lateral cross section of the vertebral artery groove was relatively thick, and the maximum lateral height at the cross section (H2D2) was significantly greater than the maximum medial height in the same

Table 1. Comparison of medial and lateral pedicle height measurements in 28 patients (56 variant atlas pedicles) with cervical instability receiving atlas pedicle screws.

	Pedicle proximal block at the root (D3), mm	Vertebral artery groove (D2), mm	Surface of posterior arch (D1), mm
H1	5.12 ± 0.30	2.61 ± 0.26	2.85 ± 0.27
H2	5.20 ± 0.27	3.24 ± 0.25	2.95 ± 0.30
Statistical analysis ^a	NS	$P < 0.01$	NS

Data are presented as mean ± SD.

^aStudent's *t*-test.

H1, pedicle medial maximum height of the cross section; H2, pedicle lateral maximum height of the cross section; NS, no significant difference ($P \geq 0.05$).

area (H1D2) ($P < 0.01$). The H2D2 heights > 3.5 mm accounted for 60.7% (34 of 56) of the patients, and H2D2 heights of 3.0–3.5 mm accounted for 32.1% (18 of 56) of the patients. A relatively small percentage of patients (7.1%; four of 56) demonstrated H2D2 heights of < 3.0 mm. All measurements of the vertebral artery groove medial maximum height (H1D2) were < 3.0 mm. The height of the posterior arch surface (D1) was < 3.0 mm for all atlas pedicles, except for four pedicles that were > 3.5 mm. No significant differences were found between the H1D1 and H2D1.

Appropriate pedicle screw placement strategies were implemented for the 28 patients diagnosed with variant atlas pedicles. For type I, 34 pedicle screws were placed successfully under the posterior arch. For type II, 18 pedicle screws were placed at the junction of the pedicle lateral mass. For type III, four pedicle screws were placed using the 'in-out-in' technique. For both types II and III, a lamina hook was used for one pedicle due to perioperative blood loss. The total success rate of pedicle screw fixation was 96.4% (54 of 56). An example case study of the treatment of a patient with a type I variant atlas pedicle is shown in Figure 3.

Postoperative X-ray and three-dimensional CT reconstruction were performed on all patients. All radiographic parameters

were evaluated on the preoperative, postoperative, and last follow-up radiographs. The accuracy of atlas pedicle screw placement was evaluated according to previously described criteria.⁹ Ideal pedicle screw placement was achieved when the pedicle screw was completely within the bone cortex. Acceptable pedicle screw placement was achieved when the invasion of the pedicle screw penetrated into the surrounding cortex, was less than half of the screw diameter, and protruded into the front cortex < 1.0 mm. Unacceptable pedicle screw placement was when there was an obvious invasion by the pedicle screw into the transverse foramen or vertebral tube, regardless of the clinical neurovascular complications. For the 56 variant atlas pedicles evaluated in this present study, 54 pedicle screws were successfully inserted. Of these, 47 of 54 (87.0%) were ideally placed, five of 54 (9.3%) had acceptable placement and two of 54 (3.7%) had unacceptable placement. Pedicle screw placement was aborted for two pedicles due to perioperative bleeding and other fixation methods were used instead.

Perioperative vertebral artery injuries, nerve root damage or posterior arch fractures were not observed in any patients in the present study. No postoperative vertebral artery injury, spinal cord injury and other complications were observed.

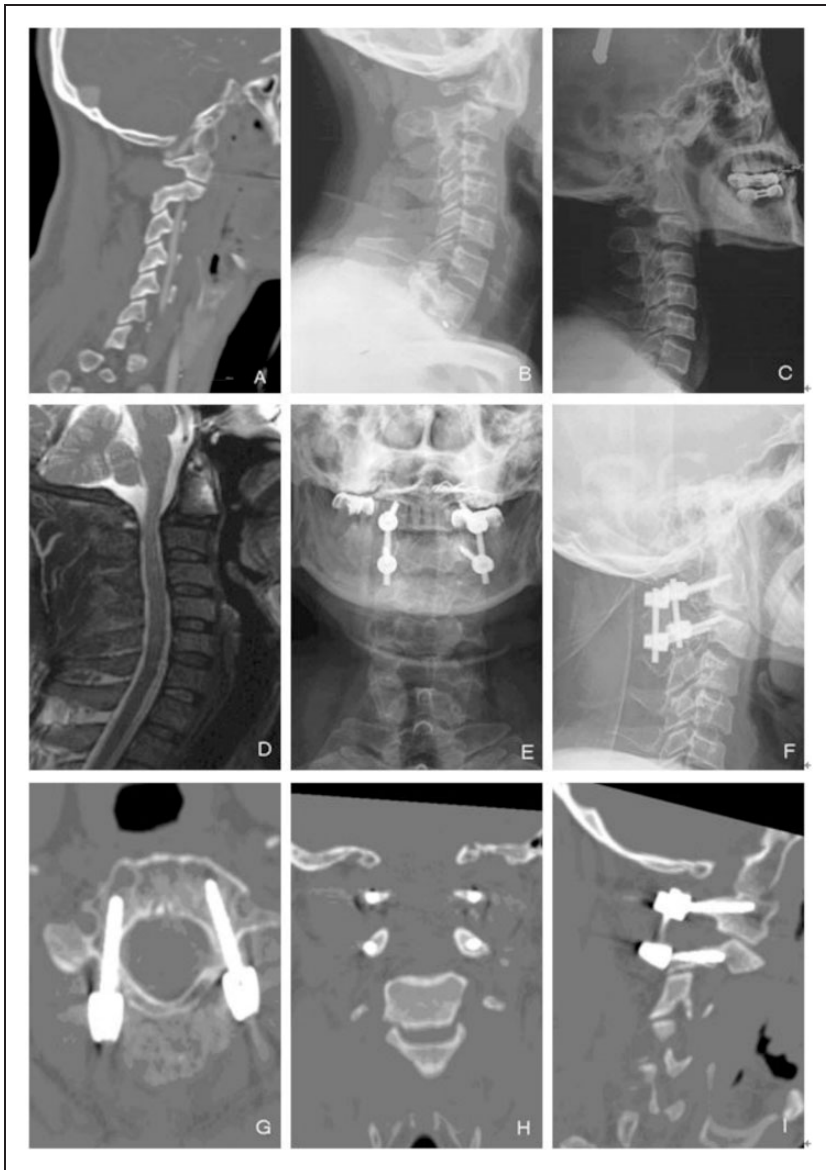

Figure 3. An example case study demonstrating a type I pedicle screw placement. A 47-year-old male patient presented with malformations of the C1 and C2 vertebrae, abnormal fusion, and atlantoaxial dislocation. Posterior relocation was achieved by fusing the atlantoaxial pedicle using fixed screws. (A) A preoperative sagittal computed tomography (CT) scan showed the height of the atlas posterior arch surface (2.5 mm; D1), as well as the height of the vertebral artery groove (3.7 mm; D2). (B) A lateral X-ray illustrated the C1 and C2 malformations, as well as the atlantoaxial dislocation. (C) Preoperative X-ray review after selecting the illustrated atlantoaxial relocation strategy (type I pedicle screw placement). (D) Magnetic resonance imaging scan showed cervical abnormality and instability, as well as partial bone contusions. (E, F) Postoperative lateral X-rays illustrated that the atlantoaxial dislocation was reset, and the pedicle screw fixation was successful. (G) A postoperative axial CT scan illustrated that the atlas pedicle screw was placed accurately. (H) A postoperative coronal CT scan showed that the atlas pedicle screw was located at the cross section of the lateral pedicle. (I) A postoperative sagittal CT scan illustrated that the pedicle screw placement was under the posterior arch.

Postoperative clinical symptoms were relieved to varying degrees. Two patients showed occipital nerve irritation postoperatively: one patient with postoperative clinical symptoms was relieved after symptomatic treatment, and the other patient improved after the removal of the fixation upon atlantoaxial fusion.

Follow-up examinations were undertaken for all patients in the present study. The mean \pm SD follow-up period was 26 ± 7.5 months (range 18–36 months). No pedicle screws were loose, shifted, or fractured, and there were no atlantoaxial re-dislocations observed at the last follow-up visit. According to follow-up CT scans at 6 months postoperation, the fusion rate was 100% (56 of 56). One patient showed graft absorption after 6 months and fused after receiving a secondary autologous ilium bone graft.

Discussion

The atlas pedicle screw fixation technique is an important method for the treatment of upper cervical spine instability.³ Research has shown that the pedicle screw fixation method is superior to atlas lateral mass screw placement in terms of the amount of perioperative blood loss, operation time and risks.¹⁰ It should be the preferred method for atlas posterior pedicle screw placement. Theoretically, due to the impact of the anatomical structure of the atlas pedicle and the adjacent tissue, the success of screw placement is mainly affected by the atlas pedicle diameter (width) and height.⁴ For example, previous studies have shown that an atlas pedicle width of approximately 7.0 mm is enough to accommodate the placement of a 3.5 mm diameter screw.^{11–14} Therefore, for the variant atlas vertebra, the pedicle height is the major limiting factor of pedicle screw placement.

When the pedicle height at the entry point and/or the vertebral artery groove height are

less than 3.5–4.0 mm, the risk and difficulty of placing a 3.5 mm-diameter pedicle screw will increase greatly.³ An atlas with a pedicle height <3.5 mm is referred to as a variant atlas.⁴ It was reported that an atlas with a vertebral artery groove height >4 mm accounted for 8% of the reported cases of variant atlas.⁶ It was observed that at least 32.7% of cases reported vertebral artery groove heights <3.5 mm.⁵ In this present study, a total of 28 cases had a posterior arch height at the entry point or a vertebral artery groove height <3.5 mm, or both; and they accounted for 12.4% of the 225 patients admitted for cervical instability during the 6-year study period.

Pedicle screws have been successfully placed in patients with atlas posterior arch heights >4.0 mm using the 'pedicle exposure method'.⁸ Some studies on pedicle screw placement were conducted by simulating the status of the atlas pedicle heights that were ≤ 3.5 mm.^{4,13,14} The results showed that when the pedicle height was 3.0–3.5 mm, pedicle screw placement could still be successful as long as the head angle was adjusted appropriately.³ However, because of the complexity and variability of atlas pedicles and the anatomical structure of the adjacent tissue, the value of a simple simulation study to clinical practice is severely limited. To date there has been no applied anatomical study on variant atlas pedicle morphology. In this present study, the atlas pedicle was divided into three coronal sections and their heights measured: the posterior arch surface, the bottom surface of the vertebral artery groove and the adjacent proximal block surface. Since pedicle proximal block surface height was not less than 3.5 mm for all variant atlases examined, the variant atlas were divided into the following three types: type I had a posterior arch height <3.5 mm and a vertebral artery groove height >3.5 mm; type II had a posterior arch height and a vertebral artery groove height <3.5 mm; and type III had a

posterior arch height >3.5 mm and a vertebral artery groove height <3.5 mm. Using 3.5-mm diameter pedicle screw as standard, three corresponding pedicle screw placement methods were developed (Figure 2).

The three coronal sections of the pedicle were further divided into two regions: the medial and the lateral. It was found that on the adjacent side block surface and the posterior arch surface, there was no significant difference between the medial and lateral pedicle heights. On the bottom surface of the vertebral artery groove, the lateral pedicle height (H2D2) was significantly greater than the medial region (H1D2). Approximately 60% of patients had lateral pedicle heights >3.5 mm, and approximately 32% of patients had lateral pedicle heights of 3.0–3.5 mm. These results suggested that for type I and III pedicles, the pedicle screw entry point should be chosen in the lateral region. For type II pedicles, both lateral and medial regions were safe for pedicle screw placement, since the pedicle height of the adjacent side block was >5.0 mm in both the inner and outer regions.

Of the 56 pedicle screws that were attempted, 54 (96.4%) were successfully placed. Pedicle screw placement was aborted for two pedicles due to perioperative bleeding. The status of the atlas pedicle screw placement was evaluated through post-operative X-ray and CT examination: 87.0% (47 of 54) were ideally placed; 9.3% (five of 54) were acceptably placed; and 3.7% (two of 54) had unacceptable placements. The two pedicle screws that had unacceptable placements were placed on the right side and penetrated the spinal canal. The surgeon was operating on the patient's left side, and the right pedicle screw placement point was not revealed sufficiently. This caused the screw entry point to slant inward.

This present study had a number of limitations. First, the sample size was small

and the study was retrospective. Secondly, the factor of race was not considered as the study was only conducted in Chinese patients. Thirdly, the study had a relatively short follow-up period. These findings should be confirmed in larger, prospective studies with longer follow-up periods in order to evaluate the long-term effect on cervical stability.

In conclusion, in our opinion, attention should be paid to the following areas during variant atlas pedicle screw placement surgery: (i) the surface of the atlas posterior arch and the lower edge of the posterior arch should be conventionally exposed. A necessary check should be conducted using a neural stripper to determine the pedicle head tilt; (ii) an abrasion drill (2.0-mm diameter) is suitable for making the decorticate openings during screw penetration; (iii) the screw penetration path should make use of the elasticity and expansion of the bone tissue. In case of resistance, the direction must be adjusted, and the screw path should be explored using a probe. If the surroundings are a wall of bone, drilling may continue; (iv) the screw should be fixed principally at the lower region and the upper region avoided; and (v) it is recommended to perform pedicle screw placement under fluoroscopic monitoring of the 'C' arm when necessary. When these suggestions were followed and imaging was used to inform the surgical strategies in the present study, pedicle screw fixation could successfully treat variant atlas pedicles. These preliminary findings should help guide clinical practice on pedicle screw placement for variant atlas pedicles.

Authors' contributions

Q.H.Z. carried out the imaging studies, participated in the data analysis and drafted the manuscript. Q.H.Z., H.D.L. and J.K.M. conceived of the study, participated in the design of the study and performed the statistical analyses. All authors read and approved the final manuscript.

Acknowledgements

The authors would like to thank the research staff and clinical personnel at the participating hospital for their outstanding performance and patient care. The authors thank Clarity Manuscript Consultant LLC for language editing and technical support.

Declaration of conflicting interest

The authors declare that there are no conflicts of interest.

Funding

This research received no specific grant from any funding agency in the public, commercial, or not-for-profit sectors.

References

1. Resnick DK and Benzel EC. C1-C2 pedicle screw fixation with rigid cantilever beam construct: case report and technique note. *Neurosurgery* 2002; 50: 426–428.
2. Lapsiwala SB, Anderson PA, Oza A, et al. Biomechanical comparison of four C1 to C2 rigid fixative techniques: anterior transarticular, posterior transarticular, C1 to C2 pedicle, and C1 to C2 intralaminar screws. *Neurosurgery* 2006; 58: 516–521.
3. Kuroki H, Rengachary SS, Goel VK, et al. Biomechanical comparison of two stabilization techniques of the atlantoaxial joints: transarticular screw fixation versus screw and rod fixation. *Neurosurgery* 2005; 56(1 Suppl): 151–159.
4. He F, Yin Q and Zhao T. Classification of atlas pedicles and methodological study of pedicle screw fixation. *Zhongguo Xiu Fu Chong Jian Wai Ke Za Zhi* 2008; 22: 905–909. [in Chinese, English Abstract].
5. Lee MJ, Cassinelli E and Riew KD. The feasibility of inserting atlas lateral mass screws via the posterior arch. *Spine (Phila Pa 1976)* 2006; 31: 2798–2801.
6. Tan M, Wang H, Wang Y, et al. Morphometric evaluation of screw fixation in atlas via posterior arch and lateral mass. *Spine (Phila Pa 1976)* 2003; 28: 888–895.
7. Ma XY, Yin QS, Wu ZH, et al. Anatomic considerations for the pedicle screw placement in the first cervical vertebra. *Spine (Phila Pa 1976)* 2005; 30: 1519–1523.
8. Tan M, Dong L, Wang W, et al. Clinical application of the “pedicle exposure technique” for atlantoaxial instability patients with a narrow c1 posterior arch. *J Spinal Disord Tech* 2015; 28: 25–30.
9. Bransford RJ, Freeborn MA, Russo AJ, et al. Accuracy and complications associated with posterior C1 screw fixation techniques: a radiographic and clinical assessment. *Spine J* 2012; 12: 231–238.
10. Ma XY, Yin QS, Wu ZH, et al. C1 pedicle screws versus C1 lateral mass screws: comparisons of pullout strengths and biomechanical stabilities. *Spine (Phila Pa 1976)* 2009; 34: 371–377.
11. Gebauer M, Barvencik F, Briem D, et al. Evaluation of anatomic landmarks and safe zones for screw placement in the atlas via the posterior arch. *Eur Spine J* 2010; 19: 85–90.
12. Young JP, Young PH, Ackermann MJ, et al. The ponticulus posticus: implications for screw insertion into the first cervical lateral mass. *J Bone Joint Surg Am* 2005; 87: 2495–2498.
13. Blagg SE, Don AS and Robertson PA. Anatomic determination of optimal entry point and direction for C1 lateral mass screw placement. *J Spinal Disord Tech* 2009; 22: 233–239.
14. Christensen DM, Eastlack RK, Lynch JJ, et al. C1 anatomy and dimensions relative to lateral mass screw placement. *Spine (Phila Pa 1976)* 2007; 32: 844–848.