



## Frequency, characteristics and outcomes of appendicular neuroendocrine tumors: A cross-sectional study from an academic tertiary care hospital



Abdelrahman Abdelaal<sup>a, \*</sup>, Walid El Ansari<sup>a</sup>, Issam Al-Bozom<sup>b</sup>, Mahwish Khawar<sup>a</sup>,  
Fakhar Shahid<sup>a</sup>, Ammar Aleter<sup>a</sup>, Mohammed Rasoul Abunuwar<sup>a</sup>, Ayman El-Menyar<sup>a</sup>

<sup>a</sup> Departments of Surgery, Hamad General Hospital, Doha, Qatar

<sup>b</sup> Departments of Pathology, Hamad General Hospital, Doha, Qatar

### ARTICLE INFO

#### Article history:

Received 17 May 2017

Received in revised form

16 July 2017

Accepted 17 July 2017

#### Keywords:

Carcinoid

Appendectomy

Appendix

Neuroendocrine tumor

### ABSTRACT

**Background:** Appendicular neuroendocrine tumors (NET, Carcinoid tumors) of the appendix are rare and mostly diagnosed incidentally on the post-operative histopathological examination. NET are usually associated with good 5-year survival rates. We aimed to assess our experience for the diagnosis and management of NET over 11 years.

**Method:** It is a retrospective chart review of all clinically suspected patients with acute appendicitis who underwent emergent appendectomy with intention to treat between January 2004–December 2014, and were clinically followed up until 2016.

**Results:** During the study period, a total of 13641 patients underwent emergency appendectomy, of which 32 were histologically confirmed NET. The mean age of the NET cases was  $25.3 \pm 7.9$  years; 78% were males and all were clinically presented with acute appendicitis. The mean leucocyte was  $15 \pm 14 \times 10^9$  per Liter, and mean tumor size was  $4.86 \pm 3.18$  (ranged 1.5–13) mm. The median length of hospital stay was 4 (2–15) days. One patient had right hemicolectomy; diagnosed with right colonic cancer with NET being an incidental finding as part of histopathological assessment. Another patient required a second stage procedure; he was diagnosed as goblet cell carcinoid with positive margin. None of the patients died 30-day postoperatively and all of them survived on clinical follow-up that ranged between 2 and 13 years.

**Conclusion:** Carcinoid tumors of the appendix are rare and typically diagnosed incidentally. Detailed examination of routine appendectomy specimens is the key for diagnosis. Simple appendectomy suffices for tumors <2 cm for adequate clearance. Appendicular carcinoid tumors are associated with good long-term outcomes.

© 2017 The Author(s). Published by Elsevier Ltd on behalf of IJS Publishing Group Ltd. This is an open access article under the CC BY-NC-ND license (<http://creativecommons.org/licenses/by-nc-nd/4.0/>).

### 1. Introduction

Appendicular Neuroendocrine tumors (NET) are neoplasms of the appendicular sub-epithelial neuroendocrine cells [1]; the majority of which are benign and rarely metastasize. NET comprises the most common neoplasm of the appendix [2]. Nevertheless, NET are rare neuroendocrine neoplasms that are encountered incidentally in 1 out of 200–300 appendectomies [3]. The scarcity of NET has been demonstrated globally for instance 0% incidence in Saudi

Arabia (2011–2014) [4]; 0.48% in Tunisia (1995–2001) [5]; and 0.45% in Turkey [6].

NET demonstrate no specific clinical presentation [2], being generally asymptomatic; or present as acute appendicitis, where NET are diagnosed incidentally after appendectomy [7,8]. Most NET are located at the tip of the appendix. They are usually minute, measuring <1 cm, and rarely grow >2 cm in diameter [9]. Whilst NET customarily behaves as benign, they have the prospect for malignancy [10]. Still, the long-term prognosis of incidental NET is good [11], with very low evidence of recurrent disease [12].

Still the published literature reveals gaps about the prevalence of NET. First, much of the literature represents single case reports [2,3]. However, some investigators analyze rather modest numbers

\* Corresponding author.

E-mail address: [aabdelaal1@hamad.qa](mailto:aabdelaal1@hamad.qa) (A. Abdelaal).

of appendectomy cases, ranging from 480 [4] or 964 appendectomies [13] to <10000 appendectomies (e.g. 2197, Saylam et al., 2011 [6]; 6777, Coşkun et al., 2006 [14]; 9584 Beyrouti et al., 2004) [5]). Interestingly, the current study bridged this gap and appraised a much larger sample of appendectomies (n = 13641). Secondly, in terms of geographical distribution, there exists few published reports on NET from the Eastern Mediterranean Region such as Turkey [6,14], and Tunisia [5]. However, only few published studies on NET are available from the Arab Middle Eastern region including Saudi Arabia [4] and United Arab Emirates [13]. The incidence of NET varies across different studies, and the current study is seminal in detailing the frequency of these tumors in our region. Given that the appendix is one of the most common gastrointestinal tract sites for carcinoids [15], it is important to assess the occurrence and clinico-pathological profile of NET in our population. Herein, we assessed the frequency, clinical, ultrasound, computerized tomography (CT) and histopathology characteristics of NET in the State of Qatar.

## 2. Methods

It is a retrospective chart review of all clinically suspected patients with acute appendicitis who underwent emergent appendectomy with intention to treat between January 2004 and December 2014 and was clinically followed up until 2016 in some cases. Histopathological records of 13641 patients who underwent appendectomy at our institution were retrieved and reviewed to determine the prevalence rate of NET based on histopathological findings. The medical records of patients histologically confirmed to have NET were comprehensively assessed for the pre-operative clinical presentation, operative and postoperative findings. These clinico-pathological data included demographics, clinical presentation such as symptoms and elicited signs, modality of diagnosis (ultrasonography, CT scan and histological findings), hospital length of stay, treatment and post-operative complications. For all patients, the pathology from the initial resection was utilized to characterize the tumor pathology i.e. tumor location, tumor size, proximal and mesenteric circumferential margin, lymph node involvement and tumor differentiation in line with others [8]. Patients without clinical or pathologic evidence of lymph node involvement were considered to be negative for lymphovascular and/or perineural infiltration [8]. The histopathological categorization of these tumors was based on the AJCC Cancer Staging Manual, 7th Edition [16]. Ethical approval was obtained from the Institutional Review Board, Medical Research Center (IRB# 14516/14) at Hamad Medical Corporation, Qatar. Data were presented as proportions, mean  $\pm$  standard deviation or median and range. Data analysis was carried out using the Statistical Package for Social Sciences version 20 (SPSS Inc., Chicago, IL, USA).

## 3. Results

Of the total 13641 resected appendices, 32 cases were diagnosed with carcinoids, generating an incidence of 0.23%. Table 1 depicts the demographic and clinical characteristics of the patients. The mean age of the cases was  $25.3 \pm 7.9$  years (range 14–64); 78% were male with male to female ratio of 3:1. There observed equal distribution of NET among non-Arab (59.4%) and Arab (40.6%) nationalities. The most frequent presenting symptom was localized pain (90.6%), followed by shifting pain (53%) and other symptoms (such as nausea, vomiting, rectal bleeding and anorexia) were found in 75% patients. The common signs were localized tenderness (90.6%), fever (25%), generalized tenderness (6.3%), and abdominal distension (6.3%). Laparoscopic appendectomy was the most common procedure undertaken (62.5%) followed by open

**Table 1**  
Demographic and Clinical Characteristics of the sample (n = 32).

Variables	n (%)
<b>Patient Characteristics</b>	
<b>Demographic</b>	
Males	25 (78.1%)
Age (years, mean $\pm$ SD)	$25.3 \pm 7.9$
<b>Nationality</b>	
Arabs <sup>a</sup>	13 (40.6%)
Non-Arabs <sup>b</sup>	19 (59.4%)
<b>Clinical features</b>	
<b>Symptoms</b>	
Localized pain	29 (90.6%)
Shifting pain	17 (53.1%)
Other Symptoms <sup>c</sup>	24 (75.0%)
<b>Signs</b>	
Localized tenderness	29 (90.6%)
Generalized tenderness	2 (6.3%)
Palpable mass in right iliac fossa	1 (3.1%)
Fever	8 (25.0%)
Abdominal distension	2 (6.3%)
<b>Types of surgical procedures</b>	
Open Appendectomy	10 (31.2%)
Laparoscopic Appendectomy	20 (62.5%)
Laparoscopic Procedure converted to Open	1 (3.1%)
Formal Right Hemicolectomy	1 (3.1%)
<b>Length of hospital stay</b> (days, median&range)	4 (2-15)

<sup>a</sup> Qatar, Egypt, Jordan, Sudan, Palestine, Iran, Lebanon, India.

<sup>b</sup> Pakistan, Nepal, Bangladesh, Sri Lanka, Philippines.

<sup>c</sup> Nausea, vomiting, rectal bleeding, anorexia.

appendectomy (31.2%). One case had a midline laparotomy, and another case required a formal right hemicolectomy (patient was diagnosed as adenocarcinoma of the right ascending colon, where NET was incidentally discovered). Only one case underwent second stage procedure, as this patient was diagnosed for goblet cell carcinoid with positive proximal and mesenteric circumferential margins (hence was re-operated upon, where right hemicolectomy was undertaken). The median length of hospital stay was 4 (2–15) days.

Table 2 shows the findings of the laboratory investigations as well as imaging characteristics of the patients. NET patients exhibited mild leukocytosis and normal bilirubin levels. About half of the cases (43.8%) required preoperative abdominal ultrasonography for definitive diagnosis, where 71.4% had ultrasound features of appendicitis, 64.3% cases had free fluid, and only one (7.1%) case had appendicular mass. Preoperative abdominal CT scan was undertaken for five patients, of which all had minute pockets free air, while 2 cases had other findings (e.g. thickening of ceecal wall or terminal ileum).

Table 3 demonstrates the histopathologic characteristics of the

**Table 2**  
Investigations and imaging characteristics of the sample (n = 32).

Investigations	
<b>Laboratory</b>	
WBC ( $10^9$ per Litre) (mean $\pm$ SD)	$15 \pm 14$
Bilirubin (mg/dl) (mean $\pm$ SD)	$12.8 \pm 10$
<b>Preoperative abdominal Ultrasound</b>	
Features of appendicitis	14 (43.8%)
Free fluid	10 (71.4%)
Free fluid	9 (64.3%)
Appendicular mass	1 (7.1%)
<b>Preoperative abdominal CT scan</b>	
Features of appendicitis	5 (15.6%)
Features of appendicitis	3 (60.0%)
Appendicular mass	5 (100.0%)
Free fluid	1 (20.0%)
Free air	5 (100.0%)
Other findings (thickening of ceecal wall or terminal ileum)	2 (40.0%)

**Table 3**  
Pathology characteristics of the biospecimens (n = 32).

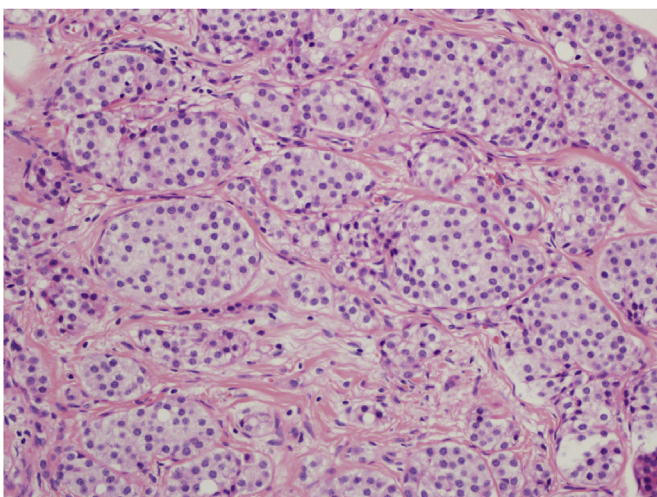
Tumor Pathology	n (%)
<b>Location</b>	
Tip	30 (93.7%)
Middle	1 (3.1%)
Base	1 (3.1%)
<b>Size (mean ± SD mm)</b>	
Proximal margin (positive)	4.86 ± 3.18
Mesenteric circumferential margin (positive) <sup>a</sup>	1 (3.1%)
Lymph node involvement	3 (9.4%)
<b>Differentiation</b>	
G1 (carcinoid)	0 (0.0%)
G2 (goblet cell carcinoid)	31 (96.8%)
	1 (3.2%)

<sup>a</sup> Two of these patient were lost to follow up; the remaining patient was followed up to date and is still alive 11 years after the surgical removal of the NET, with no evidence of metastasis or recurrence.

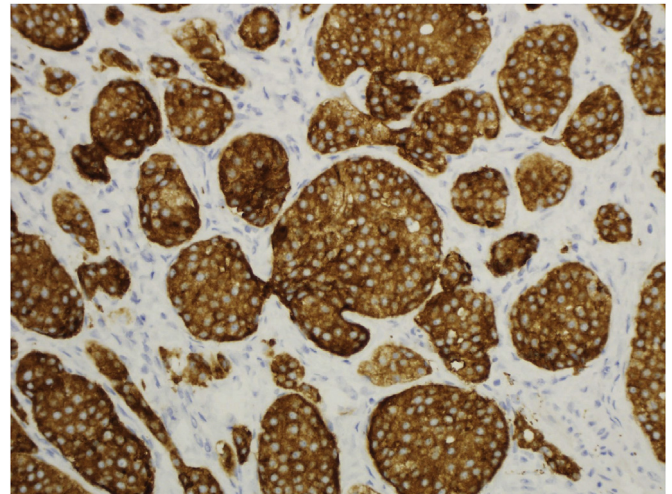
biospecimens. Across most of our sample (30 patients, 93.7%) the tumor was predominantly located at the tip of the appendix (93.7%); while one patient had NET in the middle of the appendix; and another case involves the base of the tumor (histopathologically diagnosed as goblet cell carcinoid). The mean tumor size was  $4.86 \pm 3.18$  mm (range 1.5–13 mm) and in 30 patients, the tumor size did not exceed 10 mm. Only one patient (3.1%) (diagnosed as goblet cell carcinoid) had positive proximal and mesenteric circumferential margins; another three patients had only positive mesenteric circumferential margins. A total of 31 (96.8%) patients had well differentiated conventional type NET (G1; Carcinoid); whilst the one case was adenocarcinoid (G2; Goblet Cell Carcinoid) which exhibits a more aggressive potential. All tumors except two were of PT1A stage; the exceptions were 2 cases that measured 13 and 11 mm, respectively rendering them both PT1B stage. The grading of mitoses was 0–1 in all 32 cases. Ki-67 index did not exceed 2% in nine cases as it was performed in last nine cases undertaken after 2012. Fig. 1 shows a microscopic photograph of G1-NET with nests of neuroendocrine cells (H&E  $\times 200$ ); and Fig. 2 depicts the immunohistochemistry with synaptophysin NETibody showing strong positivity in the tumor cells (immunohistochemistry  $\times 200$ ).

#### 4. Discussion

To the best of our knowledge, this is a unique study to report on



**Fig. 1.** Microscopic photograph showing G1- NET with nests of neuroendocrine cells (H&E  $\times 200$ ).



**Fig. 2.** Immunohistochemistry with synaptophysin NETibody showing strong positivity in the tumor cells (immunohistochemistry $\times 200$ ).

the frequency, clinico-pathological profile of NET in a cohort of 13641 patients that underwent appendectomies for clinically suspected acute appendicitis at our institute in Qatar. Our observed NET frequency was 0.23% which is less than those reported from Belgium (0.4%) [17], UK (0.62%) [18] and United Arab Emirates (0.93%) [13]. Nevertheless, our rate of NET corroborates with the recent data (ranges from 0.27% to 1.6%) reported for the overall NET frequency among patients undergoing emergent appendectomies [19,20].

The mean age of our cohort (25.3 years) is in agreement with a report of a consecutive series of 1237 appendectomies, where mean age of NET patients was 29.2 (range: 6–82) years [17]. Moreover, NET are generally diagnosed more often among female than in male patients [15,21,22]. In Italy, NET was more frequent in women (2–4:1) [3]. A Turkish study reported a near equal distribution of NET by gender [14]. In contrast to these findings, our study observed more NET in males than females (3:1), which is much similar a study from the UAE, where male to female ratio was 2:1 [13]. Such contrast in our findings compared to others might be attributed to the sociodemographic composition of the population in the Middle Eastern country Qatar, where there is a much higher predominance of males over females due to the immigrant worker population. Indeed, immigrants constituted an astounding 94% of Qatar's workforce, and 70% of its total population, resulting in male predominance [23]. Such noticeable male predominance could in part be due to that most laborers and other manual and semi-professionals enter the country on single status.

In our cohort, all NET patients presented with acute appendicitis and mild leukocytosis, which is in agreement with a study from the UK, where all NET cases presented with acute appendicitis and more than half (58.5%) had raised inflammatory markers [18]. Similarly, Anwar et al. [13] reported that all NET cases were associated with concomitant suppurative appendicitis [13]. At our institution, we traditionally prefer open appendectomy particularly for thin patients; which has been replaced by laparoscopic appendectomy, particularly for obese or female patients, in line that the gold standard treatment is surgical treatment by appendectomy [11,13].

The pathologic characteristics of our NET, revealed tumor size of 4.86 (range 1.5–13) mm, which is in agreement with the UK (median tumor size 5, range 1–20) mm [18]; Belgium (median diameter 6 mm, range 3–10 mm) [17]; and United Arab Emirates (median diameter 3.3 mm) [13]. In majority of our cases, the tumor was located at the tip of the appendix, in support of Belgium (all

NET were located at the tip of the appendix [17], and Sarjah (89% of tumors were located near the tip of the appendix) [13]. We had one case where the tumor was at the base, is similar to Anwar et al. [13] who also reported one case of tumor near to the proximal end of the appendix. Furthermore, all our cases except one had negative proximal margins, in line with other NET research, where the margins of all the resected tissue samples received for histological analysis were free of tumor cells [13]. In addition, 3 of our patients (9.4%) had positive mesenteric circumferential margins, concurring with research in the USA where two NET patients (6%) had mesoappendiceal involvement [8].

Moreover, we had one male patient (64 years old) who was diagnosed for goblet cell carcinoid (GCC) and had positive proximal and mesenteric circumferential margins. This patient was re-operated upon where right hemicolectomy was undertaken (underwent second stage procedure). Older age seems to be associated with GCC, where mean age of GCC patients is around 52 years [24], and others have reported appendicular GCC in two females (60 and 54 year olds) and a male (>60 years) [25–28]. Although a case of 31-year-old man has also been described in the literature [29]. In our cohort, the treatment for appendicular GCC is in agreement with others, where the main treatment of appendicular GCC is appendectomy and right hemicolectomy [25,30].

There was no clear clinical indication for follow-up in 28 cases, all of these cases were well differentiated conventional type NET (G1 category tumor), with size <1 cm, and all were completely excised with proximal and circumferential negative margins. Such policy is in agreement with others, where NET  $\leq 1$  cm were unlikely to recur, and therefore, postoperative surveillance might be indicated in such cases [8,11]. Indeed, for such tumors, even with a median follow-up period of 7 years, studies found no evidence of recurrent disease or other non-carcinoid neoplasms [12]. Furthermore, in our series of the 3 patients with positive mesenteric circumferential margins, two were lost to follow-up as they were expatriates probably returned to their home countries; the remaining one patient was followed up to date and is still alive 11 years after the surgical removal of NET, with no evidence of metastasis or recurrence. Similarly, Murray et al. [8] reported one NET patient with mesoappendiceal involvement had no scheduled follow-up and was alive without clinically symptomatic disease 8 years after resection.

The current literature suggests inconsistency for the exact biological behavior of GCC [29], it could be metastasized in 15–30% of cases, particularly among higher age group [31]. Therefore, clinical follow-up of such patients is highly recommended. For instance, Kimura et al. [28] reported a case of GCC which was followed-up for a year after surgery with no evidence of recurrence. In line with others reports, the follow-up abdominal CT scan for our GCC patient after resection showed no evidence of metastasis or recurrence even after 13 years. Nevertheless, the current literature showed inconsistency for post-resection surveillance recommendations for NET as physician practices seem not uniform with respect to the necessity, mode, and frequency of follow-up [8].

This study has certain limitations, mainly due to its retrospective approach. Prospective studies evaluating the need and cost-effectiveness of different follow-up periods of NET patients would be useful. Although, the low frequency of NET necessitate large multi-centre studies with long-term follow-up to determine the differences in the outcomes of various follow-up periods. However, the present study has much strength due to large number of appendectomies and nationally representative cohort as our institution is the tertiary referral hospital in the State of Qatar.

In conclusion, this seminal study reports the frequency of incidentally detected NET in patients underwent appendectomies for clinically suspected acute appendicitis. NET is rare, and our

frequency was 0.23%. Contrary to other studies, males were involved three times more commonly than females. We observed no recurrence or metastasis of NET, even for the goblet cell carcinoid tumor. Our findings could suggest that appendectomy is adequate for well differentiated NET <2 cm with negative pathological margins.

### Ethical approval

The study received ethical approval from the Medical Research Centre at Hamad Medical Corporation (Protocol #14516/14).

### Funding

None.

### Author contribution

Abdelrahman Abdelaal: conception of idea and design, supervision, and review.

Walid El Ansari: write up manuscript and review.

Issam Al-Bozom: write up the pathology section and review.

Mahwish Khawar: data collection and review.

Fakhar Shahid: data collection, interpretation and review.

Ammar Aleter: data collection, interpretation and review.

Mohammed Rasoul Abu nuwar: data collection, interpretation and review.

Ayman El-Menyar: write up and review.

All authors read and approved the final manuscript.

### Conflict of interest

The authors have no conflict of interest.

### Guarantor

Dr Abdelrahman Abdelaal.

### Authorship

All authors have substantially contributed in the study conduction and manuscript writing and approval.

### References

- [1] I.M. Modlin, K.D. Lye, M. Kidd, A 5-decade analysis of 13,715 carcinoid tumors, *Cancer* 97 (2003) 934–959.
- [2] Y. Gu, N. Wang, H. Xu, Carcinoid tumor of the appendix: a case report, *Oncol. Lett.* 9 (5) (2015) 2401–2403.
- [3] S.I. Spallitta, G. Termine, M. Stella, V. Calistro, P. Marozzi, Carcinoid of the appendix. A case report, *Minerva Chir.* 55 (1–2) (2000) 77–87.
- [4] M.A. Jat, F.K. Al-Swailmi, Y. Mehmood, M. Alrowaili, S. Alanazi, Histopathological examination of appendectomy specimens at a district hospital of Saudi Arabia, *Pak J. Med. Sci.* 31 (4) (2015) 891–894.
- [5] M.I. Beyrouti, A. Gharbi, M. Abid, R. Beyrouti, S. Elleuch, W. Gharbi, M. Chaabouni, I. Kchaou, M. Kharrat, N. Jomaa, T. Boudawara, Carcinoid tumors of the appendix. A report of 46 cases, *Tunis. Med.* 82 (7) (2004) 668–673.
- [6] B. Saylam, Ö.K. Küçük, A.P. Düzgün, M.V. Özer, F. Coşkun, Carcinoid tumor of the appendix: report on ten cases, *Eur. J. Trauma Emerg. Surg.* 37 (5) (2011) 491–493.
- [7] A. Roggo, W.C. Wood, L.W. Ottinger, Carcinoid tumors of the appendix, *Ann. Surg.* 217 (1993) 385–390.
- [8] S.E. Murray, R.V. Lloyd, R.S. Sippel, H. Chen, S.C. Oltmann, Postoperative surveillance of small appendiceal carcinoid tumors, *Am. J. Surg.* 207 (3) (2014) 342–345 discussion 345.
- [9] D. Debnath, J. Rees, F. Myint, Are we missing diagnostic opportunities in cases of carcinoid tumours of the appendix? *Surgeon* 6 (2008) 266–272.
- [10] M.C. Safioleas, K.G. Moulakakis, K. Kontzoglou, J. Stamoulis, G.C. Nikou, C. Toubanakis, N.J. Lygidakis, Carcinoid tumors of the appendix. Prognostic factors and evaluation of indications for right hemicolectomy, *Hepatogastroenterology* 52 (61) (2005) 123–127.

- [11] K.H. In't Hof, H.C. van der Wal, G. Kazemier, J.F. Lange, Carcinoid tumour of the appendix: an analysis of 1,485 consecutive emergency appendectomies, *J. Gastrointest. Surg.* 12 (8) (2008) 1436–1438.
- [12] R. Shapiro, S. Eldar, E. Sadot, M.Z. Papa, D.B. Zippel, Appendiceal carcinoid at a large tertiary center: pathologic findings and long-term follow-up evaluation, *Am. J. Surg.* 201 (6) (2011) 805–808.
- [13] K. Anwar, M. Desai, N. Al-Bloushi, F. Alam, F.S. Cyprian, Prevalence and clinicopathological characteristics of appendiceal carcinoids in Sharjah (United Arab Emirates), *World J. Gastrointest. Oncol.* 6 (7) (2014) 253–256, 15.
- [14] H. Coşkun, O. Bostanci, M.E. Dilege, M. Mihmanli, B. Yilmaz, I. Akgün, Yildirim S. Carcinoid tumors of appendix: treatment and outcome, *Ulus. Travma Acil Cerrahi Derg.* 12 (2) (2006) 150–154.
- [15] J.C. Yao, M. Hassan, A. Phan, C. Dagohoy, C. Leary, J.E. Mares, E.K. Abdalla, J.B. Fleming, J.N. Vauthey, A. Rashid, D.B. Evans, One hundred years after “carcinoid”: epidemiology of and prognostic factors for neuroendocrine tumors in 35,825 cases in the United States, *J. Clin. Oncol.* 26 (2008) 3063–3072.
- [16] S.B. Edge, D.R. Byrd, M.A. Carducci, C.C. Compton, *AJCC Cancer Staging Manual*, seventh ed., Springer, New York, NY, 2009.
- [17] V. Tchana-Sato, O. Detry, M. Polus, A. Thiry, B. Detroz, S. Maweja, E. Hamoir, T. Defechereux, C. Coimbra, A. De Roover, M. Meurisse, P. Honoré, Carcinoid tumor of the appendix: a consecutive series from 1237 appendectomies, *World J. Gastroenterol.* 12 (41) (2006) 6699–6701, 7.
- [18] B. Amr, F. Froghi, M. Edmond, K. Haq, R. Thengungal Kochupapy, Management and outcomes of appendicular neuroendocrine tumours: retrospective review with 5-year follow-up, *Eur. J. Surg. Oncol.* 41 (9) (2015) 1243–1246.
- [19] Z. Zvizdić, A. Đuran, K. Karavdić, A. Jakić, E. Milišić, Carcinoid tumors of the appendix vermiform in children—ten year analysis of 1503 appendectomies, *BH Surg.* 1 (2011) 100–103.
- [20] S.G. Barreto, L. Tionga, T. Thomas, E. Traversa, R.S. Williams, Incidental appendiceal carcinoids: is surgery affecting their incidence? *World J. Oncol.* 3 (2012) 227–230.
- [21] U.F. Pape, A. Perren, B. Niederle, et al., ENETS Consensus Guidelines for the management of patients with neuroendocrine neoplasms from the jejunum and the appendix including Goblet Cell Carcinomas, *Neuroendocrinology* 95 (2012) 135–156.
- [22] O. Hauso, B.I. Gustafsson, M. Kidd, H.L. Waldum, I. Drozdov, A.K. Chan, I.M. Modlin, Neuroendocrine tumor epidemiology: contrasting Norway and North America, *Cancer* 113 (2008) 2655–2664.
- [23] *The Guardian*, Qatar's migrants: how have they changed the country?. <https://www.theguardian.com/news/datablog/2013/sep/26/qatar-migrants-how-changed-the-country>, 2013.
- [24] K.S. Lee, L.H. Tang, J. Shia, P.B. Paty, M.R. Weiser, J.G. Guillem, L.K. Temple, G.M. Nash, D. Reidy, L. Saltz, M.J. Gollub, Goblet cell carcinoid neoplasm of the appendix: clinical and CT features, *Eur. J. Radiol.* 82 (1) (2013) 85–89.
- [25] K. Ptasiński, A. Bartczak, B. Kołodziej, M. Szczepkowski, Goblet cell carcinoid of the vermiform appendix - a case report, *Pol. J. Pathol.* 63 (4) (2012) 294–297.
- [26] K. Yokota, M. Takahashi, K. Okada, H. Ishizu, H. Masuko, K. Tanaka, T. Hata, H. Kawamura, H. Yamagami, H. Watarai, M. Kuji, T. Tanioka, K. Shibuya, A case report of goblet cell carcinoid tumor of the appendix, *Gan To Kagaku Ryoho* 39 (12) (2012) 2286–2288 ([Article in Japanese]).
- [27] D.S. Kahraman, N. Akin, Goblet cell carcinoid of the appendix: a case report, *Türk Patoloji Derg.* 31 (2) (2015) 136–140 ([Article in Turkish]).
- [28] K. Kimura, Y. Kagawa, T. Kato, Y. Katsura, Y. Ohmura, A. Takeno, H. Sakisaka, H. Taniguchi, Y. Takeda, S. Tamura, A case of goblet cell carcinoid diagnosed after appendectomy, *Gan To Kagaku Ryoho* 42 (12) (2015) 2221–2223 ([Article in Japanese]).
- [29] B. Mitra, M. Pal, B. Paul, T.N. Saha, A. Maiti, Goblet cell carcinoid of appendix: a rare case with literature review, *Int. J. Surg. Case Rep.* 4 (3) (2013) 334–337.
- [30] N. Holt, H. Grønbaek, Goblet cell carcinoids of the appendix, *ScientificWorldJournal* 2013 (2013) 543696.
- [31] N.C. Gallegos, C. Milroy, I.P. Linehan, P.B. Boulos, Crypt cell carcinoma of the appendix, *Eur. J. Surg. Oncol.* 18 (1992) 386–387.