

A Rare Case of Oral Cavity Eumycetoma

Kavita Ramesh Wadde, Samir Dashrath Khaire, Tabita Joy¹, Manisha Ahire Sardar¹, Mrimingsi Kri, Lakshmi Venkatakrishnan

Departments of Oral and Maxillofacial Surgery and ¹Oral and Maxillofacial Pathology, Government Dental College and Hospital, Mumbai, Maharashtra, India

Abstract

Rationale: Mycetoma is a chronic granulomatous infection that involves the skin and subcutaneous tissue which presents as an abscess with multiple draining sinuses. It is common in the tropical and subtropical regions where the conditions favour the growth of the soil saprophytes – fungi and bacteria. **Patient Concerns:** We report the rare case of a 62-year-old patient who presented with a soft-tissue overgrowth in the mandibular posterior ridge area for eight months. **Diagnosis:** The patient was diagnosed with eumycetoma, with foreign-body reaction based on clinical and histopathological examination which revealed characteristic brown-coloured amorphous grains. **Treatment:** The lesion was surgically excised under local anaesthesia. **Outcomes:** On the seventh day post-operative follow-up, the patient was relieved of pre-operative symptoms and the surgical site had healed well. **Take-Away Lessons:** This particular case of eumycetoma had an unusual site and appearance, making the clinical diagnosis confusing with other reactionary lesions of the oral cavity.

Keywords: Oral cavity eumycetoma, oral fungal infection, oral mycetoma

INTRODUCTION

Mycetoma is a progressive chronic granulomatous infection of the skin and subcutaneous tissue. It occurs due to fungi, referred to as eumycetoma, or by bacteria, referred to as actinomycetoma.^[1] Actinomycotic species causing mycetoma include *Streptomyces somaliensis*, *Actinomadura madurae*, *Actinomadura pelletieri* while the common fungal species include *Madurella mycetomatis*, *Madurella grisea* and *Pseudallescheria boydii*.^[2]

This disease is common in tropical countries, occurring in populations of low socioeconomic status, usually in men who work barefoot or are in regular contact with the soil.^[3]

The most common site affected is the foot (79.2%). Other exposed body parts such as the hand (6.6%), knee, arm, thigh and perineum can also be infected. Rarer sites are the paranasal sinuses, mandible and orbit.^[4] The most prevalent age group is between 20 and 40 years of age, although it is not rare to find the disease in older adults.^[5]

Organisms causing mycetoma are soil saprophytes that gain access into the tissues through trauma from splinters. After inoculation of the causative agent, it has a progressive and indolent course.^[1] It usually begins as a painless subcutaneous swelling which if left untreated leads to destruction of deeper

tissues and bone. The common presentation is an abscess with multiple draining sinuses.^[6]

Here, we report a very rare case of oral cavity eumycetoma and discuss the aetiology of the possible fungal contamination of this area.

CASE REPORT

A 62-year-old patient reported to the Department of Oral and Maxillofacial Surgery with a complaint of a growth in the right lower jaw region for eight months. It had started as a small growth in the right lower jaw posterior region and slowly progressed to the present size. The patient did not give any history of trauma to the region. On extraoral examination, the right side submandibular lymph nodes were palpable, soft, mobile and non-tender.

Address for correspondence: Dr. Mrimingsi Kri,
Department of Oral and Maxillofacial Surgery, Government Dental College
and Hospital, Mumbai, Maharashtra, India.
E-mail: mrimingsikri27@gmail.com

Received: 21-12-2022

Last Revised: 06-04-2023

Accepted: 03-05-2023

Published: 12-07-2023

This is an open access journal, and articles are distributed under the terms of the Creative Commons Attribution-NonCommercial-ShareAlike 4.0 License, which allows others to remix, tweak, and build upon the work non-commercially, as long as appropriate credit is given and the new creations are licensed under the identical terms.

For reprints contact: WKHLRPMedknow_reprints@wolterskluwer.com

How to cite this article: Wadde KR, Khaire SD, Joy T, Sardar MA, Kri M, Venkatakrishnan L. A rare case of oral cavity eumycetoma. *Ann Maxillofac Surg* 2023;13:108-12.

Access this article online

Quick Response Code:



Website:
<https://journals.lww.com/aoms>

DOI:
10.4103/ams.ams_242_22

Intraoral examination revealed a 3 cm × 4 cm soft tissue growth over the alveolar ridge anteroposteriorly extending from right first molar till the right pterygomandibular raphae region [Figure 1]. Mediolaterally, it was covering the right buccal vestibule with extension towards the lingual sulcus [Figure 2]. The bilateral mandibular molars were missing which were lost two to three years back due to mobility. The growth was pink with smooth margins. On palpation, it was rubbery in consistency, with no tenderness or bleeding and had a pedunculated base. The patient had reported with magnetic resonance imaging of the head and neck region that showed a lesion of 43 mm × 33 mm × 33 mm, heterogeneous, predominantly fluid intensity involving the right mandibular alveolus [Figure 3]. Scalloping and cortical erosion of the underlying alveolus and few enlarged lymph nodes at right level IA (16 mm × 14 mm) and level IB (22 mm × 16 mm × 11 mm) were also seen. Panoramic radiograph showed horizontally placed right mandibular third molar [Figure 4].

After clinical and radiological examination, initial diagnosis of irritational fibroma was given with peripheral ossifying fibroma as differential diagnosis.

Routine blood investigation revealed decreased haemoglobin (Hb) 10.1 g/dL, increased neutrophil count 85% and increased leucocyte count 14100/cu mm. Red blood cell parameter showed increased haematocrit, mean corpuscular volume (CV), mean corpuscular haemoglobin (MCH), MCH concentration and red cell distribution width-CV suggestive of anaemia and underlying infection.

Excision under local anaesthesia was carried out and the specimen was sent for histopathological examination [Figure 5]. Injection augmentin 1.2 g was administered for seven days post-operatively. The patient was reviewed on the seventh day postoperatively where on examination, the surgical site had healed well [Figure 6].

Histopathological examination of excised specimen revealed places of suppurative granulomas composed of neutrophils surrounding characteristic brown-coloured amorphous grains at places. Multinucleated giant cells were seen with few of them engulfing the grains [Figure 7]. At few places, black to grey coloured round-to-oval refractile materials were seen. Myxomatous changes were seen in the connective tissue stroma and few areas showed the presence of round eosinophilic

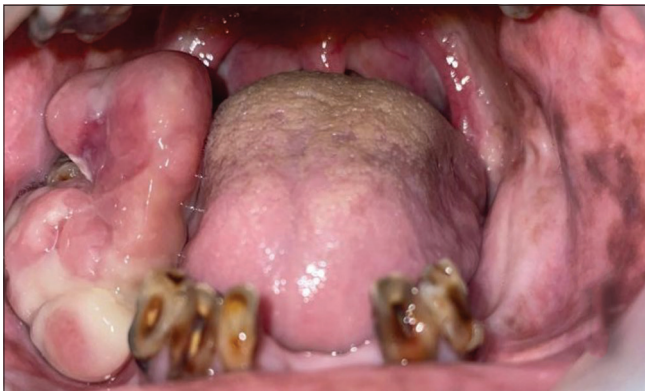

Figure 1: Intraoral examination revealing a 3 cm × 4 cm soft tissue growth over the alveolar ridge anteroposteriorly extending from the right mandibular first molar till the right pterygomandibular region

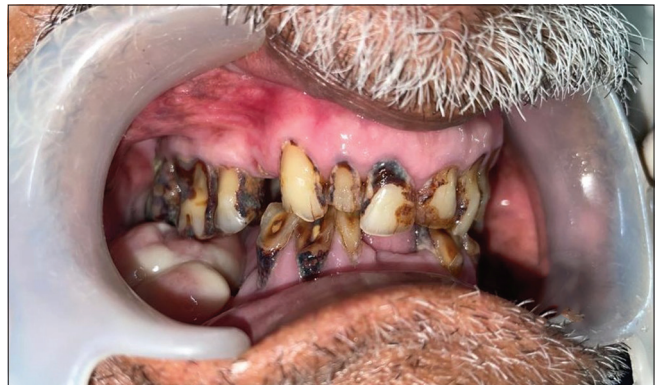

Figure 2: Right side maxillary molars impinging over the soft tissue overgrowth

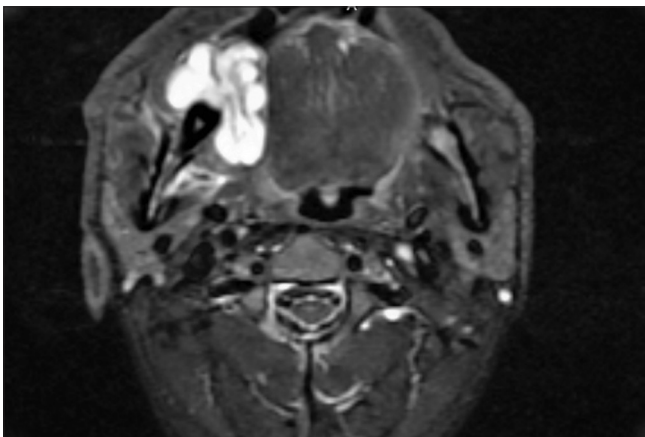


Figure 3: MRI neck showing a heterogeneous, predominantly fluid intensity oral cavity lesion, involving the right mandibular alveolus. MRI: Magnetic resonance imaging

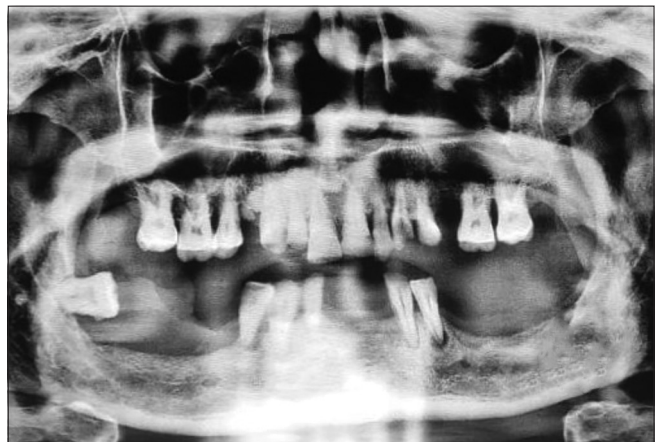

Figure 4: Orthopantomogram showing horizontally placed right side mandibular third molar, missing bilateral mandibular molars and periodontally compromised remaining dentition

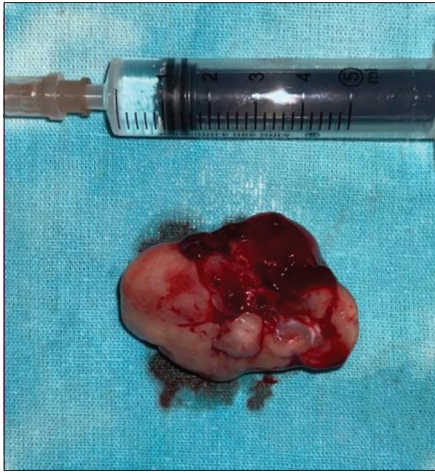


Figure 5: Excised specimen

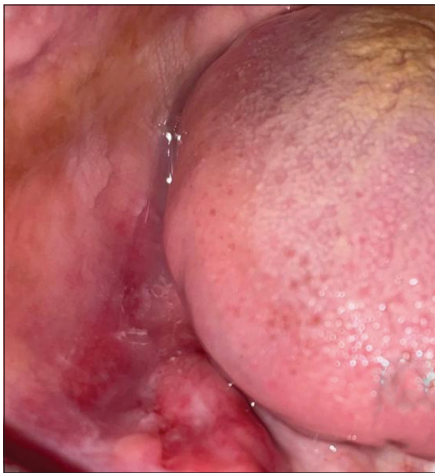

Figure 6: On the seventh day follow-up, the surgical site had healed well

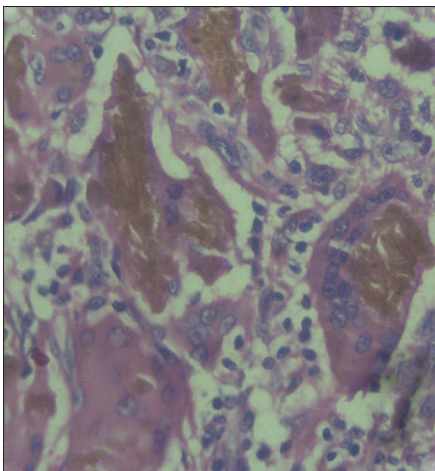


Figure 7: ×40 objective showing suppurative granulomas surrounding characteristic brown-coloured amorphous grains with multinucleated giant cells engulfing the grains

coagulum-like substance which was suggestive of foreign body reaction. Special stains were done for the grains noted. The grains were positive on periodic acid–Schiff staining and

negative on gram staining. Grocott methenamine silver staining which is used to identify fungal elements was faintly positive.

All these findings were suggestive of eumycetoma with foreign-body reaction. Culture and sensitivity testing was not done as the diagnosis of a fungal infection was not suspected at the first place.

DISCUSSION

Oral cavity eumycetoma is a rare finding with reported cases in the mandible, palate and floor of the mouth [Table 1].^[6-8] Our case was rare as it was predominantly a soft-tissue overgrowth with mild erosion of the underlying alveolus. Localised fibrous tissue overgrowth is a very common in oral mucosa which led to our initial diagnosis of irritational fibroma.^[9]

Although the patient did not give any history of trauma or puncture at the site of the lesion, there was a lone standing horizontally positioned right mandibular third molar. The posterior teeth overclosure and the continuous interference from the periodontally compromised, horizontally positioned right mandibular third molar could have been the possible cause of trauma to the lower alveolus. The patient being a farmer by profession had frequent contact with soil. All the above-mentioned factors with the prevailing systemic condition and poor oral hygiene status of the patient must have contributed to inoculation of the fungal element. It is very important to distinguish between eumycetoma and actinomycetoma by histopathological examination, using aided histochemical staining and direct microscopical examination as the management of the two are entirely different; the differentiating points are mentioned in Table 2. For the pigmented granular material seen in the connective tissue stroma, we had considered them to be either haemosiderin or grains of chromogenic microorganism. Perls Prussian blue gives positive results for both and hence microbial staining was used to differentiate between the two. From the positive results of special stain, we came to a conclusion that these were grains of fungi.

Grains are crucial to establish the diagnosis of the causative organism. The grains found in eumycetoma are densely packed fungal mycelia embedded in a hard and brown–black cement material.^[10]

The overproduction of polysaccharides in the fungal cell wall makes eumycetoma less susceptible to the action of antifungal agents and resistant to the host's immune system. Management requires long course of antifungal therapy of approximately 18–24 months combined with surgical excision. Most common agents are azoles such as itraconazole and ketoconazole, but they have a disadvantage of short-term efficacy, recurrence and side-effects.^[10] Eumycetoma is refractory to treatment and thus the patient counselling is very much important as a prolonged follow-up period is necessary to monitor for disease recurrence.^[10] New therapies such as voriconazole and posaconazole are effective in refractory types of

Table 1: Comparison of cases of oral cavity eumycetoma available in the literature

Studies	Current study	Nai et al. ^[7]	Suleiman and Fahal. ^[8]	Joshi et al. ^[6]
Patient details (age/sex)	62 years/male	43 years/male	25 years/male	2 years/male
Chief complaint	Growth in the right lower jaw region for eight months	Swelling with discharge in the palate for two years	Painless swelling under the tongue	Swelling in the right lower third of the face for 3 months
Clinical history	Started as a small growth in the lower jaw posterior region and slowly progressed to the present size	A liquid content would often drain from the swelling, leading to a reduction of the oedema	Started several years before as a small oral swelling which was of gradual onset and course Enlarged rapidly for two months	Blunt non-penetrating injury while playing
Lesion characteristics	Soft tissue growth over the right mandibular alveolar ridge from first molar region till the pterygomandibular raphae Palpation - rubbery in consistency with no tenderness	Palatal swelling with draining sinus	Examination - a pigmented mass in the floor of the mouth exactly in the midline directly below the tongue Palpation - tender to, firm in consistency, fixed to deep structures and non-reducible	Examination - diffuse swelling in the right angle of the mandible Palpation - non-tender, hard swelling with no local rise in temperature
Additional features	MRI - lesion of size 43 mm × 33 mm × 33 mm, heterogeneous, pre-dominantly fluid intensity involving the right mandibular alveolus Cortical erosion of the underlying alveolus	Panoramic radiographic showed and CT - a large radiolucent area involving the region of teeth 21–26 and communication with the nasal cavity	CT - a large mass under the tongue	CT scan - expansile residual osteolytic lesion in the mandible
Histopathology	Suppurative granulomas composed of neutrophils surrounding characteristic brown-coloured amorphous grains Gram staining - negative PAS - positive GMS - positive	Granulomatous inflammation with pus containing characteristic grains in the centre Gram staining - negative GMS - positive	Numerous <i>Madurella mycetomatis</i> grains surrounded by various tissue reactions	Granulomatous inflammation with the mixed inflammatory cells containing characteristic grains in the centre Gram stain - negative GMS - positive PAS - positive
Surgical management	Excision	Enucleation	Excision	Excision and curettage
Medical management	-	Ketoconazole 200 mg/day for nine months	Ketoconazole 400 mg/day for 6 months	Ketoconazole 50 mg/day for three months

GMS: Grocott methenamine silver, PAS: Periodic acid–Schiff, CT: Computed tomography

Table 2: Distinguishing features of eumycetoma and actinomycetoma^[6]

Distinguishing feature	Actinomycetoma	Eumycetoma
Clinical features	Clinical triad <ul style="list-style-type: none"> Painless subcutaneous mass (tumour) Multiple sinuses Discharge containing grains of different colours, sizes and consistency 	Same as actinomycetoma
Rate of progression	Rapid	Slow
Histopathology		
Size of the grains	Smaller	Larger
Nature	Fine branching filaments <1 µm thick	Septate hyphae 4–5 µm thick
Pigment	Absent	Melanin
	White to yellow and red to pink in colour	Black in colour
IHC		
Gram staining	Positive	Negative
PAS stain	Negative	Positive
Grocott-Gomori	Negative	Positive
Drug of choice	Antimycobacterials Dapsone and streptomycin Sulfamethoxazole-trimethoprim and rifampicin	Antifungals Ketoconazole Itraconazole

PAS: Periodic acid–Schiff, IHC: Immunohistochemistry

eumycetoma. Posaconazole can penetrate the bone and shows promising results in salvage therapy with minimal adverse

effects.^[10] In our case, unfortunately, the patient was lost for follow-up before the diagnosis of eumycetoma was proven by

histopathological diagnosis, and hence, the antifungal drugs could not be started.

The clinical diagnosis of mycetoma is usually made on the presence of sinus tract or discharge with deep tissue involvement. Our case had an atypical site and presentation with very less clinical and radiological finding to its attribute. Histopathological evidence aided with special staining helped us in the diagnosis of eumycetoma which could have been otherwise missed.

CONCLUSION

The histopathological evaluation all lesions although intensive, is mandatory, avoiding which we may fail to address the underlying infection.

Declaration of patient consent

The authors certify that they have obtained all appropriate patient consent forms. In the form, the patient has given his consent for his images and other clinical information to be reported in the journal. The patient understands that name and initials will not be published and due efforts will be made to conceal identity, but anonymity cannot be guaranteed.

Financial support and sponsorship

Nil.

Conflicts of interest

There are no conflicts of interest.

REFERENCES

1. Yadlapati S, Chaudhari SP. Eumycetoma. In: StatPearls. Treasure Island (FL): StatPearls Publishing; 2022.
2. Verma P, Jha A. Mycetoma: Reviewing a neglected disease. *Clin Exp Dermatol* 2019;44:123-9.
3. Emery D, Denning DW. The global distribution of actinomycetoma and eumycetoma. *PLoS Negl Trop Dis* 2020;14:e0008397.
4. Fahal AH, Suliman SH, Hay R. Mycetoma: The spectrum of clinical presentation. *Trop Med Infect Dis* 2018;3:97.
5. Fahal AH, Yagi HI, el Hassan AM. Mycetoma-induced palatal deficiency and pharyngeal plexus dysfunction. *Trans R Soc Trop Med Hyg* 1996;90:676-7.
6. Joshi A, Acharya S, Anehosur VS, Tayaar AS, Gopalkrishnan K. Oral eumycetoma of infancy: A rare presentation and a brief review. *J Craniomaxillofac Surg* 2014;42:35-40.
7. Nai GA, Stuani ML, Stuani LA. Oral cavity eumycetoma. *Rev Inst Med Trop Sao Paulo* 2011;53:165-8.
8. Suleiman AM, Fahal AH. Oral cavity eumycetoma: A rare and unusual condition. *Oral Surg Oral Med Oral Pathol Oral Radiol* 2013;115:e23-5.
9. Lanjekar A, Kulkarni S, Akhade S, Sonule S, Rathod U. An unusually large irritation fibroma associated with gingiva of lower left posterior teeth region. *Case Rep Dent* 2016;2016:1-4.
10. Sawatkar GU, Wankhade VH, Supekar BB, Singh RP, Bhat DM, Tankhiwale SS. Mycetoma: A common yet unrecognized health burden in central India. *Indian Dermatol Online J* 2019;10:256-61.