

*Teaching Point*  
(Section Editor: A Meyrier)

## Adenovirus nephritis and obstructive uropathy in a renal transplant recipient: case report and literature review

Luiz M. Kolankiewicz<sup>1</sup>, James Pullman<sup>2</sup>, Mark Raffeld<sup>3</sup>, Jeffrey B. Kopp<sup>4</sup> and Daniel Glicklich<sup>1</sup>

<sup>1</sup>Department of Nephrology, <sup>2</sup>Department of Pathology, Albert Einstein College of Medicine, New York, NY, USA, <sup>3</sup>Laboratory of Pathology, National Cancer Institute and <sup>4</sup>Kidney Disease Section, National Institute of Diabetes and Digestive and Kidney Disease, National Institutes of Health, Bethesda, MD, USA

Correspondence and offprint requests to: Daniel Glicklich; E-mail: dglichli@montefiore.org

We report an unusual case of adenoviral nephritis in a 45-year-old woman who presented with fever, gross haematuria, acute kidney injury and obstructive uropathy 17 months following renal transplantation. Adenoviral nephritis was confirmed with immunohistochemistry. We identified 10 other published cases of adenoviral nephritis proven by immunohistochemistry. Obstructive uropathy has been reported only once before in a renal transplant recipient with adenoviral nephritis. Contrary to other reports, this case series shows that renal function may not always recover to baseline following the acute adenoviral disease. Adenoviral nephritis should be considered in the renal transplant patient with fever, haematuria, acute kidney injury and hydronephrosis in both the early and late post-transplant periods.

**Keywords:** adenovirus nephritis; obstructive uropathy; renal transplant

### Introduction

Adenovirus infection in a renal transplant recipient was reported 35 years ago in an autopsy study which showed cytopathic changes of allograft tubular epithelial cells and diffuse interstitial pneumonitis [1]. The most common urologic manifestation of adenoviral infection is haemorrhagic cystitis [2,3], but disseminated disease with multi-organ failure and death has rarely been reported in renal transplant patients [4–7]. Over the last 25 years, there have been sporadic case reports of adenovirus-related renal allograft nephritis. In this report, we describe an unusual case of late onset adenoviral allograft nephritis with obstructive uropathy and we review other cases of adenoviral nephritis proven by biopsy immunohistochemistry.

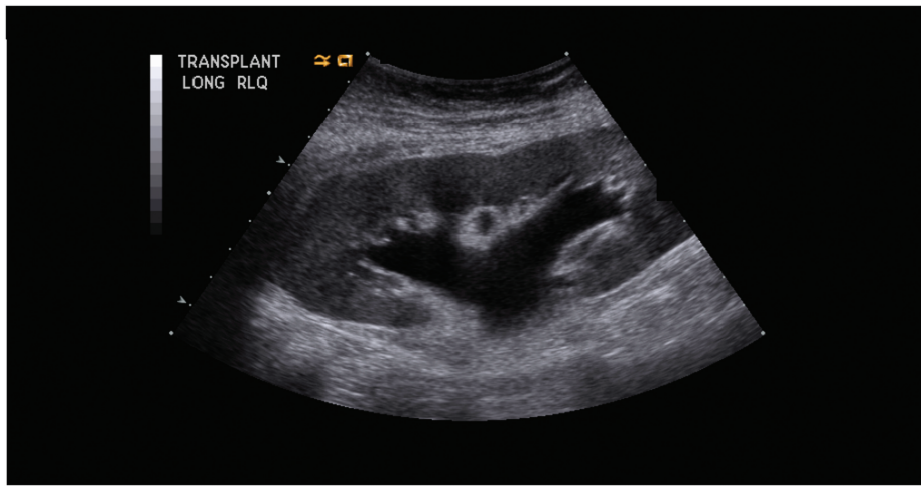
### Case report

A 45-year-old woman had a longstanding history of systemic lupus erythematosus, treated for years with gluco-

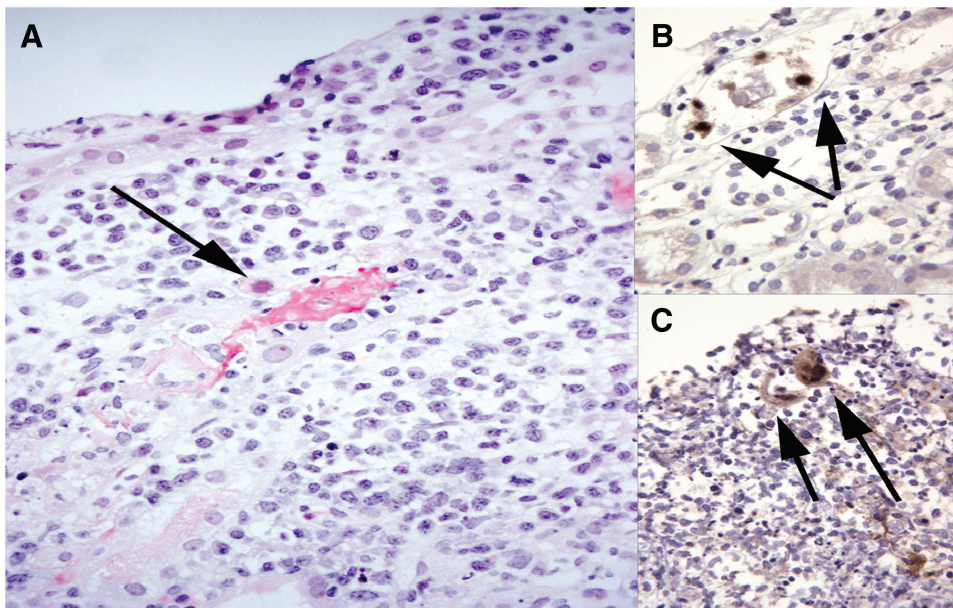
corticoids and intravenous cyclophosphamide. She developed end-stage renal disease in 1998. She underwent a deceased-donor renal transplant on April 2006. The adult donor was a six-antigen mismatch. An intraoperative kidney biopsy showed normal histology. She received thymoglobulin induction, followed by prednisone, tacrolimus and mycophenolic acid. Trimethoprim–sulfamethoxazole and valganciclovir were given for viral and bacterial prophylaxis. Her baseline serum creatinine was 1.0 mg/dl. She developed diabetes mellitus requiring an oral agent.

She was admitted to the hospital 17 months following transplant to evaluate 3 days of gross haematuria, abdominal pain and fevers. Her admission medications included prednisone 5 mg daily, tacrolimus 5 mg twice daily, mycophenolic acid 720 mg twice daily, clonidine 0.2 mg twice daily, glipizide 5 mg daily, valganciclovir 450 mg daily and trimethoprim–sulfamethoxazole daily. On admission, her temperature was 37.8 °C, blood pressure was 130/80 mmHg and physical exam showed mild tenderness over the right lower quadrant of the allograft and suprapubic area.

Laboratory tests showed increased azotaemia with blood urea nitrogen 45 mg/dl and creatinine 2.3 mg/dl. Urine was grossly bloody and urinalysis showed numerous red blood cells without casts and 10–20 white blood cells per high power field. Urine bacterial culture and urine cytology examination were unremarkable. Transplant renal sonogram showed moderate hydronephrosis with hydroureter (Figure 1). Abdominal pelvic computerized tomography (CT) showed the hydronephrosis and a left ovarian mass consistent with a dermoid cyst; lymphadenopathy was absent. A percutaneous nephrostomy was placed on hospital Day 3, ciprofloxacin was given prophylactically and mycophenolic acid was discontinued. Serum creatinine decreased to 1.4 mg/dl. Cystoscopy performed on hospital Day 5 showed only a small discrete reddish granular area identified near the neo-orifice of the transplant ureter. A bladder biopsy showed normal uroepithelium with no inflammation or pathologic le-



**Fig. 1.** Renal transplant ultrasound. The renal ultrasound image shows the renal allograft in the right lower quadrant of the abdomen. The allograft measures 12.7 cm in the long axis and demonstrates moderate hydronephrosis.



**Fig. 2.** Localization of adenoviral antigen in the renal allograft. (A) Renal allograft biopsy revealed interstitial nephritis, with numerous mildly atypical lymphocytes, focal necrosis and haemorrhage. Arrow indicates a tubular epithelial cell nucleus with apparent viral cytopathic changes. Haematoxylin and eosin, original magnification  $\times 400$ . (B and C) Immunostaining for adenovirus antigens labelled several tubular cell nuclei and, more faintly, adjacent cytoplasm (dark brown diaminobenzidine product; haematoxylin counterstain; original magnification  $\times 400$ ).

sion. Three days later, the percutaneous nephrostomy was removed.

The patient had daily fevers to 39 °C. The tacrolimus dose was adjusted to maintain a 12-h trough level of 4–7 ng/ml. Blood and urine cultures, lupus serologies, PCR assays of the blood for adenovirus, Epstein–Barr virus, cytomegalovirus, BK virus (BKV) and parvovirus B19 were negative. Chest X-ray was unremarkable. She was initially reluctant to consent for a renal biopsy. Neutropenia developed, requiring filgrastim therapy. Subsequently, the serum creatinine increased to 2.4 mg/dl. A repeat sonogram showed resolution of the hydronephrosis.

The patient agreed to a renal allograft biopsy, which was performed on hospital Day 6. The biopsy showed necrotiz-

ing interstitial nephritis with tubular necrosis, a single granuloma and an inflammatory infiltrate largely comprised of dense plasmacytoid lymphocytes (Figure 2) which had sufficient cytologic atypia to initiate a work up for post-transplant lymphoproliferative disorder, which was ruled out by negative Epstein–Barr encoded small RNA *in situ* hybridization. No microorganisms were identified on Giemsa, periodic acid-Schiff and acid-fast bacillus stains. Immunoperoxidase stains for SV 40 large T antigen and C4d were negative.

Meanwhile, repeat CT scan studies of the chest, abdomen and pelvis were unremarkable, a positron emission tomography scan was unremarkable and a bone marrow aspirate and biopsy showed hypocellular marrow with no

**Table 1.** Adenoviral interstitial nephritis of renal allografts, proven by immunohistochemistry

Case	Reference	Age	Sex	Immunosuppression	Disease onset after transplant (months)	Presentation			Adenoviral detection			Interstitial nephritis		Follow-up	
						Fever	Gross haematuria	Acute kidney injury	Blood	Urine	Granulomatous	Necrotizing	Months	Serum creatinine (mg/dl)	
1	[8]	43	M	OKT3, Pr, Aza, Tac	3	+	+	+	NR	+	+	+	NR	NR	2.4
2	[10]	46	F	NR	1	+	-	+	NR	+	+	-	NR	NR	NR
3	[9]	60	M	BCM, Pr, My, CsA	1	-	+	-	NR	-	+	-	24	24	1.5
4	[11]	14	F	DCM, Pr, CsA	8	-	+	+	NR	+	-	-	NR	NR	1.5
5	[12]	46	F	BCM, Pr, My, Tac	18	+	+	+	NR	+	+	+	7	7	1.2
6	[13]	51	M	DCM, Pr, My, Tac	1	+	+	-	-	-	+	+	5	5	1.2
7	[14]	19	M	Pr, Aza, Tac	144	+	+	+	-	-	+	+	4	4	2.0
8	[4]	68	M	BCM, Pr, My, CsA	1	+	+	+	+	+	+	+	8	8	1.4
9	[6]	27	M	ATG, Ritux, Pr, MMF, CsA	6	+	+	+	+	+	+	+	12	12	1.3
10	[15]	64	M	Pr, My, CsA	2	+	+	+	+	+	+	+	6	6	8.0
11	Present case	45	F	ATG, Pr, My, Tac	17	+	+	+	-	ND	+	+	24	24	1.2

Presented are 11 published cases of adenoviral interstitial nephritis, all confirmed by immunohistochemistry. Abbreviations include the following: NR, not reported; ND, not determined; ATG, anti-thymocyte globulin; Aza, azathioprine; BCM, basiliximab; CsA, cyclosporine; DCM, daclizumab; My, mycophenolic acid; OKT3, muromonab; Pr, prednisone; Tac, tacrolimus.

**Table 2.** Renal manifestation of adenoviral infection

Acute haemorrhagic cystitis
Acute interstitial nephritis, with granulomatous and/or necrotizing changes
Acute kidney injury, including acute tubular necrosis
Obstructive uropathy
Renal mass

tumour or granulomas. Anti-human leukocyte antigen antibody levels were negative. The oral prednisone dose was increased to 15 mg daily. In the following days, the white cell count returned to normal, serum creatinine decreased slightly to 2.0 mg/dl and fevers abated. The patient was sent home 3 weeks after hospital admission, on prednisone 15 mg daily and tacrolimus 2 mg daily. Mycophenolic acid was not restarted. One week after discharge, a urine culture became positive for adenovirus.

Two months after discharge, creatinine had decreased to 1.7 mg/dl and microscopic haematuria had resolved. Prednisone was reduced to 10 mg daily. A repeat blood adenoviral PCR test was negative. Immunosuppressive therapy was targeted to a lower tacrolimus level 4–6 ng/ml and a slow taper of prednisone, over 3 months, to a target of 5 mg daily.

Subsequently, immunostaining for adenovirus antigens was performed, using antibody directed against adenovirus Type 3 protein antigens (Chemicon-Millipore, Billerica, MA) and lung tissue obtained from a patient who died with adenoviral pneumonia as a positive control tissue. Adenoviral antigens were detected within tubular epithelial cells (Figure 2). Two years later, the patient was doing well, with a stable serum creatinine of 1.2 mg/dl and normal urinalysis.

## Discussion

This case illustrates the difficulty of establishing the diagnosis of adenoviral nephritis in the renal allograft. Atypical features of our patient included late onset of the disease (17 months after transplant) and obstructive uropathy.

A search of the literature revealed 10 other cases of renal transplant-related adenoviral nephritis biopsy proven by immunostaining, all reported since 1998 (Table 1) [4,6,8–15]. Two were children and the others were adults. Seven patients were male and four were female. Most of the cases (eight out of 11) presented within 8 months of the transplant, at a mean of 2.9 months with a range of 1–8 months. Three cases presented later, at 17, 18 and 144 months, respectively. Most of the patients initially received induction immunosuppression and maintenance therapy with glucocorticoids, calcineurin inhibitors and mycophenolic acid. Patients commonly presented with gross haematuria and dysuria (10 out of 11), fever (nine out of 11) and acute renal failure (nine out of 11). Three patients required acute haemodialysis, but one patient failed to regain allograft function and returned to maintenance dialysis 6 months after transplant. As for the other patients, only limited follow-up was available, ranging from 4 to 24 months. Although most patients returned to baseline renal function, two reported patients had significant renal impairment at follow-up with serum creatinine

values of 2.0 and 2.4 mg/dl, respectively. The present case series shows that a significant minority (three out of 11, 27%) of patients were left with significant renal impairment following adenoviral nephritis, in contrast to previous reports [3,6].

Renal biopsy with specific immunohistochemical staining for adenovirus is required for definite diagnosis of adenoviral interstitial nephritis [2,7,16], but this assay is not readily available at most institutions. Traditionally, a diagnosis of adenoviral infection was made with a positive viral culture from urine, blood or tissue [2,16]. Recent applications of quantitative real-time PCR assays have improved sensitivity over traditional methods. However, the sensitivity, specificity and predictive value of PCR tests have yet to be established [2,7,16]. As shown in Table 1, only three out of 10 cases were blood PCR positive and seven out of 10 were urine PCR positive at the time of the diagnosis. In our patient, repeated tests of blood adenovirus PCR were negative.

Surveillance studies of asymptomatic adult renal transplant patients have shown an incidence of adenoviral viraemia by PCR testing of 6.5% and viruria by culture of 11% [2,16]. Asymptomatic viral shedding in the urine makes urinary cultures unreliable in the absence of signs and symptoms of disease activity. At present, there is no consensus regarding treatment of asymptomatic patients with detectable adenoviraemia. Ison concluded that screening of asymptomatic adult transplant solid organ recipient for adenovirus is not useful because progression to disease is infrequent [16].

Characteristic histologic changes of adenoviral interstitial nephritis are listed in Table 1. In the present series, nine out of 11 cases had granulomatous changes and eight out of 11 had necrotizing inflammation, while one case had interstitial nephritis only, without necrotizing changes or granulomas. It may be useful to compare histologic changes seen in adenoviral nephritis with the much more common BKV nephritis. Intranuclear 'smudge'-type viral inclusion bodies are typical of both BKV and adenoviral infection. Interstitial granulomatous changes have been reported in both BKV and adenoviral nephritis but are more common in adenoviral [7]. In a similar fashion, the necrotizing changes seen in adenoviral infection generally distinguish adenoviral nephritis from BKV nephropathy. Another difference between the two may be the lack of chronic changes with adenoviral nephritis, while BKV nephropathy is commonly associated with tubular atrophy and interstitial fibrosis. This may be related to the more indolent course and delay in diagnosis in BKV disease. Electron microscopy in adenoviral infection shows hexagonal virus particles of 70–80 nm in diameter, closely packed in a crystalline array, whereas BKV has an icosahedral shape with 40–44 nm in diameter [2,7,16,17]. Specific immunohistochemical stains for adenovirus and BKV most easily establish the correct diagnosis. There has been only one case report of concurrent adenovirus and BKV interstitial nephritis in a renal transplant patient [7].

Renal manifestations of adenoviral infection are shown in Table 2. Most common is acute haemorrhagic cystitis [2,3,7]. Acute interstitial nephritis with or without acute kidney injury syndrome is the second most common presenta-

tion. Less well appreciated is the fact that adenoviral infection, similar to BKV infection, may be associated with obstructive uropathy. Our patient and three others, two bone marrow transplant recipients [18,19] and a renal transplant recipient [14], developed hydronephrosis requiring percutaneous nephrostomy. All four had concurrent evidence of acute interstitial nephritis on biopsy. The other renal transplant patient with hydronephrosis also had a late presentation, 144 months post-transplant. The obstructive process resolved concurrent with the nephritis following reduction of immunosuppression or antiviral therapy. There were two reported cases of adenoviral nephritis associated with an inflammatory renal mass, one discovered at autopsy in a bone marrow transplant patient [20] and the other in a patient with a renal transplant who did well with therapy [13].

Reduction of immunosuppression after the onset of clinical infection is usually an effective therapeutic approach. In patients with a more severe clinical presentation, reduced immunosuppression and concomitant cidofovir, ribavirin and intravenous immunoglobulin have been successfully employed [16]. Antiviral therapy may carry significant risk for renal toxicity (notably with cidofovir) but merit consideration nonetheless. As adenoviral nephritis with or without other organ system involvement remains an uncommon complication in renal transplant recipients, there have been no randomized controlled trials of therapy or standard therapy guidelines.

In summary, this case report and review of the literature show that adenoviral nephritis should be considered in the renal transplant recipient with fever, haematuria, acute kidney injury and obstructive uropathy in both the early and late post-transplant periods. The obstructive uropathy seen in adenoviral nephritis tends to resolve with the resolution of interstitial nephritis. Reduction of immunosuppression is the most important therapeutic intervention, although more severe cases may benefit from additional antiviral therapy. Contrary to other case reports, this case series shows that renal function does not always recover to baseline following adenoviral nephritis. However, reported follow-up was limited for most patients. While granulomas and necrotizing interstitial changes are characteristic of adenoviral nephritis, immunohistochemical demonstration of adenovirus in biopsy tissue should be the standard for diagnosis and treatment guidance.

### Teaching points

- (1) Adenoviral nephritis should be considered in the renal transplant recipient with fever, haematuria, acute kidney injury and obstructive uropathy.
- (2) Obstructive uropathy tends to resolve with the resolution of interstitial nephritis.
- (3) Granulomas and necrotizing interstitial changes are characteristic of adenoviral nephritis and immunohistochemical demonstration of adenovirus in biopsy tissue should be the standard for diagnosis and treatment guidance.
- (4) Reduction of immunosuppression is the most important therapeutic intervention, although more severe cases may benefit from additional antiviral therapy.

- (5) Contrary to other case reports, renal function does not always recover to baseline following adenoviral nephritis.

*Acknowledgements.* This work was supported in part by the NCI and NIDDK Intramural Research Programs.

*Conflict of interest statement.* None declared.

### References

1. Myerowitz RL, Stalder H, Oxman MN *et al.* Fatal disseminated adenovirus infection in a renal transplant recipient. *Am J Med* 1975; 59: 591–598
2. Ison MG. Adenovirus infections in transplant recipients. *Clin Infect Dis* 2006; 43: 331–339
3. Hofland CA, Eron LJ, Washecka RM. Hemorrhagic adenovirus cystitis after renal transplantation. *Transplant Proc* 2004; 36: 3025–3027
4. Barraclough K, Oliver K, Preston J, Campbell S, Eps CV, Isbel N. Life-threatening adenovirus infection in a kidney transplant recipient. *NDT Plus* 2009; 2: 250–253
5. Rosario RF, Kimbrough RC, Van Buren DH *et al.* Fatal adenovirus serotype-5 in a deceased-donor renal transplant recipient. *Transpl Infect Dis* 2006; 8: 54–57
6. Hensley JL, Sifri CD, Cathro HP *et al.* Adenoviral graft-nephritis: case report and review of the literature. *Transpl Int* 2009; 22: 672–677
7. Colvin RB, Nijkeleit V. *Renal Transplant Pathology*. In: Jennette J, Olson J, Schwartz M *et al.* (eds). Philadelphia, PA: Lippincott-Raven, 2007
8. Mathur SC, Squiers EC, Tatum AH *et al.* Adenovirus infection of the renal allograft with sparing of pancreas graft function in the recipient of a combined kidney–pancreas transplant. *Transplantation* 1998; 65: 138–141
9. Asim M, Chong-Lopez A, Nijkeleit V. Adenovirus infection of a renal allograft. *Am J Kidney Dis* 2003; 41: 696–701
10. Friedrichs N, Eis-Hubinger AM, Heim A *et al.* Acute adenoviral infection of a graft by serotype 35 following renal transplantation. *Pathol Res Pract* 2003; 199: 565–570
11. Kim SS, Hicks J, Goldstein SL. Adenovirus pyelonephritis in a pediatric renal transplant patient. *Pediatr Nephrol* 2003; 18: 457–461
12. Emovon OE, Chavin J, Rogers K *et al.* Adenovirus in kidney transplantation: an emerging pathogen? *Transplantation* 2004; 77: 1474–1475
13. Lim AK, Parsons S, Ierino F. Adenovirus tubulointerstitial nephritis presenting as a renal allograft space occupying lesion. *Am J Transplant* 2005; 5: 2062–2066
14. Alsaad KO, Tobar A, Belanger E *et al.* Late-onset acute haemorrhagic necrotizing granulomatous adenovirus tubulointerstitial nephritis in a renal allograft. *Nephrol Dial Transplant* 2007; 22: 1257–1260
15. Gaspert A, Luthi B, Mueller NJ *et al.* Subacute allograft failure with dysuria and hematuria in a kidney transplant recipient. *Am J Kidney Dis* 2009; 54: 154–158
16. Ison MG. Adenovirus in solid organ transplant recipient. *Am J Transplant* 2009; 9: S161–S165
17. Drachenberg CB, Papadimitriou JC, Wali R *et al.* BK polyoma virus allograft nephropathy: ultrastructural features from viral cell entry to lysis. *Am J Transplant* 2003; 3: 1383–1392
18. Bruno B, Zager RA, Boeckh MJ *et al.* Adenovirus nephritis in hematopoietic stem-cell transplantation. *Transplantation* 2004; 77: 1049–1057
19. Mori K, Yoshihara T, Nishimura Y *et al.* Acute renal failure due to adenovirus-associated obstructive uropathy and necrotizing tubulointerstitial nephritis in a bone marrow transplant recipient. *Bone Marrow Transplant* 2003; 31: 1173–1176
20. Teague MW, Glick AD, Fogo AB. Adenovirus infection of the kidney: mass formation in a patient with Hodgkin's disease. *Am J Kidney Dis* 1991; 18: 499–502

*Received for publication: 4.2.10; Accepted in revised form: 19.2.10*