

# Histopathological Features of Drug-Induced Liver Injury Secondary to Osimertinib

Iván González, MD<sup>1</sup>, and Deyali Chatterjee, MD<sup>1</sup>

<sup>1</sup>Division of Anatomic and Molecular Pathology, Department of Pathology and Immunology, Washington University School of Medicine, St. Louis, MO

## ABSTRACT

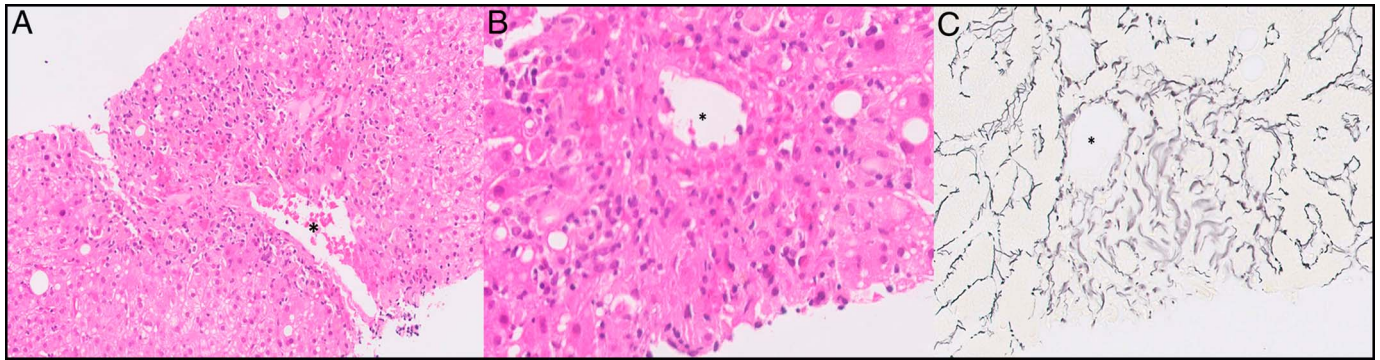
In the past few years, a better understanding of the genomic alterations in lung cancer has facilitated a targeted therapy. Lung adenocarcinomas with epidermal growth factor receptor mutations have a good response to tyrosine kinase inhibitors (TKIs). Osimertinib is a third-generation TKI approved by the Food and Drug Administration (FDA). Drug-induced liver injury is a well-known adverse effect of TKIs as a group and reported to show an autoimmune hepatitis-like picture. However, little is known about the histopathologic changes with osimertinib. We present a case of drug-induced liver injury secondary to osimertinib and discuss the histopathologic findings.

## INTRODUCTION

Recent developments in the understanding of the molecular biology of lung cancer have led to the use of targeted therapy for specific molecular signatures. The most common molecular alterations in lung adenocarcinomas include Ki-Ras2 Kirsten Rat Sarcoma (KRAS) gene (30%), epidermal growth factor receptor (EGFR; 10%–15%), and BRAF (7%) mutations.<sup>1,2</sup> Cases with EGFR mutations are known to have a high response rate to tyrosine kinase inhibitors (TKIs),<sup>3–6</sup> and in particular, EGFR exon 19 deletions are associated with better outcomes.<sup>7</sup> Osimertinib is a third-generation TKI selective for both EGFR TKI-sensitizing mutations and EGFR Thr790Met resistance mutations.<sup>4,5,8</sup> The most common documented adverse events with osimertinib use are diarrhea, skin toxicity, nausea, and anorexia.<sup>5</sup> In the AURA2 (ClinicalTrials.gov identifier: NCT02094261) study, 1 patient developed drug-induced liver injury (DILI) manifested by an increase in serum aminotransferase levels (<1%).<sup>4</sup> DILI secondary to TKIs such as imatinib and sorafenib has been associated with hepatocellular necrosis with some reports of concomitant cholestatic injury, especially with imatinib treatment.<sup>9</sup> However, little is known about the histologic features of osimertinib-induced liver injury.

## CASE REPORT

A nonsmoker 57-year-old woman with a right lower lobe lung adenocarcinoma presented with disseminated disease to the lymph nodes, bones, and brain. The patient's non-small-cell carcinoma had an exon 19 deletion in EGFR (E746-A750del), with low programmed death-ligand 1 (PD-L1) expression, and was negative for anaplastic lymphoma kinase gene rearrangement. The patient received palliative whole-brain radiation therapy and was started on osimertinib 40 mg daily. The patient was not taking any other drugs concomitantly. Subsequently, the patient developed transaminitis of unclear etiology. The patient also complained of chronic right upper quadrant pain, which was determined to be secondary to cholelithiasis. The patient underwent a cholecystectomy. It revealed cholesterosis and multiple stones in the gallbladder but none in the common bile duct. The enzymes continued to increase even after cholecystectomy, and a liver biopsy was performed 49 days after initiation of treatment with osimertinib, with the aspartate aminotransferase and alanine aminotransferase (ALT) levels of 519 U/L and 694 U/L, respectively, an alkaline phosphatase level of 86 U/L, and a bilirubin level of 0.6 mg/dL. An abdominal ultrasound before the biopsy showed a normal-sized liver with a normal echotexture and echogenicity. An abdominal magnetic resonance imaging was also performed and showed a normal liver appearance without steatosis or surface nodularity. The patient had negative serologies for hepatitis A antibody, hepatitis B core



**Figure 1.** (A and B) Disrupted lobular architecture secondary to pericentral confluent necrosis and parenchymal collapse, (C) highlighted with reticulin stain. The asterisk (\*) highlights the central vein.

antibody and surface antigen, and hepatitis C antibody. She also had negative antinuclear antibody and antimitochondrial antibody in serum.

A core needle biopsy from the liver showed a mildly disrupted lobular architecture on routine hematoxylin and eosin staining, secondary to pericentral confluent necrosis and parenchymal collapse, also confirmed by a reticulin stain (Figure 1). There were no other features to suggest sinusoidal obstruction syndrome: the central vein appeared intact, and there was no sinusoidal dilatation or congestion. A mild mixed chronic inflammatory infiltrate surrounding the necrotic areas was identified, predominantly composed of macrophages with rare lymphocytes and plasma cells. The portal tracts showed mild nonspecific chronic inflammation, without interface activity. The trichrome stain showed no portal expansion, periportal or bridging fibrosis. The bile ducts were preserved and did not show signs of injury. There was no ductular proliferation. No granuloma, cholestasis, or significant steatosis was identified. Investigating more into the clinical condition did not reveal any predisposing factors to account for venous obstruction or an ischemic or cardiogenic process.

Treatment with osimertinib was discontinued, and the liver enzymes started downtrending, with the aspartate aminotransferase and ALT levels of 54 and 55 U/L, respectively, an alkaline phosphatase level of 91 U/L, and a bilirubin level of 0.6 mg/dL, 53 days after discontinuation.

## DISCUSSION

DILI is one of the leading causes of liver failure in the United States,<sup>10</sup> but an accurate and early diagnosis is challenging and in most cases is a diagnosis of exclusion. In 2003, the National Institute of Diabetes and Digestive and Kidney Diseases established the Drug-Induced Liver Injury Network,<sup>10</sup> which is a multicenter observational study of consecutive cases of DILI enrolled at eight academic medical centers in the United States.<sup>10,11</sup>

Clinically, DILI is classified as hepatocellular, cholestatic, or mixed, on the basis of its biochemical pattern of injury. Our case is best classified as hepatocellular, which is a pattern of injury

defined by an increase in the ALT level greater than 2–5 times the upper limit and/or ALT/alkaline phosphatase ratio greater than 5.<sup>9</sup> Drug-Induced Liver Injury Network lists eighteen distinct histologic patterns of liver injury: acute hepatitis, chronic hepatitis, acute cholestasis, chronic cholestasis, cholestatic hepatitis, granulomatous hepatitis, macrovesicular steatosis, microvesicular steatosis, steatohepatitis, zonal necrosis, nonzonal necrosis, vascular injury, hepatocellular alteration, nodular regenerative hyperplasia, mixed or unclassified injury, minimal nonspecific changes, absolutely normal, and massive necrosis.<sup>9–11</sup> This case would qualify as zonal necrosis. Kleiner et al grouped 83% of their 249 cases into 5 histologic patterns: acute hepatitis, chronic hepatitis, acute cholestasis, chronic cholestasis, and cholestatic hepatitis.<sup>11</sup> Little is known about the histological changes of TKI-induced DILI. Some case reports of DILI secondary to TKIs, specifically imatinib and sorafenib, have been associated with hepatocellular necrosis, with some reports of concomitant cholestatic injury, especially with imatinib treatment.<sup>9</sup> There has been no documentation of histologic changes with DILI so far, from third-generation TKIs.

Our case presented with DILI secondary to osimertinib, which is a third-generation TKI used in the treatment of EGFR TKI-sensitizing mutations and EGFR Thr790Met resistance mutations.<sup>4,5,8</sup> In the AURA2 study, only 1 patient (<1%) developed DILI secondary to osimertinib.<sup>4</sup> The liver biopsy in our case showed pericentral confluent necrosis and parenchymal collapse, as described earlier. Pericentral necrosis has been reported in other TKIs, but to our knowledge, confluent necrosis has not been previously described secondary to TKIs. Imaging studies before the biopsy showed a normal liver architecture, highlighting the importance of a liver biopsy in this setting. The differential diagnosis of pericentral confluent necrosis usually includes acetaminophen toxicity, acute viral hepatitis, and acute autoimmune hepatitis.<sup>9,12</sup> Our patient did not have histologic or serologic evidence of autoimmune and acute viral hepatitis and was not taking acetaminophen or any other drugs concomitantly. Moreover, unlike in acute viral or autoimmune hepatitis, there was no portal or lobular inflammation elsewhere. The patient discontinued treatment with osimertinib, and the liver enzymes started to decrease and reached almost normal values 1 month after discontinuation.

Hirabayashi et al, reported a case of osimertinib-induced fever and hepatotoxicity after 15 days of treatment.<sup>8</sup> Similarly, Yoshida and Kim<sup>13</sup> reported a similar case of grade 2 hepatotoxicity developing 1 month after initiation of osimertinib treatment.<sup>13</sup> No histopathologic findings were discussed in either of the cases. In both cases, the authors reduced the dose of treatment without success; however, on oral desensitization, the patients successfully continue treatment without recurrence of side effects. More cases are needed to further characterized DILI secondary to osimertinib and the potential use of oral desensitization.

## DISCLOSURES

Author contributions: I. González reviewed the literature, and wrote and edited the article. D. Chatterjee reviewed the literature, edited the article, and is the article guarantor.

Financial disclosure: None to report.

Informed consent was obtained for this case report.

Received April 16, 2018; Accepted November 16, 2018

## REFERENCES

- Devarakonda S, Morgensztern D, Govindan R. Genomic alterations in lung adenocarcinoma. *Lancet Oncol*. 2015;16:342–51.
- Barr N, Zanwijk NV, Soo RA. Molecular targeted therapy in the treatment of advanced stage non-small cell lung cancer (NSCLC). *Respiratory*. 2015; 20:370–8.
- Tan DS, Yom SS, Tsao MS, et al. The International Association for the Study of Lung Cancer Consensus statement on optimizing management of EGFR mutation-positive non-small cell lung cancer: Status in 2016. *J Thorac Oncol*. 2016;11(7):946–63.
- Goss G, Tsai CH, Shepherd F, et al. Osimertinib for pretreated EGFR Thr790Met-positive advanced non-small-cell lung cancer (AURA2): A multicentre, open-label, single-arm, phase 2 study. *Lancet Oncol*. 2016;17: 1643–52.
- Sullivan I, Planchard D. Osimertinib in the treatment of patients with epidermal growth factor receptor T790M mutation-positive metastatic non-small cell lung cancer: Clinical trial evidence and experience. *Thorax*. 2016;10(6):549–65.
- Vestergaard HH, Christensen MR, Lassen UN. A systematic review of targeted agents for non-small cell lung cancer. *Acta Oncol*. 2018;57(2): 176–86.
- Rossi S, D'Argento E, Basso M, et al. Different EGFR gene mutations in exon 18, 19 and 21 as prognostic and predictive markers in NSCLC: A single institution analysis. *Mol Diagn Ther*. 2016;20(1):55–63.
- Hirabayashi R, Fujimoto D, Satsuma Y, Hirabatake M, Tomii K. Successful oral desensitization with osimertinib following osimertinib-induced fever and hepatotoxicity: A case report. *Invest New Drugs*. 2018; 36(5):952–4.
- Fisher K, Vuppalanchi R, Saxena R. Durg-induced liver injury. *Arch Pathol Lab Med*. 2015;139:876–87.
- Fontana RJ, Watkins PB, Bonkovsky HL, et al. Drug-Induced Liver Injury Network (DILIN) prospective study: Rationale, design and conduct. *Drug Saf*. 2009;32(1):55–68.
- Kleiner DE, Chalasani NP, Lee WM, et al. Hepatic histological findings in suspected drug-induced liver injury: Systematic evaluation and clinical associations. *Hepatology*. 2014;59(2):661–70.
- Krishna M. Patterns of necrosis in liver disease. *Clin Liver Dis*. 2017;10(2): 53–6.
- Yoshida H, Kim YH. Successful osimertinib rechallenge after Severe osimertinib-induced hepatotoxicity. *J Thorac Oncol*. 2017;12(5):61–3.

**Copyright:** © 2019 The Author(s). Published by Wolters Kluwer Health, Inc. on behalf of The American College of Gastroenterology. This is an open-access article distributed under the terms of the Creative Commons Attribution-Non Commercial-No Derivatives License 4.0 (CCBY-NC-ND), where it is permissible to download and share the work provided it is properly cited. The work cannot be changed in any way or used commercially without permission from the journal.