

Spontaneous eruption of maxillary third molars in the adult patient undergoing orthodontic treatment after first molar extractions

Kelly Jackson¹  | Desmond Ong^{1,2}  | Elissa Freer¹ 

¹School of Dentistry, The University of Queensland, Brisbane, QLD, Australia

²Private Practice, Townsville, QLD, Australia

Correspondence

Kelly Jackson, School of Dentistry, The University of Queensland, Brisbane, QLD 4072, Australia.
Email: kelly.jackson@uqconnect.edu.au

Abstract

Class II division 1 malocclusions are common, and first permanent molars are frequently compromised teeth. Removal of compromised maxillary first permanent molars with planned orthodontic treatment can result in favorable treatment outcomes.

KEYWORDS

compromised first permanent molars, orthodontic treatment, third molar eruption

1 | INTRODUCTION

The orthodontic treatment of Class II division 1 malocclusions frequently requires the extraction of maxillary premolars; however, the extraction of compromised first permanent molars may also result in favorable outcomes. Subsequent extraction space closure may also result in the eruption of impacted maxillary third molars in mature adult patients.

Angle's Class II division 1 malocclusion is defined as any malocclusion with a Class II molar relationship with greater than half-a-cusp displacement and protruding maxillary incisors. Class II division 1 malocclusion patients can display a diverse range of underlying skeletal morphologies, dental characteristics, and soft tissue patterns.

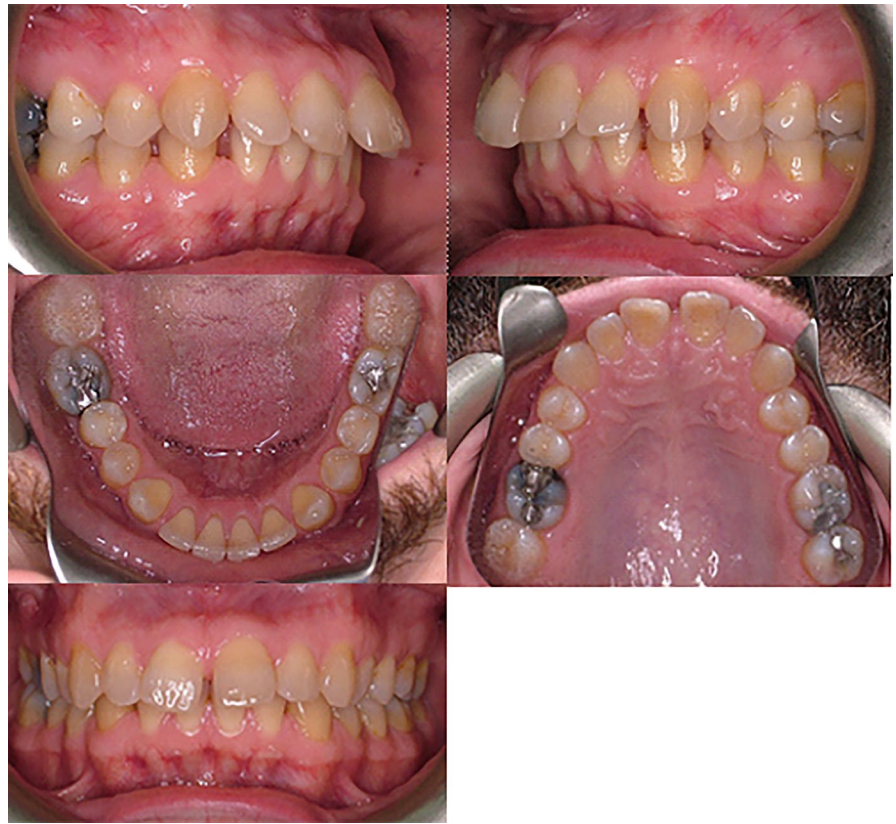The presence of such variation requires careful and customized treatment planning for the individual patient. Extraction of maxillary first or second premolars may be indicated for Class II division 1 patients with normal mandibular projection, minimal mandibular crowding and significantly proclined maxillary incisors.¹ It is widely acknowledged that first permanent molars are more commonly affected by developmental enamel defects,² caries,³ or large pre-existing restorations. In situations where the maxillary first permanent molars are significantly compromised, removal of these

compromised teeth may be both justifiable and extremely beneficial for the patient.⁴⁻⁶ Space gained from the bilateral extraction of compromised maxillary first permanent molars can be utilized for overjet reduction, correction of the Class II malocclusion and dental alignment.⁵

Third permanent molars are recognized as the teeth with the highest incidence of impaction with studies indicating that 17-25 percent of the population have one or more impacted third molars.^{7,8} Prior to recommending extraction of any maxillary first permanent molars, the presence, morphology, angulation, and eruption path of the maxillary second and third permanent molars should be considered, as these teeth will potentially become part of the functional dentition.⁹ Studies indicate that extraction of the maxillary first or second permanent molars can significantly improve the angulation and future eruption potential of unerupted maxillary third molars on that same side, as closure of the resultant extraction space often permits mesial bodily movement of the third molars.^{10,11} This subsequent increase in eruption space may significantly reduce the frequency of third molar impaction in such cases.^{10,12-17}

Although the potential for successful third molar eruption appears to be more predictable when second permanent molars are removed, well-timed extraction of maxillary first permanent molars in conjunction with active orthodontic space

FIGURE 1 Pretreatment intraoral photographs of a thirty-seven-year-old patient with a Class II division 1 malocclusion and anterior dental spacing. The anterior overjet was measured to be 10mm, and the vertical anterior overbite measured as 60 percent. The molar and canine relationships were determined to be in a half-unit Class II relationship



closure can provide pleasing outcomes in adolescent patients.¹⁸ The predictability of such treatment for adult patients remains questionable, as the expected eruption potential for maxillary third molar teeth with complete root formation reduces with age.¹⁹ In addition, published peer-reviewed studies on this topic are very limited. This case report presents the treatment of an adult patient with a Class II division 1 malocclusion involving bilateral maxillary first permanent molar extractions and unexpected, yet favorable spontaneous eruption of the impacted and mature maxillary third permanent molar teeth.

2 | CASE REPORT

A thirty-seven-year-old male patient presented with a desire to reduce his maxillary incisor protrusion. The orthodontic

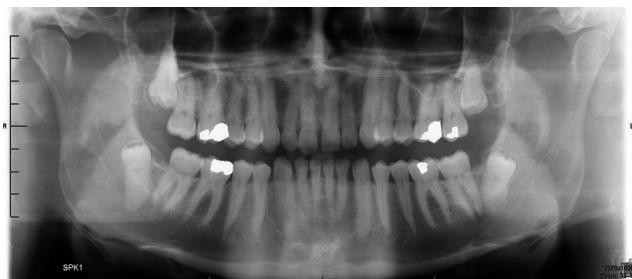

FIGURE 2 Pretreatment panoramic radiograph. All permanent teeth are present, including impacted third molars with complete root formation. Large amalgam restorations are present in the 16, 26, and 46

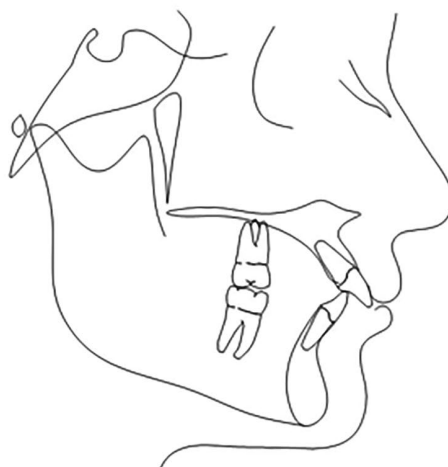
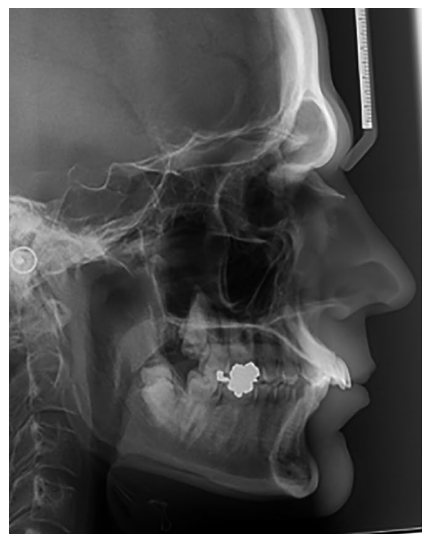diagnostic assessment revealed a Class II division 1 malocclusion with anterior spacing in the maxillary and mandibular arches (Figures 1 and 2). The overjet was measured to be 10mm, and the anterior vertical overbite covered approximately 60 percent of the crown heights of the mandibular incisors (Table 1). The posterior occlusion was determined to be in a half-unit Class II relationship, where the mesiobuccal cusp of the maxillary first molar occludes with the mesiobuccal cusp of the mandibular first molar (Table 1 and Figure 1).²⁰ The pretreatment panoramic radiograph demonstrated that all permanent teeth including the third molars were present (Figure 2). The maxillary and mandibular third molars were impacted and exhibited complete root formation (Figure 2). Large amalgam restorations were noted in the 16, 26, and 46 (Figure 1). Cephalometric analysis revealed a mild skeletal Class II base relationship with brachyfacial vertical proportions (Figure 3, Table 2). Given the severity of the anterior overjet and the absence of any significant remaining growth potential, removal of two maxillary teeth was suggested as a reasonable treatment option.

Prior to confirming the treatment plan, the orthodontist referred the patient to a general dentist to evaluate the large restorations in the 16 and 26 and to provide an opinion regarding their current integrity and expected long-term restorative requirements. The general dentist reported that although the restorations in the 16 and 26 were currently satisfactory, the restorations were large and likely to require ongoing maintenance and probable replacement

Horizontal dental features

Molar relationship	½ unit (end-on) Class II
Canine relationship	½ unit (end-on) Class II
Anterior overjet	10mm
Maxillary incisor-palatal plane	129.5° (110.0° ± 5.0°) McLaughlin (mean and standard deviation)
Mandibular incisor-mandibular plane	107.7°

Note: Vertical dental features: Anterior Overbite with 60 percent coverage of mandibular incisors. Transverse dental features: No posterior crossbites noted; No significant dental arch asymmetry noted; Dental midlines coincident with each other and the facial midline. Other dental features: Large pre-existing restorations in 16, 26, and 46; Impacted and unerupted 18, 28, 38, and 48 with complete root development.

TABLE 1 Pretreatment dental analysis**FIGURE 3** Pretreatment lateral cephalograph and tracing (black) demonstrates a mild Class II skeletal base relationship with brachyfacial vertical proportions

over the patient's lifetime. The general dentist and orthodontist agreed that, should removal of two maxillary teeth be required to achieve an effective orthodontic treatment

TABLE 2 Pretreatment facial and cephalometric analysis

Horizontal skeletal base relationship		
SNA	89.3° (82.0° ± 3.5°)	Steiner (mean and standard deviation)
SNB	86.6° (80.9° ± 3.4°)	Steiner
ANB	2.7° (1.6° ± 1.5°)	Steiner
Wits	6.6mm (−1.0mm ± 1.0mm)	
Vertical skeletal base relationship		
Mandibular plane angle	16.6° (25° ± 5°)	Ricketts (mean and standard deviation)
Facial angle	89.0° (89.6° ± 3.0°)	Ricketts
Facial axis angle	98.9° (90.0° ± 3.5°)	Ricketts
Lower facial height	39.0° (45.0° ± 4.0°)	Ricketts

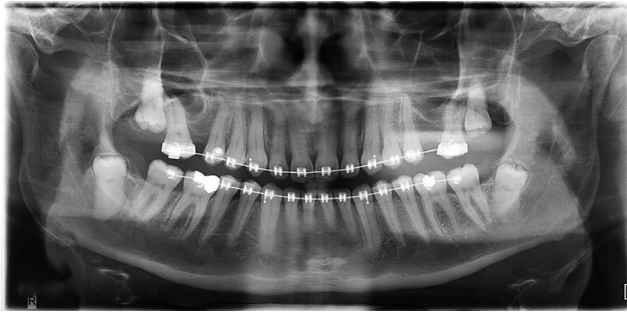
Note: Transverse skeletal base relationship: No significant facial asymmetry was noted. Cephalometric summary: Class II division 1 malocclusion on a mild skeletal Class II base with increased anterior overjet and deep anterior overbite with brachyfacial vertical proportions.

outcome, the restored 16 and 26 would be the most appropriate candidates for extraction. Complete closure of the resultant extraction sites would be performed with orthodontic treatment with such space closure expected to facilitate correction of the increased anterior overjet and half-unit Class II posterior occlusal relationship (Treatment Option One). Due to the absence of crowding and increased anterior overjet, no mandibular teeth were recommended for extraction in conjunction with the proposed orthodontic treatment. Subsequent spontaneous eruption of the impacted maxillary third molars was not expected given their pretreatment position, their complete root formation, and the patient's chronological age.

The impacted mandibular third molars were asymptomatic with no clinical or radiographic signs of pathology. Following a detailed discussion with both the orthodontist and oral and maxillofacial surgeon, periodic monitoring of these teeth rather than extraction was deemed to be appropriate. Given the patient's age, lack of retro-molar space, and disto-angulation of the mandibular third molars, spontaneous eruption was unlikely to occur.²¹ Indications for removal of mandibular third molars have been reported to include the presence of symptoms, clinical or radiographic signs of pathology or other dental and general diseases.²¹ The relative

TABLE 3 Summary of the relevant risks and costs

	Treatment option 1	Treatment option 2
Financial cost	+	++
Biological cost	+	++
Risk of incomplete Orthodontic correction of the presenting malocclusion	Minimal	Likely (unless orthognathic surgery is performed)

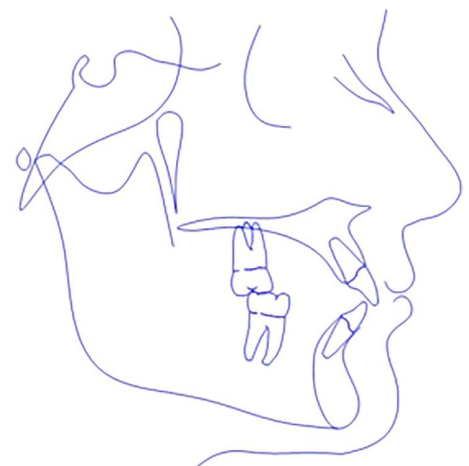
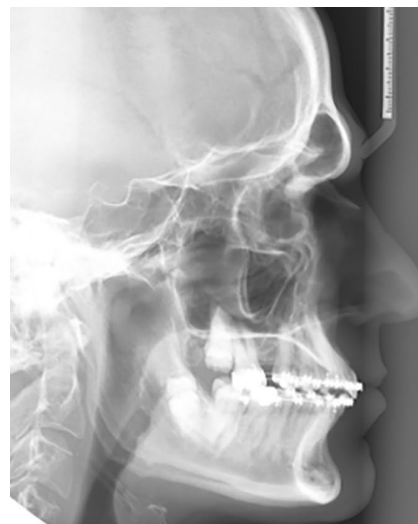**FIGURE 4** Progress panoramic radiograph taken ten months into treatment demonstrates acceptable overall root parallelism and incomplete closure of the 16 and 26 extraction spaces

infrequency (i.e. 1-2 percent) of adverse consequences such as tumors and odontogenic cysts questions the justification for extracting asymptomatic third molars to prevent the development of pathological sequelae.²² Despite this, preventative mandibular third molar extractions may still be considered justifiable subject to an individual patient's life situation, general medical health, career, or special interests.²¹ Extraction of the asymptomatic and disease-free mandibular third molars for this mature adult patient²³ may be associated with an increased risk of a delayed return to his usual lifestyle,²³ more difficult surgery, and trigeminal nerve injury.²⁴ Following consideration of the patient's age, pre-existing disto-angular

impaction of the asymptomatic mandibular third molars, and the relatively small likelihood of developing subsequent pathology, the clinicians involved determined that the risks associated with their extraction significantly outweighed any potential prophylactic benefits of this procedure.

An alternative nonextraction orthodontic treatment plan was considered (Treatment Option Two). This treatment plan involved no tooth extractions, with comprehensive fixed orthodontic appliance therapy to correct the presenting malocclusion. With this treatment plan, the patient will knowingly accept that the compromised first maxillary molars are likely to require future restorative treatment and a residual anterior overjet would be expected on completion of the orthodontic treatment, unless a surgical mandibular advancement was provided. Both the patient and the orthodontist did not consider the skeletal discrepancy to be severe enough to warrant a more invasive and costly surgical-orthodontic treatment plan. The patient was presented with the relevant treatment options along with their relative advantages and disadvantages, which included the expected financial and biological costs (Table 3). Incomplete orthodontic correction of the presenting malocclusion was not expected to satisfy the treatment expectations of patient, general dentist, or orthodontist. After providing appropriate informed consent, the patient chose to have the compromised 16, 26 removed in conjunction with comprehensive fixed appliance orthodontic treatment (Treatment Option One). The patient was not interested

FIGURE 5 Progress treatment cephalometric radiograph and tracing (blue) demonstrates a reduction in the anterior overjet and bodily mesial movement of the maxillary second permanent molar



in mandibular advancement orthognathic surgery and did not wish to maintain the compromised 16, 26 (Treatment Option Two).

Prior to commencing orthodontic treatment, the 16 and 26 were removed uneventfully under local anesthesia. Following orthodontic leveling and aligning, active intra-arch space closure was commenced. The patient was advised that excellent compliance wearing bilateral Class II intermaxillary elastics would be essential to achieve an effective correction of the Class II division 1 malocclusion. Stainless steel buttons were bonded to the palatal aspect of both maxillary second premolars to facilitate efficient orthodontic space closure. The progress panoramic radiograph (Figure 4) taken 10 months into the fixed appliance treatment demonstrates acceptable overall root parallelism and incomplete closure of the 16 and 26 extraction spaces. The progress lateral cephalograph (Figure 5, Table 4) demonstrates a decrease in overjet and mesial bodily movement of the second permanent molar. Superimposition of the pretreatment and progress cephalographs revealed positive dentoalveolar changes.

Approximately 28 months into the fixed appliance treatment the patient reported discomfort in the posterior aspects of the maxillary arch. It was determined that the maxillary third permanent molars were erupting clinically. Following 31 months of active orthodontic treatment, the fixed

appliances were removed and flossable stainless steel wire retainers were subsequently bonded to the maxillary and mandibular anterior teeth (Figure 6). Maxillary and mandibular vacuum-formed removable retainers were also issued for indefinite nocturnal wear. Two years following the completion of the fixed appliance orthodontic treatment, the 18 and 28 were noted to have spontaneously erupted into excellent functional positions (Figure 7). The patient was 42.5 years of age at this time point.

3 | DISCUSSION

This case report demonstrated a very pleasing treatment outcome, with an effective orthodontic correction of the pre-treatment Class II division 1 malocclusion. The 16 and 26 extraction spaces were closed, with no reopening of these extraction spaces occurring post-treatment. Despite the 18 and 28 showing no previous signs of eruption and having complete root formation for many years, the orthodontic mesialisation of the 17 and 27 provided additional space in the maxillary posterior region. Given the age and complete root development of the 18 and 28, the likelihood of spontaneous eruption of these teeth was not estimated to be high.^{25,26} Despite these factors, the 18 and 28 did spontaneously erupt, which further enhanced the overall treatment outcome from the functional perspective. The eruption of the 18 and 28 was likely due to the creation of space distal to the maxillary second molars. This additional space then allowed for the appropriate change in angulation of the maxillary third molars and subsequently created an eruption path for these previously impacted teeth.

The likelihood of the spontaneous eruption of bilateral maxillary third molars from an impacted position with complete root formation at 42.5 years of age was low, as this is significantly later than the expected physiological eruption age. Space permitting, maxillary third permanent molars generally commence clinical eruption at approximately 17 to

TABLE 4 Treatment progress: Cephalometric analysis

	Pretreatment measurements	Progress measurements	Change
SNA	89.3°	87.6°	−2.3
SNB	86.6°	85.8°	−0.8°
ANB	2.7°	1.8°	−0.9°
Wits	6.6mm	4.8mm	1.8mm
Mandibular plane angle	16.6°	19.8°	3.2°
Facial angle	89.0°	88.2°	−0.8°
Facial axis angle	98.9°	97.4°	−1.5°
Lower facial height	39.0°	40.6°	1.6°
Maxillary incisor-palatal plane	129.5°	117.2°	−12.3°
Mandibular incisor-Mandibular plane	107.7°	111.1°	3.4°

Note: Cephalometric interpretation: The Class II division 1 malocclusion has been improved through effective retraction of the maxillary incisor position and acceptable proclination of the mandibular incisor position. The change in the vertical cephalometric measurements reflects a slight clockwise rotation of the mandible during treatment. Clockwise rotation of the mandible often accompanies reduction of a deep anterior overbite and Curve of Spee through requisite orthodontic extrusion of the mandibular molars.

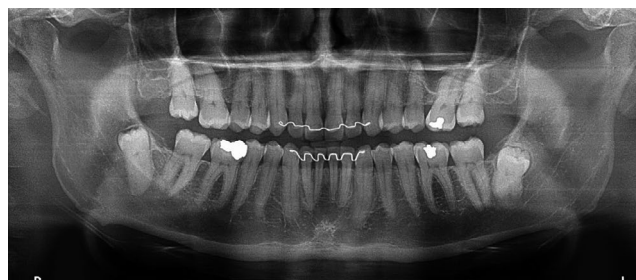


FIGURE 6 Post-treatment panoramic radiograph demonstrates satisfactory root parallelism and complete eruption of maxillary third molars. The mandibular third molars have remained unchanged, and no evidence of pathology is noted

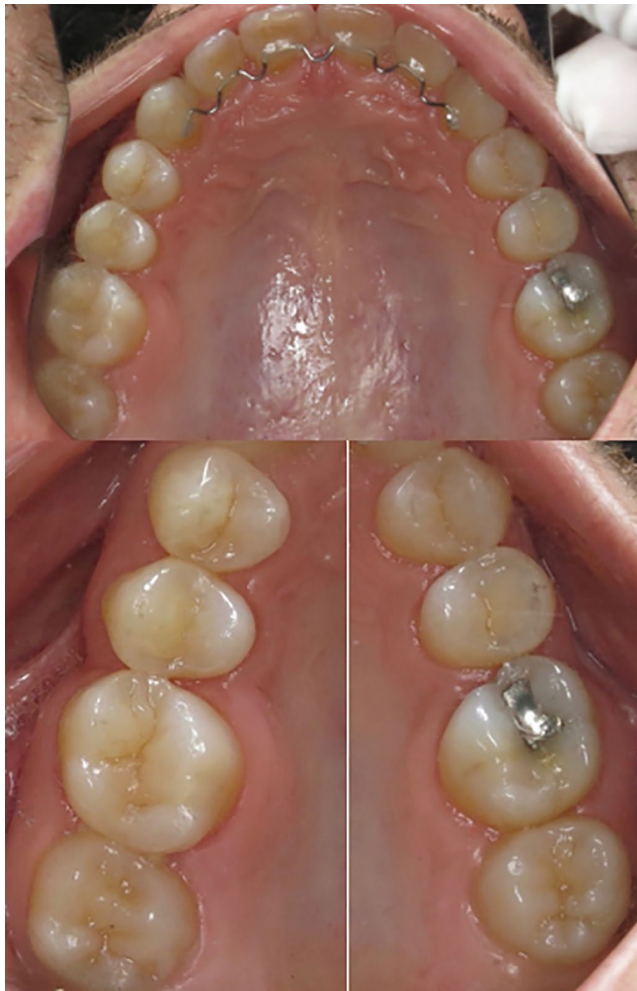

FIGURE 7 These intraoral photographs reveal the excellent functional position of the recently erupted maxillary third molars

21 years of age; however, their roots are not usually not completely formed until up to 25 years of age.¹⁸

The rate of spontaneous eruption decreases with age though, with only ten percent of unerupted third molars expected to spontaneously erupt between 20 and 38 years of age.²⁵ For these patients in their twenties and thirties, the position of these erupted maxillary third molars is generally not functional and the erupting tooth is often carious or periodontally involved.²⁵ It is therefore generally accepted that after age of 25, spontaneous eruption of a maxillary third molar into a functional position is unlikely.²⁶ Although age plays a significant role in the likelihood of eruption of maxillary third molars, the availability of space in the arch is also strongly associated with eruption outcomes.

The presence of retro-molar space provided by permanent tooth extractions, natural spacing, or orthodontic mesialisation of the first and second permanent molar teeth significantly increases the probability of eruption of third molars.²⁷ Studies have reported that having a missing tooth in a quadrant increases the probability of eruption of

maxillary third molar teeth, due to the presence of increased space availability.²⁶ Clinical research has also reported that extraction of maxillary first or second permanent molars in conjunction with orthodontic treatment can increase the rate of eruption of maxillary third permanent molars.^{14,15,18} Comprehensive orthodontic treatment can effectively provide true mesial translation movement of maxillary second permanent molars following extraction of the maxillary first permanent molars.^{11,28} The combination of space created through extractions and controlled bodily mesialisation of the maxillary second permanent molars may also encourage the spontaneous eruption of maxillary third permanent molars from a previously impacted position.⁸ The presence, angulation, and eruption path of third maxillary molars should be carefully evaluated prior to the commencement of orthodontic treatment, particularly in patients who demonstrate significant compromise of maxillary posterior teeth.

4 | CONCLUSION

This case report documents several advantages of judicious removal of compromised maxillary first permanent molars for an adult patient with a Class II division 1 malocclusion. The presenting malocclusion was effectively resolved through relatively conservative orthodontic treatment and favorable spontaneous eruption of the previously impacted maxillary third molars occurred despite the maturity of the patient.

ACKNOWLEDGMENTS

The authors wish to sincerely thank and acknowledge the following clinicians for their involvement in the overall management for this case: Dr Jiten Rao (General Dentist), Dr Desmond Ong (Orthodontist), and Dr Geoffrey Dance (Oral and Maxillofacial Surgeon).

The authors also wish to sincerely thank the patient for kindly granting permission to use the clinical records and photographs for the purpose of continuing professional development.

CONFLICT OF INTEREST

None declared.

AUTHOR CONTRIBUTION

KJ and EF: were the authors and collaborators. DO: was the clinician and author, and involved in data collection and analysis.

ORCID

Kelly Jackson  <https://orcid.org/0000-0002-3364-3921>
Desmond Ong  <https://orcid.org/0000-0002-0557-0657>
Elissa Freer  <https://orcid.org/0000-0003-2692-9064>

REFERENCES

- Verma S, Sharma V, Singh G, Sachan K. Comparative assessment of soft-tissue changes in Class II Division I patients following extraction and non-extraction treatment. *Dent Res J*. 2013;10:764-771.
- Arrow P. Prevalence of developmental enamel defects of the first permanent molars among school children in Western Australia. *Aust Dent J*. 2008;53:250-259.
- Todd JE, Dodd DT. *Children's Dental Health*. London, UK: HMSO; 1983.
- Dhole P, Maheshwari D. Orthodontic space closure using simple mechanics in compromised first molar extraction spaces: Case series. *J Indian Orthod Soc*. 2018;52:51-59.
- Ong DCV, Bleakley J. Compromised first permanent molars: an orthodontic perspective. *Aust Dent J*. 2010;55:2-14.
- Halicioglu K, Toptas O, Akkas I, Celikoglu M. Permanent first molar extraction in adolescents and young adults and its effect on the development of third molar. *Clin Oral Investig*. 2014;18:1489-1494.
- Richardson M. The development of third molar impaction and its prevention. *Int J Oral Surg*. 1981;10:122.
- Janson G, Putrick LM, Henriques JF, de Freitas MR, Henriques RP. Maxillary third molar position in Class II malocclusions: the effect of treatment with and without maxillary premolar extractions. *Eur J Orthod*. 2006;28:573-579.
- Seddon JL. Extraction of four first molars: a case for a general practitioner? *J Orthod*. 2004;31:80-85.
- Cavanaugh JJ. Third molar changes following second molar extractions. *Angle Orthod*. 1985;55:70-76.
- Booij JW, Goeke J, Bronkhorst EM, Katsaros C, Ruf S. Class II treatment by extraction of maxillary first molars or Herbst appliance: dentoskeletal and soft tissue effects in comparison. *J Orofac Orthop*. 2013;74:52-63.
- Rindler A. Effects on lower third molars after extraction of second molars. *Angle Orthod*. 1977;47:55-58.
- Gaumond G. Second molar germectomy and third molar eruption. 11 cases of lower second molar enucleation. *Angle Orthod*. 1985;55:77-88.
- Gooris C, Rtun J, Joondeph D. Eruption of mandibular third molars after second-molar extractions: A radiographic study. *Am J Orthod Dentofacial Orthop*. 1990;98:161-167.
- Orton Gibbs S, Crow V, Orton HS. Eruption of third permanent molars after the extraction of second permanent molars. Part 1: Assessment of third molar position and size. *Am J Orthod Dentofacial Orthop*. 2001;119:226-238.
- Kim TW, Årtun J, Behbehani F, Artese F. Prevalence of third molar impaction in orthodontic patients treated nonextraction and with extraction of 4 premolars. *Am J Orthod Dentofacial Orthop*. 2003;123:138-145.
- Richardson ME. Some aspects of lower third molar eruption. *Angle Orthod*. 1974;44:141-145.
- Bayram M, Özer M, Arici S. Effects of first molar extraction on third molar angulation and eruption space. *Oral Surg Oral Med Oral Pathol Oral Radiol Endod*. 2009;107:e14-e20.
- De La Rosa GC, Valmaseda Castellón E, Gay EC. Spontaneous third-molar eruption after second-molar extraction in orthodontic patients. *Am J Orthod Dentofacial Orthop*. 2006;129:337-344.
- Janson G, Sathler R, Fernandes TMF, Zanda M, Pinzan A. Class II malocclusion occlusal severity description. *J Appl Oral Sci*. 2010;18:397-402.
- Ventä I. How often do asymptomatic, disease-free third molars need to be removed? *J Oral Maxillofac Surg*. 2012;70:S41-S47.
- Dodson TB. How many patients have third molars and how many have one or more asymptomatic, disease-free third molars? *J Oral Maxillofac Surg*. 2012;70:S4-S7.
- Phillips C, White RP. How predictable is the position of third molars over time? *J Oral Maxillofac Surg*. 2012;70:S11-S14.
- Renton T, Al-Haboubi M, Pau A, Shepherd J, Gallagher JE. What has been the United Kingdom's experience with retention of third molars? *J Oral Maxillofac Surg*. 2012;70:S48-S57.
- Ventä I, Ylipaavalniemi P, Turtola L. Clinical outcome of third molars in adults followed during 18 years. *J Oral Maxillofac Surg*. 2004;62:182-185.
- Ventä I, Murtomaa H, Turtola L, Meurman J, Ylipaavalniemi P. Clinical follow-up study of third molar eruption from ages 20 to 26 years. *Oral Surg Oral Med Oral Pathol*. 1991;72:150-153.
- Miclotte A, Grommen B, de Llano C, et al. The effect of first and second premolar extractions on third molars: A retrospective longitudinal study. *J Dent*. 2017;61:55-66.
- Jacobs C, Jacobs Müller C, Luley C, Erbe C, Wehrbein H. Orthodontic space closure after first molar extraction without skeletal anchorage. *J Orofac Orthop*. 2011;72:51-60.

How to cite this article: Jackson K, Ong D, Freer E. Spontaneous eruption of maxillary third molars in the adult patient undergoing orthodontic treatment after first molar extractions. *Clin Case Rep*. 2020;8:1392–1398. <https://doi.org/10.1002/ccr3.2934>