

Irreversible Kidney Damage due to Multicentric Castleman's Disease

Fredrik Kahn¹, Anna Fagerström², Mårten Segelmark² and Omran Bakoush²

¹ Department of Infectious Disease, and ² Department of Nephrology, Lund University Hospital, Lund, Sweden

Abstract: Castleman's Disease (CD) is a rare lymphoproliferative disorder accompanied by marked systemic inflammatory response. Morphological diagnosis of CD requires biopsy of the whole of the involved lymph node tissue. Three histologic variants have already been described in CD morphology (hyaline vascular, plasma-cell, and mixed). In this study, we report a case of a multicentric Castleman's disease of the plasma cell variant type with negative Herpes Virus 8. The clinical presentation of this patient was of systemic amyloidosis as a result of both a delayed diagnosis and medical management. Previously described cases of CD with secondary amyloidosis have been of the localized type. Regardless, long-standing clinical remission of CD by cytotoxic drugs and anti-CD20 antibody therapy was achieved, but the nephrotic syndrome remained irreversible.

Introduction

The first case of Castleman's disease was described by Dr Benjamin Castleman in 1954 and it is a rare and poorly understood lymphoproliferative disorder [1,2]. Castleman's disease may occur at any age with no sex predominance. Clinical manifestations range from asymptomatic discrete lymphadenopathy to recurrent episodes of diffuse lymphadenopathy associated with severe systemic symptoms in some patients [2, 3]. Infectious diseases: TB, HIV, cat scratch disease and tumours like neurofibromatosis lipoma, thymoma, non-Hodgkin lymphoma are all differential diagnoses of CD.

Our case study is that of a male patient who presented to our hospital with complicated longstanding systemic inflammation in which the underlying cause "Castleman's disease" was diagnosed after many years of illness.

Case presentation:

In 1998, a 48-year-old male of Mediterranean origin presented to the infectious disease clinic with a three week history of mild fever (38.1°C), weight loss (5-6 kg), elevated CRP, but other laboratory tests were within normal limits (table 1). Immunological tests for ANA, anti-DNA, ANCA, anti-MPO, anti-smooth muscle and anti-mitochondrial antibodies were all negative. Two weeks later he presented again with fever (41.9) °C and was re-admitted for further evaluation.

On admission he was anaemic (Hgb 69 g/l) and complained of left sided weakness. Head and spine CT and MRI results were normal, however lumbar puncture showed a slight increase of leukocytes with normal protein. The polymerase chain reaction (PCR) and culture of bone marrow, liquor and urine for tuberculosis were all negative. Previously the patient had completed a course of antibiotics (cefuroxime, doxycycline and imipenem) for ex juvantibus treatment without improvement.

Abdomen CT revealed an enlarged spleen and lymph nodes near the kidney hilus, whereas the chest CT showed only a diffuse parenchymal process in lung bases with no visible masses.

During the next two years, the patient experienced a persistent inflammatory reaction on serum protein electrophoresis and persistent high serum alkaline

phosphatase (ALP) and glutamyltransferase (GT), table 1. Follow up CT and MRI showed slightly enlarged lymph nodes (1 cm in size) of para-aortic and liver hilus where fine needle biopsies showed no evidence of malignancy. Chromogranin A, carcinoembryonic antigen, and alpha-feto protein tests were all normal.

Table 1 Laboratory findings during follow up evaluation, up to 2 months post renal transplantation, 2007

| | Normal values | 1 month (Sept 1998) | 2 months. | 4 months | 3 years (2001) | 7 years (2005) | 8 years (Feb 2006) | 9 years (Aug 2007) |
|-----------------------|--|---------------------|-----------|----------|----------------|----------------|--------------------|--------------------|
| Hgb | (11.5-18.6g/dL) | 11.9 | 10.3 | 11.3 | 13.1 | 11.7 | 12.6 | 12.6 |
| Leucocytes | (4-10x10 ⁹ /L) | 8.7 | 8.2 | 6.1 | | 7.3 | 7 | |
| CRP | (<5mg/L) | 312 | 34 | 64 | 40 | 124 | 5.1 | 2.1 |
| ESR | (2-32mm/h) | 90 | | | | 81 | | |
| Bilirubin | (<20µmol/L) | 42 | 11 | 3 | 4 | 3 | | 8 |
| ALP | (0.8-4.6µkat/L 1998-2003) (0.6-1.8µkat/L 2003-) | 15 | 5.3 | 3.1 | 5.8 | 3.1 | 2.1 | 0.85 |
| GT | (<0.65µkat/L) | | | | 3.9 | | 3.4 | 1.6 |
| AST | (<0.7µkat/L) | 0.86 | 0.28 | 0.25 | 0.5 | 0.25 | 0.25 | 0.32 |
| ALT | (<0.7µkat/L) | 1.9 | 0.55 | 0.17 | 0.57 | 0.17 | 0.21 | 0.38 |
| S. Creatinine | (45-116µmol/L) | 86 | 76 | 79 | 74 | 90 | 588 | 101 |
| S. Albumin | (36-51g/L) | | 34 | 32 | 37 | 25 | 12 | 35 |
| Albuminuria (mg/mmol) | <3.8 | Negative albustix | | | | 303 | 7447 | |

During follow up, he maintained normal blood hemoglobin concentration (Hgb), negative urine dipstick protein analyses and his diabetes was controlled with regular follow up in the outpatient clinic. In March 2005, the patient presented to the infectious disease clinic with three weeks' history of dry cough, generalized malaise, fatigue, and vertigo. On admission he experienced sudden right lower extremity weakness diagnosed as quadriceps muscle mononeuritis which gradually decreased, and disappeared after two weeks. Chest X-ray was normal. Serum albumin was low (25g/L) but urine dipstick was 3+

positive for albumin (Table1). Urine albumin excretion quantification (albumin creatinine ratio, ACI) was 239 mg/mmol. Renal biopsy showed nodular mesangial matrix deposition stain positive for Congo red (Fig. 1). Immunofluorescence stain for serum amyloid AA was positive, indicating amyloidosis secondary to longstanding inflammation. DNA-analysis for familial Mediterranean fever showed no mutation consistent with that disease. The angiotensin converting enzyme (ACE) level was normal which excluded sarcoidosis. HIV ELISA was negative. PPD-test resulted in a reaction of 14 mm, which was compared to a negative test five years earlier. The patient had received BCG vaccination in childhood. TB-culture of the urine and gastric lavage were also negative. A quantiferon test for detecting *Mycobacterium tuberculosis* was negative as well.

Abdominal CT showed para-aortic lymphadenopathy with a clear inflammatory process near the left kidney (para- and peri-renal inflammation). Chest CT showed four small diffuse changes in the upper and lower lobes of the right lung (4.5, 6, 3.5, and 25 mm respectively) whereas open pleural and lung biopsies proved non-conclusive. Enlarged para-aortal lymph node fine needle aspirate showed reactive plasmacytosis without evidence of T or B cell malignancy. During medical evaluation, Castleman's disease was considered, and diagnostic laparotomy for lymph node biopsy was performed in the retroperitoneal space which showed a morphological picture consistent with Castleman's disease, plasma cell variant type (Fig. 2 A and B). The follicles were mostly small and atrophic and the interfollicular area contained large numbers of plasma cells with a polyclonal pattern. There were no signs of increased vascularisation or hyalinization nor could HHV-8 positive cells be detected.

Final diagnosis

Multicentric Castleman's disease of plasma cell variant with secondary renal amyloidosis.

Subsequent management course

To decrease the proteinuria, treatment with ACE inhibitors was initiated. Anticoagulation prophylaxis therapy with warfarin was used. When initial treatment for Castleman's disease with high dose prednisolone (100 mg/day) was unsuccessful, treatment with the R-CHOP 21 chemotherapy regime, (Rituximab, Vincristine, Doxorubicin, Cyclophosphamide and Prednisolone every 21 days) was initiated. After the second course of chemotherapy, the patient's condition was complicated by pneumonia and multiorgan system failure including acute renal failure requiring haemodialysis. *Pneumocystis carinii* was diagnosed and successfully treated, with complete remission.

Repeated earlier testing showed normal serum amyloid AA (5.4 mg/l) and abdominal ultrasound confirmed complete remission of the lymphadenopathy. Accordingly, remission of Castleman's disease was concluded and no further chemotherapy was necessary. Subsequently, renal function improved and serum creatinine decreased to 150 µmol/l. However, the patient remained severely nephrotic (serum albumin 10-15 g/l and albuminuria of

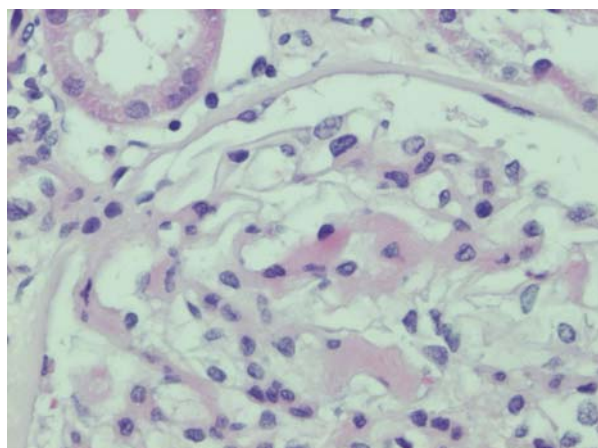


Figure 1. Kidney biopsy show amyloid deposit in the glomeruli. Congo red.

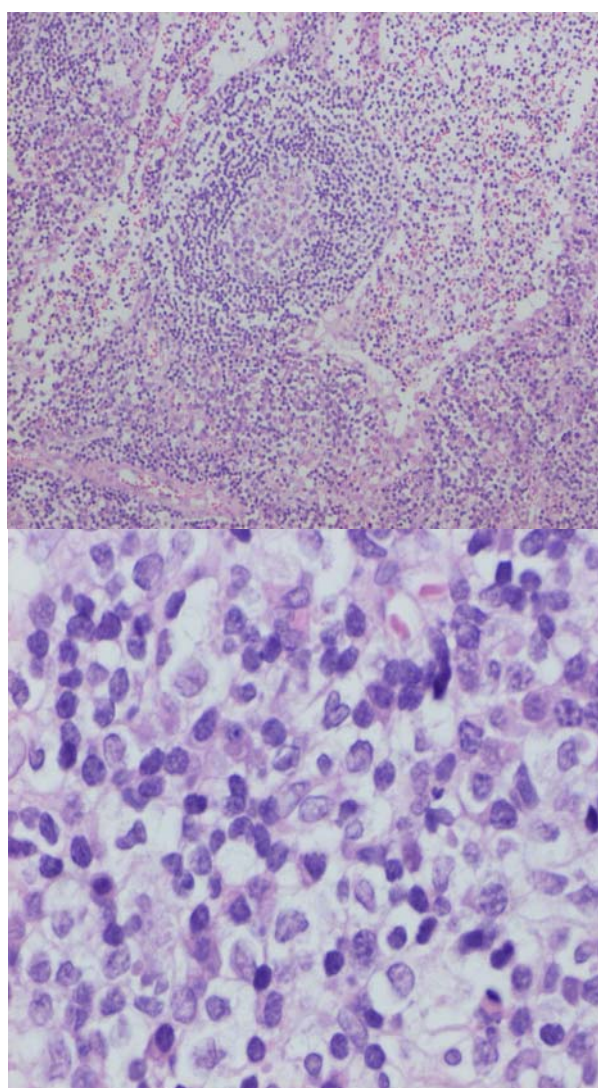


Figure2. Excisional Lymph node biopsy show small lymphoid follicles with regressive changes in germinal centre (A). The interfollicular areas contain large number of plasma cells (B).

6 - 7000 mg/mmol creatinine). In addition, due to long standing muscular atrophy combined with severe orthostatic blood pressures, the patient was unable to walk or even stand up independently. ACE inhibitor therapy was unsuccessful in treating the patient's

proteinuria, so treatment with NSAIDs was added. During the following three months, renal function deteriorated slowly and chronic haemodialysis treatment was initiated. The patient's general condition improved, serum albumin and systolic blood pressure normalized. One year later the patient received a renal transplant from a living donor.

Discussion

The combination of persistent inflammation and radiologic findings of lymph node enlargement raised the possibility of lymphoproliferative disease as early as 1998. Fine needle aspiration biopsies of enlarged lymph nodes excluded TB and lymphoma diagnoses, but did not exclude CD. Not until seven years later after open lymph node biopsy was the final diagnosis of CD established. Unfortunately, the long standing inflammation had given rise to irreversible organ damage which eventually required renal replacement therapy.

CD is a rare pathological entity among atypical lymphoproliferative disorders. Mediastinal and cervical lymph nodes are more commonly involved than retroperitoneal and pelvic lymph groups [4]. Diagnosis requires a histopathological examination of involved lymph node structures. The histological diagnosis is divided into 3 basic types: hyaline vascular (HV), plasma cell (PC) and mixed variant (MV) [5]. Even though 80-90% of CD cases are of the hyaline vascular type, many cases of amyloidosis have been of the plasma cell variant. Contrasting to this case, however, most of those have been localized [6]. Recently human herpes virus 8 infection (HHV-8) has been implicated in the aetiology of several cases [7]. The large amount of IL-6 produced by involved lymph nodes in CD contributes to the sustained overproduction of acute phase protein CRP and serum amyloid A protein (SAA) [8]. Serum AA is the precursor of the amyloid AA protein in reactive amyloidosis [9]. Systemic amyloidosis sometimes complicates an occult CD where the underlying disease is diagnosed after many years of illness [6, 10-12].

While surgical removal of the involved lymph nodes is curative in unicentric variant CD, there is no consensus on how to treat multicentric variant CD [4, 13]. Such cases do not benefit from surgery and systemic treatment may be required to abolish the inflammation even though spontaneous remissions have been reported. Steroid treatment is usually associated with partial response and combination chemotherapy therapy like CHOP with additional Anti-CD20 (Rituximab) have also induced remission in some cases [2, 13-15]. In this case, two courses of R-CHOP were enough to establish a long-lasting remission, but the nephrotic syndrome did not regress. Most likely, the kidney disease was in an advanced stage at the time of initiation of chemotherapy treatment for CD.

In order to decrease the proteinuria and improve the nutritional status in patients with intractable nephrotic syndrome, bilateral nephrectomy and subsequent dialysis have been successful [16]. More recently, a combination of Angiotensin-converting enzyme inhibitors and prostaglandin synthetase inhibitors have been reported to be a successful alternative to surgery, sometimes referred

to as "chemical nephrectomy". ACE inhibitors preferentially dilate the efferent arterioles and NSAIDs selectively induce vasoconstriction of the afferent arterioles [17]. Our patient was at first reluctant to try this approach. When it was finally used, there was a delayed effect.

Summary

In summary the diagnosis of Castleman's disease could easily be missed and should be considered on the differential diagnosis list for patients with unexplained chronic inflammation. Open lymph node biopsy is an important option to establish the diagnosis of CD.

References

1. Castleman B, Iverson L, Menendez VP: Localized mediastinal lymphnode hyperplasia resembling thymoma. *Cancer* 1956; 9:822-830.
2. Casper C: The aetiology and management of Castleman disease at 50 years: translating pathophysiology to patient care. *Br J Haematol* 2005; 129:3-17.
3. Herrada J, Cabanillas F, Rice L, et al.: The clinical behavior of localized and multicentric Castleman disease. *Ann Intern Med* 1998; 128:657-662.
4. Waterston A, Bower M: Fifty years of multicentric Castleman's disease. *Acta Oncol* 2004; 43:698-704.
5. Keller AR, Hochholzer L, Castleman B: Hyaline-vascular and plasma-cell types of giant lymph node hyperplasia of the mediastinum and other locations. *Cancer* 1972; 29:670-683.
6. Altiparmak MR, Pamuk GE, Pamuk ON, et al.: Secondary amyloidosis in Castleman's disease: review of the literature and report of a case. *Ann Hematol* 2002; 81:336-339.
7. Malnati MS, Dagna L, Ponzoni M, et al.: Human herpes virus 8 (HHV-8/KSHV) and hematologic malignancies. *Rev Clin Exp Hematol* 2003; 7:375-405.
8. Ikeda S, Chisuwa H, Kawasaki S, et al.: Systemic reactive amyloidosis associated with Castleman's disease: serial changes of the concentrations of acute phase serum amyloid A and interleukin 6 in serum. *J Clin Pathol* 1997; 50:965-967.
9. Gillmore JD, Lovat LB, Persey MR, et al.: Amyloid load and clinical outcome in AA amyloidosis in relation to circulating concentration of serum amyloid A protein. *Lancet* 2001; 358:24-29.
10. Kazes I, Deray G, Jacobs C: Castleman disease and renal amyloidosis. *Ann Intern Med* 1995; 122:395-396.
11. Tanaka K, Horita M, Shibayama H, et al.: Secondary amyloidosis associated with Castleman's disease. *Intern Med* 1995; 34:122-126.
12. Lachmann HJ, Gilbertson JA, Gillmore JD, et al.: Unicentric Castleman's disease complicated by systemic AA amyloidosis: a curable disease. *Qjm* 2002; 95:211-218.
13. Dispenzieri A, Gertz MA: Treatment of Castleman's disease. *Curr Treat Options Oncol* 2005; 6:255-266.
14. Gholam D, Vantelon JM, Al-Jijakli A, et al.: A case of multicentric Castleman's disease associated with advanced systemic amyloidosis treated with chemotherapy and anti-CD20 monoclonal antibody. *Ann Hematol* 2003; 82:766-768.
15. Ocio EM, Sanchez-Guijo FM, Diez-Campelo M, et al.: Efficacy of rituximab in an aggressive form of multicentric Castleman disease associated with immune phenomena. *Am J Hematol* 2005; 78:302-305.
16. Olivero JJ, Frommer JP, Gonzalez JM: Medical nephrectomy: the last resort for intractable complications of the nephrotic syndrome. *Am J Kidney Dis* 1993; 21:260-263.
17. Heeg JE, de Jong PE, Vriesendorp R, et al.: Additive antiproteinuric effect of the NSAID indomethacin and the ACE inhibitor lisinopril. *Am J Nephrol* 10 Suppl 1990; 1:94-97.