

Prelaminated flaps in head and neck cancer reconstructive surgery: A systematic review

Matteo Fermi MD^{1,2,3}  | Edoardo Bassano MD¹  | Giulia Molinari MD^{1,2,3} |
 Matteo Alicandri-Ciufelli MD¹ | Alfonso Scarpa MD⁴ | Livio Presutti MD^{1,2,3} |
 Giorgio De Santis MD⁵ | Francesco Mattioli MD¹

¹Otorhinolaryngology-Head and Neck Surgery Department, University Hospital of Modena, Modena, Italy

²Department of Otolaryngology-Head and Neck Surgery, IRCCS Azienda Ospedaliero-Universitaria di Bologna, Bologna, Italy

³Department of Specialist, Diagnostic and Experimental Medicine, Alma Mater Studiorum University, Bologna, Italy

⁴Department of Medicine and Surgery, University of Salerno, Salerno, Italy

⁵Division of Plastic Surgery, Department of Medical and Surgical Sciences for Children and Adults, University of Modena and Reggio Emilia, Modena, Italy

Correspondence

Edoardo Bassano, Otorhinolaryngology-Head and Neck Surgery Department, University Hospital of Modena, Largo del Pozzo, 71, 41125 Modena, Italy.
 Email: edoardo.bassano91@gmail.com

Abstract

Background: Prelamination is a reconstructive technique providing fasciomucosal or composite flaps with low donor-site morbidity. We conducted a systematic review of retrospective studies to assess the application of prelaminated flaps in reconstructive surgery of head and neck cancer patients, and to evaluate the advantages and disadvantages of this technique.

Methods: This systematic review adhered to the recommendations of the PRISMA (Preferred Reporting Items of Systematic Reviews and Meta-analysis) 2009 guidelines. A computerized MEDLINE search was performed using the PubMed service of the U.S. National Library of Medicine (www.pubmed.org) and Scopus database (www.scopus.com), running the following search string: “prelamination OR prelaminated AND flap.” Two authors screened the articles, then selected and extracted data on malignancies characteristics, reconstructive techniques, outcomes and complications.

Results: A total of 19 articles were selected and reviewed from 128 identified. Seven of 19 articles were case reports, 12 articles were case series. One-hundred-two patients underwent reconstructive treatment by prelamination technique using a wide variety of flaps (92 free, 10 pedicled). The sites of reconstruction were oral cavity (66 floor of the mouth, 3 retromolar trigone, 6 hard palate, 4 cheek, 4 tongue), 8 facial skin (5 of them sited on the nose), 4 oropharyngeal defects, 1 laryngotracheal region. No case of total flap loss was reported. Partial flap loss or shrinkage requiring minor surgical revisions was observed in 18 patients (17.6%). Primary closure of the donor site was achieved in 97 cases (97%) and 3 (3%) required revision surgery of the donor site.

Conclusion: Prelamination is an effective and versatile technique, with low donor-site morbidity. Further studies would be needed to investigate the impact on the patient's oncologic outcome. More comparative studies with standard reconstructive techniques are essential to understand when it is worth performing this sophisticated procedure.

1 | INTRODUCTION

Head and neck cancers are uncommon (4% of all malignant cancers in Europe), but still represent one of the biggest challenges for a surgeon (Gatta et al., 2015). The primary aim of oncologic surgery is to completely remove the neoplasm complying with radicality criteria. However, functional outcomes should be taken into consideration as well, especially when dealing with the head and neck area.

Up to date the most popular technique for head and neck reconstruction is the vascularized free flap tissue transfer. Among the advantages are the possibility to utilize vascularized tissue from remote parts of the body that are outside the malignancy or irradiation field, a stable wound coverage, and improved aesthetic and functional outcomes (Gabrysz-Forget et al., 2019). On the other hand, traditional free flaps could present some drawbacks, such as bulkiness, color and texture unmatching, and donor site morbidity (Millesi et al., 1998; Poeschl et al., 2003; Soutar & McGregor, 1986).

To overcome these disadvantages, some authors developed a new surgical technique: the prelaminated flap. Pribaz and Fine (1994) introduced the term “prelamination” in 1994 referring to the implantation of tissue or devices into or onto a flap prior to its transfer to the recipient site. This is typically a two-stage procedure, with a gap of at least 2 or 3 weeks between the prelamination phase and the prelaminated flap transfer, which is needed by the implanted tissue to grow and merge on the flap's surface.

Over the last 30 years, a limited number of cases have been reconstructed by this particular technique after head and neck cancer surgical removal.

The aim of the present work is to conduct a systematic review of the literature on the application of prelaminated flaps in reconstructive surgery of head and neck cancer patients, and to evaluate the advantages and disadvantages of this technique.

2 | METHODS

2.1 | Eligibility criteria

This systematic review adhered to the recommendations of the PRISMA (Preferred Reporting Items of Systematic Reviews and Meta-analysis) 2009 guidelines, to guarantee a scientific strategy of research to limit bias by a systematic assembly, critical appraisal and synthesis of all the relevant studies published on the chosen topic (Moher et al., 2009). With the research question being focused on the application of prelaminated flaps in head and neck oncologic reconstructive surgery, data from studies on patients that underwent reconstruction with prelaminated flaps after head and neck cancer resection were pooled for review process.

2.2 | Information sources and search

In March 2021, a computerized MEDLINE search was performed using the PubMed service of the U.S. National Library of Medicine

(www.pubmed.org) and Scopus database (www.scopus.com), running the following search string: “prelamination OR prelaminated AND flap.” The initial search returned a total of 128 results. After electronically removing duplicates, titles and abstracts obtained were screened independently by two of the authors (M.F. and E.B.), who subsequently met and discussed disagreement on citation inclusion. The inclusion criteria for citations were set a priori to encompass as many articles as possible without compromising the validity of the results. Articles mentioning patients surgically treated for head and neck cancer, who underwent reconstruction by a prelaminated flap, after resection of a malignant tumor (either in a primary setting or in salvage surgery) were included.

Exclusion criteria were articles written in languages other than English and with research subject clearly unrelated to head and neck oncology and/or prelamination.

Afterwards, the selected full-texts articles underwent a second screening by the same two authors. Full-texts articles were considered regardless of their study design, in order not to miss any relevant data, and were included if: (1) Reporting cases of reconstruction of head and neck defects by pedicled or free flap prelaminated with autologous tissues, according to the definition of Pribaz and Fine (1994); (2) stating the defect localization; (3) defining the type of flaps for defect reconstruction (i.e., antero-lateral thigh free flap [ALT], fibula free flap [FFF], radial forearm free flap [RFFF], etc.) and their prelamination tissue (i.e., skin, mucosa, cartilage, bone, etc.); (4) reporting the time interval between prelamination and the flap transfer; (5) listing postoperative early and late complications, and (6) specifying the need of revision surgery. Full-texts reporting data from the same study population were excluded.

After manual search on the references from the pooled full-texts, the final number of articles included in the present review was identified (Figure 1), and the main information was extracted and summarized in a database.

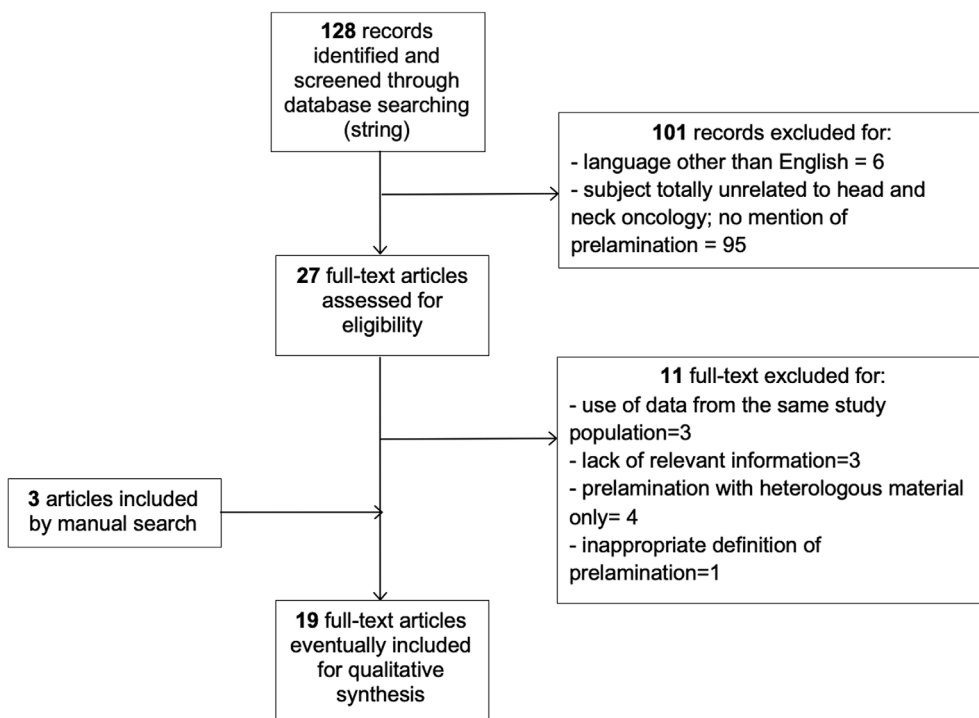
2.3 | Statistical analysis

Statistical analysis was performed using SPSS software 16.0 version (SPSS Inc./IBM).

The results were expressed as mean (standard deviation, SD) for continuous variables with normal distribution, median (interquartile range, IQR) for continuous variables with nonnormal distribution and as percentages for categorical variables. The Kolmogorov–Smirnov test was used to assess the normality of distribution.

Paired and unpaired *t* Student's test were used for continuous variable with normal distribution, while in case of nonnormal distribution Wilcoxon and *U* Mann–Whitney test were employed. Categorical variables' comparisons were assessed with Chi-squared test. To reduce the error in approximation, Yates's correction for continuity was applied.

When more than 20% of expected counts less than 5, Fisher's exact test was used instead. A *p* value of 0.05 was considered statistically significant.

FIGURE 1 Flow diagram of the review

Due to the nature of this study, it was granted an exemption by the Institutional Review Board of the University Hospital of Modena, Italy (Comitato Etico dell'Area Vasta Emilia Nord). There was no funding source for this study.

3 | RESULTS

A total of 19 studies was included in this systematic review, as showed by the PRISMA flow diagram (Figure 1) (Alves et al., 2020; Chiarini et al., 2002; Collar & Byrne, 2013; Colletti et al., 2012; Jehn et al., 2019; Kilinc & Aytakin, 2014; Kim et al., 2013; Lauer et al., 2001; Maruccia et al., 2020; Nehrer-Tairych et al., 2002; Poeschl et al., 2003; Rath et al., 1999; Sadigh & Jeng, 2015; Schlenz et al., 2001; Teng et al., 2005; Upton et al., 1994; Wolff et al., 1996; Ziegler & Oyer, 2021). Seven out of the selected 19 articles were case reports (Alves et al., 2020; Collar & Byrne, 2013; De Santis et al., 2020; Maruccia et al., 2020; Sadigh & Jeng, 2015; Teng et al., 2005; Ziegler & Oyer, 2021), while the remaining 12 articles were case series (with five out of them including less than five cases) (Chiarini et al., 2002; Colletti et al., 2012; Jehn et al., 2019; Kilinc & Aytakin, 2014; Kim et al., 2013; Lauer et al., 2001; Nehrer-Tairych et al., 2002; Poeschl et al., 2003; Rath et al., 1999; Schlenz et al., 2001; Upton et al., 1994; Wolff et al., 1996). The whole study population was represented by 102 patients (63 males, 30 females, 9 not specified) undergoing reconstruction of an anatomical defect secondary to oncological ablative surgery with a prelaminated flap, over the last 27 years (1994–2021). The mean reported age of patients was 56.5 ± 10.7 years.

The tumor's histologic diagnosis was squamous cell carcinoma (SCC) in 15 out of 19 studies (86 patients; 96.7%), while one article dealt with adenoid cystic carcinoma (ACC) and two with basal cell carcinoma (BCC). Data regarding histopathological diagnosis was lacking in one article (Kim et al., 2013).

Based on the treatments performed before reconstructive surgery with prelaminated flap (data reported in 15 studies and available for a total of 94 patients (92.1%), patients were divided into three groups, as follows: group A, including 53 patients (56.3%) who underwent previous chemoradiation (CTRT) therapy; group B, consisting of 6 patients (6.3%) who had undergone previous surgery with or without adjuvant radiotherapy for head and neck malignant tumor; the surgery with prelamination was performed for cancer recurrence or previous flap failure, and thus were considered as a “salvage surgery group”; group C, including 35 patients (37.2%) who did not undergo any medical oncologic treatment before prelaminated flap reconstruction (primary treatment).

Most of the reconstructions were performed for oral cavity malignancies (floor of the mouth, 64.7%; retromolar trigone, 2.9%; hard palate, 5.8%; cheek, 3.9%; tongue; 3.9%). Facial skin malignancies accounted for 8 cases (7.8%), of which the nose was the most involved subsite (5 cases). Four oropharyngeal defects involving the lateral pharyngeal wall and a case of laryngotracheal reconstruction were also reported. For the vast majority of the pooled articles, data regarding the exact size of the defect to be reconstructed were not available. There was a wide variety of flaps, 10 (9.8%) being harvested as pedicled flaps, while 92 (90.1%) as free flaps. The most commonly chosen flap was the RFFF (81 cases; 79.4%), followed by the temporoparietal pedicled flap (5 cases; 4.9%), the scapular flap (4 cases; 3.9%), the latissimus dorsi free flap (4 cases; 3.9%), the FFF

FIGURE 2 Histogram showing postoperative complication rate within patients who underwent neoadjuvant chemoradiation (group A) and patients who did not undergo any previous treatment (group C)

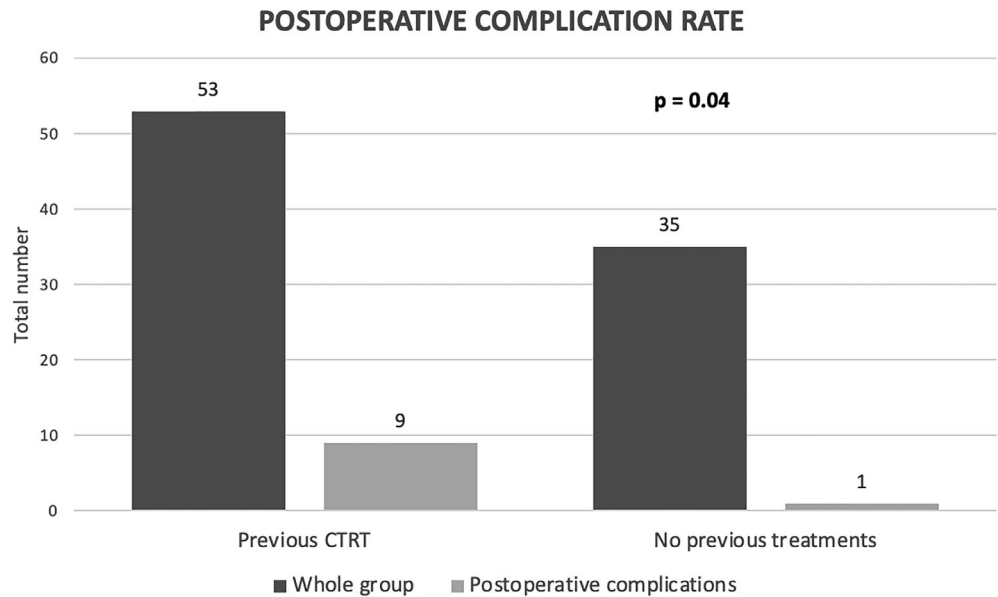


TABLE 1 Details on prelaminated flaps included in the review

Reconstruction site		
	Oral cavity	FOM
		Retromolar trigone
		Hard palate
		Cheek
		Tongue
	Facial skin	
	Oropharynx	
	Laryngotracheal tract	
Type of prelaminated flap		N
Free	RFFF	81
	Fibula FF	2
	Scapular FF	4
	Latissimus dorsi FF	4
	ALT	1
Pedicled	Temporoparietal PF	5
	Supraclavicular PF	2
	Calvarial Osteofacial PF	2
	Paramedian forehead PF	1
Prelamination tissue		
	Buccal mucosa	75
	Full or split-thickness skin graft	19
	Subcutaneous tissue	4
	Costal cartilage	4
	Fibular bone	1

Abbreviations: ALT, antero-lateral thigh flap; FF, free flap; FOM, floor of the mouth; N, number; PF, pedicled flap; RFFF, radial forearm free flap; TFC, temporalis fasciocutaneous.

(2 cases; 1.9%), the supraclavicular pedicled flap (2 cases; 1.9%) and the calvarial osteofacial pedicled flap (2 cases; 1.9%). ALT flap was employed only in one case. Details on prelaminated flaps included in the review are summarized in Table 1.

Different kinds of tissues were employed for the flap prelamination procedure. Seventy-five cases were prelaminated with buccal mucosa harvested from the cheek contralateral to the tumor's location. In all these patients the tumor and the subsequent defect

TABLE 2 Summary of included studies

Authors (year of publication)	N of included patients	Tumor histology	Treatments preceding prelamination	Reconstruction site	Type of prelaminated flap	Prelamination tissue	Timing of reconstruction with prelaminated flap (from primary oncologic resection)	Time between prelamination and reconstruction with prelaminated flap (weeks)	Donor site management	Prelaminated flap success rate	Complications	N revision surgery on flap	N reintervention on donor site
Upton et al. (1994)	4	SCC	1 CTRT	3 nose; 1 upper lip	4 temporo-parietal PF	4 skin	NA	3-4	4 PC	100%	0	NA	NA
Wolff et al. (1996)	5	SCC	5 CTRT	5 FOM	5 RFFF	5 STSG	Simultaneous	2	5 PC	100%	0	0	0
Rath et al. (1999)	10	SCC	10 CTRT	8 FOM; 2 retromolar triangle	8 RFFF; 2 fibula FF	10 buccal mucosa	Simultaneous	8-10	9 PC; 1 STSG	90%	1 shrinkage	0	1
Schlenz et al. (2001)	4	SCC	NA	4 Hard Palate	4 Scapular FF	4 dermis	NA	8-12	4 PC	100%	0	0	0
Lauer et al. (2001)	5	SCC	None	4 FOM; 1 cheek	5 RFFF	5 buccal mucosa	Simultaneous	1	4 PC	100%	0	0	0
Chiarini et al. (2002)	10	SCC	None	7 FOM; 1 FOM + tongue; 1 AGP region + FOM; 1 AGP region	10 RFFF	10 buccal mucosa	Simultaneous	3	10 PC	100%	1 fistula	0	0
Nehrer-Tairych et al. (2002)	20	SCC	20 CTRT	20 FOM	20 RFFF	20 buccal mucosa	Simultaneous	8-10	20 PC	100%	0	0	0
Poeschl et al. (2003)	16	SCC	16 CTRT	13 FOM; 2 tongue; 1 retromolar region	16 RFFF	16 buccal mucosa	Simultaneous	9-11	16 PC	56.2%	1 wound infection, 7 flap dehiscences	14 for shrinkage	1 (for wound infection)
Teng et al. (2005)	1	SCC	1 CTRT	1 tracheal defect	1 RFFF	1 costal cartilage	Delayed	4	NA	100%	0	NA	NA
Colletti et al. (2012)	2	SCC	2 surgeries (flap failure)	2 cheek	1 TFC PF; 1 supraclavicular PF	2 skin	Delayed	1.5 (TFC PF) 2 (supraclavicular)	1 STSG; 1 PC	100%	0	0	0
Kim et al. (2013)	13	NA	None	10 FOM; 1 tonsil; 2 soft palate	13 RFFF	1 buccal mucosa	Simultaneous	3	13 PC	84.6%	1 dehiscence, 1 fistula	2	0
Collar and Byrne (2013)	1	BCC	1 surgery + adjuvant RT	1 auriculo-temporal bone	1 RFFF	1 costal cartilage	Delayed	NA	1 PC	100%	0	0	0
Kilinc and Aytekin (2014)	2	ACC	NA	2 palate	2 Calvarial osteofascial PF	2 skin	Simultaneous	3-4	2 PC	100%	0	0	0
Sadigh and Jeng (2015)	1	SCC	1 surgery + adjuvant RT (flap failure)	1 cheek-mandible	1 ALT	1 fibula bone	Delayed	3	1 PC	100%	0	0	0
Maruccia et al. (2020)	1	SCC	1 surgery (flap failure)	1 nose-upper lip	1 RFFF	1 costal cartilage	Delayed	8	1 STSG	100%	0	1	1 (STSG)
Jehn et al. (2019)	4	SCC	1 surgery	3 superior mandibular region; 1 FOM	4 latissimus dorsi FF	4 skin	Simultaneous	2	4 PC	100%	0	0	0

TABLE 2 (Continued)

Authors (year of publication)	N of included patients	Tumor histology	Treatments preceding prelamination	Reconstruction site	Type of prelaminated flap	Prelamination tissue	Timing of reconstruction with prelaminated flap (from primary oncologic resection)	Time between prelamination and reconstruction with prelaminated flap (weeks)	Donor site management	Prelaminated flap success rate	Complications	N revision surgery on flap	N reintervention on donor site
Alves et al., 2020	1	SCC	NA	1 Ear	1 Supraclavicular PF	1 cartilage	NA	25.7	NA	100%	0	1 (surgical debridement)	NA
Ziegler & Oyer, 2021	1	BCC	NA	1 Nose	1 Paramedian forehead PF	1 STSG and cartilage	NA	8	NA	100%	0	0	NA
De Santis et al. (2020)	1	SCC	None	1 Tongue	1 RFFF	1 buccal mucosa	Simultaneous	3	1 PC	100%	0	0	0

Abbreviations: ACC, adenoid cystic carcinoma; AGP, amigdaloglossal-palatine region; ALT, antero-lateral thigh flap; CTRT, chemo-radiation; FF, free flap; FOM, floor of the mouth; N, number; NA, data not available; PC, primary closure; PF, pedicled flap; RFFF, radial forearm free flap; RT, radiotherapy; SCC, squamous cell carcinoma; STSG, split-thickness skin graft; TFC, temporalis fasciocutaneous.

were located in oral cavity, with the exception of 4 oropharyngeal SCCs (Chiarini et al., 2002; Kim et al., 2013). Seventeen cases (16.7%) were prelaminated with full or split thickness skin grafts. Subcutaneous tissue and costal cartilage were employed in 4 (3.9%) and 3 (2.9%) cases, respectively. In one case both split-thickness skin graft and costal cartilage was employed (Ziegler & Oyer, 2021). Lastly, fibular bone was used to prelamine an ALT flap in order to obtain an osteo-cutaneous flap for a case of revision surgery after a previous fibula flap failed due to osteoradionecrosis (Sadigh & Jeng, 2015).

The majority of patients (86/92, 93.5%) underwent simultaneous demolition and reconstruction, while 6 of 92 (6.5%) underwent delayed prelaminated flap reconstruction, after tumor resection. This data was lacking in four articles, counting for 10 patients (Alves et al., 2020; Schlenz et al., 2001; Upton et al., 1994; Ziegler & Oyer, 2021).

The prelamination interval, defined as the time passed between the execution of the prelamination and the inseting of the prelaminated flap, varied among the selected studies, with a median prelamination interval of 3.5 weeks (IQR = 6.5). The difference between the patients who underwent previous chemo/radiation therapy or surgical cancer removal (group A and B, mean prelamination interval 6.7 weeks) and patients who did not undergo previous treatments (group C, mean prelamination interval 2.5 weeks) was not statistically significant ($p = 0.07$).

The main advantages reported for the use of prelaminated flaps regarded the donor site: primary closure was achieved in 97 cases (97%) and only 3 (3%) required revision surgery of the donor site; in two articles no data regarding the donor site management and outcome was available from text reading, however the pictures showed excellent aesthetic results (Alves et al., 2020; Ziegler & Oyer, 2021). Moreover, no case of total flap loss was reported. On the other hand, partial flap loss or shrinkage requiring minor surgical revisions was observed in 18 patients (18.5%), 14 of which (77.8%) had undergone CTRT therapy before surgery. Postoperative complications and flap success rate were included and summarized in Table 2. There was a statistically significant difference in terms of postoperative complication rate between the group C (2.9%) and group A (17%) ($p = 0.04$) (Figure 2). The majority of RFFFs has been transferred with no major complications and only in 8 of 81 (9.9%) patients a partial flap loss occurred, while in 2 of 81 (2.5%) patients a fistula occurred. Most of these complications befell patients who had undergone previous CTRT (group A), where a 15% rate of post-operative complication was reached. On the contrary, only 5.9% of patients from group C (reconstruction with prelaminated flap as a primary cancer treatment) encountered post-operative complications. Only in two patients within group C data regarding adjuvant radiation therapy were reported, with a satisfactory morphological and functional results (Chiarini et al., 2002; De Santis et al., 2020). It was not possible to evaluate data regarding duration of hospitalization and long-term complications, since data regarding surgical outcome achieved a mean follow-up of 17 months (range 0.5–30.4). Data regarding the oncologic follow-up were available only for 17 (16.7%) patients, since only two studies reported this information, achieving mean follow-up of 30.4 months (range 11–54) (De Santis et al., 2020; Poeschl et al., 2003).

4 | DISCUSSION

Before Pribaz and Fine in 1994 defined the term “prelamination”, few authors had already described this procedure, but often referring to it as prefabrication, and thus creating some misunderstanding in the referral to these surgical techniques by which a multilayered flap is created (Costa et al., 1993; Pribaz & Fine, 1994). Prelamination consists of a graft of tissue or a device in or on a flap with its native blood supply, prior to its transfer (Pribaz et al., 1999), while in prefabrication, a flap is prepared introducing a new blood supply by pedicle transfer, and after a period of neovascularization, the flap is transferred with its new blood supply to a distant region (Pribaz & Fine, 1994).

To date prelamination of different flaps has been reported as a suitable method to improve flap design, enhance functional aspects and reduce donor-site morbidity (Jehn et al., 2019). According to the present systemic review, prelamination was mostly employed in oral cavity reconstruction and the RFFF resulted the most commonly flap to be prelaminated to reconstruct the oral cavity, similarly to the literature on not-prelaminated free flap reconstructive options for oral cavity (Urken et al., 1994).

The advantages of this flap are represented by a constant vascular anatomy, a thin, almost hairless skin, pliability, and relatively easiness of harvesting (Timmons et al., 1986). However, considering the oral cavity, the drawbacks of this flap are the mismatch of skin color, the loss of mucosa able to produce saliva, and especially the donor-site morbidity (Millesi et al., 1998; Poeschl et al., 2003; Soutar & McGregor, 1986). To overcome some of the disadvantages of the RFFF, various techniques have been developed, such as the jejunal patch with mucosa able to produce saliva (Chiarini et al., 2002). However, this option is not suitable to reconstruct composite defects and is not feasible in patients who had previous abdominal surgery (Chiarini et al., 2002; Millesi et al., 1998; Poeschl et al., 2003).

In the early 90s', the RFFF was first prelaminated with buccal mucosa to become a fasciomucosal flap and reconstruct oral cavity defects. Histological analysis of a bioptic mucosal specimen after the prelaminated-flap transfer has been conducted in various studies, showing a regular nonkeratinized, stratified epithelium (Chiarini et al., 2002; Rath et al., 1997).

According to the results of this systematic review, the prelaminated RFFF is an effective reconstructive option for defects after oral cavity neoplasms removal. As shown in Table 2, the majority of RFFFs has been transferred with no major complications and only in 8 of 81 (9.9%) patients a partial flap loss occurred, while in 2 of 81 (2.5%) patients a fistula occurred. Most of these complications befell patients who had undergone previous CRTT (group A), where a 15% rate of post-operative complication was reached. On the contrary, only 5.9% of patients from group C (reconstruction with prelaminated flap as a primary cancer treatment) encountered post-operative complications. However, none of these patients required revision surgery and primary healing was achieved with conservative treatments.

Flap's shrinkage is another element that should be considered when performing reconstructive surgery. In this systematic review, a

clinically relevant shrinkage was reported for 15 patients (14.7%). It is interesting to notice that all of them underwent previous CRTT. Almost all of the cases were part of a study by Poeschl et al. (2003) and the majority of the patients needed revision surgery. Comparing two groups of 16 patients treated with prelaminated versus non-prelaminated RFFF for oral cavity cancers, respectively, the authors reported a shrinkage rate of 6% versus 87.5% in the fasciocutaneous versus the fasciomucosal group, respectively. This data is not in agreement with the literature, as reported by the authors themselves (Poeschl et al., 2003), who noticed the highest shrinkage rates in those cases where the transplanted mucosa did not spread very well across the fascia. However, the post-operative flap's volume reduction is a well-known issue, whose risk factors are mainly related to adjuvant treatment, low body-mass index and poor nutritional status (Bittermann et al., 2015; Wang et al., 2020). Thus, even for prelaminated flaps, these aspects should be considered preoperatively and possibly addressed by overcorrection.

Another advantage of RFFF prelamination is the low donor-site morbidity. Aesthetic appearance of the donor-site, functional impairment (i.e., limited wrist mobility), wound infection, heat or cold intolerance are the most frequent complications after RFFF harvesting (Kansy et al., 2019). The prelamination procedure seems to significantly reduce those risks. First, according to the pooled analysis, a high rate (96.9%) of primary closure of the donor-site was reached, also when other donor-sites were considered. Second, Neherer-Tayrich et al. evaluated the motor (strength and range of motion of the joint) and sensitive (cold intolerance, pain) function after fasciomucosal and fasciocutaneous RFFFs (Nehrer-Tairych et al., 2002). The functional outcomes resulted slightly better in the prelamination-group, whereas the cosmetic results were much more desirable. In addition, several authors achieved satisfactory outcomes by prelaminating other flaps with different autologous tissues, such as skin grafts (i.e., nose and lip reconstruction) or cartilage and bone grafts (i.e., auricle and mandible reconstruction) (Collar & Byrne, 2013; Kilinc & Aytekin, 2014; Sadigh & Jeng, 2015; Schlenz et al., 2001; Upton et al., 1994; Wolff et al., 1996).

The reconstruction's planning is another issue worth discussing. The time needed for the prelamination of the flap, the tumoral growth rate and the possibility of neoadjuvant treatment should be considered in order to plan a flap prelamination. Most of the authors preferred to execute the resection and the reconstruction simultaneously, some weeks after the flap prelamination (range 3–11 weeks). The patients who underwent CRTT treatment (group A) showed a longer time of prelamination, even if not reaching statistically significance. This multimodal therapeutic strategy theoretically grants a better preparation of the flap, which can sufficiently grow over time (Rath et al., 1999). Furthermore, it is possible to irradiate the site of the neoplasm, without damaging the flap. The drawbacks could be represented by the necessity to act on an unfavorable surgical field treated with radiation therapy. On the other hand, a long wait in-between the diagnosis and the treatment could worsen the prognosis of patients waiting for definitive surgical treatment. Another aspect to decide on the best planning Chiarini et al. (2002), as well as De

Santis et al. (2020), chose to wait only 3 weeks before the harvest of the prelaminated flap and neither neoadjuvant radiotherapy nor chemotherapy was not used in any of their patients. The authors stated that this amount of time was enough to reach a great increase of the size of the graft, due to the intense mitotic activity of the oral mucosa and the high vascularization of the fascia antibrachialis (Chiarini et al., 2002).

The insertion of alloplastic sheets between the fascia and the raised subcutaneous tissue is crucial to increase the size of the prelaminated flap, since it prevents adhesions between the tissues and enables mucosal spreading (Rath et al., 1997). So far, the most effective material used was silicon, which granted a size double than the original after 3 weeks (Chiarini et al., 2002). Future developments in tissue engineering could facilitate the spread and integration of the prelaminated tissue on the flap, possibly overcoming the issue of timing for this kind of surgery.

The overall survival related to the diagnosis-to-treatment interval is a fundamental aspect to consider, as it may influence the adequacy of the prelaminated flaps in the treatment of oncologic head and neck patients. The delay of treatment was described as an independent prognostic factor affecting the overall survival in those patients (Graboyes et al., 2019). Nevertheless, the threshold that shall not to be passed is still a matter of debate. Murphy et al., (2015) conducted a retrospective study on more than 50,000 patients with head and neck SCC finding that a time of treatment initiation greater than 46–52 days determined an increased risk of death and that was most consistently detrimental beyond 60 days. However, in a recent systematic review, Graboyes et al. (2019) underlined how in literature there are very heterogeneous studies (in terms of study design, samples, histotypes, subsites and other factors), with delay thresholds ranging widely from 20 to 120 days or more. The heterogeneity of these studies makes it very difficult to produce strong recommendations about a pinpoint time not to exceed. According to the data gathered for this systematic review, it was not possible to draw any conclusion about the influence of this reconstructive strategy on the survival and disease-control rates of head and neck cancer patients, especially due to the lack of data regarding the oncologic follow-up in most of the included studies.

Besides the oral cavity, significant conclusions about the advantages and limitations of the reconstruction of other anatomical sites (e.g., tracheal, nasal and auricular defect) by prelaminated flaps cannot be drawn. Overall, the short-term results of prelaminated flaps in these areas have been reported as positive (Alves et al., 2020; Maruccia et al., 2020; Teng et al., 2005; Upton et al., 1994; Ziegler & Oyer, 2021).

Moreover, the lack of quantification of the benefits on speech articulation, swallowing, breathing and overall quality of life of patients reconstructed with prelaminated flaps prevents to establish the impact of prelamination on these aspects in cancer patients. In fact, given the complexity of the procedure and the need to perform at least two surgeries, more comparative studies with standard reconstructive techniques are essential to understand when it is worth performing this sophisticated procedure. In addition, unfortunately only

few data regarding the outcomes of prelaminated flaps undergoing postoperative radiation therapy are available in this systematic review, even if it is more likely that a consistent amount of the evaluated patients underwent such adjuvant treatment due to the disease extent which often goes with free flap reconstructions (Chiarini et al., 2002; De Santis et al., 2020). Finally, every systematic review includes case series and case reports, often showing the best author's experience with a specific technique, while failures and complications are usually not published. This bias affects every systematic review and should be taken in consideration by the readers of this study.

5 | CONCLUSION

Considering the several technical nuances and possible different tissues applicable for prelamination on the head and neck area, prelaminated flaps should be considered a versatile reconstructive option for composite defects or functionally challenging areas of the head and neck region, especially if other flaps have failed or are not available. Prelamination is an effective technique and, especially with RFFF, it reduces the morbidity of the donor site.

Further studies would be needed to investigate whether the prelamination time interval has a significant impact on the patient's oncologic outcomes and which are the functional benefits of prelamination in the head and neck area, as compared to other reconstructive techniques.

CONFLICT OF INTEREST

The authors declare no conflict of interest.

DATA AVAILABILITY STATEMENT

The data that support the findings of this study are available from the corresponding author upon reasonable request.

ORCID

Matteo Fermi  <https://orcid.org/0000-0002-2727-0321>

Edoardo Bassano  <https://orcid.org/0000-0002-1603-8359>

REFERENCES

- Alves, H. R. N., de Rodriguez, J. F. G. U. M., Fernandes, T. R. R., Busnardo, F. F., Besteiro, J. M., Cernea, C. R., & Gemperli, R. (2020). Prelaminated supraclavicular Island flap for total ear reconstruction: A new technique. *Plastic and Reconstructive Surgery. Global Open*, 8(5), e2736. <https://doi.org/10.1097/gox.0000000000002736>
- Bittermann, G., Thönissen, P., Poxleitner, P., Zimmerer, R., Vach, K., & Metzger, M. C. (2015). Microvascular transplants in head and neck reconstruction: 3D evaluation of volume loss. *Journal of Cranio-Maxillofacial Surgery*, 43(8), 1319–1324. <https://doi.org/10.1016/j.jcms.2015.06.013>
- Chiarini, L., De Santis, G., Bedogni, A., & Nocini, P. F. (2002). Lining the mouth floor with prelaminated fascio-mucosal free flaps: Clinical experience. *Microsurgery*, 22(5), 177–186. <https://doi.org/10.1002/micr.22511>
- Collar, R. M., & Byrne, P. J. (2013). Prelaminated free flap for auricular reconstruction. *New England Journal of Medicine*, 369(12), 1151–1151. <https://doi.org/10.1056/NEJMicm1213320>

- Colletti, G., Autelitano, L., Tewfik, K., Rabbiosi, D., & Biglioli, F. (2012). Autonomized flaps in secondary head and neck reconstructions. *Acta Otorhinolaryngologica Italica*, 32(5), 329–335.
- Costa, H., Cunha, C., Guimarães, I., Comba, S., Malta, A., & Lopes, A. (1993). Prefabricated flaps for the head and neck: A preliminary report. *British Journal of Plastic Surgery*, 46(3), 223–227. [https://doi.org/10.1016/0007-1226\(93\)90172-8](https://doi.org/10.1016/0007-1226(93)90172-8)
- De Santis, G., Mattioli, F., Pinelli, M., et al. (2020). Tip of the tongue reconstruction with prelaminated fasciomucosal radial forearm free flap. *Plastic and Reconstructive Surgery—Global Open*, 8(12), e3226. <https://doi.org/10.1097/GOX.0000000000003226>
- Gabrysz-Forget, F., Tabet, P., Rahal, A., Bissada, E., Christopoulos, A., & Ayad, T. (2019). Free versus pedicled flaps for reconstruction of head and neck cancer defects: A systematic review. *Journal of Otolaryngology—Head & Neck Surgery*, 48(1), 13. <https://doi.org/10.1186/s40463-019-0334-y>
- Gatta, G., Botta, L., Sánchez, M. J., Anderson, L. A., Pierannunzio, D., Licitra, L., Hackl, M., Zielonke, N., Oberaigner, W., van Eycken, E., Henau, K., Valerianova, Z., Dimitrova, N., Sekerija, M., Zvolský, M., Dušek, L., Storm, H., Engholm, G., Mägi, M., ... Otter, R. (2015). Prognoses and improvement for head and neck cancers diagnosed in Europe in early 2000s: The EUROCARE-5 population-based study. *European Journal of Cancer*, 51(15), 2130–2143. <https://doi.org/10.1016/j.ejca.2015.07.043>
- Graboyes, E. M., Kompelli, A. R., Neskey, D. M., Brennan, E., Nguyen, S., Sterba, K. R., Warren, G. W., Hughes-Halbert, C., Nussenbaum, B., & Day, T. A. (2019). Association of treatment delays with Survival for patients with head and neck cancer: A systematic review. *JAMA Otolaryngology—Head & Neck Surgery*, 145(2), 166–177. <https://doi.org/10.1001/jamaoto.2018.2716>
- Jehn, P., Zimmerer, R., Dittmann, J., Winterboer, J., Gellrich, N. C., Tavassol, F., & Spalthoff, S. (2019). Prelamination of the latissimus dorsi flap for reconstruction in head and neck surgery. *International Journal of Oral and Maxillofacial Surgery*, 48(9), 1163–1168. <https://doi.org/10.1016/j.ijom.2019.02.004>
- Kansy, K., Hoffmann, J., Alhalabi, O., Mistele, N., Freier, K., Shavlokhova, V., Mertens, C., Freudlsperger, C., & Engel, M. (2019). Long-term donor site morbidity in head and neck cancer patients and its impact on quality of life: A cross-sectional study. *International Journal of Oral and Maxillofacial Surgery*, 48(7), 875–885. <https://doi.org/10.1016/j.ijom.2019.01.009>
- Kilinc, H., & Aytakin, A. H. (2014). Prelaminated calvarial osteofascial flap for palatal reconstruction. *The Journal of Craniofacial Surgery*, 25(4), e365–e368. <https://doi.org/10.1097/SCS.0b013e3182a30627>
- Kim, G. G., Halvorson, E. G., Hang, A. X., Pederson, W. C., De Santis, G., & Hackman, T. G. (2013). Prelamination of radial forearm free flap with buccal mucosa. *Otolaryngology—Head and Neck Surgery*, 148(2), 341–343. <https://doi.org/10.1177/0194599812471632>
- Lauer, G., Schimming, R., Gellrich, N. C., & Schmelzeisen, R. (2001). Prelaminating the fascial radial forearm flap by using tissue-engineered mucosa: Improvement of donor and recipient sites. *Plastic and Reconstructive Surgery*, 108(6), 1564–1572; discussion 1573–1575. <https://doi.org/10.1097/00006534-200111000-00019>
- Maruccia, M., Elia, R., Nacchiero, E., & Giudice, G. (2020). Microsurgical reconstruction of the isolated columellar defect with a pre-laminated radial forearm free flap. A case report and a review of the literature. *Microsurgery*, 40(2), 241–246. <https://doi.org/10.1002/micr.30472>
- Millesi, W., Rath, T., Millesi-Schobel, G., & Glaser, C. (1998). Reconstruction of the floor of the mouth with a fascial radial forearm flap, pre-laminated with autologous mucosa. *International Journal of Oral and Maxillofacial Surgery*, 27(2), 106–110. [https://doi.org/10.1016/s0901-5027\(98\)80305-6](https://doi.org/10.1016/s0901-5027(98)80305-6)
- Moher, D., Liberati, A., Tetzlaff, J., Altman, D. G., & PRISMA Group. (2009). Preferred reporting items for systematic reviews and meta-analyses: The PRISMA statement. *PLoS Medicine*, 6(7), e1000097. <https://doi.org/10.1371/journal.pmed.1000097>
- Murphy, C. T., Galloway, T. J., Handorf, E. A., Egleston, B. L., Wang, L. S., Mehra, R., Flieder, D. B., & Ridge, J. A. (2015). Survival impact of increasing time to treatment initiation for patients with head and neck cancer in the United States. *JCO*, 34(2), 169–178. <https://doi.org/10.1200/JCO.2015.61.5906>
- Nehrer-Tairych, G. V., Millesi, W., Schuhfried, O., & Rath, T. (2002). A comparison of the donor-site morbidity after using the pre-laminated fasciomucosal flap and the fasciocutaneous radial forearm flap for intraoral reconstruction. *British Journal of Plastic Surgery*, 55(3), 198–202. <https://doi.org/10.1054/bjps.2002.3812>
- Poeschl, P. W., Kermer, C., Wagner, A., Klug, C., Ziya-Ghazvini, F., & Poeschl, E. (2003). The radial free forearm flap—Prelaminated versus non-prelaminated: A comparison of two methods. *International Journal of Oral and Maxillofacial Surgery*, 32(2), 159–166. <https://doi.org/10.1054/ijom.2002.0282>
- Pribaz, J. J., & Fine, N. A. (1994). Prelamination: Defining the prefabricated flap—A case report and review. *Microsurgery*, 15(9), 618–623. <https://doi.org/10.1002/micr.1920150903>
- Pribaz, J. J., Weiss, D. D., Mulliken, J. B., & Eriksson, E. (1999). Prelaminated free flap reconstruction of complex central facial defects. *Plastic and Reconstructive Surgery*, 104(2), 357–365; discussion 366–367. <https://doi.org/10.1097/00006534-199908000-00005>
- Rath, T., Millesi, W., Millesi-Schobel, G., Lang, S., Glaser, C., & Todoroff, B. (1997). Mucosal pre-laminated flaps for physiological reconstruction of intraoral defects after tumour resection. *British Journal of Plastic Surgery*, 50(5), 303–307. [https://doi.org/10.1016/s0007-1226\(97\)90537-3](https://doi.org/10.1016/s0007-1226(97)90537-3)
- Rath, T., Tairych, G. V., Frey, M., Lang, S., Millesi, W., & Glaser, C. (1999). Neuromucosal pre-laminated flaps for reconstruction of intraoral lining defects after radical tumor resection. *Plastic and Reconstructive Surgery*, 103(3), 821–828. <https://doi.org/10.1097/00006534-199903000-00007>
- Sadigh, P. L., & Jeng, S.-F. (2015). Prelamination of the anterolateral thigh flap with a fibula graft to successfully reconstruct a mandibular defect. *Plastic and Reconstructive Surgery—Global Open*, 3(8), e497. <https://doi.org/10.1097/GOX.0000000000000472>
- Schlenz, I., Korak, K. J., Kunstfeld, R., Vinzenz, K., Plenck, H., & Holle, J. (2001). The dermis-prelaminated scapula flap for reconstructions of the hard palate and the alveolar ridge: A clinical and histologic evaluation. *Plastic and Reconstructive Surgery*, 108(6), 1519–1524; discussion 1525–1526. <https://doi.org/10.1097/00006534-200111000-00012>
- Soutar, D. S., & McGregor, I. A. (1986). The radial forearm flap in intraoral reconstruction: The experience of 60 consecutive cases. *Plastic and Reconstructive Surgery*, 78(1), 1–8.
- Teng, M. S., Malkin, B. D., & Urken, M. L. (2005). Prefabricated composite free flaps for tracheal reconstruction: A new technique. *Annals of Otolaryngology, Rhinology & Laryngology*, 114(11), 822–826. <https://doi.org/10.1177/000348940511401102>
- Timmons, M. J., Missotten, F. E., Poole, M. D., & Davies, D. M. (1986). Complications of radial forearm flap donor sites. *British Journal of Plastic Surgery*, 39(2), 176–178. [https://doi.org/10.1016/0007-1226\(86\)90078-0](https://doi.org/10.1016/0007-1226(86)90078-0)
- Upton, J., Ferraro, N., Healy, G., Khouri, R., & Merrell, C. (1994). The use of prefabricated fascial flaps for lining of the oral and nasal cavities. *Plastic and Reconstructive Surgery*, 94(5), 573–579. <https://doi.org/10.1097/00006534-199410000-00001>
- Urken, M. L., Weinberg, H., Buchbinder, D., Moscoso, J. F., Lawson, W., Catalano, P. J., & Biller, H. F. (1994). Microvascular free flaps in head and neck reconstruction: Report of 200 cases and review of complications. *Archives of Otolaryngology—Head & Neck Surgery*, 120(6), 633–640. <https://doi.org/10.1001/archotol.1994.01880300047007>
- Wang, S.-J., Zhang, W.-B., Yu, Y., Wang, T., Yang, H.-Y., & Peng, X. (2020). Factors affecting volume change of anterolateral thigh flap in head

and neck defect reconstruction. *Journal of Oral and Maxillofacial Surgery*, 78(11), 2090–2098. <https://doi.org/10.1016/j.joms.2020.06.017>

Wolff, K. D., Ervens, J., & Hoffmeister, B. (1996). Improvement of the radial forearm donor site by prefabrication of fascial-split-thickness skin grafts. *Plastic and Reconstructive Surgery*, 98(2), 358–362. <https://doi.org/10.1097/00006534-199608000-00025>

Ziegler, J. P., & Oyer, S. L. (2021). Prelaminated paramedian forehead flap for subtotal nasal reconstruction using three-dimensional printing. *BML Case Reports*, 14(1), e238146. <https://doi.org/10.1136/bcr-2020-238146>

How to cite this article: Fermi, M., Bassano, E., Molinari, G., Alicandri-Ciufelli, M., Scarpa, A., Presutti, L., De Santis, G., & Mattioli, F. (2021). Prelaminated flaps in head and neck cancer reconstructive surgery: A systematic review. *Microsurgery*, 41(6), 584–593. <https://doi.org/10.1002/micr.30751>