

Available online at www.sciencedirect.com

ScienceDirect

journal homepage: www.elsevier.com/locate/radcr

Case report

Mucinous carcinoma in a male patient: Diagnosis and management of breast cancer in male patients [☆]

Umer Ahmed, MS, BS, Sean Wagner, MD, Sheryl Jordan, MD^{*,**}

University of North Carolina School of Medicine, 321 South Columbia Street, Chapel Hill, NC, USA 27599

ARTICLE INFO

Article history:

Received 20 August 2021

Accepted 6 October 2021

Keywords:

Breast cancer

Mucinous carcinoma

Multidisciplinary care

Tumor board

Male

ABSTRACT

Male breast cancer is a rare but serious condition that impacts an increasing number of men each year. Due to low incidence rate, there is a current lack of established diagnostic and management practices. Here, we provide a review of the current epidemiology, classification, diagnosis, and treatment of male breast cancer. We present a rare case of mucinous breast cancer in a 74-year-old male patient detected after he presented with a retroareolar mass. The patient underwent mammography, targeted ultrasound, and ultrasound-guided core needle biopsy, which established the diagnosis. He was treated surgically with left mastectomy and sentinel lymph node biopsy with axillary lymph node dissection, followed by post-adjuvant tamoxifen and has remained free of recurrence and metastasis since.

© 2021 The Authors. Published by Elsevier Inc. on behalf of University of Washington.

This is an open access article under the CC BY-NC-ND license

(<http://creativecommons.org/licenses/by-nc-nd/4.0/>)

Anatomically, the male breast is composed of an external nipple and areola and internal lymph nodes, fatty tissue, and ducts. The glandular portion of the male breast is mainly located in the retroareolar region. Similar to the female breast, the male breast undergoes changes in hormone exposure throughout life and expresses receptors for estrogen, progesterone, and androgens [1].

Male breast cancer is a rare condition with an estimated 2650 new cases diagnosed in the United States in 2021 [2]. Less than 1% of all breast malignancies occur in men, with a case fatality rate of 20% in 2021 [3]. Because men typically have a

small amount of mammary tissue, male breast cancer most commonly presents as a painless retroareolar anterior depth breast mass. Tumors may infiltrate the overlying skin or underlying fascia or present with nipple discharge. Due to the low incidence rate of this condition and other male breast conditions, the establishment of diagnostic, prognostic, and predictive criteria have been difficult. Studies in the past decade have elucidated the potential mechanisms behind the pathogenesis of male breast cancer and these studies guide our current understanding of the diagnosis and management of male breast cancer. Here, we report a case of a 74-year-old man

[☆] Competing interests: All authors confirm there are no known conflicts of interest associated with this publication. There has been no financial support for this work.

* Corresponding author.

** Co-corresponding author.

E-mail address: sheryl_jordan@med.unc.edu (S. Jordan).

<https://doi.org/10.1016/j.radcr.2021.10.015>

1930-0433/© 2021 The Authors. Published by Elsevier Inc. on behalf of University of Washington. This is an open access article under the CC BY-NC-ND license (<http://creativecommons.org/licenses/by-nc-nd/4.0/>)

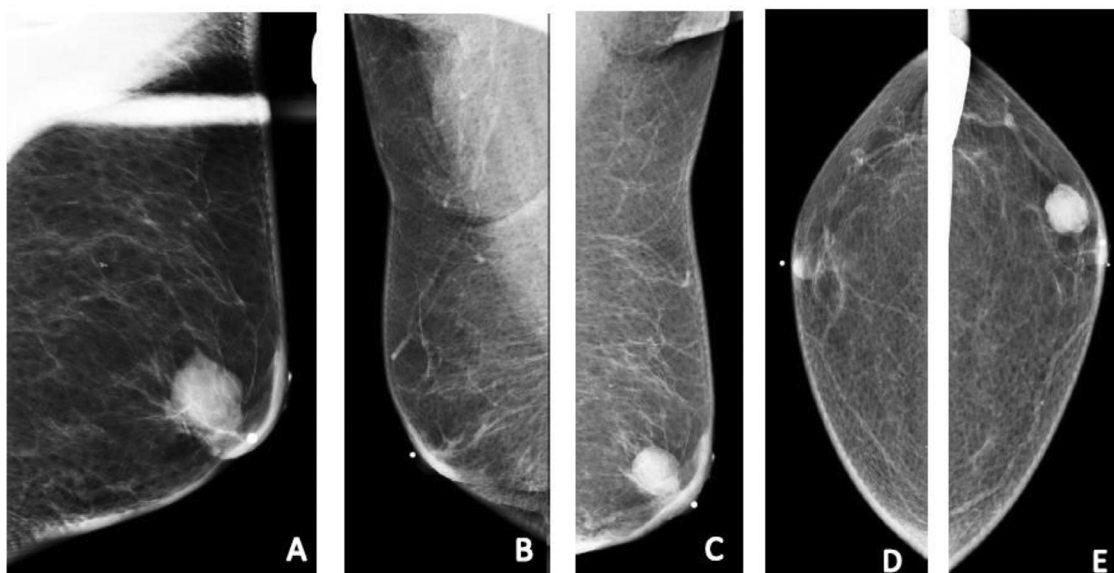


Fig. 1 – (A) Spot compression magnification MLO projection mammogram demonstrating a retroareolar high density mass with spiculated margins at the site of palpable abnormality. (B) MLO projection mammogram of the right breast demonstrating no abnormal masses, calcifications, architectural distortion or asymmetry (C) MLO projection mammogram of the left breast demonstrating a retroareolar mass at the site of palpable abnormality. (D) CC projection mammogram of the right breast demonstrating no abnormal masses, calcifications, architectural distortion or asymmetry. (E) CC projection mammogram of the left breast demonstrating an anterior depth mass eccentric to the bb-marked nipple.

with diagnosis of invasive mucinous carcinoma of the left breast.

Case report

The patient is a 74-year-old man with a past medical history of follicular thyroid cancer status post right hemithyroidectomy in 2016, who presented in 2017 with a palpable retroareolar left breast mass. Multiple family members were negative on genetic testing for hereditary breast cancer. Diagnostic mammogram demonstrated a round, dense, circumscribed 1.8 cm mass in the left breast 1 o'clock retroareolar anterior depth (Fig. 1). Mammograms were otherwise negative bilaterally. Targeted left breast ultrasound demonstrated a 1.8 cm isoechoic mass at the site (erroneously) assigned a BI-RADS Assessment Category 4B (Fig. 2).

Ultrasound-guided core needle biopsy of the left breast mass yielded invasive mucinous adenocarcinoma of the breast Nottingham grade 2 with ER/PR positivity and equivocal HER2 positivity on immunohistochemistry. Fluorescence in situ hybridization showed HER-2/neu to be not amplified. Given his history of follicular thyroid cancer and now breast carcinoma, patient underwent genetic testing and was found to be negative for mutations in the *BRCA1*, *BRCA2*, and *PALB2* genes.

The patient was referred to the authors' academic medical center multidisciplinary cancer clinic and discussed at a weekly multidisciplinary cancer clinic breast conference, with his comprehensive care discussed and decided. The patient underwent left mastectomy and sentinel lymph node biopsy

with axillary lymph node dissection. Surgical pathology results confirmed diagnosis of 18 mm grade 2 invasive mucinous cancer, with clear margins and absent lymphovascular invasion. 20 lymph nodes were negative for malignancy. His post-operative course was uncomplicated. The patient was started on tamoxifen orally and has had no evidence of disease in the ensuing 4 years, with annual imaging appointments.

Discussion

Over the past several years, the incidence of male breast cancer has risen in many regions of the world, including the United States [3]. Black men are more commonly affected than other races and are found to develop breast cancer at an earlier age, present with more advanced disease, and have higher rates of mortality [3,4]. The median age at which male breast cancer occurs is 68 years old [3].

The 5th edition of the World Health Organization Classification of Tumors includes the following as tumors of the male breast: gynecomastia, carcinoma in situ, and invasive carcinoma. Gynecomastia, or the benign proliferation of glandular tissue, can further be differentiated into florid and fibrous subtypes [3]. Carcinoma in situ consists of proliferation of epithelial cells in the mammary ducts. It can be categorized as ductal carcinoma in situ, lobular carcinoma in situ, and Paget disease of the nipple [3].

The etiology of male breast cancer is thought to most likely be due to a relative excess of estrogen, as would be seen in conditions such as cirrhosis and Klinefelter [5]. Other risk factors linked to this condition include those that decrease

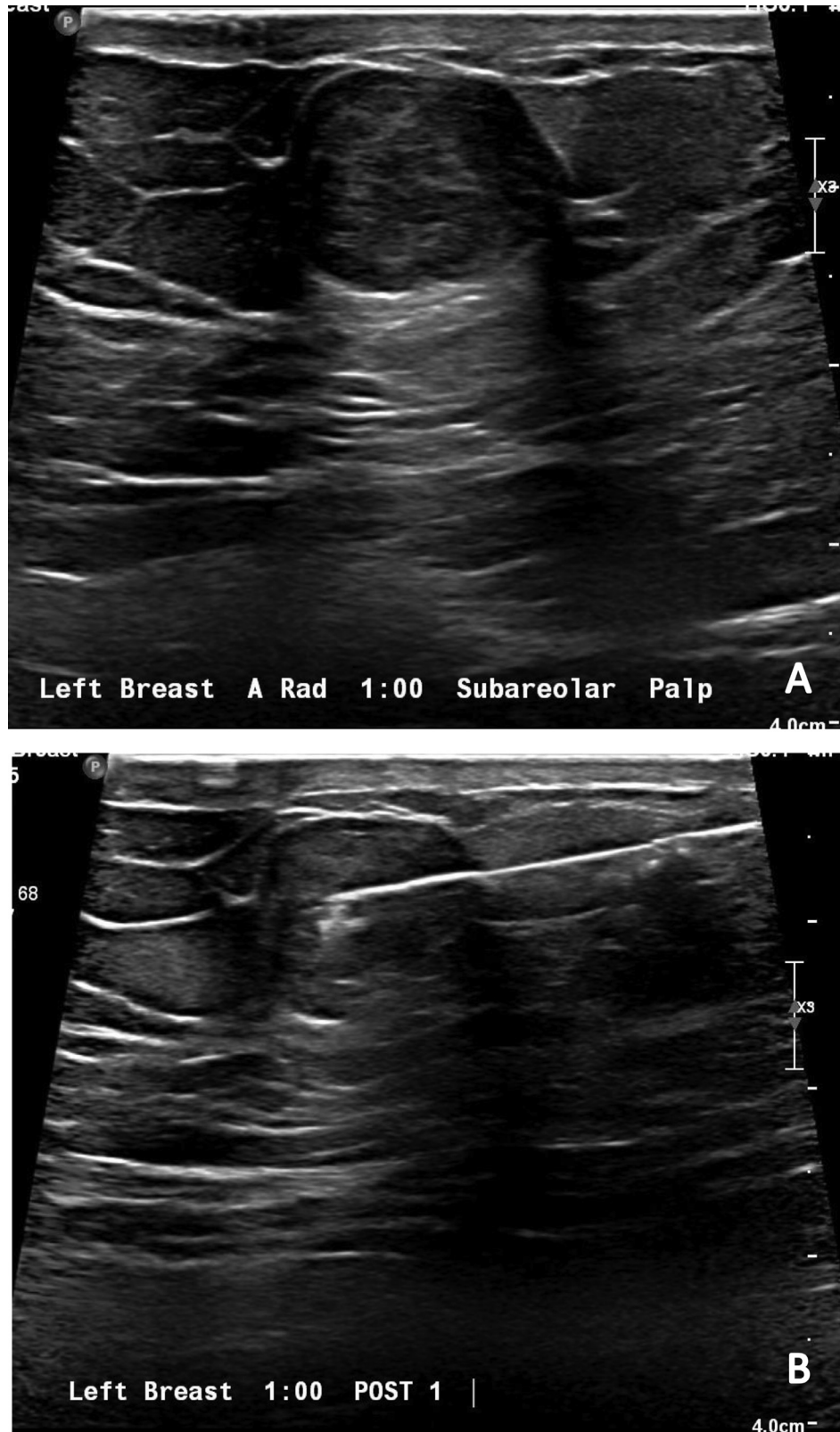


Fig. 2 - (A) Targeted ultrasound image of the left breast, retroareolar region at the palpable area of concern demonstrating a 1.5 cm oval, parallel isoechoic mass. **(B)** Targeted ultrasound-guided biopsy image of the left breast, retroareolar region demonstrating a core-needle biopsy device needle in the mass.

levels of testosterone, thus causing relatively higher levels of estrogen: increasing age, cryptorchidism, orchitis, and testicular trauma [6]. Gender confirmation hormonal therapies, both male-to-female and female-to-male, have been associated with a higher risk of developing breast cancer [3,7].

Genetics also play a significant role in the development of male breast cancer with 20% of patients having a first-degree family member with breast cancer [8]. Of these cases, one-third involve mutations of the *BRCA1/2* genes [9]. Approximately 5%-10% of men who are *BRCA2* carriers develop breast cancer, while the same occurs in only 1%-2% of *BRCA1* carriers [9,10]. Interestingly, the phenotype of *BRCA1/2* breast cancers in men seems to be more aggressive than those in women [11]. The *AR* gene plays a role in transforming male breast epithelial cells into neoplasm, highly expressed in as many as 74% of cases of male breast cancer [3].

Imaging of male breast cancer typically includes mammography and breast ultrasound. Male breast carcinoma is most commonly a high-density irregular mass on mammography [12,13]. Secondary findings include calcifications, skin thickening, nipple retraction, and axillary adenopathy [13]. Ultrasound features for invasive ductal carcinoma in men include discrete hypoechoic masses [12]. Calcifications, skin thickening, and nipple retraction can also be detected on ultrasound [12].

Pathologically, the most common type of male breast cancer is invasive ductal carcinoma of no special type, with the second most common being papillary carcinoma [3]. Lobular, mucinous, tubular, and metaplastic carcinomas are rare [3]. More than 90% of male breast cancers are ER and/or PR positive, a percentage that substantially exceeds those of female breast cancers. Most male breast cancers and their metastases express the some of the same epithelial breast markers that are present in female breast cancers; *GATA3*, *cyclin D1*, *mamoglobin*, and *BCL2* have been reported [14].

The gold standard for the diagnosis of both female and male breast cancers is now core needle biopsy [3]. Patients should undergo a clinical breast exam along with mammography and ultrasound [15]. The diagnostic criteria are the same as those of female breast cancer, with ER, PR, and HER2 immunochemistry being essential in classification [15]. Cancer staging, likewise, is based on TNM classification. Cross-sectional and molecular imaging are reserved for patients with higher stage tumor at risk for distant metastases.

Treatment options largely depend upon staging. With early, localized tumors, mastectomy with axillary dissection previously were the most commonly performed procedures [16]. Sentinel lymph node biopsy is now used as the alternative to axillary dissection in men with node-negative breast cancer [17]. Tamoxifen is a common adjuvant therapy option, with retrospective studies showing decreased rates of recurrence and death in male breast cancer patients [18,19]. One study comparing the use of aromatase inhibitors to tamoxifen in male hormone-receptor positive breast cancer patients showed that aromatase inhibitors were associated with a 1.5-fold increase in mortality to tamoxifen [20]. In cases of metastatic disease, treatment is typically limited to hormone therapy and/or chemotherapy [2].

In the case of this patient, the pathology report confirmed the presence of invasive mucinous carcinoma, which as men-

tioned previously, is very rare. The patient, older than the reported median age of 64, did not have a documented history of any conditions causing an estrogen-testosterone disruption. In terms of imaging, this patient presented with an isoechoic mass on ultrasound, consistent with imaging features of a mucinous tumor [21]. Although he did have a history of thyroid cancer, a pathogenic variant-related malignancy, genetic testing was negative and it is quite possible that a genetic mechanism by which this patient developed breast cancer has not yet been uncovered. Following then-standard surgical treatment, the patient has done well on post-adjuvant tamoxifen therapy with no evidence of disease at four years.

Conclusion

Male breast cancer is a rare but serious condition impacting a growing number of men each year worldwide. When evaluating male patients who present with a palpable retroareolar mass, a thorough history and physical should be performed for any conditions that may predispose to breast cancer. Mammography and ultrasound, along with core needle biopsy, are essential in diagnosis and characterization of the tumor. Treatment relies mainly on surgical resection, with adjuvant tamoxifen offering clear benefit.

Patient consent

Written consent for publication of this case was obtained from the patient and is available upon request. Additionally, the patient received and approved this manuscript.

REFERENCES

- [1] PDQ Adult Treatment Editorial Board Male Breast Cancer Treatment (PDQ®): Patient Version. PDQ Cancer Information Summaries 2002. National Cancer Institute (US) Accessed August 1, 2021 <http://www.ncbi.nlm.nih.gov/books/NBK65980/>.
- [2] . Cancer Facts & Figures 2021. Atlanta, GA: Published online; 1930. p. 72.
- [3] Foschini MP, Fox SB, Shaaban AM. WHO classification of tumours of the male breast. *Breast Tumours*. 5th ed. International Agency for Research on Cancer; 2019.
- [4] Anderson WF, Althuis MD, Brinton LA, Devesa SS. Is male breast cancer similar or different than female breast cancer? *Breast Cancer Res Treat* 2004;83(1):77–86. doi:10.1023/B:BREA.0000010701.08825.2d.
- [5] Gómez-Raposo C, Zambrana Tévar F, Sereno Moyano M, López Gómez M, Casado E. Male breast cancer. *Cancer Treat Rev* 2010;36(6):451–7. doi:10.1016/j.ctrv.2010.02.002.
- [6] Fentiman IS. The endocrinology of male breast cancer. *Endocr Relat Cancer* 2018;25(6):R365–73. doi:10.1530/ERC-18-0117.
- [7] de Blok CJM, Wiepjes CM, Nota NM, van Engelen K, Adank MA, Dreijerink KMA, et al. Breast cancer risk in transgender people receiving hormone treatment: nationwide cohort study in the Netherlands. *BMJ* 2019;365:l1652. doi:10.1136/bmj.l1652.

- [8] Multidisciplinary meeting on male breast cancer: summary and research recommendations. *J Clin Oncol*. Accessed August 4, 2021. <http://ascopubs.org/doi/10.1200/JCO.2009.25.5729>.
- [9] Tai YC, Domchek S, Parmigiani G, Chen S. Breast cancer risk among male BRCA1 and BRCA2 mutation carriers. *JNCI J Natl Cancer Inst* 2007;99(23):1811–14. doi:10.1093/jnci/djm203.
- [10] Evans DGR, Susnerwala I, Dawson J, Woodward E, Maher ER, Lalloo F. Risk of breast cancer in male BRCA2 carriers. *J Med Genet* 2010;47(10):710–11. doi:10.1136/jmg.2009.075176.
- [11] Silvestri V, Barrowdale D, Mulligan AM, Neuhausen SL, Fox S, Karlan BY, et al. Male breast cancer in BRCA1 and BRCA2 mutation carriers: pathology data from the Consortium of Investigators of Modifiers of BRCA1/2. *Breast Cancer Res* 2016;18(1):15. doi:10.1186/s13058-016-0671-y.
- [12] Chen L, Chantra PK, Larsen LH, Barton P, Rohitopakarn M, Zhu EQ, et al. Imaging characteristics of malignant lesions of the male breast. *RadioGraphics* 2006;26(4):993–1006. doi:10.1148/rg.264055116.
- [13] Nguyen C, Kettler MD, Swirsky ME, Miller VI, Scott C, Krause R, et al. Male breast disease: pictorial review with radiologic-pathologic correlation. *RadioGraphics* 2013;33(3):763–79. doi:10.1148/rg.333125137.
- [14] Serdy KM, Leone JP, Dabbs DJ, Bhargava R. Male breast cancer: a single-institution clinicopathologic and immunohistochemical study. *Am J Clin Pathol* 2017;147(1):110–19. doi:10.1093/ajcp/aqw207.
- [15] Giordano SH. A review of the diagnosis and management of male breast cancer. *Oncologist* 2005;10(7):471–9. doi:10.1634/theoncologist.10-7-471.
- [16] Yalaza M, İnan A, Bozer M. Male breast cancer. *J Breast Health* 2016;12(1):1–8. doi:10.5152/tjbh.2015.2711.
- [17] Maráz R, Boross G, Pap-Szekeres J, Marko L, Rajtar M, Ambrozay E, et al. The role of sentinel node biopsy in male breast cancer. *Breast Cancer* 2016;23(1):85–91. doi:10.1007/s12282-014-0535-1.
- [18] Ribeiro G, Swindell R. Adjuvant tamoxifen for male breast cancer (MBC). *Br J Cancer* 1992;65(2):252–4. doi:10.1038/bjc.1992.50.
- [19] Ribeiro GG, Swindell R, Harris M, Banerjee SS, Cramer A. A review of the management of the male breast carcinoma based on an analysis of 420 treated cases. *Breast* 1996;5(3):141–6. doi:10.1016/S0960-9776(96)90058-2.
- [20] Eggemann H, Ignatov A, Smith BJ, Altmann U, von Minckwitz G, Rohl FW, et al. Adjuvant therapy with tamoxifen compared to aromatase inhibitors for 257 male breast cancer patients. *Breast Cancer Res Treat* 2013;137(2):465–70. doi:10.1007/s10549-012-2355-3.
- [21] Pintican R, Duma M, Chiorean A, Fetica B, Badan M, Bura V, et al. Mucinous versus medullary breast carcinoma: mammography, ultrasound, and MRI findings. *Clin Radiol* 2020;75(7):483–96. doi:10.1016/j.crad.2019.12.024.