

Case report

Green laser induced foveal cyst sustained in a recreational laser light show



Rukiye Aydin^{*}; Merve Ozbek; Mustafa Ozsutcu; Fevzi Senturk

Abstract

We report the case of a 9-year-old boy complained of visual loss in his right eye after watching green laser light show being hit by a ray of a laser at shopping center before five days ago. The laser had a maximum power rating of 30 mW (US Food and Drug Administration class IIIB). Best-corrected visual acuity in his right eye was 0.2 with Snellen at 5 days after the injury. Dilated fundoscopic examination demonstrated a macular hole appearance in the right eye. Spectral domain optical coherence tomography (OCT, Spectralis, Heidelberg Engineering, Heidelberg, Germany) demonstrates a steep fovea contour, a thickening of the macular edges, intraretinal cysts, disruption of the photoreceptor inner segment/outer segment layer and macular pseudohole formation. Central foveal thickness (515 μm) was increased. Two months after the injury, the patient's visual acuity improved to 0.9 in the right eye without any ocular treatment. Spectral domain OCT revealed the closure of the macular hole with the resolution of the cystic spaces. At 6-months follow-up, visual function had fully recovered and macular assessment was normal.

Keywords: Foveal cyst, Green laser, Fundus autofluorescence, Optical coherence tomography

© 2017 The Authors. Production and hosting by Elsevier B.V. on behalf of Saudi Ophthalmological Society, King Saud University. This is an open access article under the CC BY-NC-ND license (<http://creativecommons.org/licenses/by-nc-nd/4.0/>). <http://dx.doi.org/10.1016/j.sjopt.2017.01.006>

Introduction

Lasers propagate a beam of light that is monochromatic, coherent and highly directional, and a laser beam gives very high energies to a very small area, even at great distances.¹ There has been increasing use of green lasers in industry, medicine and entertainment during the last few years. This has increased the risk of unintended retinal exposure, but accidental laser injuries are still infrequent.² Retinal laser lesions can cause serious visual problems and these are apparent with ophthalmoscopy and angiography.³ We would like to report a patient who suffered a green laser-induced foveal cyst.

Case report

A 9-year-old boy complained about visual loss in his right eye after watching a green laser light show and being hit by a

ray of a laser at a shopping center five days ago. The pulse duration of the laser was not assessed. The laser had a maximum power rating of 30 mW (US Food and Drug Administration class IIIB). He underwent a full ophthalmologic examination. The best-corrected visual acuity in his right eye was 0.2 with Snellen 5 days after the injury. Dilated fundoscopic examination demonstrated a foveal cyst in the right eye while the left eye was normal. Intraocular pressure was within normal range. *Fundus autofluorescence* (FAF) showed marked foveal hyper autofluorescence. Fig. 1 shows color fundus photographs. Spectral domain optical coherence tomography (OCT, Spectralis, Heidelberg Engineering, Heidelberg, Germany) demonstrates a steep fovea contour, a thickening of the macular edges, intraretinal cysts and a disruption of the IS/OS layer. Central foveal thickness (515 μm) was increased. Fluorescein angiography (FA) showed early hyperfluorescence within the area of the pseudohole due to window defect (Fig. 1). Fundus examination and ancillary

Received 14 July 2016; received in revised form 26 December 2016; accepted 30 January 2017; available online 21 February 2017.

Istanbul Medipol University, Department of Ophthalmology, Istanbul, Turkey

^{*} Corresponding author at: TEM Avrupa Otoyolu Goztepe Cikisi No:1, Bagcilar 34214, Istanbul, Turkey.
e-mail address: drrukiyeaydin@gmail.com (R. Aydin).

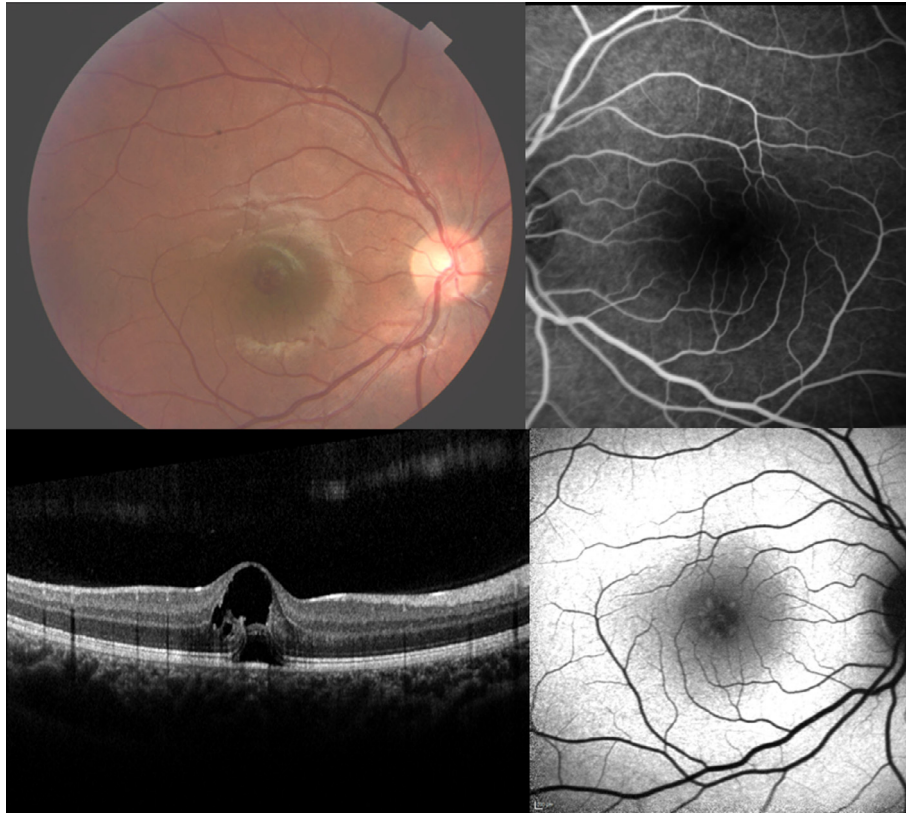


Fig. 1. Color fundus photograph, FAF, OCT and FA at first visit.

tests were consistent with laser induced foveal cyst. We did not initiate any medication therapy for the patient. The patient was followed closely. One week after the first visit, his visual acuity was 0.4 in the right eye. Fig. 2 shows color fundus photographs, FAF, OCT and FA at two weeks visit after injury. The following examinations showed closure of the foveal cyst with minimal subretinal fluid two weeks after the injury. Two months after the injury, the patient's visual acuity improved to 0.9 in the right eye. Spectral domain OCT revealed the closure of the foveal cyst with the resolution of the cystic spaces. The configuration for the photoreceptor inner segment/outer segment layer (IS/OS) was normal (Fig. 3). At 6-month follow-up, visual function was fully recovered. The final best corrected visual acuity was 1.0 with Snellen. The autofluorescence corresponding to the foveal cyst disappeared and OCT showed a normal fovea in structure and thickness (Fig. 4). Macular retinal layer segmentation by SD-OCT of the affected area is shown in Figs. 5 and 6.

Discussion

Accidental laser injuries are clearly diagnosed when there are known laser type, typical retinal injuries and visual deficits relative to retinal lesions. However, it is more difficult to determine when retinal findings are occult or absent despite reported visual symptoms and somatic complaints.³

Lasers are divided into four "classes" based on their output (Class 1 and 1 M, Class 2 and 2 M, Class 3A, 3B, and 3R and Class 4). Class 1 lasers, (energy < 0.4 mW) are the safest and cannot cause damage even if viewed for long periods of time. Visible laser pointers (400–700 nm) operating at < 1

mW and 1–5 mW power are Class 2 and Class 3A lasers respectively. Class 3B and 3R lasers generate between 5 and 500 mW of power while Class 4 lasers generate more than 500 mW of power.⁴

Although some laser-induced eye injuries have been reported in the past, reference to laser pointer-induced retinal injury has been limited to only a few articles on Class 3A red laser pointers in the literature reviews. Even less literature exists on the retinal hazards of Class 3A green laser pointers. Robertson and colleagues reported the absence of photopic retinal injury after Class 3A red laser exposure of up to 15 min.⁸ Their next study showed that a Class 3A green laser pointer is capable of causing retinal damage with exposures as short as 60 s.⁹ In the literature, retinal lesions induced by laser pointers (both Class 3A and 3B - approximately 500 mW power) include foveal granularity or foveal ring-shaped hypopigmented lesions, retinal edema, chorioretinal or vitreous hemorrhage, scars in the pigment epithelium, subretinal hemorrhage, perifoveal drusenoid-like deposits and rarely choroidal neovascularization.^{1,5} In our case, we observed a foveal cyst by 30 mW green laser. Macular holes have been reported due to exposure to a blue laser device (450 nm and a power range of 150–1200 mW) in the literature.⁶ However, there has not been a case of 30 mW green laser-induced foveal cyst reported before.

The aspect of a foveal cyst, also known as a foveal pseudocyst, is the first step in the configuration of a macular hole. A foveal cyst evolves as an effect of the vitreous pulling away from the retina. The intensity of the vitreous changes and gets thinner, as a result of the aging. This process can modify the form of the vitreous, causing it to separate from the retina and this is also known as vitreomacular traction syndrome. A

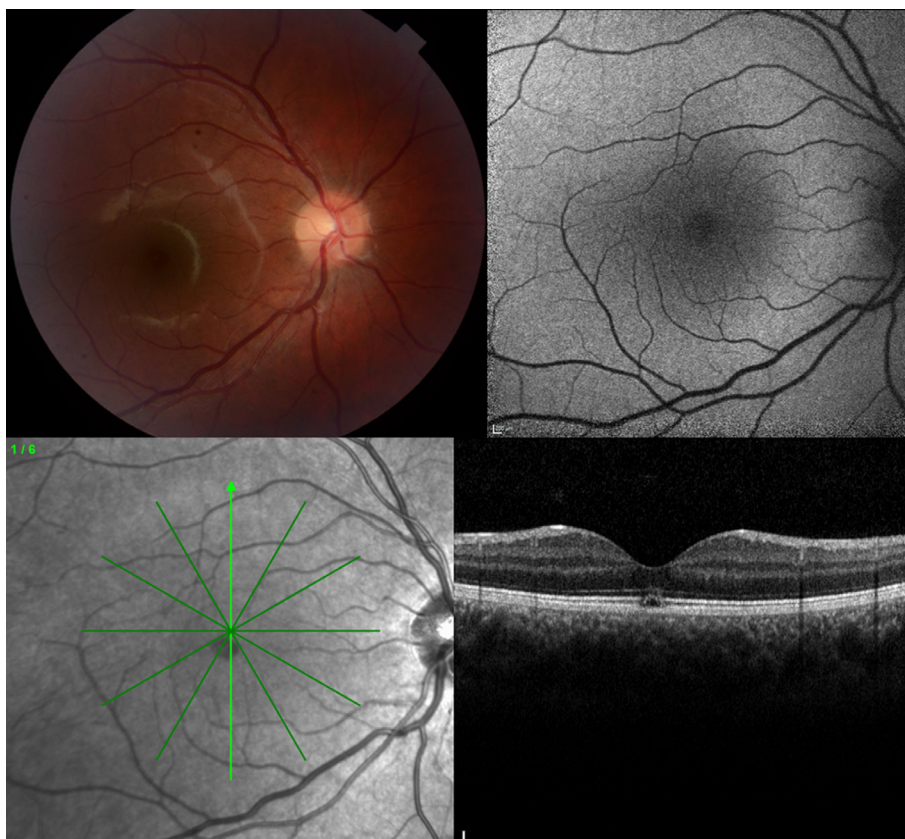


Fig. 2. Color fundus photograph, FAF and OCT at two weeks visit after injury.

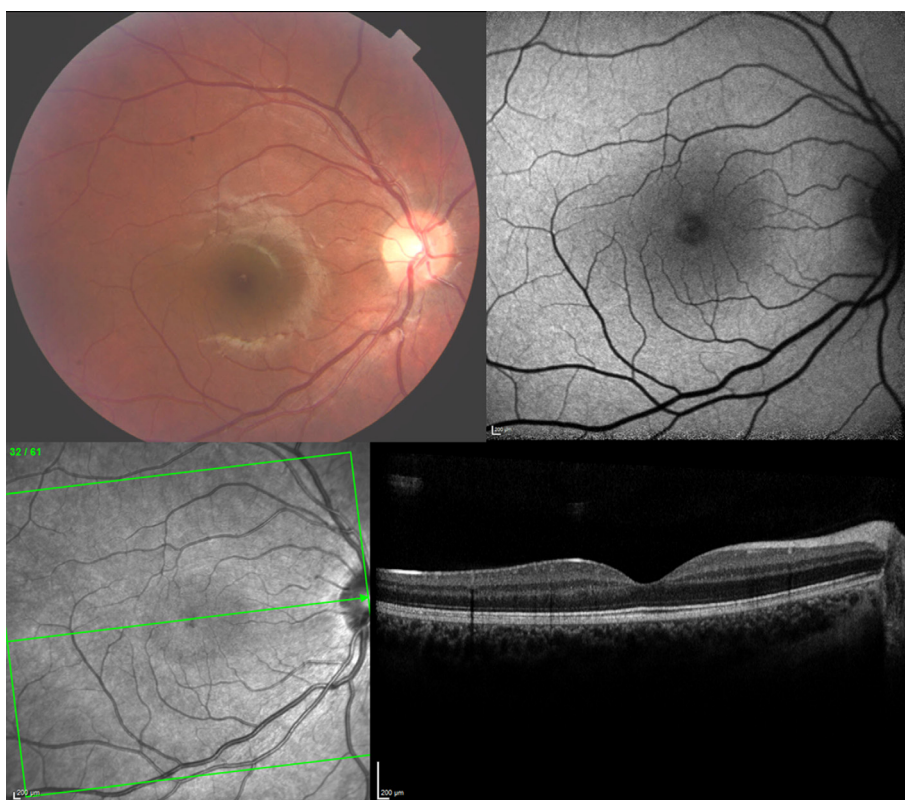


Fig. 3. Color fundus photograph, FAF and OCT at two months after injury

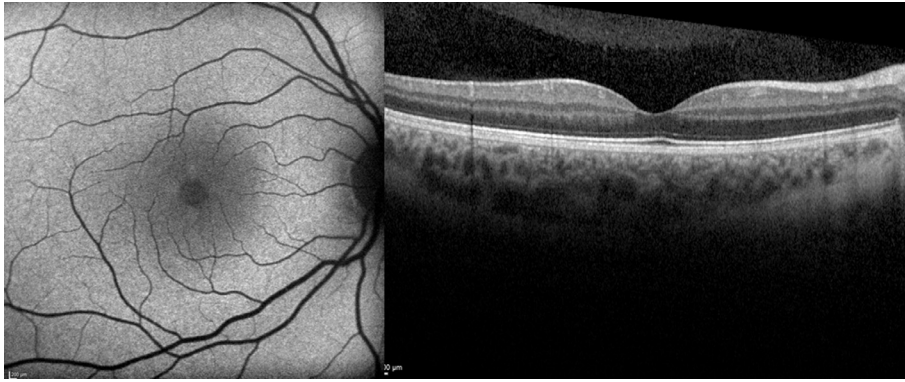

Fig. 4. FAF and OCT showed a normal fovea at six months after injury.

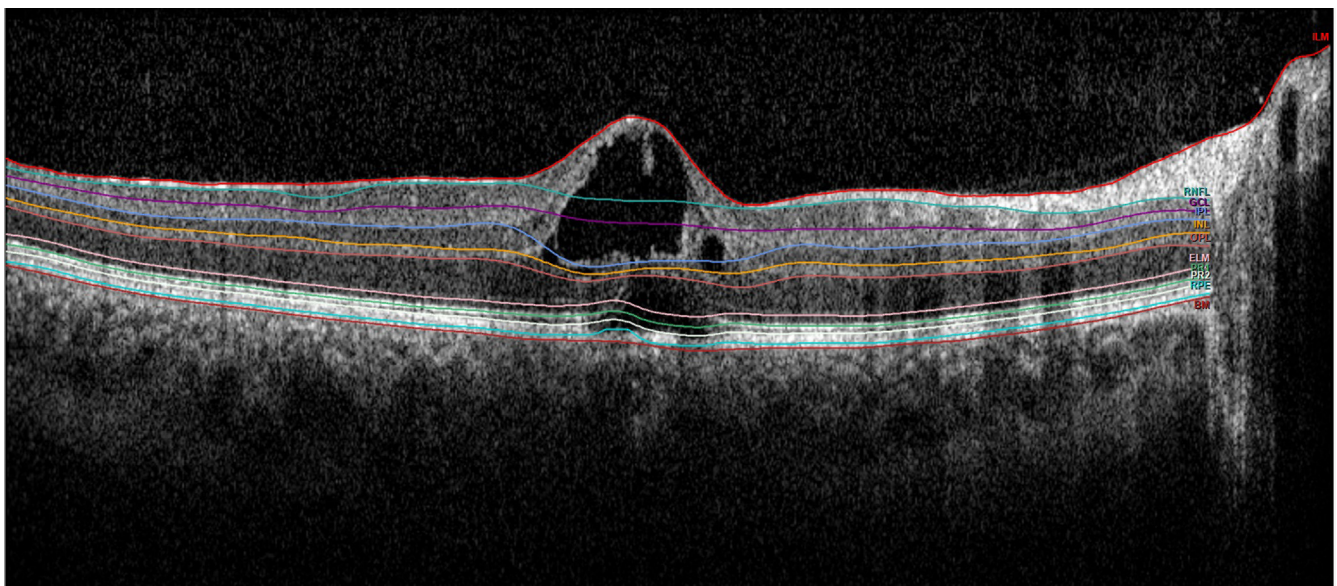


Fig. 5. Macular retinal layer segmentation by SD-OCT at first visit.

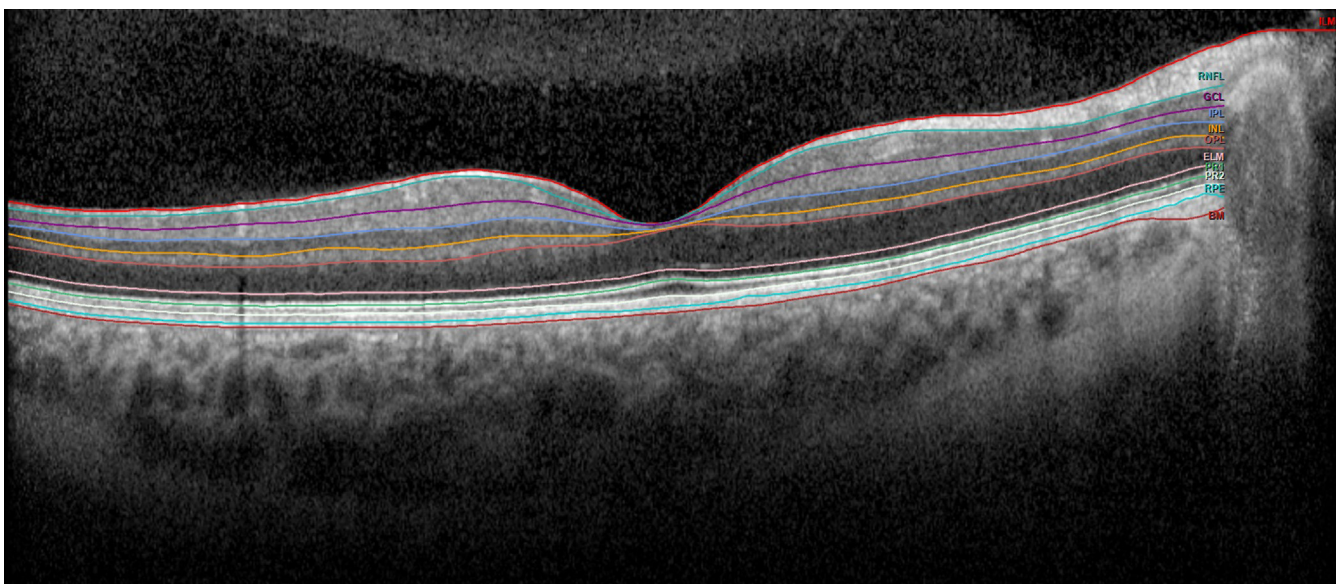


Fig. 6. Macular retinal layer segmentation by SD-OCT at six months after injury.

foveal cyst may stabilize and not need any medical treatment or it may improve further into a macular hole or a vitreous detachment. Treatment alternatives for a foveal cyst include intravitreal injections and, rarely, vitrectomy.¹⁰ Our patient's visual acuity showed a dramatic improvement in 3 months without any treatment. We closely observe patient's clinic recovery. In this case, we consider that the spontaneous vitreous liquefaction is caused by the decrease in macular traction, and this may cause foveal cyst spontaneous resolution.

It is especially important to be aware of the potential hazard of using laser beam by professional groups and to take preventive action against its dangers. Human eye should be protected against being in close contact with laser devices. These devices must be installed on places like roofs. Laser light with a power of 30 mw green laser may cause foveal cyst when used inappropriately.

This case report characterized the evolution of FAF, OCT and FA changes following laser induced macular injury. Multimodal imaging using FAF, OCT and FA imaging can help to explain mechanism and follow up patients' visual and anatomical progression.

This case report did not receive any specific grant from funding agencies in the public, commercial or not-for-profit sectors.

Conflicts of interest

The authors declared that there is no conflict of interest.

References

1. Dirani A, Chelala E, Fadlallah A, Antonios R, Cherfan G. Bilateral macular injury from a green laser pointer. *Clin Ophthalmol* 2013;**7**:2127–30.
2. Sunder KS, Shetty N, Singh VK, Chaudhary VS, Sharma S. Laser range finder can cause retinal injury. *Indian J Ophthalmol* 2004 Jun;**52**(2):169–70.
3. Mainster MA, Stuck BE, Brown Jr J. Assessment of alleged retinal laser injuries. *Arch Ophthalmol* 2004;**122**:1210–7.
4. Shenoy R, Bialasiewicz AA, Bandara A, Isaac R. Retinal Damage from Laser Pointer Misuse – Case Series from the Military Sector in Oman. *Middle East Afr J Ophthalmol* 2015;**22**(3):399–403.
5. Turaka K, Bryan JS, Gordon AJ, Reddy R, Kwong Jr HM, Sell CH. Laser pointer induced macular damage: case report and mini review. *Int Ophthalmol* 2012;**32**(3):293–7.
6. Alsulaiman SM, Alrushood AA, Almasaud J, Alzaaidi S, Alzahrani Y, Arevalo JF, et al. High-power handheld blue laser-induced maculopathy: the results of the King Khaled Eye Specialist Hospital Collaborative Retina Study Group. *Ophthalmology* 2014;**121**(2):566–72.
8. Robertson DM, Lim TH, Salomao DR, Link TP, Rowe RL, McLaren JW. Laser pointers and the human eye: a clinicopathologic study. *Arch Ophthalmol* 2000;**118**(12):1686–91.
9. Robertson DM, McLaren JW, Salomao DR, Link TP. Retinopathy from a green laser pointer: a clinicopathologic study. *Arch Ophthalmol* 2005;**123**(5):629–33.
10. Haouchine B, Massin P, Gaudric A. Foveal pseudocyst as the first step in macular hole formation: a prospective study by optical coherence tomography. *Ophthalmology* 2001;**108**(1):15–22.