

# Vomer Flaps Support Velopharyngeal Competency, Fistula Free Repair, and 3D Construction of Normal Anatomy in Patients with Cleft Palate

Gül Schmidt, MD, DMD\*

Evjenia Toubekis, MD†

Hubertus Koch, MD, DMD‡

Jürgen Schlabe, MD, DMD‡

Christa Hunn-Stohwasser\*

Benedicta Beck-Broichsitter, MD,

DMD\*

Max Heiland, MD, DMD\*

Carsten Matuschek, MSc, PhD\*

**Background:** Cleft palate repair comprises the surgical creation of a congenitally nonexistent normal anatomy, to establish physiological function by moving tissues into their normal anatomical positions. In patients with isolated incomplete (IICP) or submucous (SMCP) cleft palate, the vomer is usually not completely attached to the palatal plate in the midline. This condition, which is visible through surgical access radiologically or via endoscope, is often disregarded during hard palate repair. This can lead to “hypernasality” despite a well-functioning velopharyngeal mechanism. The general practice of hard palate repair by suturing merely the nasal layers together separates the oral and nasal cavities. However, *without* incorporation of the vomer, it is impossible to build two separate nasal floors on the left and right sides. We consider that achieving normal speech and separation of the nasal cavities are mutually dependent and have to be considered equally.

**Methods:** We described hard palate repair involving the vomer for construction of both nasal floors. We presented the occlusal relationship, hypernasality, and fistula rates in 37 patients operated on between January 1, 2017 and June 30, 2018.

**Results:** One child presented minimal hypernasality; all others had normal resonance/voice. Fistula rate was zero, and no cross bites were observed.

**Conclusions:** The implicit connection between the inner nose, resonance/voice, and prevention of fistulae has not yet been acknowledged. The correct usage of vomer flaps in IICP and SMCP creating separate nasal floors supports the velopharyngeal competency, avoids fistula formation, and should be incorporated regularly, like in other cleft forms. (*Plast Reconstr Surg Glob Open* 2021;9:e3968; doi: 10.1097/GOX.0000000000003968; Published online 6 December 2021.)

## INTRODUCTION

Koch et al highlighted the anatomical affiliation between the vomer as part of the cleft lip alveolus and hard and soft palate malformation.<sup>1</sup> Velopharyngeal incompetency has been successfully treated globally using intravelar veloplasty.<sup>2-4</sup> However, in some patients,

hypernasality in speech may occur despite velopharyngeal or borderline competency. In these patients, nonunification between the vomer and the maxilla may be observed endoscopically and radiologically, despite previous cleft palate repair, resulting in a nonphysiological connection between the left and right nasal floors. **Figure 1A** depicts a fistula and a part of the nonunited vomer is visible, **Figure 1B** depicts nonunited nasal cavities with probes, and **Figure 1C** depicts the intraoperative appearance of the entire untouched vomer after modeling osteotomy. **Figure 2** shows a magnetic resonance image demonstrating the distance between the nonunited vomer and the hard palate in the sagittal plane.

We concluded that the nonunited vomer acts like a septal defect and may cause symptoms in some patients. Accordingly, we take great care to incorporate the vomer in incomplete isolated (IICP) and submucous cleft palates (SMCP), as is normal practice in unilateral (UCLP), bilateral (BCLP), and more or less regularly (**Fig. 1**) in isolated complete (ICP) cleft palate repairs.

*From the \*Charité – Universitätsmedizin Berlin, Freie Universität Berlin, Humboldt-Universität zu Berlin and Berlin Institute of Health, Department of Oral and Maxillofacial Surgery, Berlin, Germany; †Charité – Universitätsmedizin Berlin, Freie Universität Berlin, Humboldt-Universität zu Berlin and Berlin Institute of Health, Department of Anesthesiology and Intensive Care Medicine, Berlin, Germany; and ‡DRK-Kinderklinik Siegen, LKGN-Kompetenzzentrum, Siegen, Germany.*

*Received for publication June 18, 2021; accepted October 6, 2021.*

*Copyright © 2021 The Authors. Published by Wolters Kluwer Health, Inc. on behalf of The American Society of Plastic Surgeons. This is an open-access article distributed under the terms of the [Creative Commons Attribution-Non Commercial-No Derivatives License 4.0 \(CCBY-NC-ND\)](https://creativecommons.org/licenses/by-nc-nd/4.0/), where it is permissible to download and share the work provided it is properly cited. The work cannot be changed in any way or used commercially without permission from the journal.*

DOI: 10.1097/GOX.0000000000003968

**Disclosure:** The authors have no financial interest to declare in relation to the content of this article.

We present a surgical technique for hard palate repair in IICP/SMCP that focuses on the incorporation of the vomer, thereby creating a normal nasal anatomy and obtaining physiological and clinical results.

## METHODS

### Patients

We have been documenting cases of pre- and intraoperative cleft expansions regularly since 2017. We present the data of patients operated on in our hospital between January 1, 2017 and June 30, 2018.

During the study period, the first author treated 439 patients with several forms of facial cleft. Forty-six patients had an IICP and one had an SMCP. The mean age at surgery was 7 ( $\pm 3$ ) months. Nine patients were excluded due to a syndrome or additional malformations with no speech development [unknown syndromes ( $n = 2$ ); Wolff-Hirschorn syndrome, Kabuki syndrome, severe developmental disorder, severe heart defect (+), autism, and microdeletion Chr 16 ( $n = 1$ , each)]. Among the remaining 37 patients, four presented with Pierre Robin sequence (PRS), one 8q21.11 microdeletion syndrome, and one patient had aortic valve insufficiency with early support therapy.

We have provided data on the number of fistulae and occurrence of hypernasality (resonance/voice) based on cleft audit protocols for speech and spontaneous conversation, and on the occlusal relationship at the age of 3.5–4 years.

### Anatomical Considerations

In normal individuals, the vomer is attached to the hard palate along the midline, creating two nasal floors from the nostril to the posterior nasal spine. In IICP and SMCP, this connection stops posterior to the incisive foramen in variable extensions, and can also be present along with an ossified intact bony hard palate (Fig. 3).<sup>5,6</sup> This leaves the nasal floor fused, resulting in one enlarged nasal cavity posterior to the connection, which can lead to a disturbed frequency composition manifesting as hypernasality without nasal emissions.

### Surgical Procedure

*Oral closure:* Axial flaps

*Velar closure:* Intravelar veloplasty (Kriens, Sommerlad), Furlow Z-plasty according to the surgeon's preference.<sup>2-4</sup>

*Detailed surgical technique for hard palate repair:* Complete exposure of the malformation above the intact nasal mucosa and bony plate.

The primary aim was to trace the site of attachment between the vomer and the hard palate, which can be assessed using a dental mirror (Fig. 4A, B), to estimate its range and the anterior extent of the oral axial flaps to be designed.

In some cases, it is sufficient to incise the nasal layer (of the submucous part) in the midline to gain access to the vomer. However, in more severe cases, the intact bony plate or the bony cleft edges must be removed temporarily, followed by lifting and incising the underlying

### Takeaways

**Question:** It is possible to prevent fistulae and reduce hypernasality in patients with cleft palate?

**Findings:** In patients with Veau I and submucous cleft palates, the vomer is not completely attached to the palate. The method described here explains the access to the vomer, enables 3D correction of cleft deformities, and is easy to imitate. Of the 37 patients, one child presented minimal hypernasality, and all other patients had normal resonance/voice. The fistula rate was zero, and no crossbites were observed.

**Meaning:** This method enables the surgeons to operate without fistulae, and supports velopharyngeal competency and three-dimensional construction of the normal nasal, vomerine, and palatal anatomy.

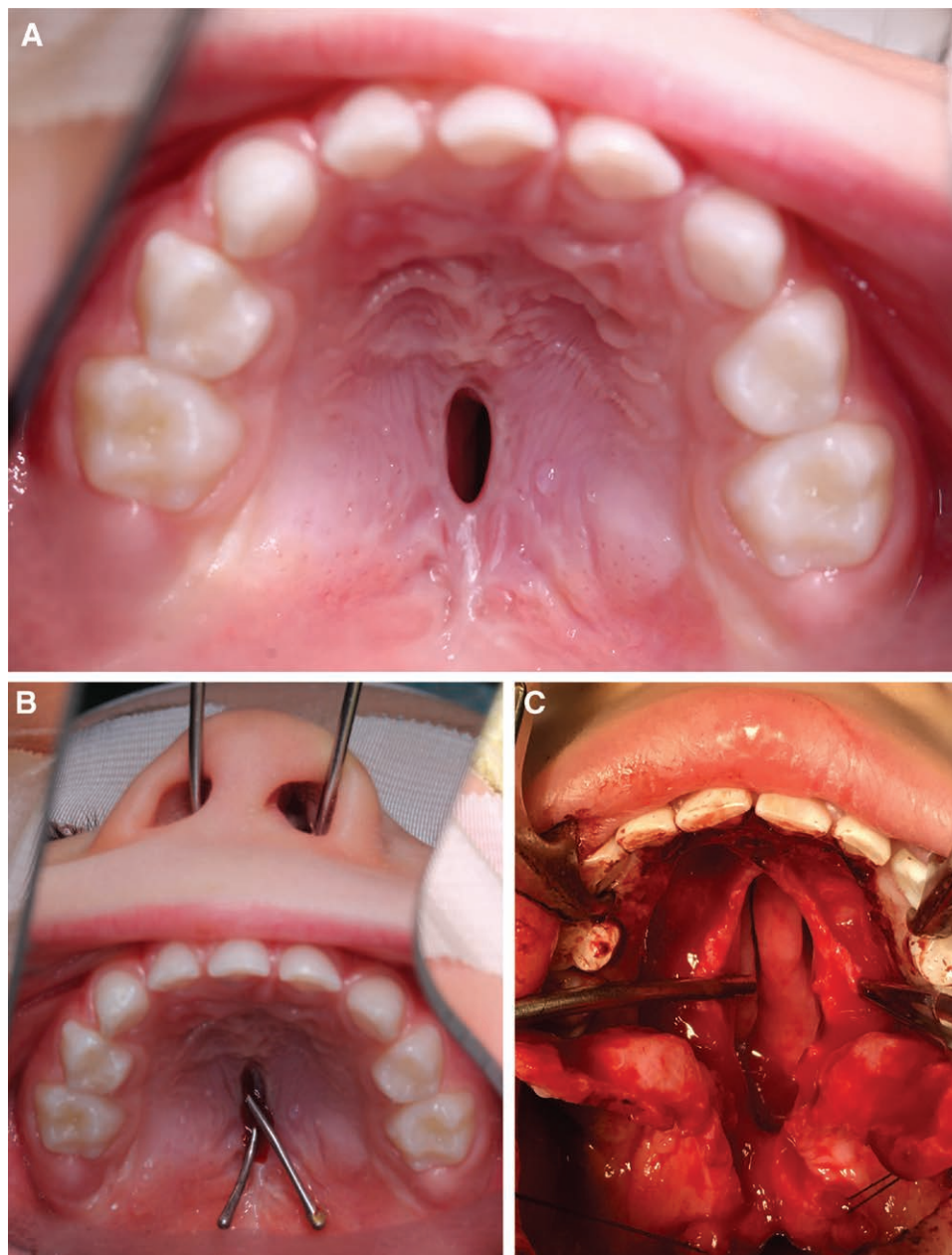
nasal mucoperiosteum with a bone nibbler or Luer bone rongeur until the attachment between the vomer and the hard palate can be observed. The extent of lateral and anterior bony resection on both sides may differ in length and breadth. This must be considered during midline incision of the vomer. The following technique ensures complete mobilization of the nasal layer on both sides (in considerably wide clefts, the elevation includes the mucoperiosteum of the medial pterygoid plate)<sup>7</sup> in continuity with the vomerine mucosa for a tension-free closure. Loosening the anterior part of the nasal mucoperiosteum in continuity with the vomer flaps at the attachment site provides a clear view and easy access, which ensures prevention of an anterior fistula (Fig. 4C, D). The vomerine mucosa on each side is then sutured to the nasal mucosa on either side, creating an individual and fully sealed nasal floor on the left and right sides.

A final suture is placed at the base of the vomer in the area of the posterior nasal spine, approximating both nasal and both vomerine layers in the midline (Fig. 4E). This maneuver creates a bed for the vomer, and allows the soft palate to be elevated cranially. This securely adapted special suture at the junction of the hard and soft palate eliminates the risk of fistula formation at this site and corresponds to the normal anatomy (Fig. 4F, Fig. 5).

After the axial flaps are sutured together, but not to the anterior attached mucosa, the previously removed bone is replanted. Repair of the soft palate includes intravelar veloplasty and closure of the nasal and oral layers to achieve a three-layered closure.

The united but dangling axial flaps, without being fixed anteriorly (Fig. 6A), are compressed after replacement of the resected bone with a dressing plate toward the hard palate to reduce the dead space and prevent tent-like sagging of the axial flaps while simultaneously creating esthetic results (Fig. 6B).

Figure 7A shows the coronal morphology after suturing merely the nasal and oral layers of the hard palate, resulting in one nasal cavity (presenting 2D repair). Figure 7B shows the creation of two nasal cavities (normal anatomy) connecting the nasal layers with the vomer flaps on both sides (3D repair).



**Fig. 1.** Situation without incorporation of the vomer. A, Patient with a fistula through which a small part of the vomer is visible. B, Probes through the nose show the pathologic connection between the right and left nasal floors. C, Whole extent of the nonunited vomer after modeling osteotomy of the hard palate.

#### Classification

##### *Hard Palate (H) and Soft Palate (S) Clefts*

- H3–H1: cleft extent, complete to 2/3 and 1/3 of the hard palate
- S3–S1: cleft extent, complete to 1/2 and 1/3 of the soft palate

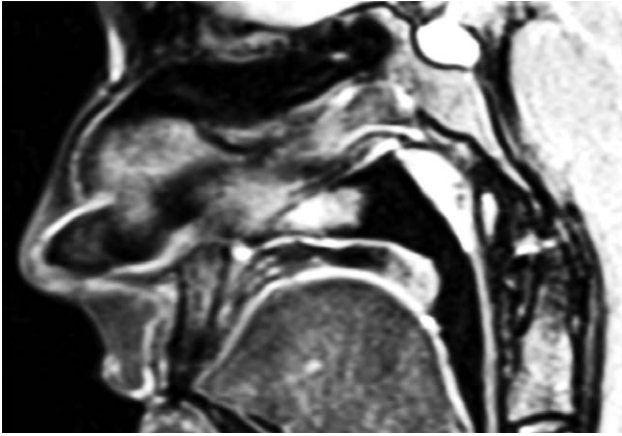
We determined the preoperative extent of the cleft based on the clinical view and the intraoperative extent depending on the attachment level of the vomer following surgical access.

In this study, we report about the resonance/voice, nasal emission/nasal turbulence, and orofacial

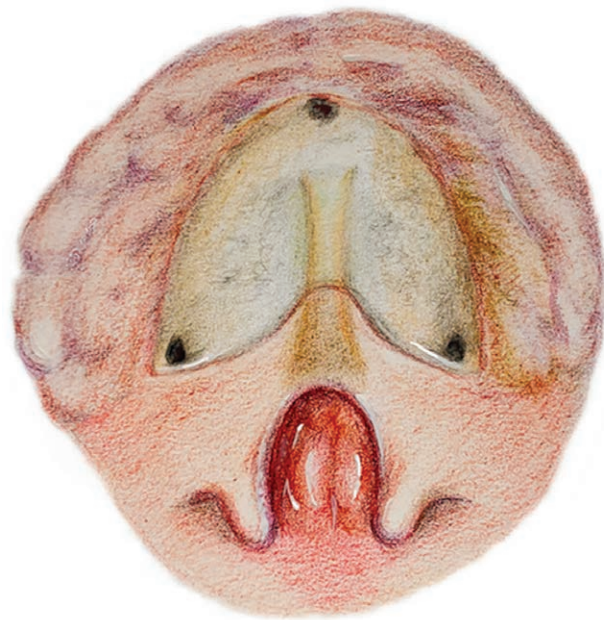dysfunction rates. Occlusal relationships and fistulae were assessed by intraoral inspections. We further differentiated among U-shaped clefts, wide (>1 cm) clefts, hypoplastic muscles, velar asymmetries, velar lengths (depending on the extent of adenoid pad visibility at the level of the posterior palatal arch), and mobility.

#### Ethics Consideration

Informed consent has been obtained from all individuals included in this study. The research related to human use complies with all the relevant national regulations and institutional policies, was performed in accordance with the tenets of the Declaration of



**Fig. 2.** MRI sagittal plane shows the distance between the nonunited vomer and the hard palate resulting in one nasal cavity.



**Fig. 3.** Initial condition without oral mucosa revealing an intact bony plate and intact nasal mucosa with a nonunited vomer, drawn translucent.

Helsinki, and was approved by the ethics committee of Charité-Universitätsmedizin Berlin (approval number: 0EA2/118/21).

## RESULTS

### Results in the 31 Patients with IICP and SMCP

In contrast to the clinical view in each patient, the vomer was intraoperatively not attached to the hard palate in several extensions. Even patients with minimal extent of soft palate cleft (S2) were intraoperatively observed to have a complete cleft palate up to the incisive foramen (Table 1).

### Results in the Patients with PRS, Microdeletion Syndrome, and Heart Defect

Out of the four patients with PRS who were postnatally treated with pre-epiglottic baton plate (PEBP) (which helped reduce the cleft width), three had H2S3 and one had S3 preoperatively.<sup>8</sup> Intraoperatively, all cleft forms extended to H3S3. The patient with the microdeletion syndrome had H2S3 that extended to H3S3 intraoperatively, and the patient with the heart defect had H1S3 that extended to H2S3 intraoperatively (Table 1).

The cleft shape characteristics had no influence on speech, occlusion, or fistula rates.

The overall cleft mobility was good.

One child presented with minimal hypernasality at the age of 3.5 years after repair of a wide S3/H2S3 cleft. The remaining 36 patients, including those with PRS, microdeletion syndrome, and heart defect, showed normal resonance/voice patterns. Apart from one child with a thumb-sucking habit and an open bite, there were no orofacial abnormalities. Occlusal relationship (including the patients with PRS who underwent postnatal PEBP therapy) was normal, except in one patient who had familial jaw protrusion. Cleft shape severity had no influence on speech or occlusal development (Tables 2, 3). Nonspaced dentition was observed in 52% of the patients with IICP/SMCP, and in 67% of the patients with PRS, microdeletion syndrome, and heart defect. These conditions were always bimaxillary.

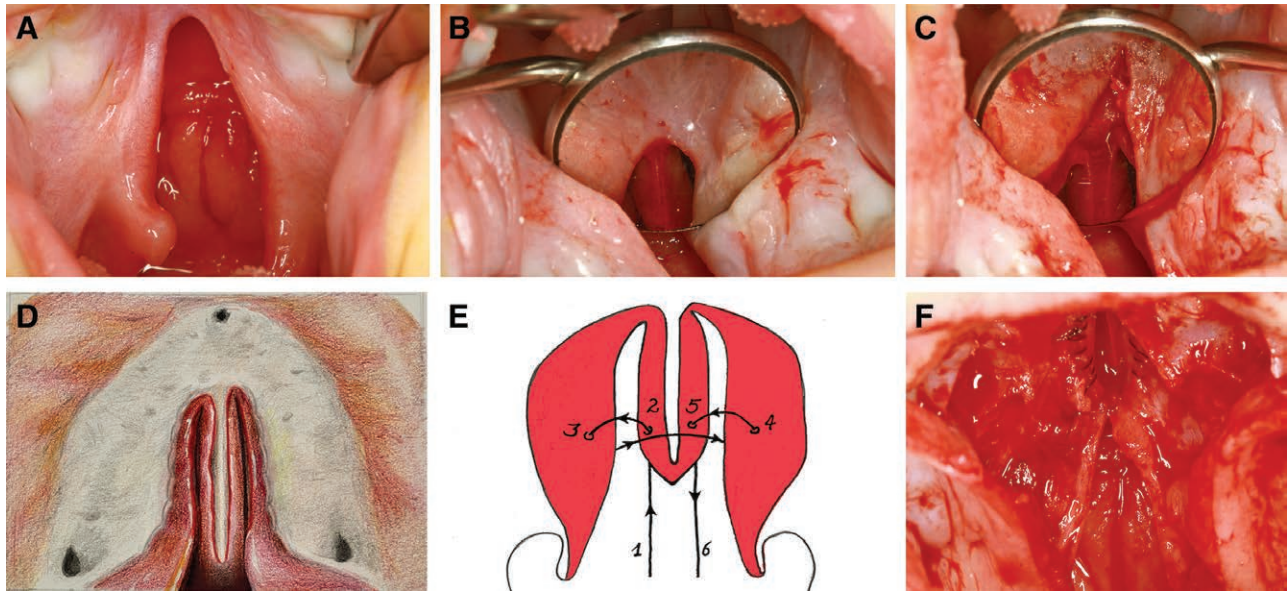
## DISCUSSION

Our findings after observing 37 miscellaneous patients with IICP and SMCP who were operated on between January 2017 and June 2018 were very promising. Except for one child with minimal hypernasality at the age of 3.5 years, normal resonance/voice was observed in all patients at an early age. No fistulae or transverse crossbites were observed.

Accurate construction of the inner nose and adequate formation of the velar muscle sling appear to be the right combination to achieve a more normal voice in patients with cleft palate. The occurrence of fistulae in patients with ICP has been previously reported. Andersson et al postulated that fistulae develop more often in patients with SMCP and ICP than in those with only soft palate clefts.<sup>9</sup> Phua et al observed higher fistula rates in more severe clefts and 31.8% hypernasality following primary palatoplasty.<sup>10</sup> Hardwicke et al reported a 5.4% fistula rate in patients with ICP.<sup>11</sup> We are convinced that the risk of fistula formation can be eliminated with our proposed technique.

Previous reports on endoscopic findings on the abnormal development of the vomer and our observation of hypernasality despite a well-functioning velopharyngeal mechanism prompted us to modify our surgical technique for hard palate repair in patients with IICP and SMCP.<sup>1,3,5,12</sup>

Vomer flaps are generally used in Veau III–IV clefts, not generally in Veau II clefts, and we could only find one article on the use of vomer flaps (recommending minimal ostectomy) in the management of Veau I clefts.<sup>12,13</sup> Incorporation of the vomer in I(I)CP and SMCP has



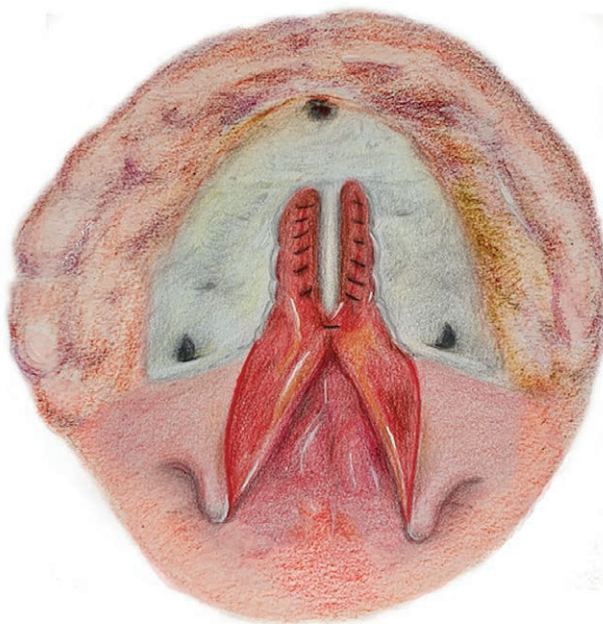
**Fig. 4.** Surgical steps demonstrating the incorporation of the vomer. A, Clinical view. B, Mirror image of the attachment site between the vomer and the hard palate, and with the incision in the midline of the vomer and along the cleft edges. C, Easy mobilization of the vomer and nasal flaps after bony resection. D, Possible extension of bony resection for an adequate approach to the nasal and vomerine flaps. E, Suture drawn to reveal the seam guide. F, Image after the key suture is tied at the spina posterior, creating a bed for the vomer and separated nasal floors.

always been left at the surgeon's discretion, without considering it as an integral part of cleft pathology.<sup>14</sup>

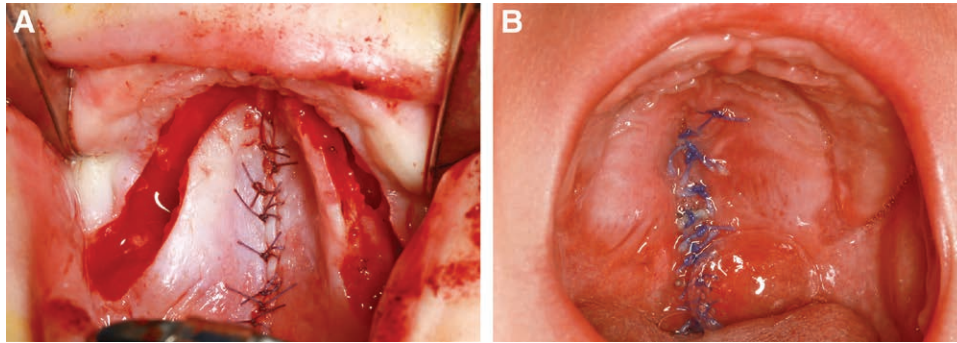
Previous literature remains unclear on whether children with ICP and SMCP present with worse speech results compared with control groups with cleft lip and palate.<sup>15,16</sup> Missing or incomplete construction of the inner nose during hard palate repair could be an explanation for the gap in the literature regarding these

results. We realized the significance of the fact that Veau I clefts are often not limited to the soft palate only. The construction of the normal anatomy with adequately separated nasal floors is essential and only possible when the entire length of the vomer is incorporated during hard palate repair. Therefore, the main emphasis of this study was on the nasal part, with a description of the accessibility of the attachment site between the vomer and the hard palate mucosa in patients with Veau I clefts, and the key suture uniting both the nasal and vomer flaps at the spina nasalis posterior, to elevate the soft palate. Following the principle of "bringing what is normal into the normal position," we believe that a surgically created normal anatomy in I(I)CP and SMCP facilitates normal nasal breathing, better control of hypernasality, and eliminates the incidence of fistula formation. The surgical technique discussed in this study is based on the ideas and work of Josef Koch, one of the leading surgeons in cleft repair in Germany. However, despite its geniality and comprehension, his technique has not been accepted in mainstream surgery.

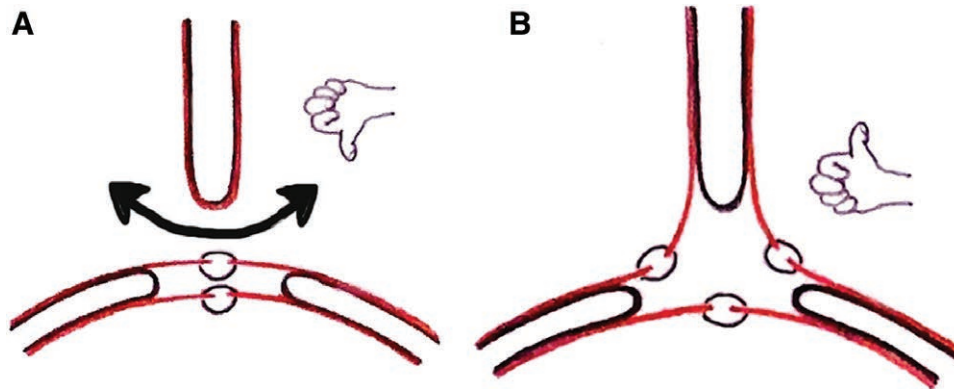
The unusual step of bony dissection, axial flaps, and extensive mobilization may be a concern in terms of deterioration of the occlusal relationship when the patients get older. However, it has been shown that patients with ICP (without inclusion of the alveolar process) have no anterior growth impairment after early cleft palate repair, and this promotes age-related speech development.<sup>17,18</sup> Therefore, transverse malocclusion may be reliably corrected later using orthodontic treatments. Freng experimentally resected bone completely along the junction between nasal septum/vomer and the hard palate; however, even after such radical resection including the prevomerine suture,



**Fig. 5.** Corresponding sketch.



**Fig. 6.** A, Dangling axial flaps. B, Two weeks postoperatively.



**Fig. 7.** Coronal diagrams. A, Pathologic (2D) construction of the anatomy by approximating the nasal and oral layers. B, Normal (3D) nasal, vomerine, and palatal anatomy after incorporation of the vomer.

premaxilla, and maxilla, the vertical, and sagittal growths remained undisturbed.<sup>19</sup> Mulliken et al reported on the necessity of the Le Fort 1 repair in patients with clefts and showed that none of the patients with ICP needed it.<sup>20</sup> Heliövaara et al have shown that male children with ICP had smaller maxillary/mandibular arch widths than those without clefts; therefore, this may be an intrinsic restriction that may explain the maxillary/mandibular nonspaced dentition in 52% of our patients.<sup>21</sup> However, none of them presented with cross bites, such as what observed in UCLP or BCLP at the age of 4 years, which depicts the onset of growth restriction. The significance of surgical construction of the normal nasal anatomy in promoting normal resonance/voice and physiology is also highlighted here, as opposed to resecting and replacing the bone with the expectation of transverse nondisfiguring growth impairment, which can be fixed using orthodontic treatment.

### CONCLUSIONS

Many ways lead to Rome: the choice between Furlow and Sommerlad veloplasty is not the question, as both methods are successful in establishing normal velopharyngeal competency. The key to achieving consistently positive results lies in the combination of (1) connecting the nasal layers using vomer flaps, such as that in UCLP/BCLP; (2) uniting all four vomer and nasal flaps at the spina nasalis posterior; and (3) construction of an appropriate velar muscle sling at the base of the soft palate.

**Table 1. Classification of Incomplete Isolated Cleft Palate and Submucous Cleft Palate Pre- and Intraoperatively**

Classification of Cleft Extent (n = 37)	
Preoperative (n)	Intraoperative (n)
H2S3 (9)	H3S3 (6)
H1S3 (14)	H2S3 (3)
	H3S3 (5)
S3 (11)	H2S3 (8)
	H1S3 (1)
	H2S3 (10)
S2 (1)	H1S3 (1)
S1 (1)	H3S3 (1)
Submucous (1)	H1S3 (1)
	H3S3 (1)

**Table 2. Cleft Characteristics (n = 37)**

Cleft Characteristics	Patients with IICP and SMCP (n = 31)	PRS (n = 4)	Microdeletion Syndrome/Heart Defect (n = 2)
U-shaped	4 (13%)	0	0
Wide cleft	4 (13%)	0	0
Hypoplastic muscles	3 (10%)	0	0
Asymmetric velar halves	3 (10%)	0	0
Long vela	7 (23%)	1 (25%)	0
Middle long vela	19 (61%)	2 (50%)	1 (50%)
Short vela	7 (23%)	1 (25%)	1 (50%)
Good velar mobility	31 (100%)	4 (100%)	2 (100%)

IICP, incomplete isolated cleft palate; PRS, Pierre Robin sequence; SMCP, submucous cleft palate.

**Table 3. Results in Patients with IICP and SMCP (n=37)**

	Patients with ICP and SMCP (n = 31)	PRS (n = 4)	Microdeletion Syndrome/ Heart Defect (n = 2)
Resonance/voice, orofacial abnormality			
Normal	30 (97%)	4 (100%)	2 (100%)
Minimal hypernasality	1 (3%)	0 (0%)	0 (0%)
Salivation and alternating closure of mouth	1 (3%)	0 (0%)	0 (0%)
Thumb-sucking	1 (3%)	0 (0%)	0 (0%)
Fistula rate	0 (0%)	0 (0%)	0 (0%)
Occlusal relationship			
Anterior/transverse crossbite	1 (3%)	0 (0%)	0 (0%)
Nonspaced dentition	16 (52%)	2 (50%)	2 (100%)
bimaxillary			
Sucking open bite	1 (3%)	0 (0%)	0 (0%)
Protrusion of lower jaw (familial)	1 (3%)	0 (0%)	0 (0%)

Hard palate closure is mostly regarded as a mechanical closure (by suturing the nasal layers together) without an age-related function; however, it leads to growth impairment when performed in infancy.<sup>13,22</sup> However, in I(I)CP and SMCP, when disfiguring growth impairment is not expected, the Veau method with axial flaps, sufficient mobilization, and incorporation of the vomer could be used to establish the underlying normal physiology and anatomy, and avoid fistula formation and speech-related re-repairs. Considering the fact that children with ICPs are more prone to other associated malformations and worse speech results compared with children with cleft lip and palate, they could be treated in a more extensive manner to eliminate cleft-related speech problems. This also suggests that secondary procedures, such as velopharyngoplasties, should be avoided in patients with PRS to prevent postoperative respiratory problems.

Intravelar veloplasty with ideal anatomical construction of the inner nose throughout its extension may be a step forward to create the basis for normal resonance/voice development in children with ICP.

We believe that this method, once mastered by dedicated and competent surgeons, can be a breakthrough, which can be used to overcome the challenges of wide cleft palate repair and provide successful treatments.

**Carsten Matuschek, MSc, PhD**

Department of Oral and Maxillofacial Surgery  
Cleft Lip and Palate Center  
Charité Universitätsmedizin Berlin  
Augustenburger Platz 1  
D 13353 Berlin  
Germany

E-mail: carsten.matuschek@charite.de

#### ACKNOWLEDGMENT

The authors thank Nanette Sarioglu and Alexander Voigt for the illustrations, and Franz Hafner for intraoperative photography.

#### REFERENCES

1. Koch H, Grzonka M, Koch J. [The primary treatment of velar, palatal and vomer malformations as a prerequisite for normal speech development]. *Fortschr Kieferorthop*. 1994;55:152–156.

2. Kriens OB. An anatomical approach to veloplasty. *Plast Reconstr Surg*. 1969;43:29–41.
3. Sommerlad BC. A technique for cleft palate repair. *Plast Reconstr Surg*. 2003;112:1542–1548.
4. Furlow LT Jr. Cleft palate repair by double opposing Z-plasty. *Plast Reconstr Surg*. 1986;78:724–738.
5. Hansen L, Nolting D, Holm G, et al. Abnormal vomer development in human fetuses with isolated cleft palate. *Cleft Palate Craniofac J*. 2004;41:470–473.
6. Grzonka MA, Koch KH, Koch J, et al. Malformation of the vomer in submucous cleft palate. *J Craniomaxillofac Surg*. 2001;29:106–110.
7. Tse RW, Siebold B. Cleft palate repair: Description of an approach, its evolution, and analysis of postoperative fistulas. *Plast Reconstr Surg*. 2018;141:1201–1214.
8. Schmidt G, Hirschfelder A, Heiland M, et al. Customized pre-epiglottic baton plate-A practical guide for successful, patient-specific, noninvasive treatment of neonates with robin sequence. *Cleft Palate Craniofac J*. 2021;58:1063–1069.
9. Andersson EM, Sandvik L, Semb G, et al. Palatal fistulas after primary repair of clefts of the secondary palate. *Scand J Plast Reconstr Surg Hand Surg*. 2008;42:296–299.
10. Phua YS, de Chalain T. Incidence of oronasal fistulae and velopharyngeal insufficiency after cleft palate repair: An audit of 211 children born between 1990 and 2004. *Cleft Palate Craniofac J*. 2008;45:172–178.
11. Hardwicke JT, Landini G, Richard BM. Fistula incidence after primary cleft palate repair: A systematic review of the literature. *Plast Reconstr Surg*. 2014;134:618e–627e.
12. Yun IS, Lee JH, Park BY. Vomopalatoplasty: A novel procedure to reduce velopharyngeal distance in cleft palate repair. *J Craniofac Surg*. 2010;21:526–528.
13. Elander A, Persson C, Lilja J, et al. Isolated cleft palate requires different surgical protocols depending on cleft type. *J Plast Surg Hand Surg*. 2017;51:228–234.
14. Calis M, Ekin O, Kayikci ME, et al. Does contribution of extended vomer flap to palatoplasty affects speech results. *J Craniofac Surg*. 2014;25:1980–1984.
15. Park S, Saso Y, Ito O, et al. A retrospective study of speech development in patients with submucous cleft palate treated by four operations. *Scand J Plast Reconstr Surg Hand Surg*. 2000;34:131–136.
16. Timmons MJ, Wyatt RA, Murphy T. Speech after repair of isolated cleft palate and cleft lip and palate. *Br J Plast Surg*. 2001;54:377–384.
17. Odom EB, Woo AS, Mendonca DA, et al. Long-term incisal relationships after palatoplasty in patients with isolated cleft palate. *J Craniofac Surg*. 2016;27:867–870.
18. Azouz V, Ng M, Patel N, et al. Low incidence of maxillary hypoplasia in isolated cleft palate. *Maxillofac Plast Reconstr Surg*. 2020;42:8.
19. Freng A. Growth of the middle face in experimental early bony fusion of the vomeropremaxillary, vomeromaxillary and mid-palatal sutural system. A roentgencephalometric study in the domestic cat. *Scand J Plast Reconstr Surg*. 1981;15:117–125.
20. Good PM, Mulliken JB, Padwa BL. Frequency of Le Fort I osteotomy after repaired cleft lip and palate or cleft palate. *Cleft Palate Craniofac J*. 2007;44:396–401.
21. Heliövaara A, Rautio J, Nyström M. Dental arches in submucous cleft palate: Comparison of six-year-old boys with unoperated submucous cleft palate, with operated cleft of the soft palate, and without a cleft. *Acta Odontol Scand*. 2007;65:231–235.
22. Friede H. Maxillary growth controversies after two-stage palatal repair with delayed hard palate closure in unilateral cleft lip and palate patients: Perspectives from literature and personal experience. *Cleft Palate Craniofac J*. 2007;44:129–136.