



First recorded outbreak of *Veronaea botryosa* in North American amphibians: Clinicopathologic features of a rare cause of phaeohyphomycosis in captive White's tree frogs (*Litoria caerulea*)

Treana Mayer^{a,*}, Alexandra E. Moskaluk^a, Jonathan E. Kolby^b, Michael Russell^a, Paula Schaffer^a, Anna C. Fagre^a

^a Colorado State University, College of Veterinary Medicine & Biomedical Science, Fort Collins, CO, USA

^b James Cook University, College of Public Health, Medical and Veterinary Sciences, Townsville, Australia

ARTICLE INFO

Keywords:

Phaeohyphomycosis
Amphibian
Emerging fungal disease
Zoonotic
Veronaea

ABSTRACT

We describe fatal phaeohyphomycosis due to *Veronaea botryosa* in captive White's tree frogs (*Litoria caerulea*), the first confirmed report in amphibians in North America. Over 15 months, six frogs developed ulcerative dermatitis on distal extremities/ventrum, which in one animal progressed to vasculitis and necrotizing osteomyelitis. All six frogs died. Clinicopathologic findings, diagnostic challenges, and control are discussed. Emerging fungi such as *V. botryosa* pose serious concerns for zoonosis and potential spread through the pet trade.

1. Introduction

Climate change and emerging infectious diseases have resulted in significant global amphibian population declines. The emerging fungal pathogen *Batrachochytrium dendrobatidis* is a well-studied example [1], though lesser-known fungal pathogens can also cause fatal disease outbreaks in amphibians. *Veronaea botryosa* is an emerging opportunistic fungus responsible for phaeohyphomycosis and/or chromomycosis in humans. Human cases manifest as cutaneous, subcutaneous, and submucosal infections, with disease sometimes progressing to fatal systemic dissemination in immunocompromised patients. The pathogen has been detected in at least 14 human cases worldwide, with source of exposure seldom determined [2–5]. The World Health Organization declared chromomycosis a neglected tropical disease in 2017 due to its disproportionate impact on vulnerable populations [6].

V. botryosa is also a significant pathogen for cold-blooded vertebrates. Detected in environmental or animal samples on all continents except Antarctica, it is also an economically significant pathogen for the aquaculture industry (affecting reared sturgeon (*Acipiter* spp.)) [7–9]. The route of infection is unknown, but environmental exposure through transcutaneous inoculation or ingestion are suspected [10].

This is the first confirmed report of *V. botryosa* in amphibians in North America, and the second report of this pathogen causing a fatal disease outbreak in captive frogs (including White's tree frogs) [9].

Infection was associated with high morbidity (67%, 6/9 cohabiting frogs) and mortality (100%, 6/6 clinically affected White's tree frogs). We provide suggestions for the investigation and diagnostic work-up of similar presentations in captive amphibians.

1.1. Case presentation

Affected frogs resided in a small facility that rehomed pet amphibians and reptiles in Texas, USA. The facility has cared for up to 27 animals at a time. All confirmed and presumptive cases were White's tree frogs cohoused together in a 100-gallon tank that had previously housed freshwater fish (species undetermined) with no direct exposure to other amphibian species. Over 11 months, 6 of 9 cohabiting White's tree frogs presented with multifocal to coalescing cutaneous pigmentation, hyperemia, swelling, and ulceration of one or more digits, the extremities, and/or ventrum, progressed with extensive necrohemorrhagic crusts (Fig. 1). Time course from onset to death ranged from a few days to 8.5 months (Fig. 2). The reported husbandry conditions (e.g. UVB light, humidity, temperature, diet, and substrate (Josh's Frogs Frog Foam Terrarium Liner, Owasso MI) were considered appropriate for this species [11]. All frogs were described as healthy upon introduction to this tank. The ages of affected frogs ranged from 6 months to 3 years (avg 14 mo), with 2 males and 4 females.

The first case presented with multifocal well-demarcated cutaneous

* Corresponding author.

E-mail address: Treana.Mayer@colostate.edu (T. Mayer).

<https://doi.org/10.1016/j.mmcr.2022.09.002>

Received 3 August 2022; Received in revised form 9 September 2022; Accepted 10 September 2022

Available online 23 September 2022

2211-7539/© 2022 The Authors. Published by Elsevier B.V. on behalf of International Society for Human and Animal Mycology. This is an open access article under the CC BY-NC-ND license (<http://creativecommons.org/licenses/by-nc-nd/4.0/>).

ulcerations of the left hind limb that progressed to flexor tendon exposure (Fig. 1C). Cases 2 and 3 developed similar cutaneous lesions concurrently and were placed in quarantine within one week of initial clinical signs. Over-the-counter triple antibiotic ointment and saline baths yielded no improvement, prompting veterinary attention.

Limb necrosis in cases 1–3 progressed, and all were treated empirically for a presumptive bacterial infection beginning day +11 (enrofloxacin 0.1mL of 2.27mg/mL solution q24 hours for 14 days; injectable amikacin 2.5mg/mL, 0.05mL subcutaneously q24 hours for 30 days; topical silver sulfadiazine cream q24 hours). Cases 2 and 3 died on days +16 and +39, respectively. Hindlimb amputation was performed on Case 1 on day +46, with a 25% reduction in body weight noted prior to surgery. Impression smear cytology of affected tissue post-operatively revealed hyphae and leukocytes; thus, topical antifungal therapy was initiated on day +47 (0.01% itraconazole in 0.6% sterile saline, 5 minutes q24 hours for 11 days) in addition to disinfection of the tank with 10% bleach (sodium hypochlorite) with all terrarium items discarded. Case 1 died on day +48.

Case 4 developed lesions on day +78 and died soon after (no diagnostics or therapeutics pursued). At day +210, Case 5 (initially

housed with Cases 1–4) presented with skin lesions on one foot and was then isolated from other frogs (Fig. 2A). Enhanced biosecurity and hygiene measures were subsequently implemented. No therapy was elected, and Case 5 died on day +465 in isolation.

Case 6 developed similar skin lesions on day +240 after being introduced to the tank housing three healthy White's tree frogs that had previously cohabited with Cases 1–4 (in the same tank that had previously housed Cases 1–5). Topical application of enrofloxacin and itraconazole (previously described) was immediately initiated but treatment was unsuccessful, and Case 6 died on day +300.

Case 6 was received by the Colorado State University Veterinary Diagnostic Laboratory for postmortem evaluation. One unfixed limb had been stored at 4°C for 13 days in a sterile blood collection tube prior to submission. The rest of the frog had been immersion-fixed in 10% neutral buffered formalin within 48 hours of death.

1.1.1. Gross findings

The formalin-fixed carcass was emaciated. Both mani and the single fixed pes were markedly swollen and red-to-black. Thick necrohemorrhagic exudates obscured digital detail. There were multiple variably

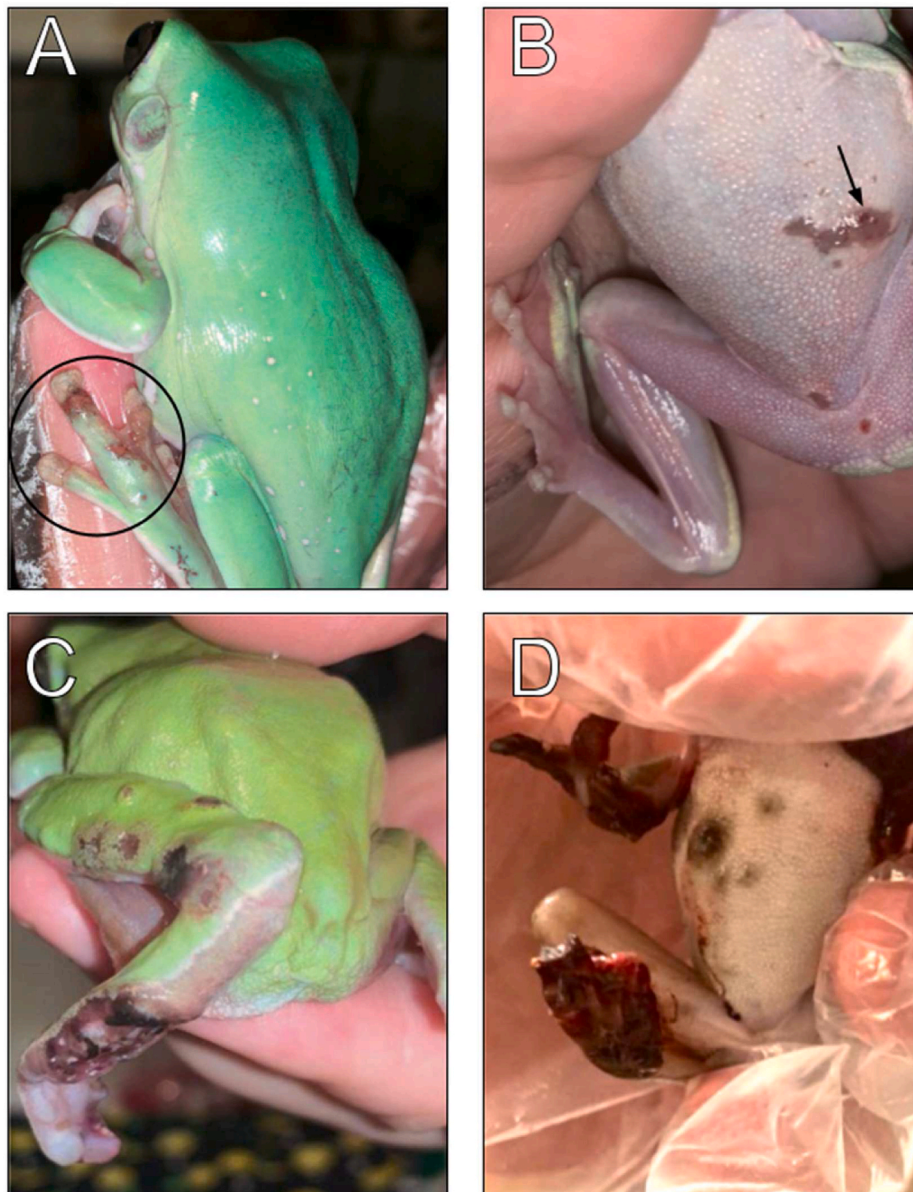

Fig. 1. (A-D). Gross findings in White's tree frogs suffering from phaeohiphomycosis associated with *V. botryosa*. Gross findings from presumptive (A, B) and confirmed (C, D) cases of phaeohiphomycosis caused by *V. botryosa* in affected White's tree frogs (*L. ceruleae*). A.) Multifocal ulcerative dermatitis of the pes (Case 5) (circle). B.) Well-demarcated ulceration of the ventrum (Case 5) (arrow). C.) Multifocal ulcerative dermatitis with deep necrosis and exposure of flexor tendons (Case 1, prior to amputation). D.) Extensive hemorrhagic necrosis of multiple distal extremities and ulcers on the ventral abdomen (Case 6, deceased).

well-demarcated dark brown-to-black flat-to-minimally raised plaques on the ventral abdomen.

1.1.2. Histopathology

Representative samples of formalin-fixed tissues from all organ systems were trimmed and routinely processed to produce hematoxylin and eosin-stained slides. Lesions were confined to the limbs and skin of the ventral abdomen. Extremely high numbers of fungal hyphae pervaded the soft tissues of the distal limbs. Hyphae were 3–4 µm in diameter and brown-pigmented with parallel walls and consistent septations (Fig. 3A). Fungal hyphae infiltrated the walls of blood vessels, which were smudged and hypereosinophilic (fibrinoid degeneration) and stippled with karyorrhectic debris (leukocytoclastic vasculitis). Some vessels were occluded by fibrin thrombi. Fungal hyphae surrounded bone and infiltrated into medullary cavities. Multiple digits were affected by osteonecrosis of one or more phalanges. Necrotic bone and articular cartilages were hypereosinophilic with loss of osteocytes and chondrocytes in lacunar spaces (Fig. 3B). Ulcerated skin surfaces were heavily colonized by mixed bacteria.

1.1.3. Microbiology

A post-mortem impression smear of the unfixed leg of Case 6 revealed mixed bacteria using Gram stain. No acid-fast bacilli or hyphae were observed with Ziehl-Neelsen stain. Tissue homogenate from the unfixed affected limb was plated on trypticase soy agar supplemented with 5% sheep blood (Becton Dickenson, Franklin Lakes, NJ), Columbia agar with 5% sheep blood (Becton Dickenson, Franklin Lakes, NJ), and MacConkey II agar (Becton Dickenson, Franklin Lakes, NJ). The TSA and MacConkey plates were incubated for 36–48 h at 37 °C under ambient conditions. Two Columbia agar plates were inoculated, with one incubated for 36–48 h at 37 °C with 10% CO₂ and the second incubated at room temperature (20–25 °C) under ambient conditions for 7 days. Tissue homogenate was also plated on CDC Anaerobe agar with 5% sheep blood (Becton Dickenson, Franklin Lakes, NJ) and incubated for 7 days at 37°C under anaerobic conditions.

Bacterial cultures yielded heavy mixed growth with no predominant species, consistent with surface contamination and/or postmortem overgrowth. Isolates included species in the genera *Morganella* sp., *Enterococcus* sp., *Citrobacter* sp., *Microbacterium* sp. and *Pseudomonas* sp. as determined by MALDI-TOF (Bruker, Billerica MA). No obligate anaerobic bacteria were detected.

Tissue homogenate was also inoculated on Sabouraud dextrose agar (Becton Dickenson, Franklin Lakes, NJ) and inhibitory mold agar containing chloramphenicol (Becton Dickenson, Franklin Lakes, NJ). The plates were incubated at room temperature (20–25 °C) under ambient conditions for 30 days. Heavy bacterial contamination was noted on both plates after 3 days of incubation. No hyphal growth was observed after 30 days of incubation.

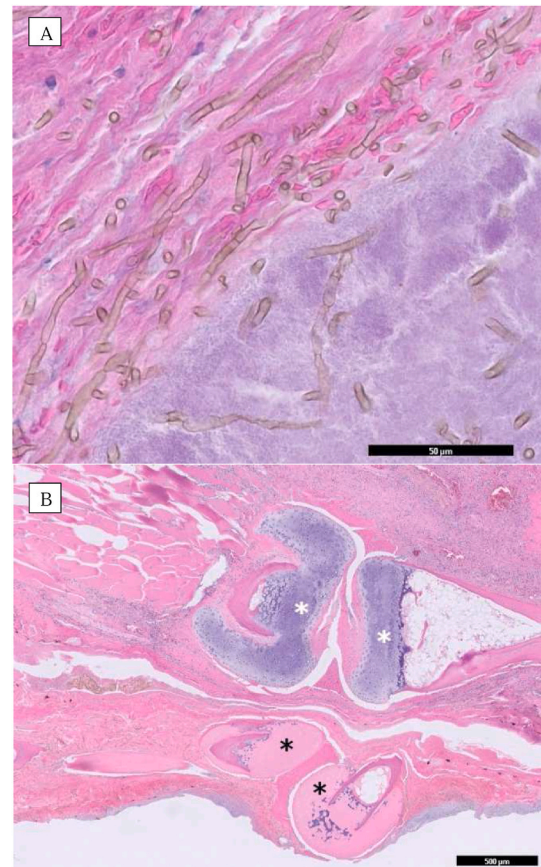


Fig. 3. Pathology associated with fungal invasion of soft tissue and bone of phalanges in affected White's tree frog (Case 5). A.) Pictured on top panel, fungal hyphae (3–4 µm in diameter) present in the soft tissues of hindlimb, featuring brown pigmentation, parallel walls, and frequent septations. Hyphae are associated with florid bacterial overgrowth at the ulcerated skin surface, which may partly represent postmortem overgrowth (right lower corner). B.) Featured in bottom panel are two phalanges (black asterisks) with coagulative necrosis. The bone and articular cartilages are hypereosinophilic. The distal phalanx (right black asterisk) is also dislocated. The phalanges of the neighboring digit (white asterisks) are viable with basophilic articular cartilages. Soft tissues are hypercellular due to inflammation and brown fungal hyphae are present throughout the soft tissues. (For interpretation of the references to colour in this figure legend, the reader is referred to the Web version of this article.)

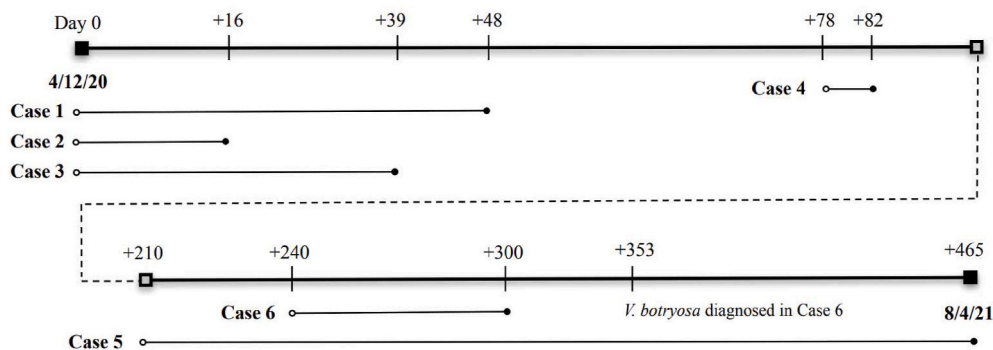


Fig. 2. Timeline of clinical disease course in presumptive and confirmed cases of captive White's tree frogs affected by *V. botryosa*. Six cases of phaeohyphomycosis documented in White's tree frogs (*L. cerulea*) throughout the course of the outbreak. For each case, reported onset of clinical signs (open circle) and reported death (closed circle) are noted. Dashed line represents a 5-month period without reported cases or deaths.

1.1.4. Molecular diagnostics

DNA was extracted from affected hindlimb tissue (Case 6) using a previously published method for fungi in tissue samples [12]. Conventional PCR of the internal transcriber spacer (ITS) region (ITS1-5.8-S-ITS2) was performed using primers ITS5F (5'-GGAAGTAAAAGTCGTAACAAGG) and ITS4R (5'-TCCTCCGCTTATTGATATGC) for an expected amplicon between 576 and 601bp [13]. The product was purified using ExoSAP-IT kit (Applied Biosystems) and Sanger sequenced (Psomagen). Sequences were trimmed for quality and converted into a 549bp consensus sequence (GenBank accession number OK526382) that was compared to sequences in NCBI's BLAST. The consensus sequence had 100% alignment with 16 sequences of the *V. botryosa* ITS region (GenBank accession numbers MH86213.1, MH863891.1, MH167396.1, MH010967.1, and AB906334.1).

Antemortem skin swabs from Case 5 and three unaffected cohabiting frogs were collected from the ventrum and feet using a chytridiomycosis surveillance sampling protocol [14]. Swabs were placed in sterile saline and shipped overnight to the Colorado State University Veterinary Diagnostic Laboratory. There was no detection of *V. botryosa* or any other primary fungal pathogen, including *B. dendrobatidis*, by culture or fungal ITS PCR.

Unfortunately, White's tree frog cases were unavailable or no longer in suitable post-mortem condition for ranavirus testing. Thus, opportunistic ranavirus testing was conducted on fresh liver and spleen collected from a Gulf Coast toad (*Inciilius valliceps*) who died suddenly at this facility (cause of death unknown) on day +426. Despite lack of direct contact between this toad and affected White's tree frogs, ranaviruses are environmentally persistent and other species in family *Bufo* are susceptible [15]. Fresh liver and spleen were pooled and homogenized prior to DNA extraction and qPCR testing using previously-described methods at Pisces Molecular Laboratory (Boulder, CO, USA) [16]. No ranavirus nucleic acid was detected.

1.2. Discussion

This is the first confirmed report of *V. botryosa* causing phaeohyphomycosis in a captive amphibian population in North America. Six of nine co-housed White's tree frogs experienced severe multifocal to regionally extensive ulcerative dermatitis on the feet and ventrum. Only one White's tree frog (Case 6) was available for postmortem evaluation from this outbreak, and findings included severe necrotizing fungal dermatitis with vasculitis, osteomyelitis, and necrosis of the distal limbs. Granulomas and visceral lesions were not observed in this case. Hosoya et al., by contrast, described granulomatous cutaneous disease with disseminated visceral and central nervous system granulomas in eastern-Japanese common toads (*Bufo japonicus formosus*) and false tomato frogs (*Dyscophus guineti*) [9]. Visceral disease cannot be ruled out for other suspected cases from this outbreak that were unavailable for postmortem evaluation, but susceptibility may vary by species. Together, clinical features and histopathology ruled out other important amphibian pathogens such as *Aeromonas* spp., *Mycobacterium* spp., *Chlamydomphila* spp., and *Batrachochytrium dendrobatidis* in Case 6; further, ranavirus was ruled out in a toad from the same facility. Gross and histopathologic review of future cases would further our understanding of *V. botryosa* pathogenesis in different amphibian species, and possibly elucidate risk factors for severe infection.

The pathology and temporal course of this outbreak may suggest environmental persistence and cutaneous introduction. The aquarium shared by all affected frogs may have been a common source of exposure, resulting in this focal and contained outbreak. It is unclear if the fish previously housed in this tank may have contributed to the outbreak, as *V. botryosa* is a known aquaculture pathogen [7]. The aquarium was disinfected after removal of the fish, though many antibacterial disinfectants may not have fungicidal activity. Pathogen introduction by subclinical frogs is also possible, particularly in a shelter setting with unknown animal histories. However, cutaneous swabs from

three unaffected frogs that cohabited with earlier clinical cases were negative for *V. botryosa* by culture and PCR. It is worth noting that this sample type may lack sensitivity when fungal shedding is low [17].

Antemortem diagnostics proved challenging, with delayed diagnosis likely contributing to disease progression and further transmission. In this outbreak, cytology served as a valuable clinical screening tool for severe ulcerative fungal dermatitis in amphibians. Histopathology is diagnostic for phaeohyphomycosis, but antemortem biopsy sampling is often limited by the size and delicacy of amphibian patients. Superficial swabbing of ulcerative lesions or autolyzed tissue for fungal culture is not recommended as a sole diagnostic tool due to high likelihood of bacterial overgrowth. The inadvertent 13-day period between death and unfixed sample processing limited diagnostic work-up owing to autolysis and postmortem bacterial overgrowth. Despite this, molecular diagnostics and histopathology of tissues allowed identification of this fungal pathogen. For deceased patients, we recommend submission of fresh tissue (affected organs or extremities) within 24 hours of death. Alternatively, storage in 10% neutral-buffered formalin allows for histopathologic examination if prompt submission of fresh tissues is not possible. For antemortem testing, surgical excision of affected tissue for fungal culture is optimal. Pending culture and/or histological findings, speciation by fungal PCR and confirmatory sequencing are likely warranted.

Medical intervention attempted in 4 of the 6 presumptive or confirmed cases was unrewarding, including topical and parenteral antibiotics, topical itraconazole, and amputation of an affected limb, with 100% mortality in clinical cases. *V. botryosa* infections previously described in eastern-Japanese common toads and false tomato frogs were unresponsive to oral itraconazole and resulted in similarly high mortality [9]. Unfortunately, antifungal treatment options for frogs are limited, with high rates of itraconazole-associated mortality reported in amphibians [14]. Studies of additional antifungals for efficacy and safety could be valuable to improve clinical outcomes and amphibian welfare.

While all suspected cases were described as presumptively healthy prior to illness, we could not rule out the contribution of underlying health conditions or immunosuppression to disease susceptibility. Since White's tree frog cases were unavailable for ranavirus testing, we collected fresh liver and spleen from a toad who died at the same facility during the outbreak. While this suggests there may not be widespread ranavirus in this facility, its presence cannot be fully ruled out based on limited testing. While histologic features of ranavirus (multisystemic necrosis with intracytoplasmic inclusion bodies) were not detected in Case 6, subclinical carriage is possible. Additionally, this outbreak began during the peak of animal intakes for this facility, and the stress of high animal density and change in habitat could have contributed to disease susceptibility [18].

The zoonotic potential of this fungal pathogen highlights the importance of investigating unspicied fungal pathogens, such as *V. botryosa*. Once identified, biosecurity practices including personal protective equipment and frequent disinfection should be prioritized to safeguard human and animal health. Care should be taken for individuals in contact with infected animals, especially the young, old, pregnant, or immunocompromised. The prognosis for phaeohyphomycosis in amphibians is considered grave to poor [10]. Prevention should focus on disinfection of housing and enrichment items, quarantining new and unhealthy animals, and when possible, reducing sources of stress—such as animal density, nutrition, and environmental conditions.

V. botryosa is an emerging fungal pathogen, and a causative agent of phaeohyphomycosis which can result in fatal infections. *V. botryosa* has resulted in morbidity and mortality in humans and many animal species worldwide, including this first report of confirmed infection in captive amphibians in North America. Ulcerative necrohemorrhagic and pigmented pododermatitis and ventral dermatitis were characteristic gross lesions distinct from other commonly encountered frog diseases, and this clinical syndrome should prompt consideration of emergent

pigmented fungal pathogens such as *V. botryosa*. Cytology may be an appropriate antemortem screening test, and fresh tissue sampling (rather than superficial swabs) for culture is recommended. Considering the zoonotic potential of this pathogen, our findings underscore the importance of considering seldom-described fungal etiologies as causative agents for outbreaks in captive amphibian facilities and the value of molecular approaches for confirmatory diagnosis of difficult to culture organisms. Environmental persistence is likely, and movement by fomites and/or asymptomatic carries may cause problems for other captive populations, in addition to wild native amphibians, if exposed to infected animals or contaminated materials. Future research should focus on virulence factors, host range, ecology, and novel treatment options for *V. botryosa* in amphibians.

Declaration of competing interest

There are none. The Veterinary Diagnostic Laboratory with which authors TM, MR and PS are affiliated does not offer some of the described tests to the public and will not directly benefit from this study.

Acknowledgements

The authors acknowledge L. Leduc, K. Page and T. Peppard for bacteriologic and mycologic technical support; T. Shoemaker for clinical histories, sample submission, and care for these frogs; Dr. M Johnston for clinical guidance; and Dr. J Daniels for diagnostic advice. Drs. AC Fagre and A Moskaluk were supported on T32 NIH-9-T32 OD0-10437-18 and Dr. T Mayer was supported by the Colorado State University, Department of Microbiology, Immunology & Pathology and Veterinary Diagnostic Laboratory.

References

- [1] J.E. Kolby, P. Daszak, The emerging Amphibian fungal disease, chytridiomycosis: a key example of the global Phenomenon of wildlife emerging infectious diseases, *Microbiol. Spectr.* 4 (2016), <https://doi.org/10.1128/microbiolspec.EI10-0004-2015>, 4.3.11.
- [2] A. Welfringer, V. Vuong, N. Argy, C. Chochillon, L. Descamps, G. Rollin, S. Harent, V. Joly, W. Vindrios, V. Descamps, A rare fungal infection: Phaeohyphomycosis due to *Veronaea botryosa* and review of literature, *Med. Mycol. Case Rep.* 15 (2017) 21–24.
- [3] C.-Y. Zhu, Y.-P. Yang, P. Sheng, W. Li, W.-M. Huang, Y.-M. Fan, Cutaneous chromoblastomycosis caused by *Veronaea botryosa* in a patient with pemphigus vulgaris and review of published reports, *Mycopathologia* 180 (2015) 123–129.
- [4] S. Davoudi, N. Shah, G. Khurshid, A. Shah, Ocular phaeohyphomycosis caused by *Veronaea botryosa*: a novel fungal infection in human beings, *Cornea* (2020), <https://doi.org/10.1097/ICO.0000000000002478>.
- [5] A. Bonifaz, M. Mohammad Davoudi, G.S. De Hoog, C. Padilla-Desgarennes, D. Vázquez-González, G. Navarrete, J.F. Meis, H. Badali, Severe disseminated phaeohyphomycosis in an immunocompetent patient caused by *Veronaea botryosa*, *Mycopathologia* 175 (2013) 497–503.
- [6] L.F.D. Passero, I.N. Cavallone, W. Belda, Reviewing the etiologic agents, microbe-host relationship, immune response, diagnosis, and treatment in chromoblastomycosis, *J. Immunol. Res.* 2021 (2021), e9742832, <https://doi.org/10.1155/2021/9742832>.
- [7] J.M. Groff, M.Y. Mok, S.V. Kubiski, A.O. Michel, G.A. Cortés-Hinojosa, B.A. Byrne, B.L. Wickes, E. Scott Weber III, L.A. Campbell, T.B. Waltzek, Phaeohyphomycosis due to *Veronaea botryosa* in cultured white sturgeon (*Acipenser transmontanus* Richardson) from California USA during 2006 to 2015, *J. Fish. Dis.* 44 (2021) 793–801, <https://doi.org/10.1111/jfd.13308>.
- [8] K. Donnelly, T.B. Waltzek, J.F.X.W. Jr, D.A. Sutton, N.P. Wiederhold, B.A. Stacy, Phaeohyphomycosis resulting in obstructive tracheitis in three green sea turtles *Chelonia mydas* stranded along the Florida coast, *Dis. Aquat. Org.* 113 (2015) 257–262, <https://doi.org/10.3354/dao02843>.
- [9] T. Hosoya, Y. Hanafusa, T. Kudo, K. Tamukai, Y. Une, First report of *Veronaea botryosa* as a causal agent of chromomycosis in frogs, *Med. Mycol.* 53 (2015) 369–377, <https://doi.org/10.1093/mmy/myu094>.
- [10] R.E. Schmidt, Amphibian Chromomycosis, in: G.L. Hoff, F.L. Frye, E.R. Jacobson (Eds.), *Diseases of Amphibians and Reptiles*, Springer US, Boston, MA, 1984, pp. 169–181, https://doi.org/10.1007/978-1-4615-9391-1_13.
- [11] T.A. Bradley, K. Wright, Captive care and breeding of White's tree frog, *Pelodryas caerulea*, *J. Herpetol. Med. Surg.* 10 (2000) 21–25.
- [12] A. Brillowska-Dabrowska, D.M. Saunte, M.C. Arendrup, DNA Preparation from Nail Samples, 2006. Denmark Patent WO2006133701.
- [13] T.J. White, T. Bruns, S. Lee, J. Taylor, Amplification and direct sequencing of fungal ribosomal RNA genes for phylogenetics, *PCR Protocols: A Guide to Methods and Applications* 18 (1990) 315–322.
- [14] L.A. Brannelly, Reduced itraconazole concentration and durations are successful in treating *Batrachochytrium dendrobatidis* infection in amphibians, *JoVE* (2014), e51166.
- [15] D.A. Patla, S. St-Hilaire, A. Ray, B.R. Hossack, C.R. Peterson, Amphibian mortality events and ranavirus outbreaks in the Greater Yellowstone Ecosystem, *Herpetol. Rev.* 47 (2016) 50–54.
- [16] M.C. Allender, D. Bunick, M.A. Mitchell, Development and validation of TaqMan quantitative PCR for detection of frog virus 3-like virus in eastern box turtles (*Terrapene carolina carolina*), *J. Virol Methods* 188 (2013) 121–125.
- [17] J. Shin, A. Bataille, T.A. Kosch, B. Waldman, Swabbing often fails to detect amphibian chytridiomycosis under conditions of low infection load, *PLoS One* 9 (2014), e111091.
- [18] S. Seyedmousavi, J. Guillot, G.S. De Hoog, Phaeohyphomycoses, emerging opportunistic diseases in animals, *Clin. Microbiol. Rev.* 26 (2013) 19–35.