

Case Report

A pediatric case of pheochromocytoma without apparent hypertension associated with von Hippel-Lindau disease

Junko Igaki^{1,2}, Akira Nishi³, Takeshi Sato⁴, and Tomonobu Hasegawa⁴

¹*Department of Pediatric Endocrinology and Metabolism, Okinawa Prefectural Nanbu Medical Center & Children's Medical Center, Okinawa, Japan*

²*Division of Endocrinology and Metabolism, Gunma Children's Medical Center, Gunma, Japan*

³*Division of Surgery, Gunma Children's Medical Center, Gunma, Japan*

⁴*Department of Pediatrics, Keio University School of Medicine, Tokyo, Japan*

Abstract. Pheochromocytomas are catecholamine-secreting tumors. These tumors are rare in children, and they may be associated with hereditary syndromes such as von Hippel-Lindau (VHL) disease. Most pediatric patients with pheochromocytoma present with sustained hypertension, while 10% to 69% of adult patients are asymptomatic. Herein, we present the case of a 12-yr-old Japanese girl with pheochromocytoma due to a germline mutation in the *VHL* (Arg161Gln). The only complaint was loss of weight. Pyrexia, anemia, and increases in C-reactive protein (CRP) and ferritin were observed. Abdominal ultrasonography revealed a right adrenal gland tumor. Fractionated catecholamines and metanephrines in plasma and 24-h collected urine revealed elevated levels of norepinephrine and normetanephrine. Although hypertension and tachycardia were inapparent by an ordinary physical examination, paroxysmal mild hypertension and tachycardia were identified by a thorough examination after walking and abdominal compression. Paroxysmal hypertension and tachycardia were profound during operation. In conclusion, pheochromocytoma can be a consideration in the differential diagnosis of weight loss. Hypertension and tachycardia can be inapparent and paroxysmal in pediatric patients as well as in adults; thus, thorough assessment should be repeated.

Key words: pheochromocytoma, VHL, asymptomatic, weight loss

Introduction

Received: September 13, 2017

Accepted: January 23, 2018

Corresponding author: Junko Igaki, Department of Pediatric Endocrinology and Metabolism, Okinawa Prefectural Nanbu Medical Center & Children's Medical Center, 118-1 Arakawa, Haebaru-cho, Okinawa 901-1193, Japan

E-mail: junko25sky@yahoo.co.jp

This is an open-access article distributed under the terms of the Creative Commons Attribution Non-Commercial No Derivatives (by-nc-nd) License <<http://creativecommons.org/licenses/by-nc-nd/4.0/>>.

Pheochromocytomas are catecholamine-secreting tumors that arise from chromaffin cells of the adrenal medulla. Symptoms are caused by tumoral hypersecretion of catecholamines. The classic triad of symptoms consists of episodic headaches, sweating, and tachycardia, usually accompanied by hypertension. Sustained tachycardia (6/6 cases (1), 16/30 cases (2)) and hypertension (6/6 cases (1), 10/14 cases (3), 19/30

cases (2)) are common among pediatric patients, although up to 10–69% (4–7) of adult patients are asymptomatic.

Pheochromocytomas are rare in children, and when discovered, they may be associated with hereditary syndromes, such as von Hippel–Lindau (VHL) disease, familial paraganglioma, and multiple endocrine neoplasia type 2A. (8). Germline mutations in 17 genes have been identified to be responsible for genetic pheochromocytomas: *VHL*, multiple endocrine neoplasia type 2 (*RET*), multiple endocrine neoplasia type 1 (*MEN1*), neurofibromatosis type 1 (*NF1*), succinate dehydrogenase subunits A, B, C, and D (*SDHA/SDHB/SDHC/SDHD*), succinate dehydrogenase complex assembly factor 2 (*SDHAF2*), transmembrane protein 127 (*TMEM 127*), MYC-associated factor X (*MAX*), prolyl hydroxylase 1,2 (*PHD1/PHD2*), Harvey rat sarcoma viral oncogene (*H-RAS*), hypoxia-inducible factor 2 alpha (*HIF2A*), kinesin family member 1B (*KIF1B*), and fumarate hydratase (*FH*) (9).

VHL disease is an autosomal dominant disorder that may present with a variety of neoplasms: pheochromocytoma, hemangioblastoma (involving the cerebellum, spinal cord, or brainstem), retinal angioma, clear cell renal cell carcinoma, pancreatic neuroendocrine tumors and serous cystadenomas, endolymphatic sac tumors of the middle ear, and papillary cystadenomas of the epididymis and broad ligament. It is caused by germline mutations in *VHL*. Herein, we present a Japanese patient with pheochromocytoma due to a germline mutation in *VHL*. Although hypertension was inapparent at initial evaluation, thorough examination revealed paroxysmal hypertension.

Case Report

The patient was a 12-yr-old Japanese girl. She was referred to us because of a right adrenal tumor with anemia and elevated C-reactive protein (CRP) levels. Her main complaint

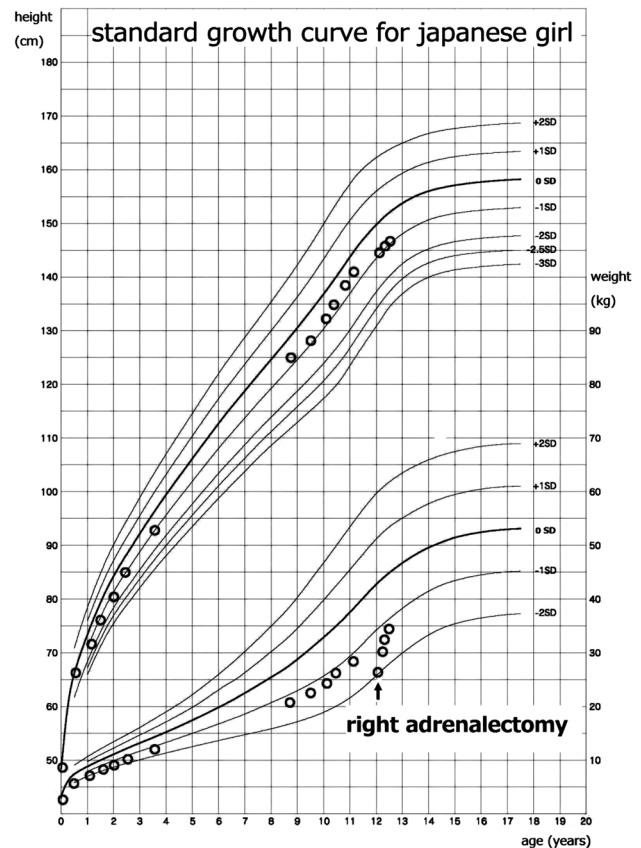


Fig. 1. Growth chart of the patient. The patient had lost weight for one year prior to admission and weighed 26.6 kg. Three months after right adrenalectomy, he regained weight and weighed 32.6 kg.

was that of weight loss (Fig. 1), and did not report of experiencing any other symptoms, including headaches and palpitation. However, she admitted to experiencing cold hands and feet, diaphoresis, dyspnea, and fatigue in the preoperative period, in retrospect. On physical examination, her height was 144.7 cm, weight was 26.6 kg, blood pressure was 123/88 mmHg (95th percentile blood pressure on the basis of age, sex, and height is 119/78 mmHg), and heart rate was 116 beats/min. Her body temperature was 37.0–38.5°C during the daytime. Hypertension was induced by both abdominal compression and food ingestion (blood pressure: 130–140/100–110 mmHg). Tachycardia was induced by

Table 1 Blood examination

WBC	5900 / μ L	TP	7.9 g/dL	Na	139 mEq/L
RBC	479×10^4 / μ L	Alb	3.2 g/dL	K	4.7 mEq/L
Hb	11 ^a g/dL	AST	22 U/L	Cl	103 mEq/L
Ht	35.1 %	ALT	13 U/L	Ca	9.7 mg/dL
MCV	73.3 ^a fL	LDH	202 U/L	IP	4.5 mg/dL
MCH	23 ^a pg	CPK	213 U/L	CRP	6 ^b mg/dL
MCHC	31.3 ^a %	ALP	440 U/L	Ferritin	457 ^b ng/mL
Plt	$54.9^b \times 10^4$ / μ L	ChE	263 U/L	BS	95 mg/dL
		BUN	6.5 mg/dL	Tchol	132 mg/dL
		Cr	0.38 mg/dL	TG	47 mg/dL
				HDL-C	38 ^a mg/dL

^a data below reference values. ^b data above reference values.

Table 2 Fractionated catecholamines and metanephrines in plasma and 24-h collected urine

	Preoperative	Reference value	Postoperative
Fractionated catecholamines in plasma			
Adrenaline	52	≤ 100 pg/mL	
Noradrenaline	4482	100–450 pg/mL	
Dopamine	19	≤ 20 pg/mL	
Fractionated catecholamines in 24-h collected urine			
Adrenaline	16.6–30.6	3.0–41.0 μ g/day	6.4
Noradrenaline	933.1–1002.6	31.0–160.0 μ g/day	75.4
Dopamine	649.6–1098.2	280.0–1100.0 μ g/day	492.1
Fractionated metanephrines in 24-h collected urine			
Metanephrine	0.15–0.21	0.04–0.18 mg/day	0.04
Normetanephrine	7.18–8.91	0.10–0.28 mg/day	0.18

light-intensity walking (heart rate: 140–160 beats/min). However, both hypertension and tachycardia subsided in a few minutes.

A blood examination revealed anemia (hemoglobin (Hb): 11.0 g/dL), elevated CRP levels (6 mg/dL), and elevated ferritin levels (457 ng/mL) (Table 1). Fractionated catecholamines and metanephrines in plasma and 24-hour collected urine revealed elevated levels of noradrenaline and normetanephrine, as follows: plasma noradrenaline, 4482 pg/mL; urinary noradrenaline, 933.1–1002.6 μ g/d; and urinary normetanephrine, 7.18–8.91 mg/d (Table 2).

Abdominal imaging studies showed that the right adrenal gland tumor was 6.0 cm in diameter (Fig. 2(a), (b)). T2-weighted magnetic

resonance imaging (MRI) showed a well-circumscribed mass that exhibited heterogeneous signal intensity. The mean apparent diffusion coefficient (ADC) of the mass was 1.75, which was higher than that of malignant tumors (Fig. 2(a)). ¹²⁵I-metaiodobenzylguanidine (MIBG) accumulated in the mass on scintigraphy (Fig. 2(b)). She was diagnosed with pheochromocytoma based on these data.

Infusion of saline was initiated five days before surgery to prevent postoperative circulatory failure. Blood pressure was slightly increased to 120–140/85–100 mmHg, and heart rate was slightly decreased to 90–100 beats/min. Right adrenalectomy was performed on the day following the initiation of α -adrenergic blockade

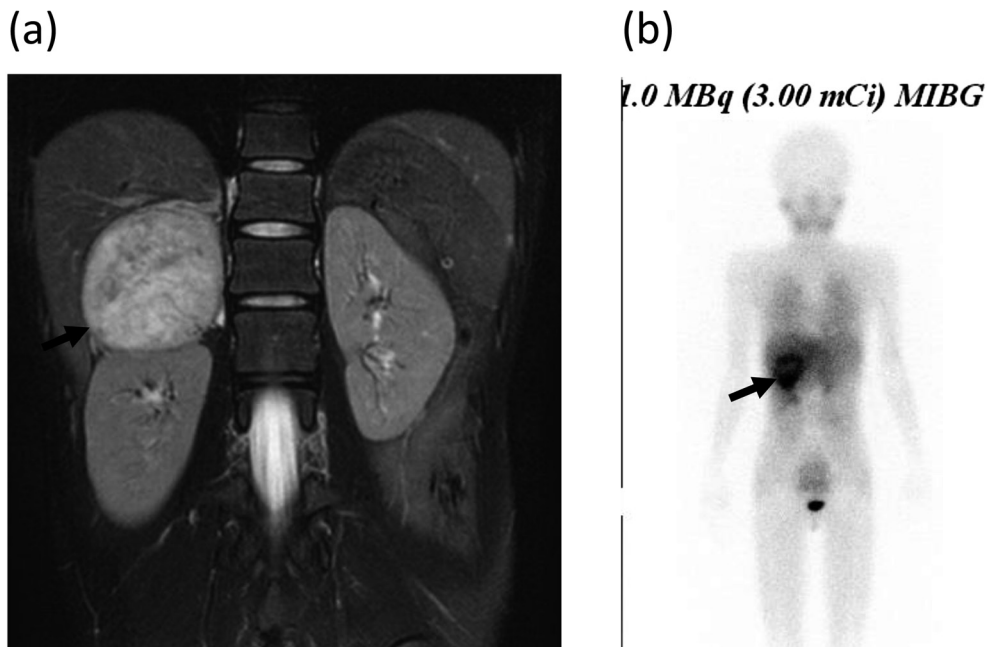


Fig. 2. Abdominal magnetic resonance imaging (MRI) and ^{121}I -metaiodobenzylguanidine (MIBG) scintigraphy. (a) Abdominal MRI: T2-weighted MRI showed a well-circumscribed mass with heterogeneous signal intensity (arrow). (b) ^{121}I -MIBG scintigraphy: ^{121}I -MIBG accumulated in the mass (arrow).

(phentolamine mesylate) therapy at a dose of 1 $\mu\text{g}/\text{kg}/\text{min}$. Although α -adrenergic blockade (2–5 $\mu\text{g}/\text{kg}/\text{min}$) and β -adrenergic blockade (lindolol hydrochloride: 5 $\mu\text{g}/\text{kg}/\text{min}$) were administered by intravenous infusion continuously during the operation, blood pressure and heart rate fluctuated abruptly from 60/40 to 170/110 mmHg and 110 to 160 beats/min, respectively, when the tumor was manipulated directly. Hypertension and tachycardia were managed with bolus doses of α - and β -adrenergic blockades. Immediately after resection of the tumor, blood pressure decreased to 60/40 mmHg. α -adrenergic blockade administration was discontinued and dopamine hydrochloride, β -agonist (ephedrine hydrochloride), and albumin administration were initiated. All medications could be discontinued before recovery from anesthesia. Dopamine hydrochloride was administered from 6 to 16 h after the surgery because of hypotension, and intravenous glucose administration was required until eight days after the surgery because of hypoglycemia before breakfast.

Her body temperature was 36.0°C, blood pressure was 90/50 mmHg, and heart rate was 80 beats/min on the 16th day after surgery. Fractionated catecholamines and metanephrines in 24-h collected urine fell into the normal range on the 40th day after surgery (Table 1). She gained her weight back to 32.6 kg 3 mo after surgery (Fig. 1).

The resected tumor was 7 × 4.5 × 4 cm in size and weighed 91 g. Histological examination of the resected tumor confirmed the diagnosis of pheochromocytoma without any findings suggesting malignancy.

After obtaining informed consent, genetic analysis was performed using the peripheral blood of the patient. We first evaluated the *VHL*, and heterozygous c.482G>A transition (p.Arg161Gln) in exon 3 was found (Fig. 3). Neither of her parents harbored this variation. She had no other clinical features suggesting *VHL* disease than pheochromocytoma by ophthalmologic and audiological evaluation and MRI.

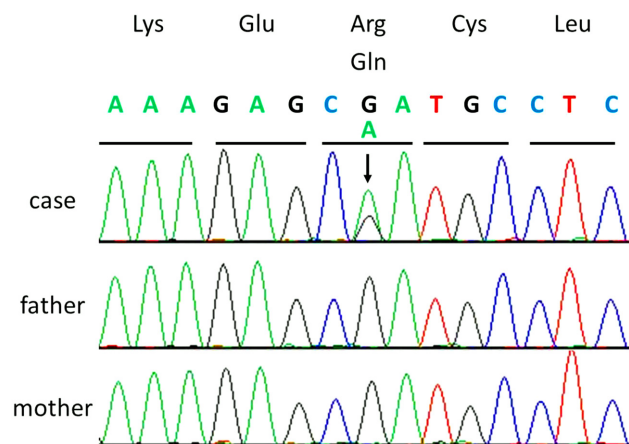


Fig. 3. Genetic analyses: Chromatogram represents a sporadic heterozygous c.482G>A transition (p.Arg161Gln). The arrow indicates the mutated nucleotide.

Discussion

A heterozygous *de novo* germline variation in the *VHL* (c.482G>A: p.Arg161Gln) was found in this case. This variation must be a causative mutation, which was described previously, and is usually associated with the VHL type 2C category characterized by the predominance of pheochromocytoma without other features of the VHL disease (10). However, patients with retinal and cerebellar hemangioblastomas and pancreatic tumors have been reported to harbor Arg161Gln mutations (11, 12). No other clinical features suggesting VHL disease other than pheochromocytoma was found in our case.

Although the symptoms, except for loss of weight, were unidentified by an ordinary physical examination, paroxysmal mild hypertension and tachycardia were identified by thorough examination after walking and abdominal compression. It is reported that 10 to 69% of adult patients with pheochromocytoma are asymptomatic (4–7). Among children, 64 to 100% of patients are reported to have hypertension (2), and most patients present with sustained rather than paroxysmal hypertension (1, 3). The reason is unknown why the symptoms including

hypertension and tachycardia were unidentified by an ordinary physical examination in this case. Although tumor size in asymptomatic patients is small (< 3 cm) (8), the tumor size in our case was large (7 cm). Theoretically possible reasons for the lack of symptoms are the following: 1) lack of catecholamine production in the tumor, 2) increased inactivation or metabolic clearance of catecholamines in the tumor, 3) impaired secretion of catecholamines from the tumor to systemic circulation, 4) reduced catecholamine receptor sensitivity in target organ, or 5) simultaneously secreted inhibitor of catecholamine from the tumor. Among these, we speculate that inactivation or metabolic clearance of catecholamines increased in the tumor, so that the symptoms were subclinical in our case, considering the following. It is reported that large tumors produce more metanephrines because the catecholamines are metabolized within the tumor before they are released, whereas small tumors are more likely to release free catecholamines (13). In our case, the tumor size was large (maximal diameter was 7 cm), and an increase in urinary metanephrine excretion (26 times the upper limit of normal) was remarkable as compared to urinary catecholamine excretion (6 times the upper limit of normal), although catecholamines and the metabolites in the tumor were not measured.

Severe paroxysmal hypertension and tachycardia were observed during operation in our case. Although preoperative therapy for pheochromocytoma with α -adrenergic blockade in patients without hypertension is controversial (14–16), α -adrenergic blockade should be prepared in case of paroxysmal hypertension during operation.

Pyrexia, anemia, and increases in CRP and ferritin levels were observed in this case. After resection of pheochromocytoma, those abnormalities disappeared. Interleukin (IL)-6-producing pheochromocytomas, which presented with acute inflammatory reactions including pyrexia, anemia, and increases in CRP levels,

were reported (17, 18). Although the plasma IL-6 concentration was not available, IL-6 was presumed to be produced by the tumor.

Conclusion

In conclusion, pheochromocytoma can be a consideration in the differential diagnosis of weight loss. Hypertension and tachycardia can be inapparent and paroxysmal in pediatric patients as well as in adults, so thorough assessment after walking and abdominal compression should be repeated. Even when hypertension is inapparent, profound paroxysmal hypertension may occur during operation.

Acknowledgements

We thank Dr. Mami Nakayashiro for her help with editing this manuscript.

References

1. Januszewicz P, Wieteska-Klimczak A, Wyszyńska T. Pheochromocytoma in children: difficulties in diagnosis and localization. *Clin Exp Hypertens A* 1990;12: 571–9. [\[Medline\]](#)
2. Pham TH, Moir C, Thompson GB, Zarroug AE, Hamner CE, Farley D, *et al.* Pheochromocytoma and paraganglioma in children: a review of medical and surgical management at a tertiary care center. *Pediatrics* 2006;118: 1109–17. [\[Medline\]](#) [\[CrossRef\]](#)
3. Caty MG, Coran AG, Geagen M, Thompson NW. Current diagnosis and treatment of pheochromocytoma in children. Experience with 22 consecutive tumors in 14 patients. *Arch Surg* 1990;125: 978–81. [\[Medline\]](#) [\[CrossRef\]](#)
4. Levitt RG, Stanley RJ, Dehner LP. Angiography of a clinically nonfunctioning pheochromocytoma. Case report and review of the literature. *JAMA* 1975;233: 268–9. [\[Medline\]](#) [\[CrossRef\]](#)
5. van Berkel A, Lenders JW, Timmers HJ. Diagnosis of endocrine disease: Biochemical diagnosis of phaeochromocytoma and paraganglioma. *Eur J Endocrinol* 2014;170: R109–19. [\[Medline\]](#) [\[CrossRef\]](#)
6. Krane NK. Clinically unsuspected pheochromocytomas. Experience at Henry Ford Hospital and a review of the literature. *Arch Intern Med* 1986;146: 54–7. [\[Medline\]](#) [\[CrossRef\]](#)
7. Saginoya T, Miyake H, Kiyosue H, Okahara M, Hori Y, Hata H, *et al.* Significance of CT findings and catecholamine determination in peripheral blood of asymptomatic pheochromocytoma and paraganglioma. *Nippon Igaku Hoshasen Gakkai Zasshi* 2001;61: 33–8 (in Japanese). [\[Medline\]](#)
8. Williams F, Young JR. Endocrine hypertension. In: Williams Textbook of Endocrinology 12th ED. Philadelphia: Elsevier/Saunders; 2011. p.545–77.
9. Dahia PL. Pheochromocytoma and paraganglioma pathogenesis: learning from genetic heterogeneity. *Nat Rev Cancer* 2014;14: 108–19. [\[Medline\]](#) [\[CrossRef\]](#)
10. Zhang J, Ma J, Du X, Wu D, Ai H, Bai J, *et al.* Clinical and genetic investigation of a multi-generational Chinese family afflicted with Von Hippel-Lindau disease. *Chin Med J (Engl)* 2015;128: 32–8. [\[Medline\]](#) [\[CrossRef\]](#)
11. Tong AL, Zeng ZP, Zhou YR, Yuan T, Cao CX, Zhang J, *et al.* Bilateral pheochromocytoma as first presentation of von Hippel-Lindau disease in a Chinese family. *Chin Med Sci J* 2009;24: 197–201. [\[Medline\]](#) [\[CrossRef\]](#)
12. Gläsker S, Bender BU, Apel TW, Natt E, van Velthoven V, Scheremet R, *et al.* The impact of molecular genetic analysis of the VHL gene in patients with haemangioblastomas of the central nervous system. *J Neurol Neurosurg Psychiatry* 1999;67: 758–62. [\[Medline\]](#) [\[CrossRef\]](#)
13. Bravo EL. Pheochromocytoma: new concepts and future trends. *Kidney Int* 1991;40: 544–56. [\[Medline\]](#) [\[CrossRef\]](#)
14. Shao Y, Chen R, Shen ZJ, Teng Y, Huang P, Rui WB, *et al.* Preoperative alpha blockade for normotensive pheochromocytoma: is it necessary? *J Hypertens* 2011;29: 2429–32. [\[Medline\]](#) [\[CrossRef\]](#)
15. Bracker L, Rath S, Dralle H, Bucher M. Preoperative α -adrenoceptor block in asymptomatic pheochromocytoma? *Pro. Chirurg* 2012;83: 546–50 (in German). [\[Medline\]](#) [\[CrossRef\]](#)

16. Groeben H. Preoperative α -receptor block in patients with pheochromocytoma? Against. *Chirurg* 2012;83: 551–4 (in German). [[Medline](#)] [[CrossRef](#)]
17. Fukumoto S, Matsumoto T, Harada S, Fujisaki J, Kawano M, Ogata E. Pheochromocytoma with pyrexia and marked inflammatory signs: a paraneoplastic syndrome with possible relation to interleukin-6 production. *J Clin Endocrinol Metab* 1991;73: 877–81. [[Medline](#)] [[CrossRef](#)]
18. Kang JM, Lee WJ, Kim WB, Kim TY, Koh JM, Hong SJ, *et al.* Systemic inflammatory syndrome and hepatic inflammatory cell infiltration caused by an interleukin-6 producing pheochromocytoma. *Endocr J* 2005;52: 193–8. [[Medline](#)] [[CrossRef](#)]