

A Case of Severe Chronic Multifocal Osteomyelitis of the Skull Caused by *Klebsiella pneumoniae* in Mali

Ke Xu^{1,2}, Dara Charles³, Salami Ismael³, Jun Zhang⁴

¹Laboratory Medicine Center, Department of Clinical Laboratory, Zhejiang Provincial People's Hospital (Affiliated People's Hospital, Hangzhou Medical College), Hangzhou, People's Republic of China; ²Laboratory and Anatomical Pathology Department of the Mali Hospital, Bamako, Mali; ³Neurosurgery Department of the Mali Hospital, Bamako, Mali; ⁴Department of Orthopedics, Zhejiang Provincial People's Hospital Bijie Hospital, Bijie, Guizhou, People's Republic of China

Correspondence: Jun Zhang, Department of Orthopedics, Zhejiang Provincial People's Hospital Bijie Hospital, 112 Guanghui Road, Bijie, Guizhou, 551700, People's Republic of China, Tel +86-13868140717, Fax +86-857-8294072, Email spinezhangjun@aliyun.com

Abstract: Highly invasive infections caused by *Klebsiella pneumoniae*, which includes bacteremia, liver abscess, meningitis, septic arthritis, and osteomyelitis, is not commonly seen in adult immunocompetent and immunocompromised patients. Here, we report an adult case of chronic multifocal osteomyelitis with severe cranial involvement caused by *Klebsiella pneumoniae*. The patient has a 5-year history of orbital abscess and multiple scalp traumas. CT scan showed right temporal and periorbital osteolysis, multiple parietal osteolysis. The pus was collected twice and routine culture was positive for *Klebsiella pneumoniae*. Good clinical outcome was achieved with debridement and antibiotic treatment. Microbiologists and clinicians should promptly perform bacteriological cultures on biopsy specimens to facilitate diagnosis when imaging or intraoperative findings of bone infection are suspected, especially in the Mali population.

Keywords: osteomyelitis, skull, *Klebsiella pneumoniae*, multifocal

Introduction

Klebsiella pneumoniae is a Gram-negative bacterium that is ubiquitous in water, sewage, and mammalian mucosal surfaces.¹ It can cause community-acquired and nosocomial infections worldwide, and has become a clinically significant pathogen. It can cause highly invasive infections in immunocompetent and immunocompromised individuals, including bacteremia, liver abscess, meningitis, septic arthritis, and osteomyelitis, but is uncommon in adult patients.² We report a very rare adult patient with chronic multifocal osteomyelitis with severe skull involvement caused by *Klebsiella pneumoniae*.

Case Report

A 44-year-old Malian male had multiple wounds on his scalp, and he did not improve after taking unknown antibiotics. He decided to see a doctor in internal medicine and was hospitalized for a multidrug-resistant infection. The patient's condition can be traced back to 2017, when it was caused by localized pain in the tooth, which then spread to the right eye, and finally formed a periorbital abscess in the right eye. The patient went to the Otorhinolaryngology Department of Mali Hospital for treatment. The CT examination at that time showed right orbital cellulitis without intracranial invasion accompanied by osteolysis of the skull. The patient was eventually admitted for surgery with a right periorbital abscess and treated with antibiotics.

In the following years, the right orbital abscess continued to attack with more and more scalp wounds, but the patient failed to see a doctor in time due to lack of payment.

In February 2023, the patient had a huge ulcerated wound on the right eye socket and multiple wounds on the scalp, and the patient did not improve after taking unknown antibiotics (Figure 1). He decided to see a doctor in the Department of Internal Medicine and was admitted to the hospital for multi-drug resistant infection.

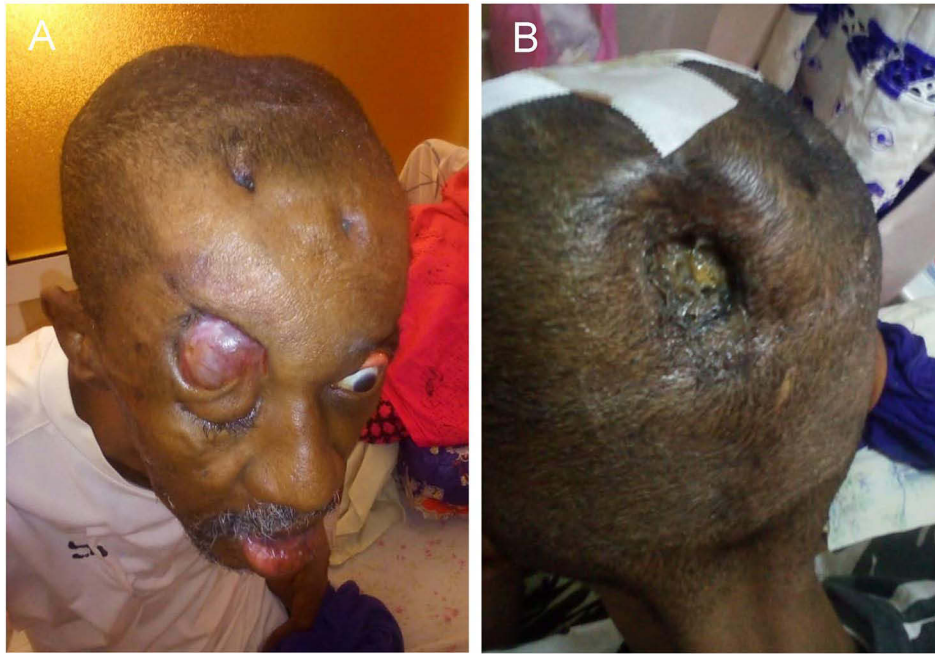

Figure 1 (A) Right orbital ulcerated wound in a patient with chronic multifocal cranial osteomyelitis caused by *Klebsiella pneumoniae*; (B) partial scalp wound.

The admission examination found that the patient weighed 41.8kg, height 1.70m, BMI 14.14kg/m², body temperature 36.2°C, dental examination showed 6 cavities (21, 22, 23, 30, 31, 41), white blood cell count was 14,920/μL, Alkaline phosphatase was 1437 U/L and C-reactive protein level was 16.798 mg/dL. Patients usually use traditional Mali natural plants to brush their teeth. This patient had no known predisposing risk factors for community-acquired infection associated with *Klebsiella pneumoniae* (diabetes mellitus, renal disease, malignancy, hepatobiliary disease, and chronic alcoholism). The admission CT results showed that the right temporal and periorbital osteolysis, multiple skull osteolysis (frontal bone, bilateral parietal bone, occipital bone), no brain abnormalities (Figure 2). The doctor's preliminary diagnosis was: hypercatabolic syndrome, osteitis complicated by cellulitis for 5 years. The pus from the wound was collected twice and sent to two different BSL2 laboratories, and both conventional cultures were positive for *Klebsiella pneumoniae*, which were resistant to amoxicillin, ticarcillin, ceftazidime, cotrimoxazole, and ciprofloxacin and sensitive to amikacin, imipenem, and ceftiofloxacin. Antibiotic susceptibility profiles were determined using the Mueller Hinton 2 agar (BIOMERIEUX; Marcy-l'etoile, France) broth microdilution method. Quality control of reagents and interpretation of minimum inhibitory concentration values were performed according to the standards of the Institute for Clinical and Laboratory Standards.

Due to the limitations of medical conditions in Mali and the economic burden of patients, the capsular typing and multilocus sequence typing of this *Klebsiella pneumoniae* strain could not be detected.

On the basis of the antibiogram, medical treatment consisted of Imipenem 1 gram slow intravenous every eight hours for 7 weeks, combined with metronidazole 500 mg every eight hours for 2 weeks, and cotrimoxazole 960 mg every eight hours as a relay after stopping metronidazole.

One month later, the patient underwent surgery: pruning + removal of bone fragments. Under general anaesthesia, a longitudinal midline incision was made from the processus occipitalis externa to the occipital region. After disinsertion of the galea and exposure of the infected bony areas, the bone sequestrations were removed and sent for bacteriological examination. Prior to closure, the wound was washed thoroughly with hydrogen peroxide and isotonic saline, and a subcutaneous drain was inserted. The bone biopsy was submitted for microbiological tests (gram stain and culture) and histopathology. Histopathology revealed the infiltration of a large number of inflammatory cells such as neutrophils and

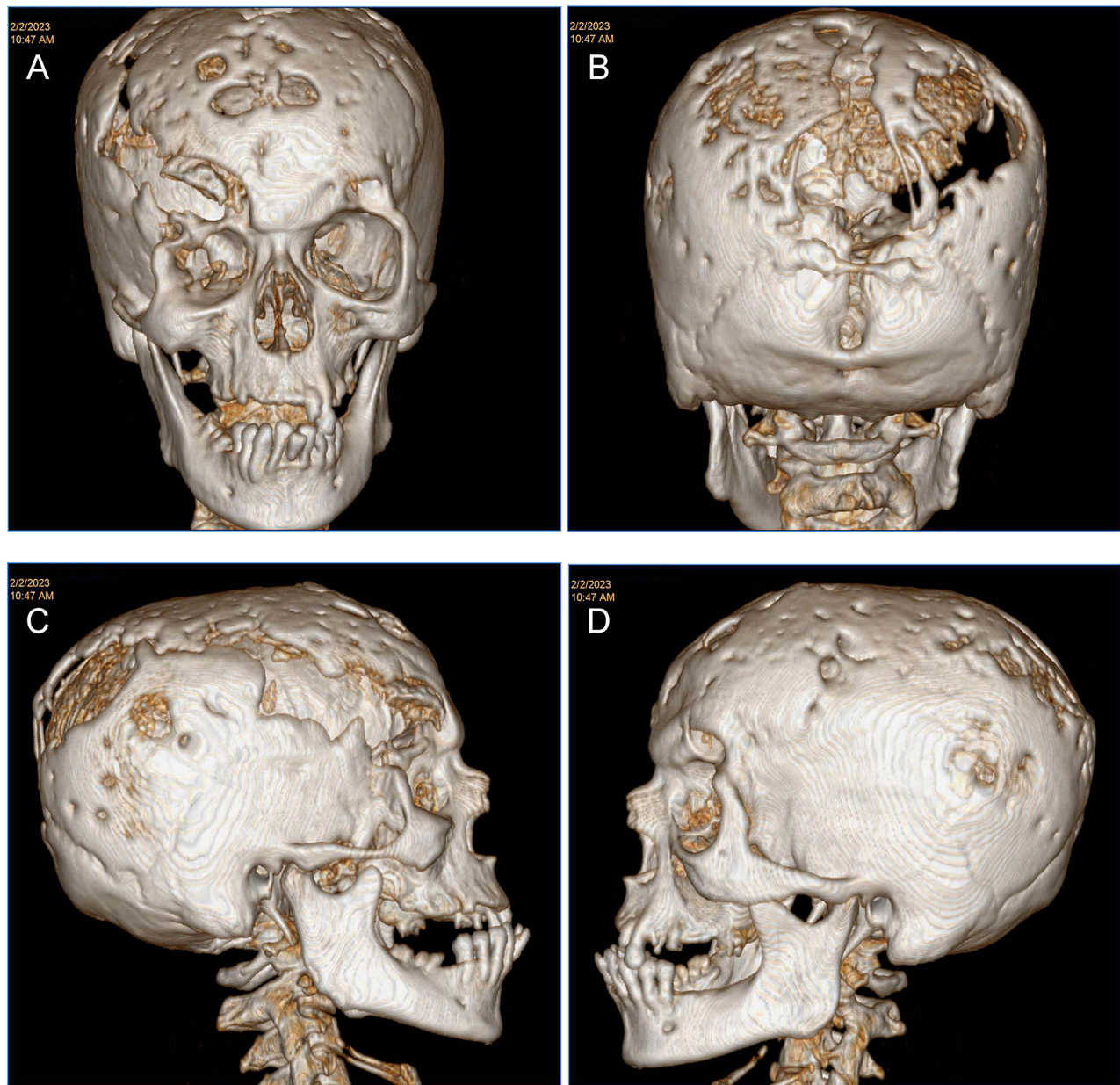


Figure 2 Three-dimensional reconstruction of computed tomography of the patient on admission showing multifocal osteolytic calvarial erosions, (A) anterior; (B) posterior; (C) right; (D) left.

lymphoplasmacytic cells, consistent with the histological manifestations of chronic osteomyelitis. Bacteriological culture results were negative.

At the follow-up review one month after the operation, the scalp wound had healed. Cerebrospinal fluid examination was clear in appearance, and bacteriological smear and culture results were negative.

Discussion

Chronic osteomyelitis is a chronic infectious disease of bone tissue, which can cause necrosis of bone, surrounding soft tissue and even bone marrow.^{3,4} It may have acute and chronic features and variable etiology. In most cases, acute osteomyelitis is due to hematogenous dissemination. Microbes can enter bone in a number of ways, including through the blood. Thus, acute hematogenous osteomyelitis is a common diagnosis. The tibia and femur are the most commonly

affected bones, followed by the humerus.⁵ *Staphylococcus aureus* was the most common organism at osteolytic bone sites (61%, 56.8% in sinuses and 76%, 37.6% in sequestrum/marrow scrapings).⁶

Microorganisms detected in samples from patients with chronic osteomyelitis included *Escherichia coli*, *Streptococcus*, *Bacillus subtilis*, *Proteus*, *coliforms*, *Klebsiella*, and many others.⁷ Taylor Sommer reported the first case of a patient who presented with acute calvarial osteomyelitis after *Varicella-zoster virus* reactivation and *Propionibacterium acnes* suprainfection.⁸ Andrew J. Kobets described a case of a child with a rare early onset STAT5b gain-of-function disease treated with targeted JAK inhibition who developed a cranial *Mycobacterium avium* osteomyelitis.⁹ Natanael Sutikno Adiwardana reported an HIV-infected patient with chronic skull osteomyelitis due to *Cryptococcus neoformans*.¹⁰ Simon Nicholson presented 2 patients of osteomyelitis of the skull caused by *Aspergillus spp.*¹¹

In humans, *Klebsiella pneumoniae* can colonize up to 35% of the colon and 5% of the oropharynx, often causing urinary, respiratory, or bile duct infections in humans.¹² In our case, the strain probably originated from dental caries in the oral cavity. Considering the living habits of Malians who use natural plant toothbrushes, there is a high risk of receiving *Klebsiella pneumoniae* from natural plant toothbrushes.¹³

Osteomyelitis in the adult population is usually exogenous or hematogenous and is associated with predisposing factors for *Klebsiella pneumoniae* infection. *K. pneumoniae* osteomyelitis affects multiple sites, with widespread destruction and periosteal reaction, and cranial osteomyelitis caused by *K. pneumoniae* is very rare.^{14,15} We do not know the capsular serotype of our isolates because typing is not available at our institution. Highly virulent and hyperviscosity *Klebsiella pneumoniae* (hvKP) strains can cause severe invasive infections such as osteomyelitis of the femur.¹⁶ Several laboratories have identified several virulence factors, including capsular serotypes, in hypervirulent hyperviscosity *Klebsiella pneumoniae*. Many reports have shown that K1 and K2 serotypes are strongly associated with hypervirulence. *Klebsiella pneumoniae*, possibly including highly virulent strains, were cultured in a group of patients with osteomyelitis in Taiwan in 2013. CHL et al reported the first case of family transmission of hvKP leading to osteomyelitis in Korea.¹⁷ Takayuki Kawamura presented a case of osteomyelitis of the femur caused by a highly virulent *Klebsiella pneumoniae* of capsular antigen type K1, sequence type 23 (ST23) in the United States.¹⁸ To determine the serotype of these strains, polymerase chain reaction testing is necessary, but this is unavailable to medical laboratories in most African countries, especially underdeveloped countries like Mali.

Conclusion

This report describes the first case of severe chronic multifocal skull involvement caused by *Klebsiella pneumoniae* in a 44-year-old Malian man. Microbiologists and clinicians should promptly perform bacteriological cultures on biopsy specimens to facilitate diagnosis when imaging or intraoperative findings of bone infection are suspected, especially in the Mali population.

Ethical Approval

The patient has given written informed consent to release case details and any accompanying images. Details of the case can be published without institutional approval.

Consent from All Authors

All authors reviewed this manuscript and agreed to submit this manuscript.

Author Contributions

All authors made a significant contribution to the work reported, whether that is in the conception, study design, execution, acquisition of data, analysis and interpretation, or in all these areas; took part in drafting, revising or critically reviewing the article; gave final approval of the version to be published; have agreed on the journal to which the article has been submitted; and agree to be accountable for all aspects of the work.

Funding

There is no funding to report.

Disclosure

The authors declare that they have no conflicts of interest in this work.

References

1. Podschun R, Ullmann U. Klebsiella spp. as Nosocomial pathogens: epidemiology, taxonomy, typing methods, and pathogenicity factors. *Clin Microbiol Rev.* 1998;11(4):589–603. doi:10.1128/cmr.11.4.589
2. Sturm E, Tai A, Lin B, et al. Bilateral osteomyelitis and liver abscess caused by hypervirulent *Klebsiella pneumoniae*- a rare clinical manifestation (case report). *BMC Infect Dis.* 2018;18(1):380. doi:10.1186/s12879-018-3277-4
3. Sağ E, Sönmez HE, Demir S, et al. Chronic recurrent multifocal osteomyelitis in children: a single center experience over five years. *Turk J Pediatr.* 2019;61(3):386–391. doi:10.24953/turkjped.2019.03.010
4. Ma J, Yang F, Yang F. Advances in clinical diagnosis and treatment of chronic osteomyelitis in adults. *Zhongguo Xiu Fu Chong Jian Wai Ke Za Zhi.* 2020;34(5):651–655. doi:10.7507/1002-1892.201909032
5. Wang X, Yu S, Sun D, et al. Current data on extremities chronic osteomyelitis in southwest China: epidemiology, microbiology and therapeutic consequences. *Sci Rep.* 2017;7(1):16251. doi:10.1038/s41598-017-16337-x
6. Sergi CM, Miller E, Demellawy DE, et al. Chronic recurrent multifocal osteomyelitis. A narrative and pictorial review. *Front Immunol.* 2022;13:959575. doi:10.3389/fimmu.2022.959575
7. Geurts J, Hohnen A, Vranken T, et al. Treatment strategies for chronic osteomyelitis in low- and middle-income countries: systematic review. *Trop Med Int Health.* 2017;22(9):1054–1062. doi:10.1111/tmi.12921
8. Sommer T, Karsy M, Driscoll MJ, et al. Varicella-zoster virus infection and osteomyelitis of the skull. *World Neurosurg.* 2018;115:297–300. doi:10.1016/j.wneu.2018.04.194
9. Kobets AJ, Ahmad S, Boyke A, et al. STAT5b gain-of-function disease in a child with mycobacterial osteomyelitis of the skull: rare presentation of an emerging disease entity. *Childs Nerv Syst.* 2023;39(8):2071–2077. doi:10.1007/s00381-023-05997-y
10. Adiwardana NS, Morás JA, Bernardo LL, et al. Chronic skull osteomyelitis due to *Cryptococcus neoformans*: first case report in an HIV-infected patient. *Braz J Infect Dis.* 2018;22(6):499–502. doi:10.1016/j.bjid.2018.11.004
11. Nicholson S, King R, Chumas P, et al. Aspergillus osteomyelitis of the skull. *J Craniofac Surg.* 2016;27(5):e504–506. doi:10.1097/scs.0000000000002797
12. Prokesch BC, TeKippe M, Kim J, et al. Primary osteomyelitis caused by hypervirulent *Klebsiella pneumoniae*. *Lancet Infect Dis.* 2016;16(9):e190–e195. doi:10.1016/s1473-3099(16)30021-4
13. Sogodogo E, Doumbo O, Kouriba B, et al. Microbial biodiversity of natural toothbrushes in Mali. *New Microbes New Infect.* 2021;40:100844. doi:10.1016/j.nmni.2021.100844
14. Singh KA, Jaunky C, Shah H. An unusual presentation, novel treatment with Meropenem PMMA beads and complications of *Klebsiella* osteomyelitis in a healthy adult- A case report. *J Clin Orthop Trauma.* 2022;24:101719. doi:10.1016/j.jcot.2021.101719
15. Stojkic I, Rubin E, Lee J, et al. An unusual presentation of chronic recurrent multifocal osteomyelitis involving bones of the skull. *Int J Rheum Dis.* 2023;26:1579–1581. doi:10.1111/1756-185x.14629
16. Kawamura T, Ono D, Shirai A, et al. Acute femoral osteomyelitis due to hypermucoviscous *Klebsiella pneumoniae*. *IDCases.* 2022;27:e01404. doi:10.1016/j.idcr.2022.e01404
17. Huang PY, Wu PK, Chen CF, et al. Osteomyelitis of the femur mimicking bone tumors: a review of 10 cases. *World J Surg Oncol.* 2013;11:283. doi:10.1186/1477-7819-11-283
18. Lee CH, Chae JD, Choe W, et al. Osteomyelitis caused by hypervirulent *Klebsiella pneumoniae*: the first Korean case with family spread. *Ann Lab Med.* 2021;41(2):250–254. doi:10.3343/alm.2021.41.2.250

Infection and Drug Resistance

Dovepress

Publish your work in this journal

Infection and Drug Resistance is an international, peer-reviewed open-access journal that focuses on the optimal treatment of infection (bacterial, fungal and viral) and the development and institution of preventive strategies to minimize the development and spread of resistance. The journal is specifically concerned with the epidemiology of antibiotic resistance and the mechanisms of resistance development and diffusion in both hospitals and the community. The manuscript management system is completely online and includes a very quick and fair peer-review system, which is all easy to use. Visit <http://www.dovepress.com/testimonials.php> to read real quotes from published authors.

Submit your manuscript here: <https://www.dovepress.com/infection-and-drug-resistance-journal>