

# Takotsubo Cardiomyopathy Secondary to Ruptured Supraclinoid Internal Carotid Artery Aneurysm

Laxmi Narayan Tripathy<sup>1</sup>, Indrajit Rana<sup>2</sup>, Amitabha Saha<sup>3</sup>, Rahul Dixit<sup>4</sup>

## ABSTRACT

A 41-year-old lady who presented with sudden-onset severe headache diagnosed to have ruptured supraclinoid internal carotid artery (ICA) aneurysm. Her cardiac echocardiography showed features of Takotsubo cardiomyopathy. After stabilizing her cardiac condition, she underwent craniotomy and clipping of aneurysm. Both cardiac and neurological catastrophes were managed by the joint team with excellent outcome. This paper emphasizes the need for high-quality combined care.

**Keywords:** Cardiomyopathy, Intracranial aneurysm, Myocardial dysfunction, Neurocritical care, Subarachnoid hemorrhage, Takotsubo cardiomyopathy.

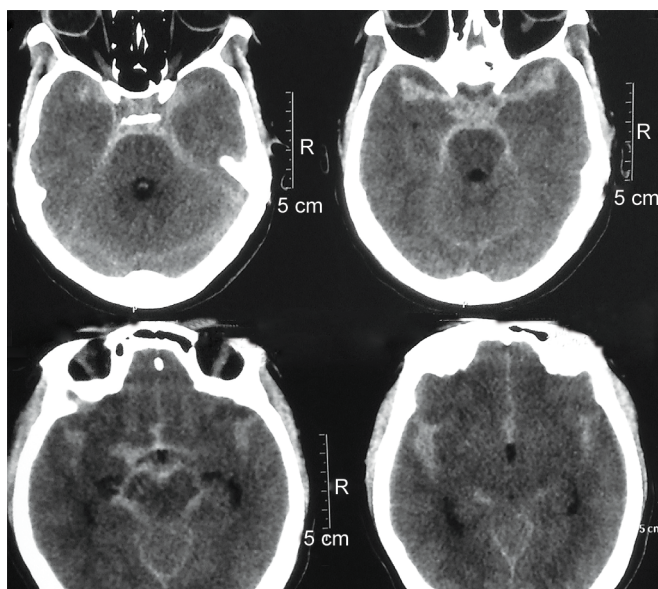
*Indian Journal of Critical Care Medicine* (2020); 10.5005/jp-journals-10071-23425

## INTRODUCTION

Subarachnoid hemorrhage (SAH) due to aneurismal bleeding carries high mortality rate. Around 61.9% of such patients can have an abnormal electrocardiogram (ECG) and many of them (20–30%) develop secondary cardiomyopathy.<sup>1</sup> The possible mechanism is that following the rupture of aneurysm there is sudden increase in the catecholamine level which can cause changes in cardiac function and direct damage to myocardium.<sup>2</sup>

## CASE DESCRIPTION

A 41-year-old lady presented with sudden-onset severe headache. Noncontrast computed tomography (CT) of brain showed SAH (Fig. 1). The CT angiography of brain did not reveal any obvious aneurysm, so DSA of cerebral vessels was suggested.



**Fig. 1:** Noncontrast computed tomography brain showing subarachnoid hemorrhage

<sup>1,2</sup>Department of Neurosurgery, Medica Superspecialty Hospital, Kolkata, West Bengal, India

<sup>3,4</sup>Department of Critical Care, Medica Superspecialty Hospital, Kolkata, West Bengal, India

**Corresponding Author:** Indrajit Rana, Department of Neurosurgery, Medica Superspecialty Hospital, Kolkata, West Bengal, India, Phone: +918820933443, e-mail: dr.indrajitrana@gmail.com

**How to cite this article:** Tripathy LN, Rana I, Saha A, Dixit R. Takotsubo Cardiomyopathy Secondary to Ruptured Supraclinoid Internal Carotid Artery Aneurysm. *Indian J Crit Care Med* 2020;24(5): 363–364.

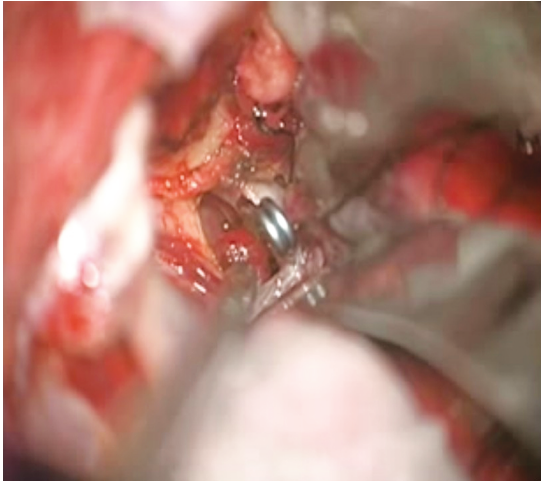
**Source of support:** Nil

**Conflict of interest:** None

Meanwhile, she developed heart failure and was intubated. Cardiac echocardiography showed apical and mid-ventricular hypokinesia (ejection fraction 25%) with normal motion of the basal wall [Takotsubo cardiomyopathy (TCM)]. Troponin I and N-terminal pro-brain natriuretic peptide (NT-proBNP) levels were high. She was kept at the ventilator support completely sedated and paralyzed with the high fraction of inspired oxygen (FiO<sub>2</sub>) and the high positive end-expiratory pressure (PEEP) setting. Treatment was given with digoxin, ivabradine and diuretics (furosemide infusion). Regular echocardiography was done to monitor cardiac function. After 1 week of all supportive management, her cardiac function was improved (ejection fraction 55%). She was extubated and following stabilization DSA of cerebral vessels was done, which showed a saccular aneurysm measuring 2 × 2.4 mm with neck of 1.5 mm arising from the medial aspect of the right supraclinoid internal carotid artery (ICA). She underwent craniotomy and clipping of supraclinoid ICA aneurysm (Fig. 2). Following operation, she had very good recovery (Glasgow outcome scale 1).

## DISCUSSION

Cardiac dysfunction in SAH can be of various types such as apical, basal, mid-ventricular, and global. Takotsubo cardiomyopathy is



**Fig. 2:** Intraoperative image showing clipped right internal carotid artery aneurysm

an apical variety of cardiac dysfunction. The incidence of TCM in SAH patients is 4–15% in different studies. It is common in women (89%) and affects mainly 50–60 years of age group.<sup>3</sup> In this case report, the patient is young and she had no comorbidity. Her cardiac dysfunction was picked up early by echocardiography, even though the initial ECG showed no changes.

Takotsubo cardiomyopathy is treated with different supportive therapy such as angiotensin-converting enzyme inhibitors, beta-blockers, and diuretics.<sup>1,4</sup> Though it is a transient disorder, the outcome is poor in majority of cases if it is not diagnosed early. It is also important to rule out other types of cardiac dysfunction as the treatment in TCM is different. The modified version of Mayo Clinic Criteria is used to diagnose such cases.<sup>4</sup>

## CONCLUSION

Cardiac complications in SAH are associated with poor outcomes. There should be early echocardiography evaluation of such patients. With prompt and careful management, cardiac complications are usually reversible. In the present case, prompt cardiac and neurointensive care combined with successful clipping of the aneurysm helped to save the patient's life and prevented any permanent disability.

## CLINICAL SIGNIFICANCE

The paper emphasizes the need for high-quality combined care in a patient of TCM secondary to ruptured aneurysm.

## DECLARATION OF PATIENT CONSENT

All appropriate patient consent was taken for this case report.

## REFERENCES

1. Banki N, Kopelnik A, Tung P, Lawton MT, Gress D, Drew B, et al. Prospective analysis of prevalence, distribution, and rate of recovery of left ventricular systolic dysfunction in patients with subarachnoid hemorrhage. *J Neurosurg* 2006;105(1):15–20. DOI: 10.3171/jns.2006.105.1.15.
2. Papanikolaou J, Makris D, Karakitsos D, Saranteas T, Karabinis A, Kostopanagiotou G, et al. Cardiac and central vascular functional alterations in the acute phase of aneurismal subarachnoid hemorrhage. *Crit Care Med* 2012;40(1):223–232. DOI: 10.1097/CCM.0b013e31822e9fab.
3. Shimada M, Jonathan DR. Takotsubo cardiomyopathy secondary to intracranial hemorrhage. *Int J Emerg Med* 2014;7(1):33–34. DOI: 10.1186/s12245-014-0033-4.
4. Núñez-Gil IJ, Molina M, Bernardo E, Ibañez B, Ruiz-Mateos B, García-Rubira JC, et al. Tako-tsubo syndrome and heart failure: long-term follow-up. *Rev Esp Cardiol* 2012;65(11):996–1002. DOI: 10.1016/j.recesp.2012.04.016.