




Contents lists available at ScienceDirect

International Journal of Surgery Case Reports

journal homepage: www.casereports.com

Removal of large impacted foreign body from the base of the skull through submandibular access: A multidisciplinary approach

Hatem H. Al-Ahmady^a, Mohamed El Sayed^b, Ahmed Fereir^{c,*}, Amr Ekram^d, Kareem Mousa^e

^a Department of Oral and Maxillofacial Surgery, Faculty of Dentistry (Girls), Al Azhar University, Cairo, Egypt.

^b Department of Otolaryngology-Head and Neck Surgery, Faculty of Medicine, Banha University, Banha, Egypt

^c Department of Oral and Maxillofacial Surgery, Faculty of Dentistry, Future University, End of 90th St., Fifth Settlement, New Cairo, Cairo, Egypt

^d Oral and Maxillofacial Radiology, Ekram Center for Oral Radiology and Computer Assisted Surgeries, Cairo, Egypt

^e Department of Radio-Diagnosis, Faculty of Medicine, Cairo University, Cairo, Egypt

ARTICLE INFO

Article history:

Received 22 May 2018

Received in revised form 2 July 2018

Accepted 14 July 2018

Available online 25 July 2018

Keywords:

Foreign body

External carotid artery

Submandibular

Infra-temporal cone beam computed

tomography

Skull base

ABSTRACT

INTRODUCTION: This report describes the removal of a missed impacted large piece of a glass that reaches the infra-temporal region after a traumatic injury at the submandibular area.

CASE PRESENTATION: A nine year-old patient presented with a limited mouth opening (0.5 cm). Initial examination showed a scar of an old trauma in the submandibular area two months prior to presentation. The radiographic study showed a large knife-shaped foreign body with its tip at the infra-temporal region, and its base at the submandibular region. Further multi-slice computed tomography with angiography was done that showed close proximity of the foreign body to the branches of the external carotid artery; maxillary, lingual and facial branches. The foreign body was removed via extra-oral approach through the old scar of the past injury under general anesthesia. Dissection, exposure of the external carotid artery and preparing it for emergency ligation, were done before extraction of the foreign body. The patient's mouth opening increased to 2.5 cm without any complications.

CONCLUSION: Cut wounds in the face should not be repaired in the primary care without detailed history, systematic examination and proper investigations.

© 2018 Published by Elsevier Ltd on behalf of IJS Publishing Group Ltd. This is an open access article under the CC BY-NC-ND license (<http://creativecommons.org/licenses/by-nc-nd/4.0/>).

1. Introduction

Penetrative wounds, which are caused by perforating or piercing objects such as knives, glasses, etc., may result in breaking of these objects with their entrapment in the soft tissue as foreign bodies [1,2].

The face is the most exposed area in the human body that is why these injuries are common [3]. Removal of the foreign bodies from the maxillofacial region is a complicated decision, which depends on size, difficulty of access and proximity to the vital structures [4].

We are here presenting a case of a limited mouth opening in a child after two months of a traumatic collision with a glass door. A part of the glass was impacted as a foreign body and missed to be diagnosed with its base at the submandibular region touching hyoid bone and its apex at the infratemporal region. This paper has been reported in line with SCARE criteria [5].

2. Case presentation

Nine-year-old female child, accompanied by her parents attended to our oral and maxillofacial surgery clinic complaining of inability to open her mouth as usual. The history of the present case was crush injury with glass door two months ago. The patient's father reported that after injury the child suffered severe bleeding from the wound under her chin. They went to a nearby hospital where they just closed the wound by stitches.

The examination revealed old scar, about six-cm in the submandibular region, with a weakness of the marginal mandibular branch of Facial nerve (VII) on the left side and the mouth opening was 0.5 cm only.

The Differential diagnosis was made as undiagnosed fracture or fibrous Ankylosis of the temporomandibular joint with post-traumatic facial nerve paresis. We requested Cone Beam Computed Tomography (CBCT) due to its low dose of radiation. The result of the CBCT (Scanora3D, Soredex, Finland) was Shocking; there was a knife shaped foreign body embedded in the soft tissue close to the lingual aspect of the mandible at the left side. Its base was in the submandibular region inferiorly resting on hyoid bone and its

* Corresponding author.

E-mail address: dr.afreer@yahoo.com (A. Fereir).

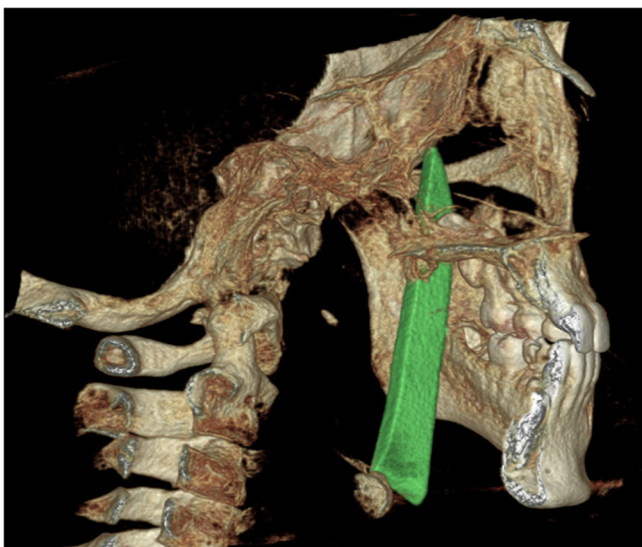

Fig. 1. Showing foreign body extended from hyoid bone inferiorly to infra temporal region superiorly.

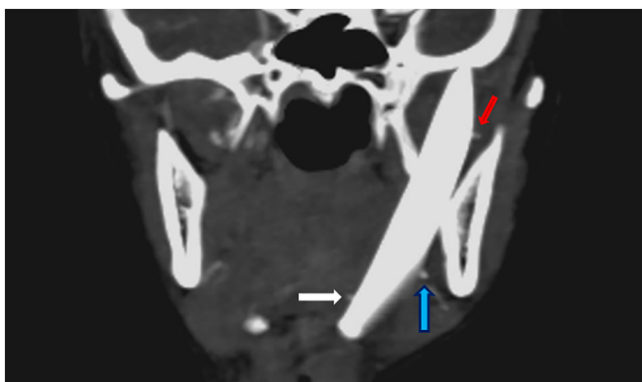


Fig. 2. Coronal cut of multi-slice computed tomography with angiography showing the left maxillary artery (red arrow) between the upper part of the foreign body and the ramus of the mandible. The lower part of the foreign body is related to the left lingual artery (white arrow) medially and the left facial artery (blue arrow) laterally.

edge was at the skull base superiorly, in the infratemporal region. Image reconstruction, volume rendering, segmentation and color-coding was performed with the software (Ondemand3D ver. 1.0.10, cybermed, Korea) for better visualization as in Fig. 1.

Due to the proximity of the foreign body to the vital structures, multi-slice computed tomography (CT) with angiography was performed with a helical multi-slice CT scanner (Siemens medical system, Germany). The data was transferred to the workstation (Syngo, Siemens medical system, Germany) where multi-planar reconstruction and volume rendering was done. The study showed that the foreign body lies anterior to the carotid sheath, as its lower part close to the lingual and facial branches of the external carotid artery and its upper part in the infra-temporal region close to the maxillary artery that passes between foreign body and mandible as shown in Fig. 2.

Group discussion was held between maxillofacial surgeon, head and neck surgeon, anesthetist and radiologist. The treatment plan was to remove the foreign body under General anesthesia starting first with; surgical exposure of the external carotid artery and its branches for emergency ligation, then removal of the foreign body.

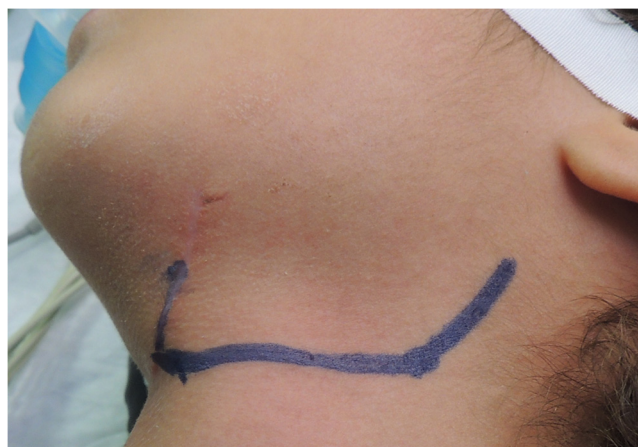

Fig. 3. Drawn incision line across the old scar.

3. Surgical procedure

The plan was to use fiber-optic during the nasal intubation to avoid opening the patient's mouth. The submandibular incision was made with slight lateral extension, for better exposure of the external carotid artery as in Fig. 3. Dissection was done with identification of the sternocleidomastoid muscle, then its anterior border was retracted posteriorly and dissection continued till identification of the common carotid artery (CCA). The external carotid artery was recognized with its branches, a 0- vicryl suture was passed underneath for emergency ligation if needed. The superior flap was dissected until identification of the submandibular salivary gland along with the facial artery and vein, at that moment, the shadow of the base of the foreign body appeared. Local dissection over the foreign body was done until all the edges of it appeared; it was a piece of glass, as in Fig. 4A. That piece was held tightly and pulled out with caution, Fig. 4B. No remarkable bleeding observed, however, suction drain inserted and the wound was closed in layers.

After 24 h, the drain was removed and the patient could open her mouth more than before (2.5 cm) but with slight pain. The patient was discharged and had been seen in the follow-up period regularly without any complications. Besides, both the patient and the family, felt grateful, as the scar is inconspicuous, As in Fig. 5.

4. Discussion

Foreign body injuries are most common in children and adults with mental impairment or adults with a history of accidents, militant actions or surgical procedures [6]. In this case, the missed foreign body was in a child with a history of trauma at the same age group mentioned earlier.

In the present case, the family seeks other consultation only, after their child complained of a limited mouth opening. It was unknown that piece of glass was deeply impacted there. Glass embedded in deep muscular tissues or in-close relation to the bone could be very hard to discover in the maxillofacial region [7]. In the management of the case, we asked for CBCT, as we did not find any radiographs done after trauma. The provisional diagnosis was a possibility of fracture or Ankylosis. There was not any sign or symptom of tetanus, so it was excluded. The use of CBCT was a felicitous choice, which leads to the discovery of the foreign body, and hence, the CBCT as a low-radiation imaging method is reported in the literature for detection and localization of foreign bodies [8].

Removal of a superficial foreign body could be done easily but the deep one is more difficult and associated with more complications [9], especially, those in head and neck area; should be managed with a multidisciplinary team approach [10]. In our case,

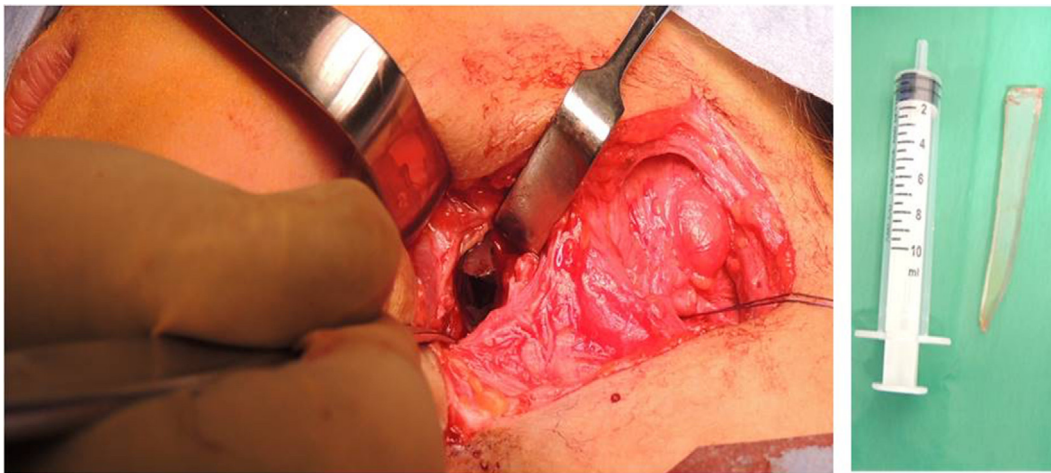


Fig. 4. A. Foreign body in place (between the two retractors). B. Large piece of glass after removal.

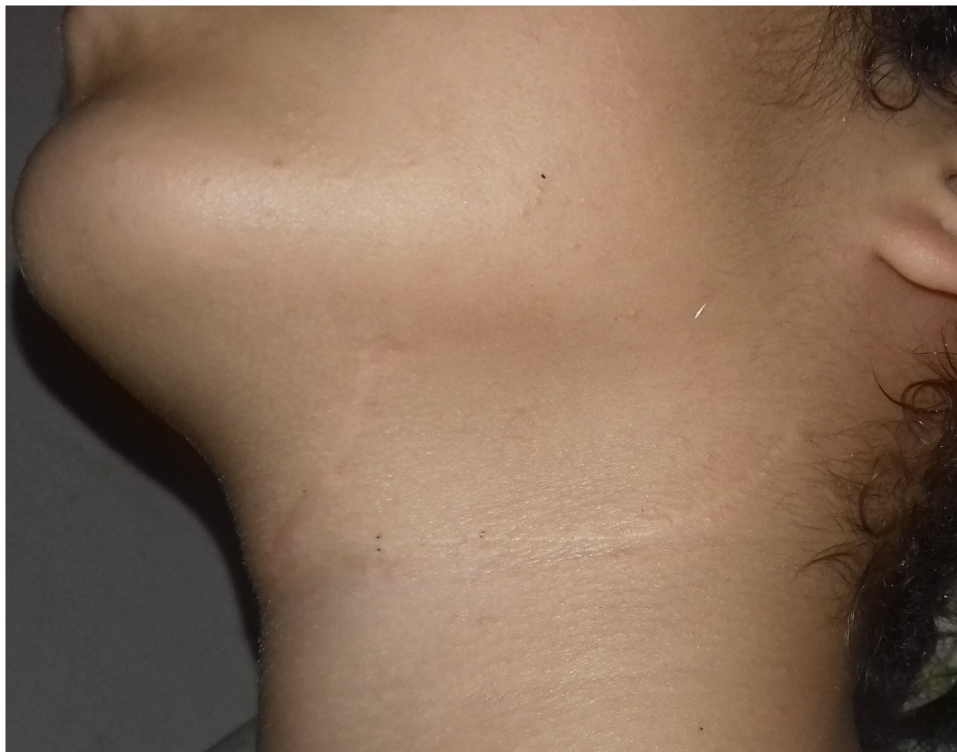

Fig. 5. Postoperative scar in the follow-up period.

the removal of the foreign body was done after gaining access across the old scar through a submandibular incision, which was advantageous, as, the scar was hidden and esthetically accepted. We did not use any localization technique during removal of the foreign body, and the plan was implemented with success, however, some authors have advocated using an advanced intraoperative method like navigation [11].

In conclusion, any maxillofacial injury should be managed in a systematic way with detailed history, examination, and suitable investigations. Cut wounds in the face should not be repaired in the primary care given to the patient without sufficient investigations first, and the operator should follow the basic surgical principles of cut wound repair. In addition, the author recommends, suturing of such like wounds in the face under General anesthesia especially, in children.

Conflict of interest

No any types of conflict of interest regarding this article.

Funding

This article did not receive any specific grant from funding agencies in the public, commercial, or not-for-profit sectors.

Ethical approval

Our institution does not require ethical approval for publishing case report.

Consent

Written informed consent was obtained from the patient's parents regarding sharing clinical data, photos and publishing as a case report.

Author contribution

1) Hatem H. Al-Ahmady: the main operator surgeon (formulated the treatment plan).

2) Mohamed el sayed: the 2nd main operator surgeon (with his expertise in skull base surgery and head and neck surgery) besides he shared in the table discussion.

3) Ahmed Fereir: 1st assistant surgeon, diagnosed the case at first and shared in writing the manuscript.

4) Amr Ekram: was great help to us in the table discussion and he made the cone beam computed tomography with software integration which enables us approaching the foreign body and he shared in writing.

5) Kareem Mousa: he made the multi-slice computed tomography integrated angiography, shared in the table discussion and in the writing of the manuscript.

Registration of research studies

There is in literature already published data stating removal of foreign body from human. This is not the first one.

Guarantor

Hatem H. Al-Ahmady.
Ahmed Fereir.

References

- [1] B.A. Ueek, Penetrating injuries to the face: delayed versus primary treatment—considerations for delayed treatment, *J. Oral Maxillofac. Surg.* 65 (6) (2007) 1209–1214.
- [2] G. Eggers, C. Haag, S. Hassfeld, Image-guided removal of foreign bodies, *Br. J. Oral Maxillofac. Surg.* 43 (5) (2005) 404–409.
- [3] S. Mohanavalli, J.J. David, A. Gnanam, Rare foreign bodies in oro-facial regions, *Indian J. Dent. Res.* 22 (5) (2011) 713–715.
- [4] S. Santos Tde, et al., Impacted foreign bodies in the maxillofacial region—diagnosis and treatment, *J. Craniofac. Surg.* 22 (4) (2011) 1404–1408.
- [5] R.A. Agha, A.J. Fowler, A. Saetta, I. Barai, S. Rajmohan, D.P. Orgill, for the SCARE Group, The SCARE statement: consensus-based surgical case report guidelines, *Int. J. Surg.* 27 (2016) 187–189.
- [6] T.B. Hunter, M.S. Taljanovic, Foreign bodies, *Radiographics* 23 (3) (2003) 731–757.
- [7] K.K. Blackhall, D.C. Laraway, Penetrating retro-orbital foreign body—large glass shards: a maxillofacial surgery case report, *SAGE Open Med. Case Rep.* 4 (2016), p. 2050313x15622890.
- [8] F. Kaviani, et al., Detection of foreign bodies by spiral computed tomography and cone beam computed tomography in maxillofacial regions, *J. Dent. Res. Dent. Clin. Dent. Prospects* 8 (3) (2014) 166–171.
- [9] T.R. Fowler, S.J. Crellin, M.R. Greenberg, Detecting foreign bodies in a head laceration, *Case Rep. Emerg. Med.* 2015 (2015) 801676.
- [10] E.H. Shinohara, L. Heringer, J.P. de Carvalho, Impacted knife injuries in the maxillofacial region: report of 2 cases, *J. Oral Maxillofac. Surg.* 59 (10) (2001) 1221–1223.
- [11] H. Gui, et al., Image-guided surgical navigation for removal of foreign bodies in the deep maxillofacial region, *J. Oral Maxillofac. Surg.* 71 (9) (2013) 1563–1571.

Open Access

This article is published Open Access at [sciencedirect.com](https://www.sciencedirect.com). It is distributed under the [IJSCR Supplemental terms and conditions](#), which permits unrestricted non commercial use, distribution, and reproduction in any medium, provided the original authors and source are credited.