

PRIMARY PULMONARY COCCIDIOIDOMYCOSIS

EXPERIMENTAL INFECTION WITH *COCCIDIOIDES IMMITIS**

BY ALFRED E. CRONKITE, M.D., AND ARTHUR R. LACK

(From the Department of Public Health and Preventive Medicine, Stanford University
School of Medicine, San Francisco)

PLATES 4 AND 5

(Received for publication, June 3, 1940)

Since the relationship of Valley fever to coccidioidal granuloma was postulated in 1936 by Gifford, and Dickson, independently (1, 2) and in collaboration (3), the experimental production of pulmonary infection with *Coccidioides immitis* has become a problem of practical importance. There are several references in the literature suggesting a primary pulmonary infection and even before the demonstration of Valley fever as a primary stage of pulmonary infection with the fungus, *Coccidioides immitis*, experiments to produce infection by inhalation of the fungus were projected.

It is of interest to review briefly references in the literature to primary inhalation infection with the fungus. The first suggestion as to the respiratory route of infection was made by Ophuls, in 1904 (4), in a discussion of an autopsied case of coccidioidal granuloma. Again in 1905 and later in 1929 (5-7) he called attention to the probability of infection through the pulmonary route. Other authors who have mentioned the probable importance of inhalation of the spores of the fungus are: McNeal and Taylor (8), Cummins and Sanders (9), Hammack and Lacey (10), Rixford (11), Sorsky and Nixon (12), Beck, Traum, and Harrington (13), and de Almeida (14). Dickson (15-19) has repeatedly emphasized the pulmonary portal of entry and has been largely responsible for the undertaking of the experiments reported here. The epidemiological survey of San Joaquin fever by Smith (20, 21) and his associates adds further clinical proof of the respiratory nature of the primary infection. Besides these pathological, clinical, and epidemiological references, there are a few experimental studies. In 1906 Brown (22, 23) attempted to infect guinea pigs by transferring cultures in the spore-bearing stage to their nostrils and their food. However, before completion of the experiments his animals were destroyed in the San Francisco fire, and there has been no subsequent report. Jacobson (24-26) unsuccessfully attempted to transmit the disease to guinea pigs kept in the same cage with or fed the leavings of infected animals. The first successful pulmonary infections were described by Ahlfeldt (27) who exposed a small number of rabbits and guinea pigs by tracheal insufflation and by spraying a suspension of the fungus into a closed chamber. She reported that three guinea pigs exposed to the spray

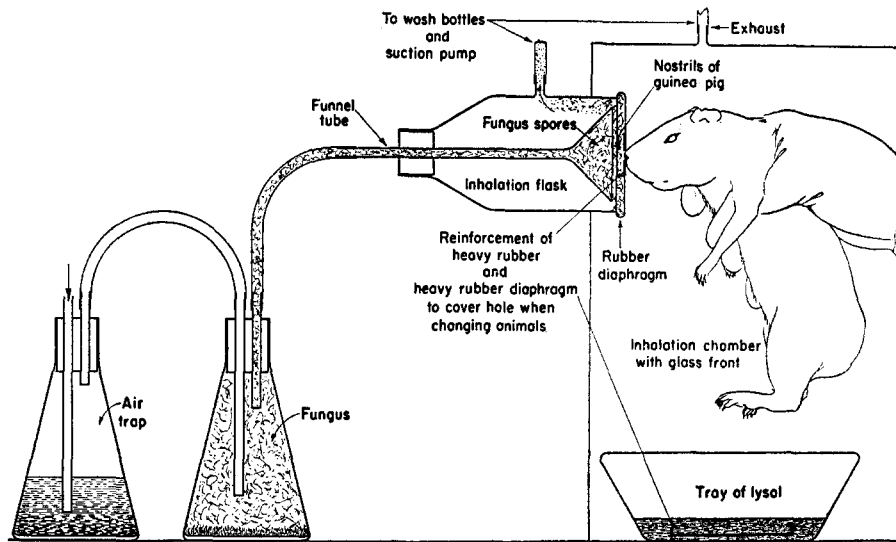
* This study was financed by a grant from the Rosenberg Foundation.

died within 11 days showing a weight loss of about 45 per cent. Autopsies were negative in the gross, but organisms were reported in cervical lymph nodes of two of the animals.

Pulford and Larson (28) stated that they have experiments under way in which spores are placed in tubes which fit over the guinea pigs' mouths. Thus far, their results have not been reported.

Method

An apparatus was developed which provided a means of permitting guinea pigs to inhale an atmosphere containing the dried mycelial spores of the fungus. This apparatus is diagrammed in Text-fig. 1. A flask of fungus (the preparation of which will be subsequently considered) was fitted with a rubber stopper with two glass tubes as indicated



TEXT-FIG. 1. Diagrammatic sketch of inhalation apparatus

and connected into the system between the air trap flask and funnel tube with rubber tubing. The air trap flask containing water acted as an indicator of the rate of flow of air through the system and also as a trap against any backflow of spores. The rate of flow of air through the system was controlled by means of a valve in the suction line. As air was sucked through the system the flask containing the fungus growth was agitated, causing the beads in the bottom of the flask to dislodge a cloud of spores. These spores were drawn in through a funnel tube into a bell jar to the vicinity of the animal's nostrils by means of a suction exhaust. Each animal exposed was restrained by being wrapped in a towel, and then held so that its nose filled the hole in the diaphragm, with the nostrils just inside the inhalation flask.

When animals were not actually in position for inhalation the aperture in the diaphragm was covered by a heavy piece of sheet rubber which was moistened with 5 per cent lysol.

It is to be noted that the open end of the inhalation flask was within a hood with a sliding glass front. Each chamber was exhausted separately through three bottles in series each containing glass beads to break up bubbles and partially filled with a saturated solution of phenol.

In all cases the operator wore cap, gown, rubber gloves, and a dust filter type of respirator.

In many cases animals were found to have a visible deposit of spores about their nostrils after exposure. The noses of the animals were sponged with 5 per cent lysol before being returned to their cages.

It was found that in order to get an adequate cloud of spores in the inhalation flask special attention had to be paid towards: (1) obtaining a luxuriant growth of fungus; (2) adequately drying the fungus and underlying media; (3) providing a means of breaking up and suspending the dried culture.

The fungus was grown in conical flasks of about 250 cc. capacity in which only enough solid medium (Sabouraud's agar) was placed to form a layer about 1 to 2 mm. deep. While the medium was still liquid the flask was rolled so as to obtain a thin coating about 3 to 4 cm. up the wall as well as on the bottom of the flask, then it was chilled.

About 15 or 20 sterilized glass beads 5 mm. in diameter were added to each flask at the time it was inoculated with a generous amount of dried fungus from old cultures. Gently shaking the beads distributed the fungus over the media. The cultures were incubated at 37°C., and on every day or two for the first 8 to 12 days 4 to 5 cc. of liquid synthetic medium was added to provide adequate fluid and nutrient material. The growth thus obtained exceeded by three to four times that of ordinary cultures on a thick layer of agar. When the cultures were about 2 or 3 weeks old they were transferred to an incubator with air circulating system which acted as a desiccator. They were left here until adequately dried, which required about 3 or 4 weeks more.

The guinea pigs were killed and examined at intervals after exposure, varying from a few hours to several weeks. Sections were prepared from lungs, tracheobronchial lymph nodes, and any other tissues of special interest. These sections were studied for any evidence of infection and for the presence of coccidioides spherules. In a portion of the series pieces of lung tissue were transferred to tubes of media for culture of the fungus. Most of the animals were skin tested with coccidioidin at frequent intervals. One series of animals was weighed daily for several weeks previous to exposure, and thereafter until time of death. All animals dying in the course of the experiments were examined similarly to those killed.

RESULTS

We shall report at this time only those experiments in which a sufficient time elapsed between exposure and death for lesions to become visible in the gross. The minimum time in which this occurred was 12 days.¹

These experiments included a total of 72 animals exposed in seven differ-

¹ Positive cultures were obtained from the lungs of animals killed 4 and 8 days after exposure.

ent groups at different times, and in some cases under slightly different conditions. The length of exposure varied from 3 to 6 minutes, and the concentration of spores in the air of the inhalation flask was not controlled. Two groups totaling 23 animals were exposed twice at intervals of approximately 1 month.

Of the total number of animals exposed, 30 (42 per cent) developed lesions recognizable in the gross.² 11 of these had been exposed to the fungus twice, an incidence of infection of 48 per cent in the doubly exposed group.

One group of 15 animals was studied for loss or gain of weight, each animal being weighed daily over a period of 3 months following inhalation. Of this group 48 per cent were positive for coccidioidal infection at the time of autopsy. Only 3 of the positive animals had lost weight. The others showed a steady gradual gain. Of those that lost weight, the amounts of loss (figured from an average maximum weight for a period of 1 or 2 weeks when the weight curve was approximately flat) were 7, 11, and 17 per cent respectively. Comments on weight variation must necessarily be limited to stating that no significant weight loss was noted in the majority of animals weighed, and nothing like the 45 per cent weight loss reported by Ahlfeldt was seen.

Coccidioidin skin tests were made at weekly intervals both before and after exposure. In one group of 11 guinea pigs, 10 showed strongly positive reactions after 3 weeks and 1 had a doubtfully positive reaction. All were previously negative before inhalation. However, there were some inconsistencies in the other groups and a more complete report in this regard must necessarily await more extensive data. Our experience with skin testing this group of animals seems to indicate that the guinea pig does not develop the high degree of sensitivity to coccidioidin that is observed in the human being. In man 0.1 cc. of 1:1000 dilution often produces marked induration and erythema, and not rarely vesiculation or even a slough. While with guinea pigs it was found necessary to use 0.1 cc. of full strength coccidioidin to obtain positive reactions.

Due to variations in amount of fungus growth and degree of desiccation of the cultures the concentration of spores to which different groups of animals were exposed varied somewhat. This factor was probably responsible for the relatively low incidence of infection. The slightly greater

² In 2 of these animals organisms were not seen in the sections of lung but were present in the tracheobronchial lymph nodes.

percentage of infection in the doubly exposed group could be explained entirely on the basis of a second chance for infection of the animals not infected at the first exposure. Considering the small number of animals involved, there is no significant difference in incidence of infection between animals exposed twice, and those exposed only once.

When a method can be worked out by which the dosage can be calibrated in terms of number of viable spores inhaled, percentages of infection under varying conditions may be of some significance. Here it is only a rough measure of success of the method.

These studies were projected with the hope of obtaining a fairly complete series showing the development of lesions from the earliest stages, and the development of the organism from the chlamyospore to spherule after invasion of tissue. However, this aspect of our study is incomplete and only a brief description of the gross and microscopic appearance of the lesions of the primary pulmonary infection as seen in the guinea pig will be given.

The early lesions (seen at 8 to 21 days after inhalation of the organism) are slightly elevated, somewhat translucent, grayish nodules varying in diameter from about 2 mm. down to the limits of visibility with the unaided eye (Fig. 1). They are quite similar in the gross to the nodules of miliary tuberculosis. More advanced lesions are fibrous, opaque nodules up to about 5 mm. in diameter which may be isolated, or numerous, scattered throughout the lung and obscuring largely its normal structure. The tracheobronchial lymph nodes are enlarged, and in cut-section may show similar nodules.

Microscopically the lesions are fairly typical granulomata. In the first 4 to 12 days there are areas of interstitial thickening characterized by the presence of mononuclear cells and often eosinophiles. This cellular infiltration results in thickened alveolar septa and narrowed alveoli with little or no exudate (Fig. 2). The inflammation may be quite generalized or limited to small areas. The gross nodules are seen in the sections as areas in which the normal architecture of the lung is obliterated (Fig. 3), being replaced with a structure of epithelioid cells with occasional multinucleated giant cells, which frequently contain one or more typical spherules of coccidioides. Older lesions show varying degrees of fibrosis and central necrosis and usually contain spherules of varying sizes. The tracheobronchial glands frequently show granulomatous lesions containing the spherules of coccidioides (Fig. 4). In the earliest lesions very few spherules are seen, the fungus not having completed the transition from chlamyospore

to spherule. Apparently the details of this transition will not be described until a differential stain is available.

SUMMARY AND CONCLUSIONS

1. The literature concerning inhalation infection with *Coccidioides immitis* is briefly reviewed.
2. A laboratory technique for exposing animals to inhalation of the spores of *Coccidioides immitis* is described.
3. Primary pulmonary infection was produced in 42 per cent of 72 animals exposed by this method.
4. No marked weight loss was apparent in the animals infected.
5. Skin tests with coccidioidin were not entirely satisfactory in diagnosis. Positive skin tests with coccidioidin were obtained in many of the infected animals, but inconsistencies occurred.
6. The gross and microscopic lesions are briefly described and illustrated.

BIBLIOGRAPHY

1. Gifford, M. A., Annual Report, Kern County Health Department for the Fiscal Year July 1, 1935, to June 30, 1936, 22.
2. Dickson, E. C., *California and West. Med.*, 1937, **47**, 151.
3. Dickson, E. C., and Gifford, M. A., *Arch. Int. Med.*, 1938, **62**, 853.
4. Ophuls, W., *California State J. Med.*, 1904, **2**, 387.
5. Ophuls, W., *J. Am. Med. Assn.*, 1929, **93**, 1055.
6. Ophuls, W., *J. Exp. Med.*, 1901-05, **6**, 443.
7. Ophuls, W., *J. Am. Med. Assn.*, 1905, **45**, 1291.
8. McNeal, W. J., and Taylor, R. M., *J. Med. Research*, 1914, **30**, 261.
9. Cummins, W. T., and Sanders, J., *J. Med. Research*, 1916, **35**, 243.
10. Hammack, R. W., and Lacey, J. M., *California and West. Med.*, 1924, **22**, 224.
11. Rixford, E., *Proc. Staff Meetings, Mayo Clinic*, 1932, **7**, 352.
12. Sorsky, E. D., and Nixon, C. E., *California and West. Med.*, 1935, **42**, 98.
13. Beck, M. D., Traum, J., and Harrington, E. S., *J. Am. Vet. Med. Assn.*, 1931, **78**, n. s. **31**, 490.
14. de Almeida, F., *Ann. Fac. Med. Sao Paulo*, 1930, **5**, 125.
15. Dickson, E. C., *Arch. Int. Med.*, 1915, **16**, 1028.
16. Dickson, E. C., *Arch. Int. Med.*, 1937, **59**, 1029.
17. Dickson, E. C., *J. Am. Med. Assn.*, 1938, **111**, 1362.
18. Dickson, E. C., *Am. Rev. Tuberc.*, 1938, **38**, 722.
19. Dickson, E. C., *Pacific Coast Med.*, 1939, **6**, 2.
20. Smith, C. E., *Proc. Epidemiol. Sect. 6th Pacific Sc. Congr.*, 1939, in press.
21. Smith, C. E., *Am. J. Pub. Health*, 1940, **30**, 600.
22. Brown, P. K., *Tr. Am. Assn. Physn.*, 1906, **21**, 651.
23. Brown, P. K., *J. Am. Med. Assn.*, 1907, **43**, 743.

24. Jacobson, H. P., *California and West. Med.*, 1928, **29**, 392.
25. Jacobson, H. P., *Arch. Dermatol. and Syphilol.*, 1930, **21**, 790.
26. Jacobson, H. P., *J. Am. Med. Assn.*, 1929, **93**, 1055.
27. Ahlfeldt, F. E., *Arch. Path. and Lab. Med.*, 1926, **2**, 206.
28. Pulford, D. S., and Larson, E. E., *J. Am. Med. Assn.*, 1929, **93**, 1049.

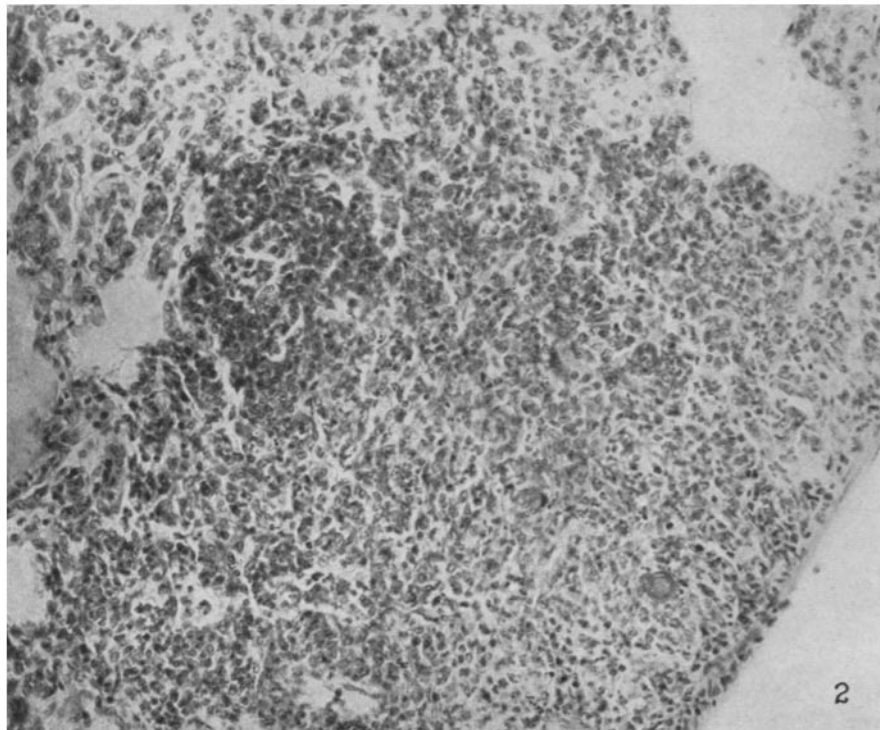
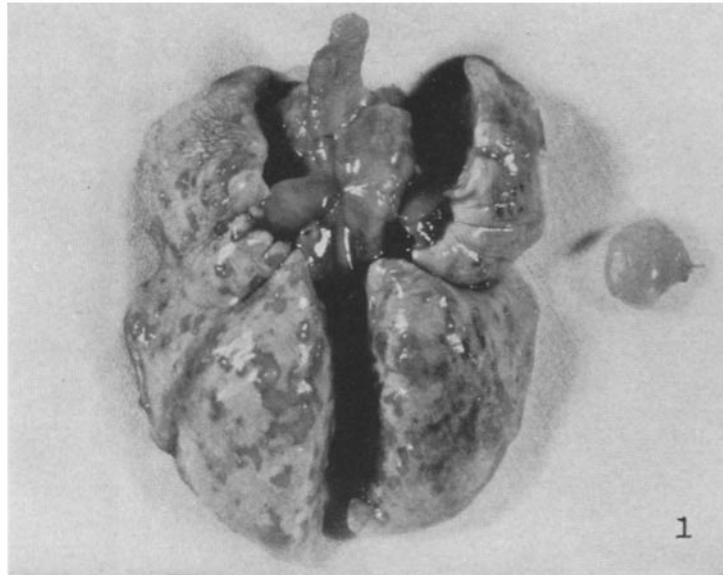
EXPLANATION OF PLATES

The sections were fixed with formalin-alcohol-acetic acid, and they were stained with hematoxylin and eosin.

PLATE 4

FIG. 1. Lungs of guinea pig 2-25, 21 days after exposure to inhalation of spores of *Coccidioides immitis*. There are many nodular lesions, 1 to 3 mm. in diameter and greatly enlarged peribronchial and peritracheal lymph nodes. Approximately $\times 1$.

FIG. 2. Microscopic section of lung of guinea pig 1-71, 12 days after inhalation. Early granulomatous lesion. Approximately $\times 225$.

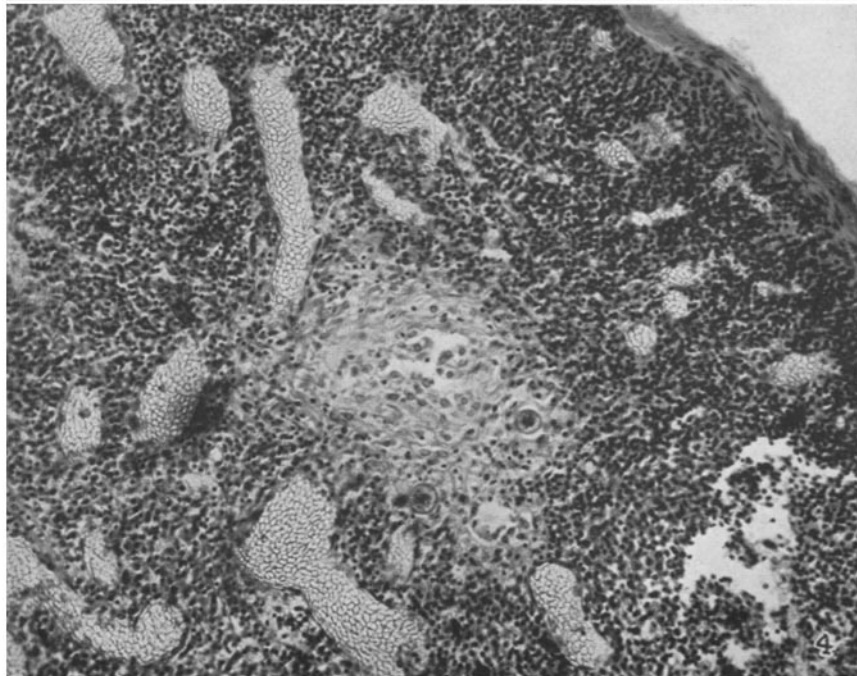
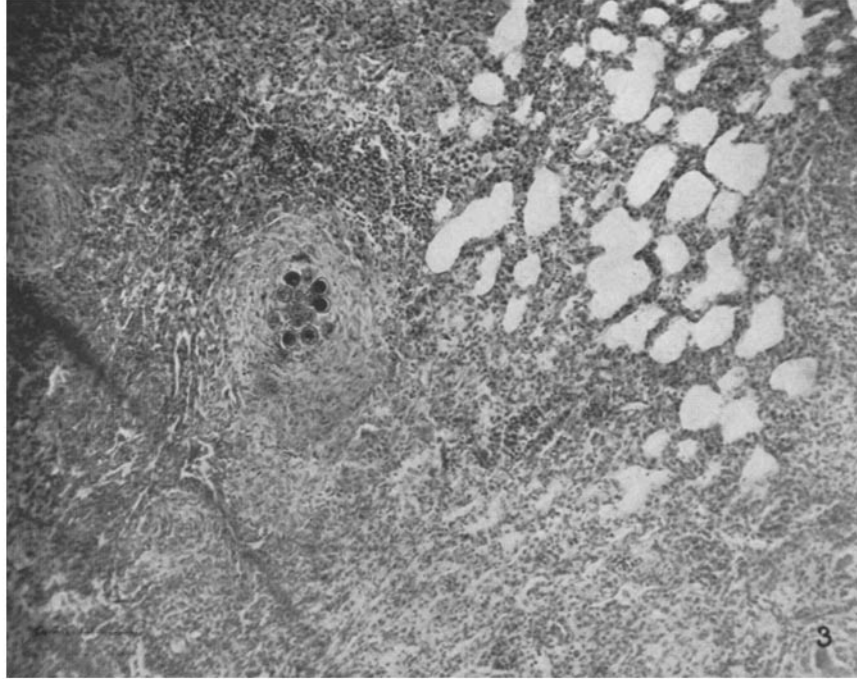


(Cronkite and Lack: Primary pulmonary coccidioidomycosis)

PLATE 5

FIG. 3. Microscopic section of lung of guinea pig 29, 3 months after infection, showing areas of interstitial thickening adjacent to a granulomatous nodule containing spherules of *Coccidioides immitis*. Approximately $\times 100$.

FIG. 4. Early nodule containing spherules of *Coccidioides immitis* in a tracheobronchial lymph node of guinea pig 31. Approximately $\times 200$.



(Cronkite and Lack : Primary pulmonary coccidioidomycosis)