

# Oesophageal ulceration in adult patients treated with doxycycline for acne vulgaris

Journal of International Medical Research

2019, Vol. 47(12) 6404–6409

© The Author(s) 2019

Article reuse guidelines:

[sagepub.com/journals-permissions](http://sagepub.com/journals-permissions)

DOI: 10.1177/0300060519881272

[journals.sagepub.com/home/imr](http://journals.sagepub.com/home/imr)



Yan Guo , Hua-Ming Li, Chun-Xia Li,  
Wei-Qin Zhu, Yu-Fang Wang and Ya-Hong He

## Abstract

**Objective:** To report drug-induced oesophageal ulceration in adult patients treated with doxycycline for acne vulgaris.

**Methods:** This retrospective case series included data from adult patients treated with oral doxycycline therapy for acne vulgaris, who had presented with oesophageal ulceration at the Third People's Hospital of Hangzhou between June 2016 and December 2017, and whose diagnosis was confirmed by gastroscopy. Clinicodemographic data were analysed, including symptom onset, endoscopy results, that were assessed for classic features of oesophageal ulceration. Patients were questioned regarding medication intake.

**Results:** A total of 12 patients were included (mean age,  $23.50 \pm 3.20$  years), eight (66.67%) of whom were female. Based on history of medication and endoscopic findings, these patients were diagnosed with doxycycline-induced oesophageal ulceration. Most patients were found to have taken the medication at bedtime, just before lying down, and/or with insufficient water.

**Conclusion:** Doxycycline may cause oesophageal irritation when not taken with sufficient water, or taken just before lying down to sleep. Prescribing physicians should be aware of these issues, and instruct patients as to the correct method for intake of doxycycline.

## Keywords

Oesophageal ulceration, doxycycline, acne vulgaris, oesophageal injury, endoscopy, oesophageal diseases

Date received: 4 July 2019; accepted: 18 September 2019

## Introduction

Acne vulgaris is a common inflammatory disorder of the skin that involves pilosebaceous units.<sup>1</sup> Typical acne lesions include comedones, inflammatory papules and pustules, but

Department of Gastroenterology, The Third People's Hospital of Hangzhou, Hangzhou, China

### Corresponding author:

Yan Guo, Department of Gastroenterology, The Third People's Hospital of Hangzhou, 38 West Lake Road, Shangcheng District, Hangzhou 310009, China.

Email: [yanguodr@163.com](mailto:yanguodr@163.com)



nodules and cysts occur in more severe acne, which can cause scarring and psychological distress. Many therapeutic options exist for treating acne, including topical benzoyl peroxide, topical and oral antibiotics, topical and oral retinoids, and oral contraceptives.<sup>2</sup> Tetracyclines are the first-line anti-acne antibiotics,<sup>3</sup> and oral tetracyclines, such as doxycycline, lymecycline, minocycline, oxytetracycline and tetracycline, are beneficial for treating acne vulgaris.<sup>4,5</sup> Doxycycline can produce a pH of <3 when dissolved in 10 ml of water or saliva, and some patients have been found to develop oesophageal ulceration due to the incorrect intake of doxycycline during treatment of acne vulgaris.<sup>6</sup> For example, doxycycline can cause oesophageal irritation when not taken with sufficient water, or taken just before going to sleep.<sup>6</sup> Nonetheless, many physicians, and even more patients, are not aware of this problem.

Oesophageal ulcer is a necrotizing lesion that occurs at different depths of each segment of the oesophagus, below the pharynx and above the dentate line, due to various causes.<sup>7</sup>

The aim of the present study was to retrospectively analyse and report diagnosed cases of oesophageal ulcers in patients treated with doxycycline capsules, in terms of onset characteristics, endoscopic performance, and treatment, in order to provide reference information for diagnosis, treatment and prevention of drug-induced oesophageal ulcers, and to enable clinicians to correctly guide patients in using doxycycline.

## Patients and methods

### Study population

The present retrospective case series included consecutive adult patients who had been treated with oral doxycycline for acne vulgaris, who had presented at the Third People's Hospital of Hangzhou, between

June 2016 and December 2017, with oesophageal ulcer.

Inclusion criteria comprised: (1) aged  $\geq$  18 years; (2) no history of digestive disease or previous history of drug allergy; (3) no history of medication or gastrointestinal symptoms at least one month prior to initiating oral doxycycline treatment; (4) medication history of only oral doxycycline capsules prior to gastroscopy; (5) no history of alcohol intake or smoking during previous 3 years; (6) no history of ever taking aspirin or nonsteroidal drugs, and no history of tuberculosis; (7) diagnosis of oesophageal ulcer confirmed by gastroscopy; and (8) complete medical history, including clinical data and endoscopy reports. Exclusion criteria comprised: (1) patients who did not meet the inclusion criteria, and (2) patients with incomplete clinical data or follow-up data.

Endoscopy reports were retrospectively assessed, together with data relating to patient demographics, medication history, disease history, symptom changes, ulcer treatment and follow-up. Patients were also questioned regarding how they self-administered the oral doxycycline treatment.

The present study was conducted in accordance with the declaration of Helsinki, and approved by the Ethics Committee of the Third People's Hospital of Hangzhou. Written informed consent was obtained from each participant.

### Statistical analyses

Data are presented as  $n$  (%) prevalence or mean  $\pm$  SD, and descriptive statistical analyses were conducted using SPSS software, version 18.0 (IBM, Armonk, NY, USA).

## Results

A total of 12 patients with doxycycline-induced oesophageal ulceration were included in the present study (mean age,

23.50 ± 3.20 years). Eight patients were female (66.67%), resulting in a male-to-female ratio of 1: 2 for this study population. All patients had been prescribed 100 mg doxycycline, oral capsule, twice daily after meals, for the treatment of acne vulgaris. At 3–12 days (mean, 7.42 ± 2.88 days) after initiating doxycycline treatment, the patients developed chest pain (seven patients), odynophagia and chest tightness (two patients), and chest tightness (three patients), and were advised to undergo an endoscopic evaluation.

All patients underwent endoscopy, and displayed evidence of acute oesophageal ulceration (Figure 1). Most of the initial damage took the form of a direct chemical injury to the mucosa caused by doxycycline impacting the oesophagus at the level of the aortic arch. However, the proximal oesophagus was normal in all patients. Furthermore, the ulceration appeared as single or multiple ulcers, and the severity of the ulcers was mixed, with some being circumferential. The ulcers and the surrounding normal mucosa boundary were clearly visible. Histology results were negative for fungi, and there was no evidence of malignancy in any of the pathologic specimens. Based on these endoscopic findings, the patients were diagnosed with drug-induced oesophageal injury resulting from doxycycline treatment. Hence, doxycycline treatment and oral intake were discontinued. All of the patients were prescribed proton pump inhibitors (20 mg esomeprazole, orally, on an empty stomach, once daily; or 30 mg lansoprazole, oral tablets, on an empty stomach, once daily; or 40 mg pantoprazole, oral capsules, on an empty stomach, once daily), or a mucosal coating agent (2 aluminium carbonate chewable tablets, three times daily; or 10 ml sucralfate, oral suspension, three times daily). Symptoms of discomfort were relieved in all patients after 3–7 days (mean, 4.33 ± 1.50 days) of ulcer treatment, and all

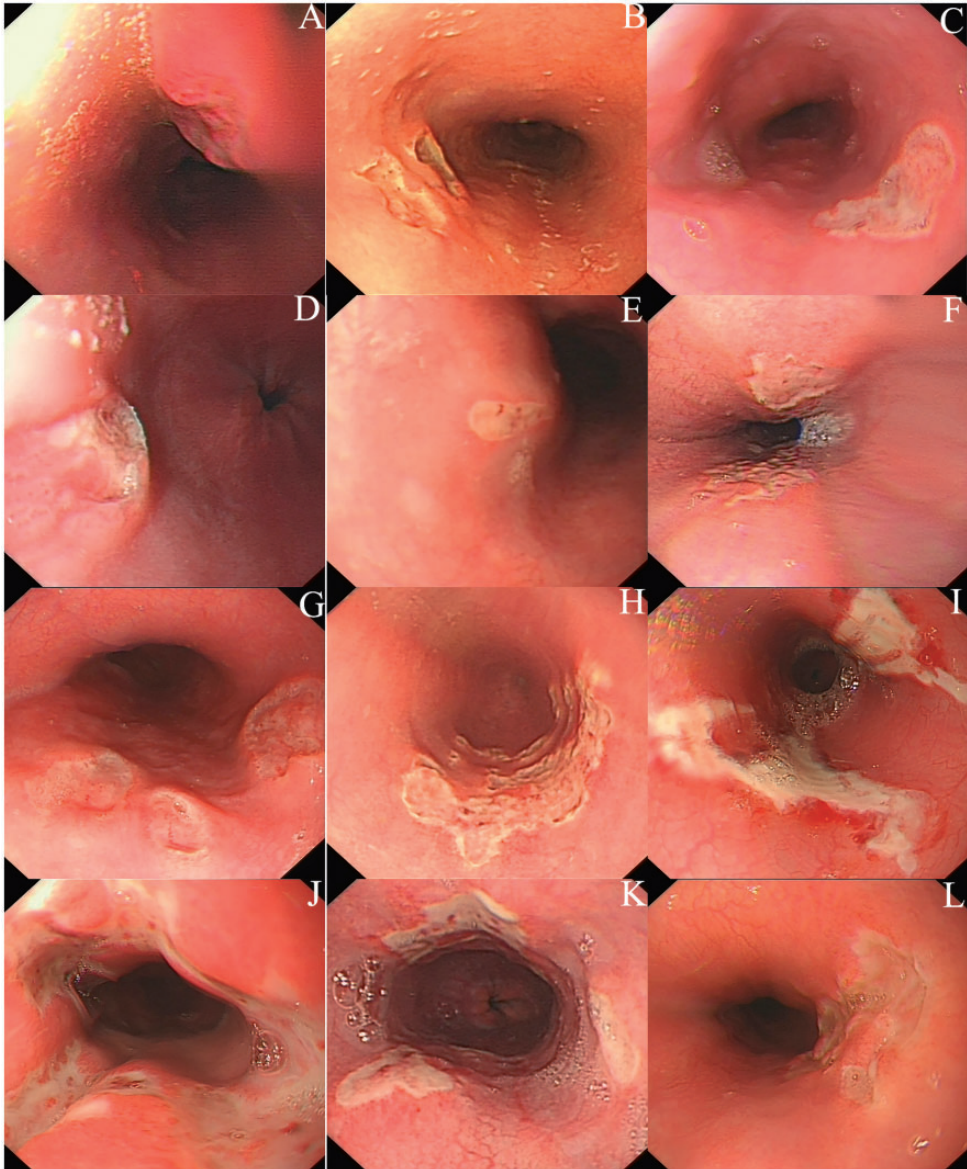
patients were reported to be able to resume a normal diet without any dysphagia.

Endoscopic follow-up at 3–12 months after the initial examination revealed complete resolution of the oesophageal lesion. No serious sequelae, such as strictures, perforation, or severe bleeding, were reported. Inquiries regarding how the patients took their doxycycline revealed that four patients took the pills at bedtime before lying down and eight patients ingested the pills with insufficient water.

## Discussion

Pill-induced oesophageal ulcers are a fairly common event, with more than 1 000 cases reported in the literature by 1995,<sup>8</sup> and cases of drug-induced oesophageal ulceration may be more numerous than previously suspected. Doxycycline is acidic when in solution and can cause mucosal injury through its caustic nature, thus, the time taken for an oral pill to travel through the oesophagus is of relative importance. Posture has been demonstrated to play a significant role in the transit time of oral pills.<sup>9,10</sup> For example, the transit time of oral pills was markedly prolonged in subjects who assumed the supine position, compared with those who were sitting or standing.<sup>10</sup> Oesophageal drug transit may also be delayed by anatomical factors, including oesophageal compression by the aortic arch or enlarged heart, or by motility disorders, such as neurological dysphagia following a cerebrovascular accident, as well as by physical position, such as taking tablets with minimal water when recumbent.<sup>11</sup> In addition, a clinical and experimental study showed that doxycycline capsules remain in the oesophagus three times longer than doxycycline tablets.<sup>12</sup>

Doxycycline-induced oesophagitis is characterized by the sudden onset of odynophagia, retrosternal burning pain, dysphagia and chest tightness during



**Figure 1.** Representative endoscopy images of oesophageal ulceration in each of 12 patients (A–L) treated with oral doxycycline for acne vulgaris, showing: (A) Crater-like mid-oesophageal ulceration; (B) Deep oesophageal ulcers with partially uncovered eroded mucosa; (C) Single mid-oesophageal ulcer; (D) Single distal-oesophageal ulcer; (E) Single oesophageal ulcer at the level of the aortic arch; (F) Kissing oesophageal ulcers at the level of the aortic arch; (G) Multiple mid-oesophageal ulcers; (H) Semi-circular oesophageal ulcers; (I) Butterfly-like mid-oesophageal ulceration partially extending in a semi-circular fashion; (J) Variable sized mid-oesophageal ulcers positioned in a circular pattern; (K) Three isolated oesophageal ulcers; and (L) Multiple mid-oesophageal ulcers and local fusion.

treatment with doxycycline,<sup>13</sup> and most cases have no history of oesophageal dysfunction. In the elderly, only 4% of gastrointestinal bleeding is reportedly due to ulcerative oesophagitis, and pill-related haemorrhage has been rarely reported.<sup>14</sup> Case history and gastrointestinal endoscopy can be used to confirm a diagnosis of doxycycline-induced oesophageal ulceration,<sup>15,16</sup> and classic endoscopic features of oesophageal ulcerations can be found. Of note, female patients appear to have twice the reported rate of drug-induced oesophageal injury as males. Treatment of drug-induced oesophagitis consists of stopping the offending medication and providing gastric acid suppression.<sup>17,18</sup>

Doxycycline has been shown to cause chemical oesophagitis when taken improperly.<sup>19,20</sup> Prevention requires a re-appraisal of the drug's indication, and adherence to guidelines on optimal drug intake, including ingestion in an upright position for 10–30 minutes after swallowing with adequate fluids.<sup>21</sup> Awareness and recognition of this problem are important, since drug-induced oesophageal injury is preventable and treatable.

During the process of enrolling cases in the present study, it was found that there was one case of gynaecological infection and one case of urinary tract infection. It is speculated that these patients may be more aware of the need to drink more water to facilitate urination and reduce symptoms. Eight patients (66.7%) in the present study were found to have taken the oral doxycycline with insufficient water. Intake of water promotes metabolism, and adequate water intake has been shown to reduce the time that doxycycline remains in the oesophagus,<sup>21</sup> reducing the time that the oesophagus is exposed to the ulcer-causing doxycycline. Due to the limited number of cases in the present study, and the

potential selection bias introduced through sampling the population by disease, exposure and outcome, the mechanism by which doxycycline causes oesophageal ulceration requires further investigation.

The scope of the present study encompassed oesophageal ulcers in adult patients treated with oral doxycycline for acne vulgaris. Due to the relatively small number of cases, patients with oesophageal ulcer who used doxycycline for other infections were not included in the research. In addition, acne can manifest in the youth, however, since the present study had a very limited number of relatively young subjects, the correlation between age and doxycycline-related oesophageal ulcer could not be investigated.

In summary, clinicians should ensure they are fully aware of the potential harm that can be caused by doxycycline, in terms of oesophageal ulcer, and take this into consideration when selecting treatment medication. Furthermore, pharmacists should provide appropriate guidance to patients for taking their medication, and patients should carefully follow the medication instructions. Efforts should be made to optimize the drug treatment, while minimizing the side effects.


### **Declaration of conflicting interest**

The authors declare that there is no conflict of interest.

### **Funding**

This research received no specific grant from any funding agency in the public, commercial, or not-for-profit sectors.

### **ORCID iD**

Yan Guo  <https://orcid.org/0000-0001-7126-1871>

## References

1. Kus S, Yucelten D and Aytug A. Comparison of efficacy of azithromycin vs doxycycline in the treatment of acne vulgaris. *Clin Exp Dermatol* 2005; 30: 215–220.
2. Amin K, Riddle CC, Aries DJ, et al. Common and alternate oral antibiotic therapies for acne vulgaris: a review. *J Drugs Dermatol* 2007; 6: 873–880.
3. Ullah G, Noor SM, Bhatti Z, et al. Comparison of oral azithromycin with oral doxycycline in the treatment of acne vulgaris. *J Ayub Med Coll Abbottabad* 2014; 26: 64–67.
4. Purdy S and de Berker D. Acne vulgaris. *BMJ Clin Evid* 2011; 2011: 1714.
5. Layton AM. Optimal management of acne to prevent scarring and psychological sequelae. *Am J Clin Dermatol* 2001; 2: 135–141.
6. Kikendall JW. Pill esophagitis. *J Clin Gastroenterol* 1999; 28: 298–305.
7. Tian YG, Cao ZZ and Bai FH. Advance in clinical characteristics of esophageal ulcer caused by different etiologies. *Chin J Gastroesophageal Reflux Dis (Electronic Edition)* 2018; 5: 189–192 [In Chinese].
8. Kikendall JW and Johnson LF. Pill-induced esophageal injury. In: Castell DO (ed) *The esophagus*. 2nd ed. Boston: Little Brown, 1995, pp. 619–634.
9. Evans KT and Toberts GM. Where do all the tablets go? *Lancet* 1976; 2: 1237–1239.
10. Passalidou P, Giudicelli H, Moreigne M, et al. Doxycycline-induced esophageal ulceration. *Arch Pediatr* 2006; 13: 90–91 [In French].
11. Shelat VG, Seah M and Lim KH. Doxycycline induced acute erosive oesophagitis and presenting as acute dysphagia. *J Assoc Physicians India* 2011; 59: 57–59.
12. Carlborg B, Densert O and Lindqvist C. Tetracycline-induced esophageal ulcers. A clinical and experimental study. *Laryngoscope* 1983; 93: 184–187.
13. Al-Mofarreh MA and Al Mofleh IA. Esophageal ulceration complicating doxycycline therapy. *World J Gastroenterol* 2003; 9: 609–611.
14. Ecker GA and Karsch J. Naproxen induced ulcerative esophagitis. *J Rheumatol* 1992; 19: 646–647.
15. Tahan V, Sayrak H, Bayar N, et al. Doxycycline-induced ulceration mimicking esophageal cancer. *Cases J* 2008; 1: 144.
16. Kadayifci A, Gulsen MT, Koruk M, et al. Doxycycline-induced pill esophagitis. *Dis Esophagus* 2004; 17: 168–171.
17. Leber A and Stal J. Simultaneous esophageal and gastric ulceration due to doxycycline ingestion: case report and review of the literature. *Gastroenterology Res* 2012; 5: 236–238.
18. Segelnick SL and Weinberg MA. Recognizing doxycycline-induced esophageal ulcers in dental practice: a case report and review. *J Am Dent Assoc* 2008; 139: 581–585.
19. Vălean S, Petrescu M, Cătinean A, et al. Pill esophagitis. *Rom J Gastroenterol* 2005; 14: 159–163.
20. Gencosmanoglu R, Kurtkaya-Yapicier O, Tiftikci A, et al. Mid-esophageal ulceration and candidiasis-associated distal esophagitis as two distinct clinical patterns of tetracycline or doxycycline-induced esophageal injury. *J Clin Gastroenterol* 2004; 38: 484–489.
21. Morris TJ and Davis TP. Doxycycline-induced esophageal ulceration in the U.S. Military service. *Mil Med* 2000; 165: 316–319.