

# New criteria to differentiate between mucinous cystic neoplasm and serous cystic neoplasm in pancreas by endoscopic ultrasound: A preliminarily confirmed outcome of 41 patients

Wengang Zhang, Enqiang Linghu, Ningli Chai, Huikai Li

Department of Gastroenterology, Chinese PLA General Hospital, Beijing 100853, China

## ABSTRACT

**Background and Objectives:** The ability to distinguish between mucinous cystic neoplasm (MCN) and serous cystic neoplasm (SCN) in the pancreas preoperatively by endoscopic ultrasound (EUS) remains a clinical challenge. To address this problem, we have developed new criteria using EUS findings and cyst fluid carcinoembryonic antigen (CEA) in the clinic. In this study, the validity and reliability of these criteria were assessed. **Materials and Methods:** Between April of 2015 and May of 2016, a total of 59 patients with pancreatic cystic neoplasms underwent EUS and ultimately received surgery in our hospital. Of the 59 patients, 21 were pathologically verified to have MCN while 20 were verified to have SCN in the pancreas. For these 41 patients with MCN or SCN, EUS findings and cyst fluid CEA were reviewed. **Results:** For the 41 patients reviewed, the new criteria were found to identify MCN with 85.71% sensitivity (95% confidence interval [CI], 64%–97%), 80.00% specificity (CI, 56%–94%), and 82.93% accuracy (CI, 68%–93%). **Conclusion:** These new criteria were preliminarily found to produce excellent results, with 82.93% accuracy determined for the differential diagnosis between MCN and SCN by EUS. However, a further prospective study with a larger population must be carried out to fully assess these new criteria.

**Key words:** Criteria, differential diagnosis, endoscopic ultrasonography, mucinous cystic neoplasm, pancreas, serous cystic neoplasm

## INTRODUCTION

Due to both widespread interest and advances in cross-sectional imaging technology, the presence of pancreatic cystic neoplasms (PCNs) is detected with increased frequency.<sup>[1]</sup> Mucinous cystic neoplasm (MCN) and serous cystic neoplasm (SCN) are the major categories of PCNs and comprise over 75% of

solitary PCNs.<sup>[2]</sup> Because MCNs have the potential to progress to a malignant state, surgical resection is the preferred treatment for this type of tumor. SCNs, on the other hand, are known to behave almost as benign tumors.<sup>[3]</sup> Thus, it is critical to accurately differentiate between MCNs and SCNs to provide proper patient

This is an open access article distributed under the terms of the Creative Commons Attribution-NonCommercial-ShareAlike 3.0 License, which allows others to remix, tweak, and build upon the work non-commercially, as long as the author is credited and the new creations are licensed under the identical terms.

**For reprints contact:** reprints@medknow.com

**How to cite this article:** Zhang W, Linghu E, Chai N, Li H. New criteria to differentiate between mucinous cystic neoplasm and serous cystic neoplasm in pancreas by endoscopic ultrasound: A preliminarily confirmed outcome of 41 patients. *Endosc Ultrasound* 2017;6:116-22.

### Access this article online

#### Quick Response Code:



#### Website:

www.eusjournal.com

#### DOI:

10.4103/eus.eus\_8\_17

### Address for correspondence

Dr. Enqiang Linghu, Chinese PLA General Hospital and Chinese PLA Medical College, Beijing 100853, China.

E-mail: linghuenqiang@vip.sina.com

**Received:** 2016-10-06; **Accepted:** 2017-01-02

management. However, the ability to differentiate between MCNs and SCNs has proven difficult using conventional imaging modalities (computed tomography [CT] and ultrasound).<sup>[2,4-7]</sup>

Endoscopic ultrasound (EUS) provides better spatial resolution compared to a CT or ultrasound and therefore allows for the more clear visualization of internal structures.<sup>[8-10]</sup> Studies have demonstrated the potential of EUS for the differential diagnosis of potentially malignant versus benign pancreatic cystic tumors.<sup>[11-14]</sup> However, endosonographers remain unable to make a confident diagnosis between MCN and SCN when using EUS. This is largely due to the fact that there exist no precise criteria for these diagnoses, with the exception of some related predictive parameters that have been confirmed.<sup>[3,13]</sup> To address this problem clinically, we have developed new criteria from EUS findings and cyst fluid carcinoembryonic antigen (CEA) for the differential diagnosis between MCN and SCN. The purpose of the present study was to assess the validity and reliability of these new criteria.

## MATERIALS AND METHODS

### *The classification of the endoscopic ultrasound findings of mucinous cystic neoplasms and serous cystic neoplasms*

Findings from EUS of MCNs and SCNs enable these to be divided into three different types. Type I is

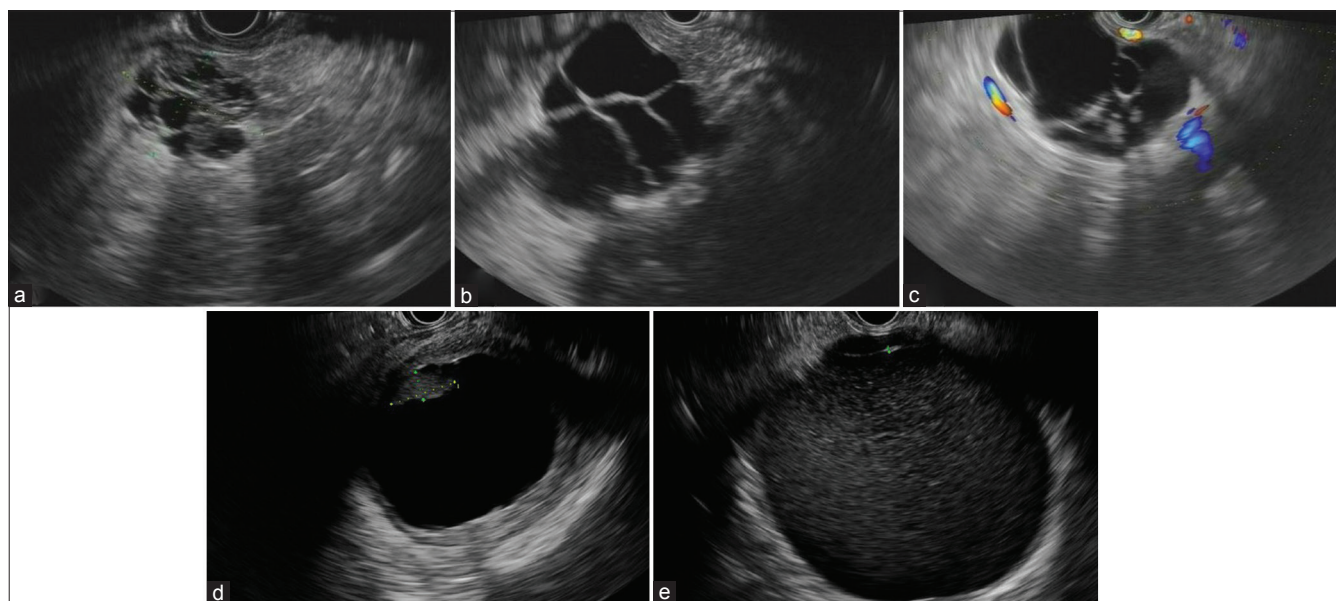
characterized by the appearance of a honeycomb cyst, which is defined as having  $\geq 10$  partitions within the cyst, and the presence of daughter cysts with a uniform size [Figure 1a and Table 1]. Type II is characterized by the appearance of a latticed cyst, which is defined as having 4–9 partitions within the cyst, and the presence of daughter cysts with various sizes [Figure 1b and Table 1]. Type III is characterized by the appearance of a rounded cyst, which is defined as having 0–3 partitions within the cyst, and the presence of mother cysts that are rounded in shape [Figure 1d, e and Table 1].

### *The new criteria*

Based on the classification of EUS findings, we generated novel criteria that include three criteria

**Table 1. Findings from endoscopic ultrasound of mucinous cystic neoplasms and serous cystic neoplasms enable these to be divided into three different types**

Classification	Definition
Type I	Characterized by appearance of honeycomb cyst, which is defined as: The number of partition in cyst $\geq 10$ , and daughter cysts have a uniform size [Figure 1a]
Type II	Characterized by appearance of latticed cyst, which is defined as: The number of partition in cyst ranges 4-9, and daughter cysts have various sizes [Figure 1b]
Type III	Characterized by appearance of rounded cyst, which is defined as: The number of partition in cyst ranges 0-3, and mother cysts are rounded in shape [Figure 1d and e]



**Figure 1.** The three different types of endoscopic ultrasound findings of mucinous cystic neoplasms and serous cystic neoplasms according to the new criteria. (a) Honeycomb cyst; (b) latticed cyst; (c) honeycomb cyst appearing in partial mother cyst after rotating endoscopy; (d) Rounded cyst with nodule-like structure; (e) rounded cyst without nodule-like structure

used to distinguish between MCN and SCN. In the case of a Type I classification, the patient can be diagnosed as SCN, unless there are nodule-like structures in the daughter cyst, which would indicate MCN [Figure 1a and Table 2]. In the case of a Type II classification, clinicians can diagnose the patient with SCN if a honeycomb cyst appears partially in the mother cyst following rotation of the endoscope. Otherwise, the patient should be diagnosed with MCN [Figure 1b, c and Table 2]. In the case of a Type III classification, the patient should be diagnosed with SCN if there are no nodule-like structures in the rounded cyst and the cyst fluid CEA <192 ng/mL. Otherwise, the patient should be diagnosed with MCN [Figure 1d, e and Table 2]. It should also be noted that there is a size restriction ( $\leq 10$  cm) associated with these new criteria. In addition, it should be noted that these new criteria apply only to patients suspected to have MCN or SCN. Thus, diagnosis of other types of pancreatic cysts should be preliminary ruled out.

#### *The patients and procedure of endoscopic ultrasound*

This study was carried out under approval from the Ethics Committee from the Chinese PLA General Hospital. Each patient involved in the study signed an informed consent form before the procedure. Between April of 2015 and May of 2016, a total of 59 consecutive patients with PCNs underwent EUS and ultimately received surgery in our hospital. Among these 59 patients, 41 were pathologically proven to have MCN (21 patients) or SCN (20 patients) in the pancreas [Table 3].

For this study, we used the echoendoscopes (GF-UCT260; Olympus, Tokyo, Japan) in the procedures. To enable the adequate transmission of the ultrasound and improve image quality, the echoprobe was routinely covered with a water-filled balloon. The patients in these studies were under general anesthesia during the procedure, and all EUS findings were recorded with video or pictures.

#### *Assessment of the new criteria*

For the 59 consecutive patients in this study, EUS findings of the 41 patients pathologically proven to have MCN or SCN were reviewed by three experienced endosonographers to classify them as MCN or SCN according to the new criteria developed. The diagnostic process is depicted in Figure 2, with the diagnosis result depending on at least two endosonographers agreeing with each other. If all three endosonographers were not

**Table 2. Differential diagnosis rules for mucinous cystic neoplasms and serous cystic neoplasms according to the classification**

Classification	Differential diagnosis rules
Type I	(A) With nodule-like structure in daughter cyst-MCN (B) Without nodule-like structure in daughter cyst-SCN [Figure 1a]
Type II	(A) Without appearance of honeycomb cyst after rotating endoscope-MCN [Figure 1b] (B) Appearing honeycomb cyst in partial mother cyst after rotating endoscope-SCN [Figure 1c]
Type III	(A) Rounded cyst with nodule-like structure-MCN [Figure 1d] (B) Rounded cyst without nodule-like structure [Figure 1e] (B-1) CEA > 192 ng/mL (B-2) CEA < 192 ng/mL

MCN: Mucinous cystic neoplasm, SCN: Serous cystic neoplasm, CEA: Carcinoembryonic antigen

**Table 3. Cystic lesions of the pancreas**

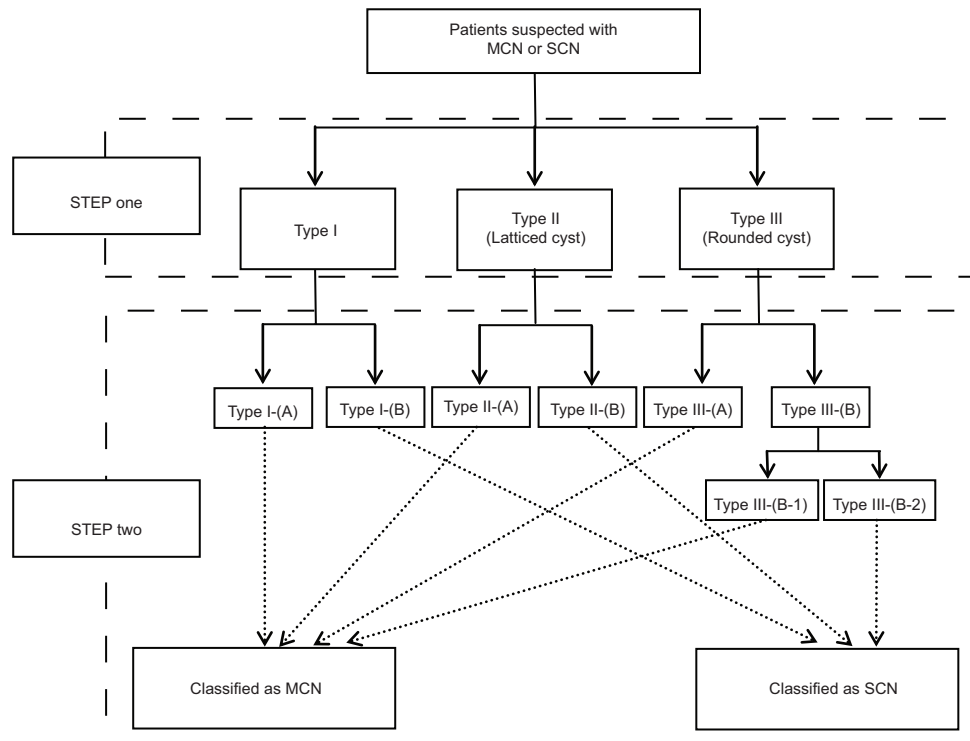
Characteristics of cystic lesions	Related data
Sex (male/female)	6/35
Mean age, years (range)	45.7 (18-76)
Tumor size, cm (range)	5.2 (2-10)
Location	
Head	13
Body/tail	28
Histology	
MCN	21
SCN	20

MCN: Mucinous cystic neoplasm, SCN: Serous cystic neoplasm

in agreement, the decision went with the majority, the two in agreement. Pathological diagnosis was considered as the gold standard here. It should be noted that the review of the EUS findings of the 41 patients was carried out after the pathologic results were obtained. However, the three endosonographers were blinded to the exact pathologic diagnosis of each patient although they were aware that the result was either MCN or SCN.

#### *Statistics*

The sensitivity, specificity, and accuracy of the new criteria developed for the identification of MCNs versus SCNs were calculated for all 41 patients that had been pathologically proven to have MCN or SCN in the pancreas. The 95% confidence intervals (CIs) were calculated for all metrics, using the exact binomial method. The location of cystic lesions, age, and sex were compared between MCN and SCN using a Chi-square test. The tumor size was compared using two-independent sample *t*-test.



**Figure 2.** The flowchart that works through the new criteria. MCN: Mucinous cystic neoplasm, SCN: Serous cystic neoplasm. STEP one, the detailed rule was shown in Table 1. STEP two, the detailed rule was shown in Table 2

**RESULTS**

*Clinical characteristics of the 41 patients with mucinous cystic neoplasm or serous cystic neoplasm*

As shown in Table 3, a total of 41 patients were pathologically proven to have MCN or SCN in the pancreas (6 males, 35 females; mean age 45.7 years; range, 18–76 years). Among these, 28 patients were found to have a cystic lesion in the body/tail of the pancreas. The remaining 13 patients were found to have a cystic lesion in the head of the pancreas. The mean tumor size was determined to be 5.2 cm (range, 2–10 cm). As shown in Table 4, both MCN and SCN occurred predominantly in females, with a tendency to be localized to the body and tail of the pancreas. However, there were no significant statistical differences measured in terms of the location of cystic lesions, age, sex, and tumor size between those with MCN versus SCN.

*Differential diagnosis between mucinous cystic neoplasm and serous cystic neoplasm according to the new criteria*

Of the 41 patients that were pathologically proven to have MCN or SCN in the pancreas, 12 were classified as Type I, 9 as Type II, and

**Table 4. Clinical characteristics of the cystic tumors of the pancreas**

	MCN	SCN	P
Sex (male/female)	4/17	2/18	0.408
Mean age (years)	43.9	47.7	0.408
Mean tumor size (cm)	5.51	5.29	0.851
Location			0.265
Head	5	8	
Body/tail	16	12	

MCN: Mucinous cystic neoplasm, SCN: Serous cystic neoplasm

20 as Type III. According to the new criteria developed, of the 12 patients classified as Type I, 1 was diagnosed as MCN and 11 as SCN. Of the nine patients classified as Type II, five were diagnosed as MCN and four as SCN. Of the 20 patients classified as Type III, 16 were diagnosed as MCN and 4 as SCN. Among the 21 patients pathologically proven to have MCN in the pancreas, 18 were diagnosed as MCN and 3 as SCN. Among the 20 patients pathologically proven to have SCN in the pancreas, 16 were diagnosed as SCN and 4 as MCN. Overall, we demonstrated that of the 41 patients, these new criteria were able to identify MCN with 85.71% sensitivity (95% CI, 64%–97%), 80.00% specificity (56%–94%), and 82.93% accuracy (68%–93%) [Figure 3 and Table 5].

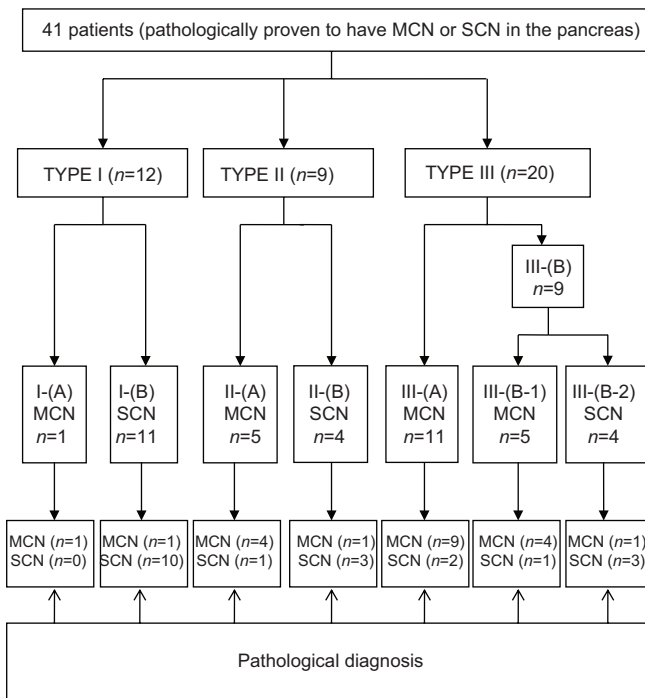


Figure 3. The diagnosis of the 41 patients according to the new criteria

Table 5. The diagnosis of the 41 patients according to the new criteria

Diagnosis according to the new criteria	Pathological diagnosis		Overall
	MCN	SCN	
MCN	18	4	22
SCN	3	16	19
Overall	21	20	41

MCN: Mucinous cystic neoplasm, SCN: Serous cystic neoplasm

## DISCUSSION

Pancreatic cysts can be broadly classified as either inflammatory or neoplastic cysts. Inflammatory cysts, also known as pseudocysts, are the sequelae of pancreatitis. Thus, these cysts can be identified relatively easily.<sup>[3]</sup> Neoplastic cysts can be classified as either nonmucinous or mucinous cysts. This classification is based on the type of fluid which the cyst produces.<sup>[15]</sup> Nonmucinous cysts are comprised SCN, and several solid lesions characterized by cystic degeneration. The latter category includes primarily pancreatic neuroendocrine tumor and solid pseudopapillary neoplasm, which are relatively simple to identify. Mucin-producing cystic neoplasms are characterized by MCNs and intraductal papillary mucinous neoplasms (IPMN).

Currently, MCN, SCN, and IPMN account for the majority of cystic neoplastic tumors in the pancreas.

SCN is considered a benign cystic tumor. However, MCN and IPMN are thought to have the potential to be malignant.<sup>[2,7,16,17]</sup> IPMN can be subclassified into main duct IPMN (MD-IPMN) and branch duct IPMN (BD-IPMN), depending on the location of the primary lesion. MD-IPMNs are characterized by a diffuse dilatation of the main pancreatic duct in the absence of a prominent cyst.<sup>[15]</sup> This is distinct from other cystic tumors of the pancreas.<sup>[18]</sup> Ninety-three percent of BD-IPMNs are found not round in appearance.<sup>[13]</sup> This characteristic can be used to differentiate between MCN and BD-IPMN. Above all, the most common and challenging issue that the endosonographer faces when diagnosing pancreatic cysts, is the differentiation between MCN and SCN.

In 2005, Sahani *et al.*<sup>[14]</sup> proposed a simple imaging-based classification system for guiding the management of PCNs. In this classification system, the morphologic appearance of PCNs was separated into either unilocular cysts, microcystic lesions, macrocystic lesions, or cysts with a solid component. However, this system did not contribute much toward the ability to differentiate between MCNs and SCNs. One primary reason that can explain this is that, despite the fact that approximately 58% of SCNs possess a classic microcystic morphology, another 20% of SCNs are macrocystic and are thus virtually identical in appearance to MCN.<sup>[19]</sup> We analyzed this problem by studying the surgical specimen. We found that the 20% of SCNs that appeared similar to MCNs in cross-sectional imaging only had partial microcystic structures in cysts. Moreover, because cross-sectional imaging is not dynamic, this can lead to the problems mentioned above. The capability for dynamic imaging as well as the ability to image in anatomical proximity to the pancreas with high resolution renders EUS an ideal tool to address this problem. Kubo *et al.*<sup>[13]</sup> reported some EUS findings that were relevant for the distinction between potentially malignant and benign PCNs in 2009. However, no precise criteria were provided. To our knowledge, this was the first EUS imaging-based criteria with the goal of distinguishing between MCN and SCN.

In the new criteria that we have developed, the goal is to dynamically observe the appearance of PCNs under EUS by rotating the endoscopy. The presence of mural nodules is an important factor for this diagnosis as is associated with the report from Rodriguez *et al.*<sup>[20]</sup> The most challenging diagnosis lies in understanding

how to differentiate between Type III-(B-1) and III-(B-2) [Table 2]. Thus, we use the CEA from cyst fluid to help with the diagnosis. We use a cutoff of 192 ng/mL from a multicenter study.<sup>[21]</sup> However, this cutoff could be altered to improve diagnosis accuracy. This is because some MCNs may not possess mural nodules or may not have a raised CEA (>192 ng/mL). Using a different cutoff value of CEA could provide the solution. For instance, Gaddam *et al.*<sup>[22]</sup> reported that a cutoff of 105 ng/mL resulted in a sensitivity and specificity of 70% and 63%, respectively. These numbers are different from that when of a cutoff of 192 ng/mL was used. However, these criteria need further study with a larger population to confirm and identify the best cutoff value. It should be noted that the lesion location and size have not been considered in these criteria due to the fact that there were no significant statistical differences observed in these two factors when comparing MCN to SCN. However, both MCN and SCN were found to occur predominantly in females, with a tendency to be localized in the body and tail of the pancreas, as demonstrated in H. Kubo's study.<sup>[13]</sup>

In the present study, the 85.71% sensitivity, 80.00% specificity, and 82.93% accuracy of the new criteria utilized to identify MCNs from SCNs mark excellent progress in this area. While the diagnosis method using CEA has a similar accuracy (79%) to these new criteria (82.93%), the new criteria are advantageous in that fine-needle aspiration (FNA) is not needed unless the cystic lesions are classified as Type III-(B).<sup>[21]</sup> Criteria that do not require FNA are advantageous in that FNA requires an experienced endoscopist and is a relatively dangerous procedure. In fact, the guidelines of the Japan Gastroenterological Endoscopy Society once proposed that EUS-guided FNA should not be permitted for the diagnosis of PCNs due to a serious risk of seeding following aspirated cystic fluid collection.<sup>[13,23]</sup>

In these new criteria, IPMN, which is also commonly found among cystic pancreatic neoplasm, was not included in this study. MD-IPMNs are relatively easy to identify by a diffuse dilatation of the main pancreatic duct in the absence of a prominent cyst,<sup>[15]</sup> and 93% of BD-IPMNs are found to not be rounded in shape.<sup>[13]</sup> Thus, IPMN can be differentiated from MCN or SCN relatively easily. Moreover, BD-IPMN is most likely to be misdiagnosed as MCN because that BD-IPMN has a similar appearance with MCN under EUS except the

nonrounded shape. Therefore, since both BD-IPMN and MCN would require surgery, it would not greatly influence patients if BD-IPMN was misdiagnosed as MCN. It has the possibility that BD-IPMN is included in these new criteria with same diagnosis criteria with MCN, which needs a further study with a large number of BD-IPMN to confirm.

Among the seven cases of misdiagnosis, two patients in line with rule of Type III-(A) were ultimately pathologically proven to be SCN. This could be explained by the fact that the presence of mural nodule is difficult to be determined by EUS alone. Recently, it has been reported that CE-EUS is effective at differentiating MNs from mucinous clots.<sup>[24,25]</sup>

One limitation of this study is that the sample size is relatively small. Another limitation is that these new criteria were applied only to patients suspected to have MCN or SCN as it is difficult to come up with exact criteria to differentiate between all types of PCNs. However, MCN and SCN are the major categories, representing over 75% of solitary PCNs.<sup>[2]</sup> Moreover, as mentioned earlier, other types of PCNs are relatively easy to identify. In the case of some simple retention cysts and lymphoepithelial cysts, they could have a similar appearance to SCN under an EUS. However, these are very rare in the clinic and are benign in nature. Therefore, since both these types of cysts and SCN would not require surgery, it would not greatly influence patients if these cysts were misdiagnosed as SCN. Thus, these new criteria will be very helpful for clinicians due to its ability to differentially diagnose between MCN and SCN. This will be of great value as this may be one of the most common challenges encountered by endosonographer when performing EUS for the diagnosis of patients with pancreatic cysts.

## CONCLUSION

These new criteria preliminarily demonstrate excellent results, with an 82.93% accuracy for the differential diagnosis between MCN and SCN by EUS. However, a further prospective study with a larger population is required to further demonstrate the value of these new criteria and determine if BD-IPMN could be included in these new criteria.

*Financial support and sponsorship*  
Nil.

*Conflicts of interest*

There are no conflicts of interest.

**REFERENCES**

1. Singhi AD, Zeh HJ, Brand RE, et al. American Gastroenterological Association guidelines are inaccurate in detecting pancreatic cysts with advanced neoplasia: A clinicopathologic study of 225 patients with supporting molecular data. *Gastrointest Endosc* 2016;83:1107-17.e2.
2. Le Borgne J, de Calan L, Partensky C. Cystadenomas and cystadenocarcinomas of the pancreas: A multiinstitutional retrospective study of 398 cases. French Surgical Association. *Ann Surg* 1999;230:152-61.
3. Hijioaka S, Hara K, Mizuno N, et al. Morphological differentiation and follow-up of pancreatic cystic neoplasms using endoscopic ultrasound. *Endosc Ultrasound* 2015;4:312-8.
4. Warsaw AL, Compton CC, Lewandrowski K, et al. Cystic tumors of the pancreas. New clinical, radiologic, and pathologic observations in 67 patients. *Ann Surg* 1990;212:432-43.
5. Visser BC, Muthusamay VR, Mulvihill SJ, et al. Diagnostic imaging of cystic pancreatic neoplasms. *Surg Oncol* 2004;13:27-39.
6. Gerke H, Jaffe TA, Mitchell RM, et al. Endoscopic ultrasound and computer tomography are inaccurate methods of classifying cystic pancreatic lesions. *Dig Liver Dis* 2006;38:39-44.
7. Levy MJ, Clain JE. Evaluation and management of cystic pancreatic tumors: Emphasis on the role of EUS FNA. *Clin Gastroenterol Hepatol* 2004;2:639-53.
8. Koito K, Namieno T, Nagakawa T, et al. Solitary cystic tumor of the pancreas: EUS-pathologic correlation. *Gastrointest Endosc* 1997;45:268-76.
9. Yamaguchi K, Tanaka M. Radiologic imagings of cystic neoplasms of the pancreas. *Pancreatol* 2001;1:633-6.
10. Ahmad NA, Kochman ML, Lewis JD, et al. Can EUS alone differentiate between malignant and benign cystic lesions of the pancreas? *Am J Gastroenterol* 2001;96:3295-300.
11. Sedlack R, Affi A, Vazquez-Sequeiros E, et al. Utility of EUS in the evaluation of cystic pancreatic lesions. *Gastrointest Endosc* 2002;56:543-7.
12. Song MH, Lee SK, Kim MH, et al. EUS in the evaluation of pancreatic cystic lesions. *Gastrointest Endosc* 2003;57:891-6.
13. Kubo H, Nakamura K, Itaba S, et al. Differential diagnosis of cystic tumors of the pancreas by endoscopic ultrasonography. *Endoscopy* 2009;41:684-9.
14. Sahani DV, Kadavigere R, Saokar A, et al. Cystic pancreatic lesions: A simple imaging-based classification system for guiding management. *Radiographics* 2005;25:1471-84.
15. Lennon AM, Wolfgang C. Cystic neoplasms of the pancreas. *J Gastrointest Surg* 2013;17:645-53.
16. O'Toole D, Palazzo L, Hammel P, et al. Macrocytic pancreatic cystadenoma: The role of EUS and cyst fluid analysis in distinguishing mucinous and serous lesions. *Gastrointest Endosc* 2004;59:823-9.
17. Sugiyama M, Atomi Y, Kuroda A. Two types of mucin-producing cystic tumors of the pancreas: Diagnosis and treatment. *Surgery* 1997;122:617-25.
18. Kubo H, Chijiwa Y, Akahoshi K, et al. Intraductal papillary-mucinous tumors of the pancreas: Differential diagnosis between benign and malignant tumors by endoscopic ultrasonography. *Am J Gastroenterol* 2001;96:1429-34.
19. Kimura W, Moriya T, Hirai I, et al. Multicenter study of serous cystic neoplasm of the Japan pancreas society. *Pancreas* 2012;41:380-7.
20. Rodriguez JR, Salvia R, Crippa S, et al. Branch-duct intraductal papillary mucinous neoplasms: Observations in 145 patients who underwent resection. *Gastroenterology* 2007;133:72-9.
21. Brugge WR, Lewandrowski K, Lee-Lewandrowski E, et al. Diagnosis of pancreatic cystic neoplasms: A report of the cooperative pancreatic cyst study. *Gastroenterology* 2004;126:1330-6.
22. Gaddam S, Ge PS, Keach JW, et al. Suboptimal accuracy of carcinoembryonic antigen in differentiation of mucinous and nonmucinous pancreatic cysts: Results of a large multicenter study. *Gastrointest Endosc* 2015;82:1060-9.
23. Hirooka Y, Goto H, Itoh A, et al. Case of intraductal papillary mucinous tumor in which endosonography-guided fine-needle aspiration biopsy caused dissemination. *J Gastroenterol Hepatol* 2003;18:1323-4.
24. Ohno E, Hirooka Y, Itoh A, et al. Intraductal papillary mucinous neoplasms of the pancreas: Differentiation of malignant and benign tumors by endoscopic ultrasound findings of mural nodules. *Ann Surg* 2009;249:628-34.
25. Yamashita Y, Ueda K, Itonaga M, et al. Usefulness of contrast-enhanced endoscopic sonography for discriminating mural nodules from mucous clots in intraductal papillary mucinous neoplasms: A single-center prospective study. *J Ultrasound Med* 2013;32:61-8.