


Evaluation of perfusion changes using a 2D Parametric Parenchymal Blood Flow technique with automated vessel suppression following partial spleen embolization in patients with hypersplenism and portal hypertension

Timo C. Meine, MD^a, Sabine K. Maschke, MD^a, Martha M. Kirstein, MD^b, Elmar Jaeckel, MD^b, Becker S. Lena, MD^a, Thomas Werncke, MD^a, Cornelia L.A. Dewald, MD^a, Frank K. Wacker, MD^a, Bernhard C. Meyer, MD^a, Jan B. Hinrichs, MD^{a,*} 

Abstract

To evaluate the feasibility and potential value of 2D Parametric Parenchymal Blood Flow (2D-PPBF) for the assessment of perfusion changes following partial spleen embolization (PSE) in a retrospective observational study design.

Overall, 12 PSE procedures in 12 patients were included in this study. The outcome of the study was the platelet response (PR), calculated as the percentage increase of platelet count (PLT), following PSE. To quantify perfusion changes using 2D-PPBF, the acquired digital subtraction angiography series were post-processed. A reference region-of-interest (ROI) was placed in the afferent splenic artery and a target ROI was positioned on the embolization territory of the spleen on digital subtraction angiography series pre- and post-embolization. The ratios of the target ROIs to the reference ROIs were calculated for the Wash-In-Rate (WIR), the Time-To-Peak (TTP) and the Area-Under-the-Curve (AUC). Comparisons between pre- and post-embolization data were made using Wilcoxon signed-rank test and Spearman's rank correlation coefficient (r). Afterwards, the study population was divided by the median of the TTP before PSE to analyze its value for the prediction of PR following PSE.

Following PSE, PLT increased significantly from $43,000 \pm 21,405$ platelets/ μL to $128,500 \pm 66,083$ platelets/ μL with a PR of $255 \pm 243\%$ ($P = .003$). In the embolized splenic territory, the pre-/post-embolization 2D-PPBF parameter changed significantly: $\text{WIR}_{\text{pre-PSE}} 1.23 \pm 2.42 / \text{WIR}_{\text{post-PSE}} 0.09 \pm 0.07$; $-64 \pm 46\%$ ($p = 0.04$), $\text{TTP}_{\text{pre-PSE}} 4.41 \pm 0.99 / \text{TTP}_{\text{post-PSE}} 5.67 \pm 1.52$ ($P = .041$); $+34 \pm 47\%$ and $\text{AUC}_{\text{post-PSE}} 0.81 \pm 0.85 / \text{AUC}_{\text{pre-PSE}} 0.14 \pm 0.08$; $-71 \pm 18\%$ ($P = .002$). A significant correlation of a 2D-PPBF parameter with the PLT was found for $\text{TTP}_{\text{pre-PSE}} / \text{PLT}_{\text{pre-PSE}} r = -0.66$ ($P = .01$). Subgroup analysis showed a significantly increased PR for the group with $\text{TTP}_{\text{pre-PSE}} > 4.44$ compared to the group with $\text{TTP}_{\text{pre-PSE}} \leq 4.44$ ($404 \pm 267\%$ versus $107 \pm 76\%$; $P = .04$).

2D-PPBF is an objective approach to analyze the perfusion reduction of embolized splenic tissue. TTP derived from 2D-PPBF has the potential to predict the extent of PR during PSE.

Abbreviations: 2D-PPBF = 2D parametric parenchymal blood flow, AUC = area-under-the-curve, DSA = digital subtraction angiography, PC = platelet concentrate, PLT = platelet count, PR = platelet response, PSE = partial spleen embolization, ROI = region-of-interest, TTP = time-to-peak, WIR = wash-in-rate.

Keywords: 2D parametric parenchymal blood flow, hypersplenism, partial spleen embolization, platelet count, portal hypertension, thrombocytopenia

Editor: Neeraj Lalwani.

The authors of this manuscript declare relationships with the following companies: Siemens Healthcare and ProMedicus (Bernhard Meyer and Frank Wacker; outside the submitted work). The remaining authors declare no relationships with any companies whose products or services may be related to the subject matter of the article.

The study was funded in parts by personal grants from Hannover Medical School ("Junge Akademie" Program). We acknowledge support by the German Research Foundation (DFG) and the Open Access Publication Fund of Hannover Medical School (MHH).

The authors have no conflicts of interest to disclose.

Supplemental Digital Content is available for this article.

All data generated or analyzed during this study are included in this published article [and its supplementary information files].

^a Department of Diagnostic and Interventional Radiology, ^b Department of Gastroenterology, Hepatology and Endocrinology, Hannover Medical School, Hannover, Germany.

* Correspondence: Jan B. Hinrichs, Institute for Diagnostic and Interventional Radiology, Hannover Medical School, Carl-Neuberg-Str. 1, 30625 Hannover, Germany (e-mail: hinrichs.jan@mh-hannover.de).

Copyright © 2021 the Author(s). Published by Wolters Kluwer Health, Inc.

This is an open access article distributed under the terms of the Creative Commons Attribution-Non Commercial License 4.0 (CCBY-NC), where it is permissible to download, share, remix, transform, and buildup the work provided it is properly cited. The work cannot be used commercially without permission from the journal.

How to cite this article: Meine TC, Maschke SK, Kirstein MM, Jaeckel E, Lena BS, Werncke T, Dewald CL, Wacker FK, Meyer BC, Hinrichs JB. Evaluation of perfusion changes using a 2D Parametric Parenchymal Blood Flow technique with automated vessel suppression following partial spleen embolization in patients with hypersplenism and portal hypertension. *Medicine* 2021;100:7(e24783).

Received: 15 February 2020 / Received in final form: 7 November 2020 / Accepted: 26 January 2021

<http://dx.doi.org/10.1097/MD.00000000000024783>

1. Introduction

Hypersplenism is defined by increased pooling and destruction of the corpuscular blood elements by an enlarged spleen.^[1] It occurs in liver cirrhosis with portal hypertension, hematologic or immunologic disorders (eg, idiopathic thrombocytopenic purpura, autoimmune thrombocytopenia, systemic lupus erythematoses) or splenic malignancies (lymphoma or leukemia).^[1–3] Clinical signs are splenomegaly, thrombocytopenia, bi- or pancytopenia with corresponding symptoms including abdominal discomfort, pain, respiratory distress or early satiety.^[1] Splenectomy is a known effective treatment for hypersplenism. Nonetheless, splenectomy is frequently accompanied with severe complications (approximately 10%), for example, splenic abscess, septicemia, or unremitting bronchopneumonia due to induced immunosuppression.^[1] Furthermore, patients with severe (pan-) cytopenia and comorbidities, especially cardiovascular diseases, may not be eligible for surgical splenectomy or even complete spleen embolization.^[1,4] Therefore, the concept of partial spleen embolization (PSE) was introduced.^[1]

In PSE, a distinct portion of the splenic tissue is embolized to reduce the consumptive activity while the remnant of the spleen is maintained vital to salvage the immunologic function.^[1] The hematologic response and the complication rate correlate with the extent of embolized splenic tissue as previously reported.^[2,5] Thus, the determination of embolization endpoints is essential for a successful intervention, because under-embolization might result in inadequate increase of the platelet count (PLT) and insufficient clotting time, whereas over-embolization might increase complications, e. g. abscess or immunologic disorders. To date, no standardized endpoint of PSE has been reported. Current endpoints are arbitrary and user-dependent, consisting of visual blush reduction of 50% to 70% in the embolized spleen and an infarction of roughly less than 60 to 80% of the splenic volume.^[2,6,7] Platelet scintigraphy is reported to predict the response to PSE, but is not available during the intervention.^[8] Peri-interventional parameters to assess and quantify the embolization effect and to estimate post-interventional outcomes are lacking. To help to overcome this issue we intended to analyze the potential of 2D Parametric Parenchymal Blood Flow (2D-PPBF). As a new prototype post-processing technique for the assessment of tissue perfusion using regular digital subtraction angiography (DSA) images 2D-PPBF is promising.^[9] The technique is based on recently described 2D perfusion angiography techniques.^[10–13] With the currently available 2D-PPBF technique, greater vessels can be automatically suppressed by a dedicated software algorithm, allowing to focus on parenchymal perfusion without superimposition of a strong signal of the greater vessels.^[9] The technique may have the potential to predict the therapeutic response during PSE and thus to be used as an objective embolization endpoint. The purpose of this study is to evaluate the ability of 2D-PPBF to assess perfusion changes during PSE using microspheres and to correlate the angiographic measurements with the hematologic outcome, the platelet response (PR) 14 days after PSE.

2. Material and methods

2.1. Study population and outcome

This retrospective study was approved by the Ethics Committee of the Hannover Medical School and is in accordance with the Declaration of Helsinki. We reviewed the institutional Picture

Archiving and Communication System for patients undergoing PSE procedures during the study period from September 2015 to February 2018 at our tertiary medical referral center for study inclusion. Inclusion criteria were portal hypertension, hypersplenism and risk of bleeding in patients not eligible for other medical, endoscopic or interventional treatment of portal hypertension. Exclusion criteria were PSE in patients with hypersplenism not related to portal hypertension. Overall, 2 PSE procedures in 1 patient not related to portal hypertension were excluded and 12 PSE procedures in 12 patients with hypersplenism and portal hypertension met the inclusion criteria. All patients were referred by the Department of Hepatology, Gastroenterology and Endocrinology with hypersplenism and portal hypertension. The treatment decision for PSE was made in an inter-disciplinary board. Amount of hypersplenism (splenomegaly and thrombocytopenia) and consecutive risk of bleeding were evaluated (s. Table 1). The included patients were not eligible for further medical, endoscopic and/or interventional treatment (s. Table 1). Patient demographics, procedural details and complications after PSE were recorded. Outcome was evaluated by PR, calculated as the percentage increase of PLT via standard venous blood count panel of the patient before and up to 14 days after PSE. When platelet concentrates (PC) were administered to the patient peri-interventionally, platelet refractoriness was indicated according to the corrected count increment.^[14,15] Hospital discharge was usually within two weeks after PSE. Vaccinations were recommended according to the national guidelines by the Standing Committee on Vaccination at the Robert Koch Institute.

2.2. Partial spleen embolization

All procedures were performed by experienced interventional radiologists following an institutional standard operating procedure on a monoplane, ceiling-mounted angiographic system (Artis Q, Siemens Healthcare, Forchheim, Germany) or on a monoplane, robotic-arm-mounted angiographic system (ARTIS pheno, Siemens Healthcare) under local anesthesia. A 6F introducer sheath (Avanti+, Cordis, Waterloo, Belgium) was placed in the right common femoral artery. By use of a suitable guiding catheter and a diagnostic catheter, a celiac angiogram was obtained. Subsequently, a microcatheter (Renegade™ STC 18 with Transend™ 0.014 guidewire, Boston Scientific, Marlborough MA, USA or Merit Maestro™ with Tenor™ 0.014 guidewire, Merit Medical, Utah, USA) was advanced to a peripheral splenic artery branch for selective embolization. According to our institutional standards, microspheres were used as permanent embolic agent, because lower recanalization rates and lower incidence of fever have been described for particles compared to other embolic agents.^[16] The particle size ranged from 100–300 μm to 700–900 μm (Embospheres, Merit Medical) at the discretion of the interventionalist in order to achieve complete stasis. The angiographic endpoint was defined as visual loss of blush in the embolization territory of the spleen and/or stasis in the splenic artery branch as assessed by the interventionalist. An embolization volume of less than 50 to 70% was considered, because the lowest rate of complications in combination with a substantial hematologic response were reported for a spleen infarct volume of less than 50% and the most severe complications occurred at 70% infarct volume of the spleen.^[2] Therefore, we aimed to embolize the inferior splenic artery branch, which supplies about 40% of the spleen.^[17]

Table 1
Study population and outcome - demographics.

Patient No.	Sex	Age	Primary Disease	Indication				Outcome		
				D _s	TCP	Other	Complication	PLT _{pre-PSE}	PLT _{post-PSE}	PR
1*	m	51	Hepatitis C Virus	22,4	severe	LC, PHTN, PVT, EGVB/EVL	discomfort, fever, ascites, atelectasis	27	266	+885%
2	f	22	Cystic Fibrosis	20,4	mild	LTx° +LC, PHTN, EGV, HRS, HPS, an-emia	discomfort	59	111	+88%
3	f	17	Hepatic Rhabdomyosarcoma	18	severe	PHTN, PVTT, EGV, UGIB/IR	-	33	60	+81%
4	m	22	Cystic Fibrosis	21,6	severe	LC, PHTN, EGVB/EVL, Hemoptysis*	ascites	22	119	+440%
5	m	19	Colitis Ulcerosa/ Primary Sclerosing Cholangitis	28	mild	LTx, PHTN, CTPV, EGVB, Pancytopenia	discomfort, fever, peritonitis	92	87	-5%
6	f	13	Cystic Fibrosis	34	severe	LC, PHTN, EGV, petechia	discomfort, ascites, pleural effusion	32	159	+396%
7*	f	38	Antisynthetase Syndrome	16	mild	LC, PHTN, PVT, EGVB/ EVL	discomfort	54	235	+335%
8	m	21	Cystic Fibrosis	22	mild	LC, PHTN, EGVB/EVL, Hemoptysis*	discomfort	65	124	+90%
9	m	40	Cryptogenic (Chronic) Hepatitis	17,8	severe	PHTN, EGVB/ EVL, PC-AB	discomfort, fever	26	45	+73%
10	f	44	Autoimmune Hepatitis Type 1	24,6	severe	LC, PHTN, EGVB/EVL, R-TIPS	fever	22	87	+295%
11	m	28	Hepatitis B Virus (perinatal)	15,65	severe	PHTN, PVT, CTPV, EGVB/ EVL	discomfort, fever, ascites	34	99	+191%
12	f	41	Budd-Chiari-Syndrome	26,4	severe	LC, PHTN, EGVB/ EVL, R-TIPS	fever	50	150	+200%

Demographics, indication, complication and outcome for all patients and PSE are tabulated. Abbreviations are: CTPV=Cavernous Transformation of the Portal Vein, D_s=Diameter of the Spleen [cm], EGV=Esophagogastric Varices, EGVB=Esophagogastric Variceal Bleeding, EVL=Endoscopic Variceal Ligation, HPS=Hepato-Pulmonary-Syndrome, HRS=Hepato-Renal-Syndrome, IR=Intestinal Resection, LC=Liver Cirrhosis, LTx=Liver Transplant, PC-AB=Antibody against Platelet Concentrate, PHTN=Portal Hypertension, PLT=Platelet count [10.000/μL], PR=Platelet Response [(PLT_{post-PSE}-PLT_{pre-PSE})/PLT_{pre-PSE}*100], PVT=Portal Vein Thrombosis, PVTT=Portal Vein Tumor Thrombosis, R-TIPS=Revision of Transjugular Intrahepatic Portosystemic Shunt, TCP=Thrombocytopenia (mild: >50.000/μL and severe: <50.000/μL), UGIB=Upper Gastrointestinal Bleeding.

* Patient 1 had complete spleen embolization with Gelfoam and Vascular Plug Implantation 351 days before PSE and Patient 7 had coil-embolization of the splenic artery 653 days before PSE; in both cases PSE was performed due to spleen regeneration. ° complex anatomical condition for transjugular intrahepatic portosystemic shunt placement after liver transplantation * no active bleeding site detectable on computed tomography and/ or endoscopy.

The embolization volume was estimated as proposed by Ou et al.^[18] Ou et al. calculated the diameter ratio of the embolized artery branch(es) to all artery branches of the same order on DSA to predict the embolization volume after PSE, which was confirmed by computer tomographic volume measurements 4 weeks later (see Table, Supplemental Content, Estimation of the embolized spleen volume by Diameter Ratio, <http://links.lww.com/MD/F710>).^[18] Intra-arterial contrast medium was administered in the selective catheter position by hand injection (separate pre- and post-interventional injection of 10 mL Iomeprol 300 mgI/mL; Bracco Imaging, Milan, Italy). Images were acquired at 2 frames per second, with a range of 10 to 30s. Pre- and post-interventional DSA images were acquired in breath-hold in comparable projections. Procedural characteristics like fluoroscopy time, number of DSA runs, Dose-Area-Product, amount of contrast media, particle size and embolization territory of the spleen were recorded (see Table, Supplemental Content, Partial Spleen Embolization - procedural characteristics, <http://links.lww.com/MD/F710>).

2.3. 2D Parametric parenchymal blood flow

DSA series were retrieved from PACS and post-processed on a dedicated workstation (syngo X Workplace VD20B, Siemens Healthcare). Post-processing was done with a newly developed 2D-PPBF prototype algorithm. DSA frames were filtered with a band-reject filter tuned to suppress the vessels. Further visualization and analysis of the parenchymal perfusion can be facilitated without the strong presence of vessels (U.S. Patent 8,848,996). In consensus, 2 radiologists (T.C.M., J.B.H.) agreed upon region-of-interest (ROI) placement: reference ROI in the afferent splenic artery (ROI arterial inflow) and a target ROI outlining the

targeted embolization territory of the spleen (ROI parenchyma), supplied by the aforementioned splenic artery branch (s. Fig. 1A/B). The 2D-PPBF analyses were done on DSA images acquired pre- and post-PSE. The reference ROI was fitted to at least 2 thirds of the artery diameter and placed distal to the tip of the diagnostic catheter to assess arterial contrast inflow. The target ROI was drawn freehand covering the whole embolization territory of the spleen (in most cases the inferior pole of the spleen). Both ROIs drawn on pre-PSE images were copied to the corresponding images acquired post-PSE to ensure that the ROIs were placed in comparable positions (s. Fig. 1A/B). Numeric density values were recorded and the ratios of the target ROI to the reference ROI pre- and post-PSE were calculated for the Wash-In-Rate (WIR), the Time-To-Peak (TTP) and the Area-under-the-Curve (AUC). The WIR represents the rate at which contrast increases from arrival of contrast in the ROI to peak density; the TTP represents the time that contrast intensity first reaches maximum; and AUC comprises the density values in a single ROI throughout the entire angiographic run.

2.4. Statistical analysis

Descriptive statistical analyses of the patient and angiographic data were calculated. The values are presented as mean ± standard deviation. To test our hypothesis that perfusion changes can be assessed with 2D-PPBF, the 2D-PPBF parameters between pre- and post-PSE were compared (WIR_{pre-PSE} / WIR_{post-PSE}; WIR_{ΔPSE}, TTP_{pre-PSE} / TTP_{post-PSE}; TTP_{ΔPSE}, AUC_{pre-PSE} / AUC_{post-PSE}; AUC_{ΔPSE}) using a 2-sided pairwise Wilcoxon signed-rank test. The analysis of the relation between the 2D-PPBF parameters and the outcome parameter pre-PSE was performed with a Spearman rank correlation coefficient. Afterwards, the study

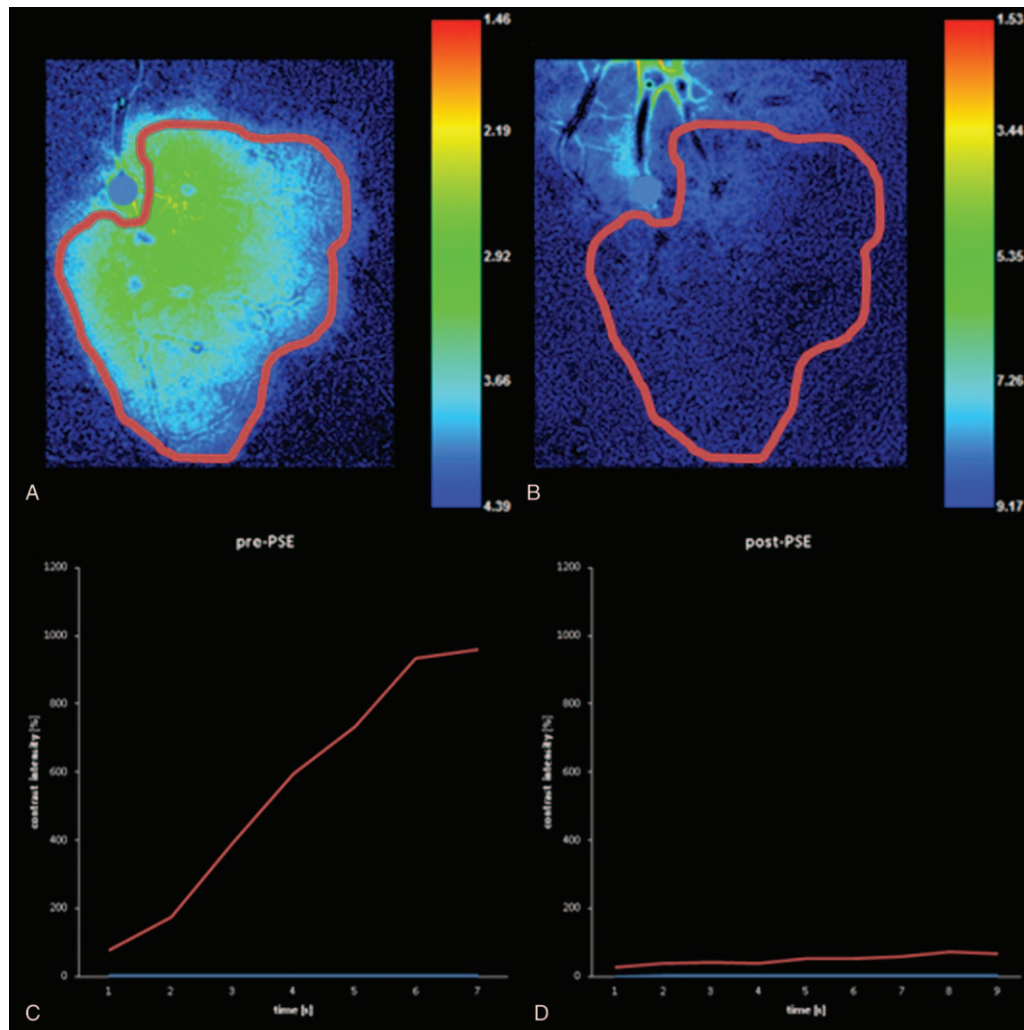


Figure 1. DSA series, 2D-PPBF images and time-density-curves pre- and post-PSE. 2D-Parametric Parenchymal Blood Flow (2D-PPBF) images, derived from the Digital Subtraction Images (DSA), are depicted with colour encoded time-density values for Patient 11. The reference Region-of-Interest (ROI) (blue) is placed within the splenic artery branch and the target ROI (red) is outlining the supplied splenic parenchyma before (A) and after (B) Partial Spleen Embolization (PSE). Pre-PSE (A) there is a high intensity of the splenic parenchyma, whereas post-PSE (B) the intensity of the splenic parenchyma decreased. The splenic artery branches are suppressed by the 2D-PPBF algorithm (A, B). The corresponding time-density-curves pre-PSE (C) and post-PSE (D) are illustrated with the values of the reference ROI (blue) in relation to the values of the target ROI (red) over the time, showing the decrease of the Wash-In-Rate (WIR), the Time-To-Peak (TTP) and the Area-under-the-Curve (AUC) after PSE.

population was divided in 2 subgroups by the median of the $TTP_{pre-PSE}$ in analogy to the platelet clearance from scintigraphy studies.^[19] PR between the subgroups was compared with a 2-tailed Mann-Whitney *U* test to analyze the potential value of the $TTP_{pre-PSE}$ for outcome prediction. A *p* value of <0.05 was defined as significant. Statistical analyses were conducted using commercially available software (SPSS Statistics, Version 25, IBM, New York).

3. Results

3.1. Study population and outcome

The study population consisted of 6 women and 6 men (mean age of 29 ± 12 years) with a mean cranio-caudal diameter of the spleen of 22.2 ± 5.6 cm and a mean PLT of $43,000 \pm 21,405$ platelets/ μ L, characterizing hypersplenism. All patients had esophagogastric varices and were at risk of severe variceal

bleeding without medical, endoscopic or interventional radiologic treatment options other than PSE. There were no other severe adverse events. Following PSE, a statistically significant increase of the PLT from $43,000 \pm 21,405$ platelets/ μ L to $128,500 \pm 66,083$ platelets/ μ L with a positive PR of $255 \pm 243\%$ was observed ($p=0.003$). For details see Table 1 and Supplemental Content (Figures, 1–12 – Platelet change following PSE and Table, Evaluation of platelet refractoriness by Corrected Count Increment, <http://links.lww.com/MD/F710>).

3.2. Partial spleen embolization

Procedural characteristics included a mean fluoroscopy time of 16 ± 17 minutes, a radiation exposure of $7,328 \pm 13,045$ cGym² (cone beam computed tomography excluded) and a mean volume of injected contrast medium was 94 ± 43 mL. Aiming for an embolization volume of less than 50 to 70%, we performed most PSE solely with the embolization position in the inferior splenic

Table 2

2D parametric parenchymal blood flow - parameters.

2D-PPBF parameter	pre-PSE	post-PSE	ΔPSE	Wilcoxon signed-rank test
WIR	1.23 ± 2.24	0.09 ± 0.07	-64% ± 46%	P = .004
TTP	4.41 ± 0.99	5.67 ± 1.52	+34% ± 47%	P = .041
AUC	0.81 ± 0.85	0.14 ± 0.08	-71% ± 18%	P = .002

2D Parametric Parenchymal Blood Flow (2D-PPBF) parameters pre- and post-PSE and percentage changes are tabulated with Mean and Standard Deviation (SD). Level of Significance of the Wilcoxon signed-rank test between pre- and post-PSE data is shown. AUC = area-under-the-curve, TTP = time-to-peak, WIR = wash-in-rate.

artery branch. The target embolization volume was confirmed with a mean and standard deviation of $47 \pm 7\%$ by calculation of the diameter ratio as proposed by Ou et al.^[18] Most frequent particle size was 300–500 μm. For details see Supplemental Content (Table, Partial Spleen Embolization – procedural characteristics and Table, Estimation of the embolized spleen volume by Diameter Ratio, <http://links.lww.com/MD/F710>).

3.3. 2D Parametric parenchymal blood flow

Following PSE, all mean 2D-PPBF parameters - WIR, TTP and AUC - changed significantly. There was a significant difference in $WIR_{pre-PSE} 1.23 \pm 2.42 / WIR_{post-PSE} 0.09 \pm 0.07$; $-64 \pm 46\%$ ($p = 0.004$), $TTP_{pre-PSE} 4.41 \pm 0.99 / TTP_{post-PSE} 5.67 \pm 1.52$ ($P = .041$); $+34 \pm 47\%$ and $AUC_{post-PSE} 0.81 \pm 0.85 / AUC_{pre-PSE} 0.14 \pm 0.08$; $-71 \pm 18\%$ ($P = .002$) (s. Table 2). Therefore, the time-density-curve following PSE is compressed with a decrease of the slope and the maximum of contrast intensity as well as the total amount of contrast (s. Fig. 1C/D). Correlations between the 2D-PPBF parameters to the PLT pre-PSE were not statistically significant, except the correlation of the $TTP_{pre-PSE}$ with the $PLT_{pre-PSE}$ ($r = -0.66$; $P = .01$) (s. Fig. 2 and see Table, Supplemental Content, <http://links.lww.com/MD/F710>, Correlation of 2D Parametric Parenchymal Blood Flow parameters and

Platelet Count). We divided the study population in 2 subgroups by the median $TTP_{pre-PSE}$ of 4.44 to analyze the potential value of $TTP_{pre-PSE}$ for outcome prediction. Patient 2, 3, 5, 8, 11, and 12 had $TTP_{pre-PSE} \leq 4.44$ ($n = 6$), whereas Patient 1, 4, 6, 7, 9 and 10 had $TTP_{pre-PSE} > 4.44$ ($n = 6$). In the subgroup with the rapid $TTP_{pre-PSE}$ of ≤ 4.44 , the PLT increased from $55,500 \pm 22,061$ platelets/μL to $105,166 \pm 31,005$ platelets/μL with a PR of $107 \pm 76\%$ ($P = .04$). In contrast, in the group with the slow $TTP_{pre-PSE}$ of > 4.44 , the PLT increased from $30,500 \pm 12,095$ platelets/μL to $151,833 \pm 85,670$ platelets/μL with a PR of $404 \pm 267\%$ ($P = .02$). Furthermore, the $PLT_{pre-PSE}$ compared between the subgroups was significantly lower in the subgroup with $TTP_{pre-PSE} > 4.44$ ($P = .01$), while the PR was significantly higher than in patients with $TTP_{pre-PSE} \leq 4.44$ ($P = .04$). Comparison of the PLT and PR between the subgroups was summarized in detail in Table 3.

4. Discussion

PSE is a known treatment approach for patients at increased risk of life-threatening bleeding due to hypersplenism and portal hypertension. As shown in our study PLT increased significantly after PSE causing only minor complications like discomfort, pain and fever; these are reported in up to 90% of patients after

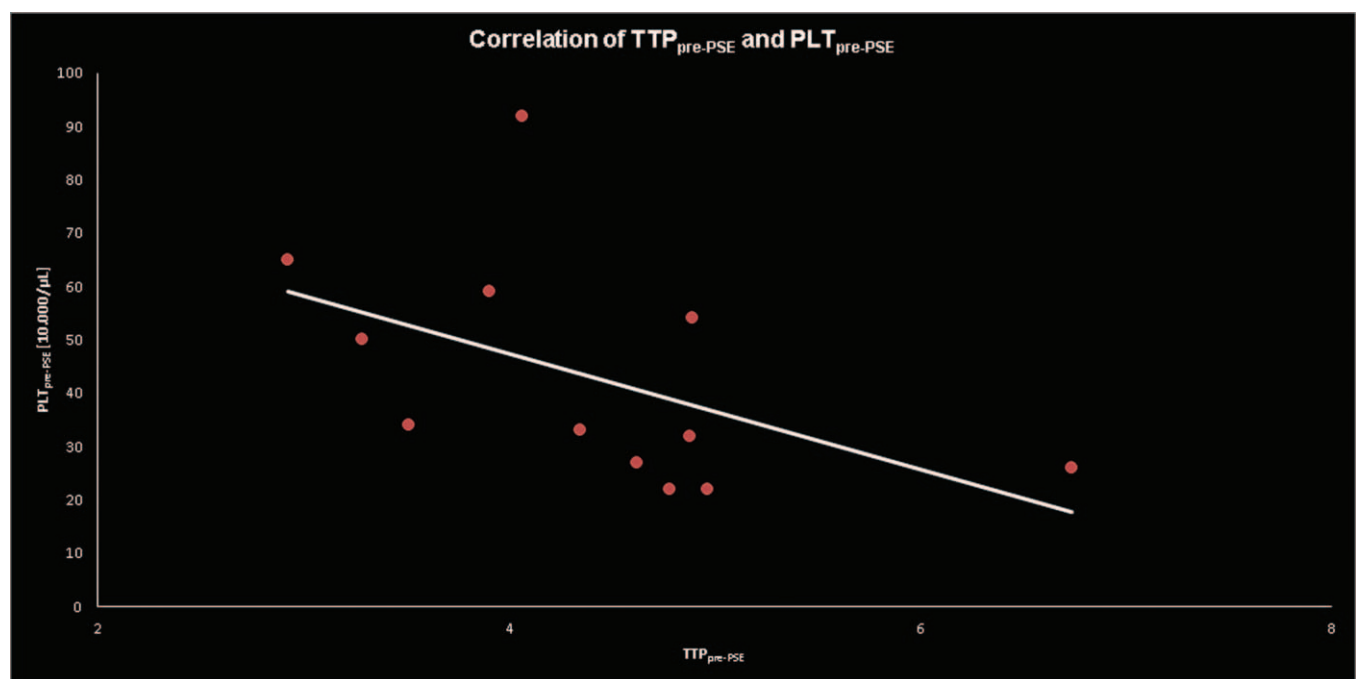


Figure 2. Correlation between Time-To-Peak and Platelet Count prior Partial Spleen Embolization. Correlation between the Time-To-Peak (TTP) and the Platelet Count (PLT) pre-PSE is illustrated. Spearman's rank correlation coefficient is -0.66 with $P = .01$.

Table 3
Time-to-peak and platelet count.

PLT/Subgroups	PLT _{pre-PSE}	PLT _{post-PSE}	PR	Wilcoxon signed-rank test
TTP _{pre-PSE≤4.44}	55.500 ± 22.061 [n=6]	105.166 ± 31.005 [n=6]	+107% ± 76% [n=6]	<i>P</i> = .04
TTP _{pre-PSE>4.44}	30.500 ± 12.095 [n=6]	151.833 ± 85.670 [n=6]	+404% ± 267% [n=6]	<i>P</i> = .02
Mann-Whitney <i>U</i> test	<i>p</i> = 0.01	<i>p</i> = 0.39	<i>p</i> = 0.04	-

Time-To-Peak (TTP) and platelet count (PLT) pre- and post-PSE are tabulated with Mean and Standard Deviation (SD). Study population was divided in two groups by the median of the 2D Parametric Parenchymal Blood Flow Parameter with the best correlation to the outcome parameter: TTP_{pre-PSE} median of 4.44. Level of Significance of the Wilcoxon signed-rank test between pre- and post-PSE data and of the Mann-Whitney *U* test between TTP_{pre-PSE} ≤ 4.44 and > 4.44 are shown. PLT = platelet count in platelets/ μ L, PR = platelet response in percent of the PLT_{pre-PSE}, TTP = time-to-peak.

PSE.^[16] Severe complication, e.g. splenic abscess and septicemia did not occur. This is in line with the reported low rate of severe complications for PSE of about 4% and stands in contrast to CSE or splenectomy with complication rates of about 10%.^[1,2] Regarding efficiency, PLT was significantly increased within 14 days after PSE confirming sufficient embolization. Also, the PR of 255% following PSE is comparable to the publication by Passhak et al., who reported a PR of about 260%.^[6] Considering the patients with indicated platelet refractoriness before PSE (Patient 3 and Patient 6) an uptake following PC post-PSE was shown. This indicates recovered sensitivity to PC and is reported in the literature following splenectomy.^[15] No other patients required further PC administrations after PSE. Patient 5 did not respond to PSE despite embolizing a calculated embolization volume of 54% with 500–700 μ m particles. This might be due to insufficient embolization or due to hepatic accumulation of the platelets.^[8] Furthermore, the limited observation interval of 14 days after PSE might be too short for this particular patient, since later responses have been reported in the literature.^[20]

Radiation exposure with a mean Dose-Area-Product of 7,328 ± 13,045 cGym² and a fluoroscopy time of 16 ± 17 min are comparable to other common abdominal interventions, such as hepatic chemoembolization or embolization of gastrointestinal bleeding (28,232 to 34,737 cGym² and 17 to 26 min).^[21] We used microspheres as permanent embolic agent, because lower recanalization rates and a lower incidence of fever have been described for particles as compared to other embolic agents.^[16] The most common embolization position in our study was the inferior splenic artery branch supplying approximately 40% of the spleen (the inferior spleen territory).^[17] The lowest complication rates have been reported for a spleen infarct volume of less than 50%, thus the approach to embolize the inferior splenic artery seems reasonable.^[2] The estimated embolization volume of 47% in our study is in accordance with the aforementioned findings.

Our feasibility study shows that 2D-PPBF is a suitable approach to analyze perfusion changes of the embolization territory of the spleen after PSE. Technically, 2D-PPBF is a post-processing technique requiring no additional DSA runs, contrast medium applications or radiation exposure.^[9] The WIR, TTP and AUC showed significant changes in the embolized spleen territory following PSE. Usually, parenchymal perfusion during angiographic interventions is assessed on conventional, iodinated contrast angiography by the investigating radiologist with a subjective endpoint of blush reduction.^[6,7] This operator-dependent interpretation is highly subjective resulting in inter- and intra-observer variability.^[22–25] The potential of 2D-PPBF is to objectify the immediate assessment of perfusion changes during angiographic interventions. From the calculated mean density values for the ROI in each frame objective information regarding flow time, maximal values, and rates of flow can be

generated.^[24] In 2D-PPBF greater vessels are suppressed and the pure parenchymal perfusion is depicted.^[9] The decrease of WIR and the AUC after PSE represent the reduced blood flow to the embolized spleen territory and the reduced blood volume in the embolized spleen territory due to the occlusion of the supplying arteries. Furthermore, the ratio of the TTP before PSE shows a significant correlation to the PLT pre-PSE in our study. This negative correlation of the TTP and PLT might best be explained by increased pooling of the platelets in the enlarged spleen due to slow intrasplenic blood flow. Similar results are reported from scintigraphy studies on platelet kinetics, which showed a dependence of splenic platelet pool capacity and the splenic platelet clearance (reciprocal of intrasplenic transit time).^[19] In addition, our subgroup analysis shows a significantly higher PR for patients with TTP > 4.44 compared to patients with TTP ≤ 4.44 pre-PSE (Table 3). Therefore, TTP_{pre-PSE} - in analogy to the platelet clearance and the platelet pooling capacity derived from scintigraphy - might be valuable to estimate the PR during the intervention. Nonetheless, the splenic volume change is the only reported predictive value for the platelet outcome after PSE.^[5] In the studies by Osaki et al. and Ou et al the splenic volume change was determined using CT scans 2 and 4 weeks following PSE.^[5,18] Therefore, the splenic volume change is not a suitable parameter to estimate the PR during the intervention. The TTP_{pre-PSE} derived from 2D-PPBF directly during the procedure might be valuable to estimate PR following PSE. In a study by Zhou et al., the usefulness of TTP to assess endoleak related adverse events following endovascular aortic repair was reported.^[26] Zhou et al. showed that complication rates correlate with a fast filling of the aneurysm sack as measured by a fast TTP indicating the potential benefit of peri-interventional flow and perfusion measurements.^[26] Considering patients with hypersplenism, a high pre-interventional TTP might represent a slow intrasplenic blood flow, leading to increased sequestration and pooling of platelets in the spleen. Therefore, the evaluation of patients or even of the different arterial territories of the spleen using TTP_{pre-PSE} might be valuable to optimize treatment response. Depending on the TTP_{pre-PSE}, adjustments of the embolization volume and/or the optimal catheter position(s) in the splenic artery branch(es) might be able to achieve the optimal predictable response. After PSE, the perfusion reduction in the embolized splenic territory can be assessed by 2D-PPBF. If the predicted PR is not sufficient, the PSE can be extended to further arterial territories of the spleen. The residual platelet pooling capacity of the untreated splenic territories can be evaluated by the TTP. Depending on the TTP the interventional radiologist is able to decide the extension of the embolization volume to achieve the desired response. However, the value of 2D-PPBF for outcome prediction and monitoring of perfusion changes needs to be confirmed in a larger study. To further improve interventional flow analysis machine learning approaches as already reported for analysis of coronary

computed topographies to assess the fractional flow reserve might be beneficial and need to be evaluated.^[27,28]

Our study has some limitations. First, our retrospective study is based on a relatively small number of patients undergoing PSE at our tertiary medical referral center. Follow-up analysis was conducted at secondary and primary health care centers without acquisition of cross-sectional imaging. A larger study population, included in a multi-centric and prospective study design with long-term follow-up, needs to be considered to further assess the potential of 2D-PPBF and to define objective, standardized angiographic endpoints as well as possible cut-off values for PSE. Therefore, clinical trials are needed to evaluate and assess the clinical impact of 2D-PPBF on the reduction of platelet transfusions and the duration of treatment- or bleeding-free intervals. Moreover, we examined a distinct subset of arterial territories (the upper, middle or inferior splenic artery branch) but not the entire spleen. Although the mean estimated embolization volume was 47%, the exact volume of infarction was not evaluated. Since the PR depends on the volume of embolized spleen tissue, it would be interesting to correlate the PR with the 2D-PPBF parameter changes in combination with the measured volume change of the perfused spleen (e.g. via segmentation on cone beam computed tomography after PSE^[29]). Unfortunately, this was not standard in our institution in this retrospective study.

5. Conclusion

Our study demonstrates the feasibility of 2D-PPBF to assess the perfusion changes of embolized splenic tissue in patients with portal hypertension and hypersplenism undergoing PSE. As a post-processing modality for functional imaging 2D-PPBF provides an objective approach to peri-interventionally monitor the embolization. Furthermore, TTP derived from 2D-PPBF has the potential to estimate PR during PSE and might serve as a predictor for platelet increase following PSE.

Acknowledgments

The authors would like to thank John Baumgart and Anke Siebert for technical support. The authors Bernhard C. Meyer and Frank K. Wacker declare relationships with Siemens Healthcare and ProMedicus (outside the submitted work). The remaining authors of the manuscript declare no relationships with any companies whose products or services may be related to the subject matter of the article.

Author contributions

Conceptualization: Timo C Meine, Cornelia LA Dewald, Bernhard C Meyer, Jan B Hinrichs.

Data curation: Timo C Meine, Sabine K. Maschke, Becker S Lena, Cornelia LA Dewald, Thomas Werncke, Jan B Hinrichs.

Formal analysis: Timo C Meine, Sabine K. Maschke, Becker S Lena, Martha M Kirstein, Thomas Werncke, Jan B Hinrichs.

Funding acquisition: Timo C Meine, Martha M Kirstein, Cornelia LA Dewald, Jan B Hinrichs.

Investigation: Timo C Meine, Sabine K. Maschke, Becker S Lena, Martha M Kirstein, Cornelia LA Dewald, Thomas Werncke, Bernhard C Meyer, Jan B Hinrichs.

Methodology: Timo C Meine, Becker S Lena, Martha M Kirstein, Elmar Jaeckel, Thomas Werncke, Jan B Hinrichs.

Project administration: Timo C Meine, Becker S Lena, Elmar Jaeckel, Cornelia LA Dewald, Jan B Hinrichs.

Resources: Timo C Meine, Cornelia LA Dewald, Jan B Hinrichs.

Software: Timo C Meine, Jan B Hinrichs.

Supervision: Timo C Meine, Elmar Jaeckel, Frank K Wacker, Bernhard C Meyer, Jan B Hinrichs.

Validation: Martha M Kirstein, Frank K Wacker, Bernhard C Meyer, Jan B Hinrichs.

Visualization: Becker S Lena, Frank K Wacker, Bernhard C Meyer, Jan B Hinrichs.

Writing – original draft: Timo C Meine, Jan B Hinrichs.

Writing – review and editing: Sabine K. Maschke, Becker S Lena, Martha M Kirstein, Elmar Jaeckel, Cornelia LA Dewald, Thomas Werncke, Frank K Wacker, Bernhard C Meyer, Jan B Hinrichs.

References

- [1] Madoff DC, Denys A, Wallace MJ, et al. Splenic arterial interventions: anatomy, indications, technical considerations, and potential complications. *RadioGraphics* 2005;25(suppl_1):S191–211.
- [2] Haddock TA. Partial splenic artery embolization in cirrhotic patients. *World J Radiol* 2014;6:160.
- [3] Barron N, Arenas-Osuna J, Medina G, et al. Splenectomy in systemic lupus erythematosus and autoimmune hematologic disease: a comparative analysis. *Clin Rheumatol* 2018;37:943–8.
- [4] Togasaki E, Shimizu N, Nagao Y, et al. Long-term efficacy of partial splenic embolization for the treatment of steroid-resistant chronic immune thrombocytopenia. *Ann Hematol* 2018;97:655–62.
- [5] Osaki A, Suda T, Waguri N, et al. Formula to predict platelet count after partial splenic arterial embolization in patients with hypersplenism. *J Vasc Interv Radiol* 2012;23:900–7.
- [6] Passhak M, Shachar SS, Ofer A, et al. Partial splenic embolization in the treatment of prolonged thrombocytopenia due to hypersplenism in metastatic cancer patients. *Supportive Care Cancer* 2018;26:3527–32.
- [7] Nassef AA, Zakaria AA, Abd ElBary MS. Partial splenic artery embolization in portal hypertension patients with hypersplenism: Two interval-spaced sessions' technique. *Egypt J Radiol Nucl Med* 2013;44:531–7.
- [8] Uchida Y, Minoshima S, Miyazaki M, et al. Normalized spleen/liver ratios on ¹¹¹In-labelled platelet scintigraphy to predict the outcome of partial splenic embolization in patients with idiopathic thrombocytopenic purpura. *Nucl Med Commun* 2000;21:441–7.
- [9] Maschke SK, Winther HMB, Meine T, et al. Evaluation of a newly developed 2D parametric parenchymal blood flow technique with an automated vessel suppression algorithm in patients with chronic thromboembolic pulmonary hypertension undergoing balloon pulmonary angioplasty. *Clinical Radiology [Internet]* 2019;74:437–444.
- [10] Hinrichs JB, Murray T, Akin M, et al. Evaluation of a novel 2D perfusion angiography technique independent of pump injections for assessment of interventional treatment of peripheral vascular disease. *Int J Cardiovasc Imaging* 2017;33:295–301.
- [11] Maschke SK, Renne J, Werncke T, et al. Chronic thromboembolic pulmonary hypertension: evaluation of 2D-perfusion angiography in patients who undergo balloon pulmonary angioplasty. *Eur Radiol* 2017;27:4264–70.
- [12] Maschke SK, Werncke T, Klöckner R, et al. Quantification of perfusion reduction by using 2D-perfusion angiography following transarterial chemoembolization with drug-eluting beads. *Abdom Radiol* 2018;43:1245–53.
- [13] Almadidy Z, Brunozzi D, Nelson J, et al. Intracranial venous sinus stenosis: hemodynamic assessment with two-dimensional parametric parenchymal blood flow software on digital subtraction angiography. *J NeuroIntervent Surg* 2020;12:311–4.
- [14] Davis KB, Slichter SJ, Corash L. Corrected count increment and percent platelet recovery as measures of posttransfusion platelet response: problems and a solution. *Transfusion* 1999;39:586–92.
- [15] Slichter SJ. Factors affecting posttransfusion platelet increments, platelet refractoriness, and platelet transfusion intervals in thrombocytopenic patients. *Blood* 2005;105:4106–14.

- [16] Guan Y-S, Hu Y. Clinical application of partial splenic embolization. *ScientificWorldJournal* 2014;2014:1–9.
- [17] Ignjatovic D, Bergamaschi R. Anatomical rationale for spleen salvage by lobe/segment dearterialization in inferior pole spleen injury during left hemicolectomy: a post-mortem study. *Tech Coloproctol* 2002;6:93–6.
- [18] Ou M-C, Chuang M-T, Lin X-Z, et al. A novel method for the angiographic estimation of the percentage of spleen volume embolized during partial splenic embolization. *Eur J Radiol* 2013;82:1260–5.
- [19] Peters AM, Saverymuttu SH, Wonke B, et al. The interpretation of platelet kinetic studies for the identification of sites of abnormal platelet destruction. *Br J Haematol* 1984;57:637–49.
- [20] Wu B-G, Chou A-B, Ho G-J, et al. Eighty percent partial splenic embolization is a safe and effective procedure in management of cirrhotic hypersplenism. *Formosan J Surg* 2017;50:101.
- [21] Miller DL, Balter S, Cole PE, et al. Radiation doses in interventional radiology procedures: the RAD-IR study part I: overall measures of dose. *J Vascul Interv Radiol* 2003;14:711–27.
- [22] Wang J, Cheng J-J, Huang K-Y, et al. Quantitative assessment of angiographic perfusion reduction using color-coded digital subtraction angiography during transarterial chemoembolization. *Abdom Radiol* 2016;41:545–52.
- [23] Reekers JA, Koelemay MJW, Marquering HA, et al. Functional imaging of the foot with perfusion angiography in critical limb ischemia. *Cardiovasc Intervent Radiol* 2016;39:183–9.
- [24] Murray T, Rodt T, Lee MJ. Two-dimensional perfusion angiography of the foot: technical considerations and initial analysis. *J Endovasc Ther* 2016;23:58–64.
- [25] Kim AH, Shevitz AJ, Morrow KL, et al. Characterizing tissue perfusion after lower extremity intervention using two-dimensional color-coded digital subtraction angiography. *J Vasc Surg* 2017;66:1464–72.
- [26] Zhou M, Su Z, Shi Z, et al. Application of color-coded quantitative digital subtraction angiography in predicting the outcomes of immediate type I and type III endoleaks. *J Vasc Surg* 2017;66:760–7.
- [27] Gao Z, Wang X, Sun S, et al. Learning physical properties in complex visual scenes: an intelligent machine for perceiving blood flow dynamics from static CT angiography imaging. *Neural Netw* 2020;123:82–93.
- [28] Itu L, Rapaka S, Passerini T, et al. A machine-learning approach for computation of fractional flow reserve from coronary computed tomography. *J Appl Physiol* 2016;121:42–52.
- [29] Ishikawa T, Imai M, Okoshi M, et al. Cone beam versus conventional computed tomography angiography volume measurement in partial splenic embolization. *Medicine* 2019;98:e14312.