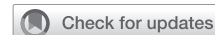

## PEYRONIE'S DISEASE

## The Effectiveness of 3-D Computed Tomography in the Evaluation of Penile Deformities in Patients With Peyronie's Disease: A Pilot Study



Abdulkadir Özmez, MD,<sup>1</sup> Mazhar Ortac, MD, FEBU,<sup>1</sup> Gokhan Cevik, MD,<sup>2</sup> Hakan Akdere, MD,<sup>2</sup> Barış Bakır, MD,<sup>3</sup> and Ateş Kadioglu, MD, FESCM<sup>3</sup>

## ABSTRACT

**Background:** Anatomic and functional evaluation of the penis before treatment is very important in the choice of treatment in patients with Peyronie's disease (PD).

**Aim:** To compare 3 different methods for the evaluation of the penile deformity, including auto-photography, combined intracavernous injection stimulation test (CIS), and 3-dimensional computed tomography (3D CT) during artificial penile erection in patients with PD.

**Methods:** Pretreatment penile deformities of patients with PD were compared with those detected with auto-photography, using goniometer after intracavernosal vasoactive agent, and 3D CT correlations among these 3 methods were investigated.

**Main Outcome Measures:** Assessments of penile curvature with auto-photography, CIS, and 3D CT.

**Results:** The mean age of 36 patients who were included in the study was  $58 \pm 8.25$  (36–72) years, and the mean time since the onset of the disease was  $25 \pm 24$  months (2–144). Degrees of penile curvatures measured using auto-photography, CIS, and CT were determined as  $24^\circ$  ( $0^\circ$ – $80^\circ$ ),  $40^\circ$  ( $0^\circ$ – $90^\circ$ ), and  $34^\circ$  ( $0^\circ$ – $80^\circ$ ), respectively. When general correlation analysis was performed to evaluate the penile curvatures of all patients using 3 methods, a moderate correlation between auto-photography and both CIS ( $r = 0.72$ ,  $P < .001$ ) and 3D CT ( $r = 0.56$ ,  $P < .001$ ) was detected, whereas a strong correlation was noticed between CIS and 3D CT ( $r = 0.78$ ,  $P < .001$ ). When the correlation analysis between patients with and without ED was examined, a statistically significant decrease in the strength of correlation between CIS and auto-photography in patients with ED (0.629 vs 0.925,  $P < .05$ ), however, was detected without any statistically significant difference in patients without ED (0.694 vs 0.813,  $P > .05$ ).

**Conclusion:** The superiority of 3D CT over auto-photography and its strong correlation with CIS in most parameters have been demonstrated. However, it was found that CT did not give more information than the evaluation with CIS. Current limitations and cost increases limit the use of 3D CT in the assessment of PD.

**Özmez A, Ortac M, Cevik G, et al. The Effectiveness of 3-D Computed Tomography in the Evaluation of Penile Deformities in Patients With Peyronie's Disease: A Pilot Study. Sex Med 2019;7:311–317.**

Copyright © 2019, The Authors. Published by Elsevier Inc. on behalf of the International Society for Sexual Medicine. This is an open access article under the CC BY-NC-ND license (<http://creativecommons.org/licenses/by-nc-nd/4.0/>).

**Key Words:** Deformity; Penile Curvature; Peyronie's Disease

Received February 19, 2019. Accepted June 16, 2019.

<sup>1</sup>Department of Urology, Istanbul Faculty of Medicine, Istanbul University, Istanbul, Turkey;

<sup>2</sup>Department of Urology, Trakya University, Medical Faculty, Edirne, Turkey;

<sup>3</sup>Department of Radiology, Istanbul Faculty of Medicine, Istanbul University, Istanbul, Turkey

Copyright © 2019, The Authors. Published by Elsevier Inc. on behalf of the International Society for Sexual Medicine. This is an open access article under the CC BY-NC-ND license (<http://creativecommons.org/licenses/by-nc-nd/4.0/>).

<https://doi.org/10.1016/j.esxm.2019.06.009>

Sex Med 2019;7:311–317

## INTRODUCTION

Peyronie's disease (PD) is an acquired benign disease characterized by the formation of fibrous collagen plaques on the tunica albuginea of the penis.<sup>1</sup> PD is characterized by penile pain, nodules (plaques), penile deformity, and erectile dysfunction (ED). Penile deformity may be in the form of penile curvature, penile shortening, notching, or hourglass deformity.<sup>2</sup>

When the treatment algorithm of PD is considered, surgical treatment is recommended in patients in chronic phase of the disease, patients whose penile deformity precludes sexual

intercourse, or in patients with ED.<sup>3</sup> Reconstructive surgeries are recommended for patients with good erectile capacity, but penile prosthesis implantation is recommended in patients with ED refractory to medical treatment. In the selection of reconstructive surgery, in patients with adequate penile length and mild–moderate curvature, shortening procedures are applied, for patients with good erectile capacity, whereas in cases with a severe degree of curvature or complex deformity, penile lengthening procedures are applied. Surgical technique should be optimal in terms of its psychological, anatomic, and functional outcomes.<sup>4</sup> The type and degree of deformity, the size of the penis, the presence of notching, and the preoperative capacity of erectile function have been reported in the literature as criteria for the selection of the correct surgical approach.<sup>5</sup>

Anatomic and functional evaluation of the penis before treatment is very important in the choice of the treatment.<sup>6</sup> The most critical part of the role of the urologist during the preoperative phase is to establish appropriate expectations for the patient, to achieve high success in reconstruction, and to obtain sufficient foresight concerning the possible complications related to the operation.<sup>4</sup>

Evaluation of penile curvature can be performed by several methods, and it may be based on the patient's own statement, evaluation of the photos taken by the patients or goniometric measurements obtained after intracavernosal injection (ICI) or application of vacuum erection device (VED).<sup>6</sup> Therefore, the presence of an objective method to minimize patient and physician factors may be useful in pretreatment planning.<sup>4,6</sup> In addition, 3-dimensional (3D) evaluation of preoperative penile anatomy in surgical candidates would provide optimal planning of the surgery to be performed.

The effectiveness of radiologic methods in the assessment of PD has been evaluated in several studies.<sup>7</sup> In a comparative study between magnetic resonance imaging and ultrasonography (US), plaque detection rates of both methods were similar (68.2% vs 61.2%,  $P = .083$ ), but magnetic resonance imaging was found to be superior in detecting especially non-clear deformities (waisting).<sup>8</sup>

The ideal evidence-based method for the evaluation of penile deformity has not yet been defined. The degree of recommendation of the methods used for penile deformity is low.<sup>4,9</sup> Pre-treatment penile deformities of patients with PD were compared with those detected with auto-photography at home, using goniometer post-combined with injection and stimulation (CIS), and 3D computed tomography (CT), and correlations among these 3 methods were investigated.

## MATERIALS AND METHODS

The local ethics committee approved this study (No:131/2018), and all patients were competent and willing to give informed consent to participate in the study. A total of 36 patients aged 18–75 years with a diagnosis of PD were included in the study. Patients'

age, comorbid diseases (diabetes mellitus, hypertension, ischemic heart disease, hyperlipidemia), BMI, American Society of Anesthesiologists scores were recorded, PD-specific parameters such as degrees of penile curvature, the presence of plaque and complex deformity and duration of disease were evaluated. According to the International Index of Erectile Function—Erectile Function domain (IIEF-5) scale scores, the patients were grouped as healthy individuals (26–30), and patients with mild (17–25), moderate (11–16), and severe ED (0–10).<sup>10</sup>

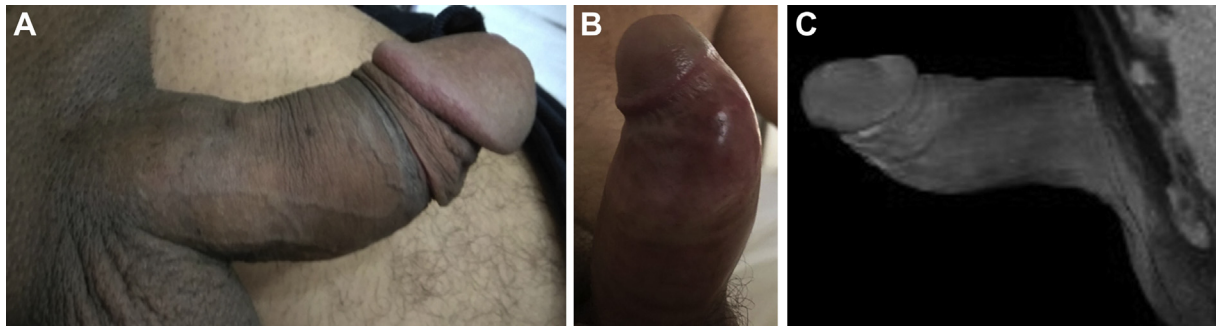The patients with PD were categorized as those with the right ( $n = 6$ ; group 1), left ( $n = 6$ ; group 2), ventral ( $n = 6$ ; group 3), dorsal curvature ( $n = 12$ ; group 4), and complex deformity with notching ( $n = 6$ ; group 5). Patients with biplanar deformity were excluded from the study. The evaluation of penile deformity was performed using the 3 methods, and correlations among them were investigated.

## Application Protocols of The Methods Used

Auto-photography is a 3D (from the top, both sides, and en face) self-photographing of the patient's own penis in the maximal erection, as described by Alpay Kelami.<sup>11</sup> With this method, the penis can only be evaluated in two dimensions. In this study, the type of penile deformity and angle of curvature were evaluated in PD patients using auto-photography by patient's own penis in the maximal erection at their home (Figure 1A). As the second method, artificial erection is described, as examinations, and measurements performed after intracavernosal vasoactive agent (papaverine) injection, together with manual and visual-sexual stimulation (combined with injection and stimulation[CIS]) under office conditions (Figure 1B). The final method has been defined as the evaluation of images obtained with non-contrast penile 3D-CT reconstruction. In the 3D-CT method, the patient receives an intracavernosal vasoactive agent (papaverine) injection (Figure 1C and Figure 2). The type and angle of the deformity, length of the penis, and its short and long sides and circumference measured from the notch, proximal, and the distal part of the notch were evaluated

## Statistics

In descriptive statistics, continuous data were expressed with the mean and standard deviation values. For statistical comparison of categorical data, the  $\chi^2$  test was used. Fitness to a normal distribution for continuous data was evaluated by Kolmogorov-Smirnov analysis, and the Kruskal Wallis test was used for independent group comparisons. Combined change in continuous data was evaluated using Spearman's correlation analysis. Correlation groups were classified as follows: lack of correlation (0%–24%), weak (23%–49%), moderately strong (50%–74%), strong (75%–84%), and very strong (95%–100%) correlations. A  $P$  value  $< .05$  was considered statistically significant with 95%CI. The SPSS v 22.0 (SPSS Statistics, IBM, Armonk, NY, USA) program was used for statistical analysis.



**Figure 1.** Panel A shows auto-photograph of a patient with Peyronie's disease (PD). Panel B shows assessment of PD with goniometry after intracavernosal injection. Panel C shows computed tomography scan of a patient with PD.

## RESULTS

The mean age of 36 patients who were included in the study was  $58 \pm 8.25$  (36–72) years and the mean time since the onset of the disease was  $25 \pm 24$  months (2–144). 9 patients (25%) had active and 27 (75%) patients had chronic PD. A comparison of the demographic data of the 5 groups is shown in [Table 1](#). There was no statistically significant difference among the groups in terms of age, duration of PD, BMI, American Society of Anesthesiologists score, the presence of additional disease, and palpable plaque, and IIEF-5 scores. According to IIEF-5

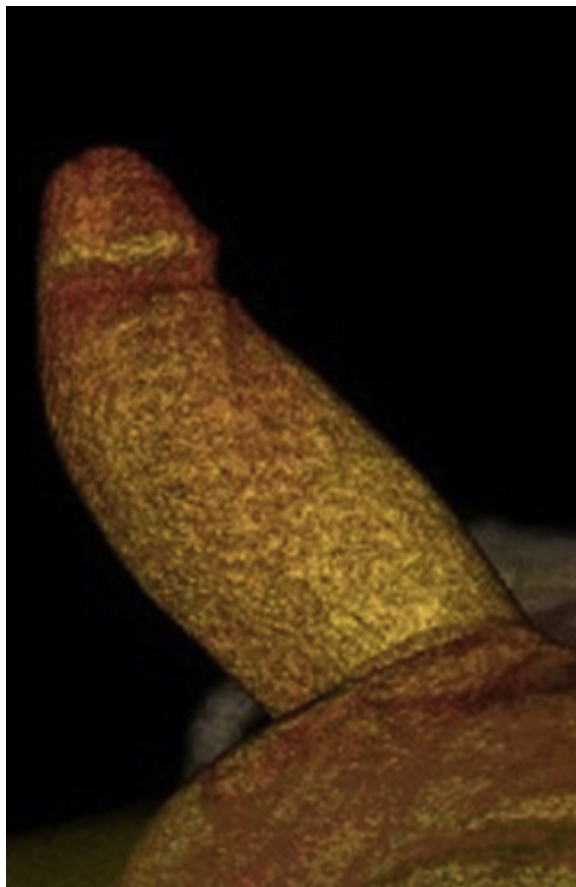
classification 30 (83.4%) patients had erectile dysfunction including cases with mild ( $n = 22$ ; 61.1%), moderate ( $n = 4$ ; 10%), and severe ED ( $n = 4$ ; 10%).

Degrees of penile curvatures measured using auto-photography, CIS, and CT were determined as  $24^\circ$  ( $0^\circ$ – $80^\circ$ ),  $40^\circ$  ( $0^\circ$ – $90^\circ$ ), and  $34^\circ$  ( $0^\circ$ – $80^\circ$ ), respectively. When general correlation analysis was performed to evaluate the penile curvatures of all patients using 3 methods, a moderate correlation between auto-photography and both CIS ( $r = 0.72$ ,  $P < .001$ ) and CT ( $r = .56$ ,  $P < .001$ ) was detected, whereas a strong correlation was noticed between CIS and CT ( $r = 0.78$ ,  $P < .001$ ) ([Table 2](#)). Evaluation of curvature measurements according to group is shown in [Table 3](#).

Correlation analysis of evaluation methods was also performed according to the direction of the deformity, and a strong relationship was detected only between auto-photography and CIS in terms of dorsal and left-sided curvatures ( $r = 0.77$ ,  $P = .03$ , and  $r = 0.82$ ,  $P = .047$ , respectively). Although a very strong correlation was observed between CIS and CT with respect to ventral and right-sided curvature ( $r = 0.94$ ,  $P = .005$ , and  $r = 0.94$ ,  $P = .03$ , respectively), a strong correlation was noted between ventral and left-sided curvatures ( $r = 0.79$ ,  $P = .01$ ), and a moderate correlation between ventral and dorsal curvatures ( $r = 0.68$ ,  $P = .02$ ).

When the correlation analysis between patients with and without ED was examined, a statistically significant decrease in the strength of correlation between CIS and autography in patients with ED (0.629 vs 0.925,  $P < .05$ ) was detected without any statistically significant difference. It was observed that the decrease between CIS and CT did not reach a statistically significant level (0.694 vs 0.813,  $P > .05$ ) ([Table 4](#)).

When the patients with complex deformities (group 5) were evaluated using all 3 methods, notching deformity was detected by CIS in all patients ( $n = 6$  [100%]), whereas notching deformities were revealed with CT ( $n = 5$  [83%]) and auto-photographs ( $n = 4$  [67%]) in a scarce number of patients. However, the measurement of penile thickness was possible only with CT and CIS. Measurements with CIS from the notching, and its proximal and distal parts were 10.7 (9–12) cm, 12 (10–13) cm, and 11 (11–13) cm, respectively, whereas the



**Figure 2.** 3-Dimensional computed tomography scan of a patient with Peyronie's disease.

**Table 1.** A comparison of the demographic data of the 5 groups

Parameter	Group 1 (right-sided curvature) N = 6	Group 2 (left-sided curvature) N = 6	Group 3 (ventral curvature) N = 6	Group 4 (dorsal curvature) N = 12	Group 5 (deformity and notching) N = 6	P value
Age mean ( $\pm$ SD)	62 (5.7)	57 (6.2)	55 (9.5)	57 (9.8)	59 (7.9)	.59
Duration of PD, mos (mean $\pm$ SD)	14.5 (7.9)	19.1 (9.6)	34.6 (53)	27.6 (12.9)	24 (18.9)	.25
BMI (kg/m <sup>2</sup> )	26.5 (1.32)	26.6 (3.7)	26.8 (2.9)	26.4 (2.8)	25.9 (2.4)	.832
ASA score						.665
I	1 (16.7%)	2 (33.3%)	2 (33.3%)	6 (50%)	3 (50%)	
II	2 (33.3%)	3 (50%)	3 (50%)	5 (41.7%)	1 (16.7%)	
III	3 (50%)	1 (16.7%)	1 (16.7%)	1 (8.3%)	2 (33.3%)	
Comorbidity, n(%)						N/A
DM	2	1	3	2	1	
HT	3	1	—	1	1	
IHD	1	—	1	1	—	
HL	1	1	—	2	2	
Hypothyroidism	1	—	—	—	—	
Smoking, n(%)	4 (66.7%)	—	—	4 (33.3%)	2 (33.3%)	.225
Palpable plaque, n(%)	4 (66.7%)	2 (33.3%)	5 (83.3%)	8 (66.7%)	3 (50%)	.329
Painful erection, n(%)	6 (100%)	2 (33.3%)	4 (66.7%)	1 (8.3%)	1 (16.7%)	.04
IIEF-5	19 (6.3)	22.3 (3.1)	21.5 (5.5)	22.6 (3.7)	19.6 (6.8)	.817

ASA = American Society of Anesthesiologists; DM = diabetes mellitus; HL = hyperlipidemia; HT = hypertension; IHD = ischemic heart disease; IIEF-5 = International Index of Erectile Function–5-Item Version; PD = Peyronie disease.

corresponding measurements made with CT were 9.8 (8-12) cm, 11 (9-12) cm and 10.2 (8-11) cm, respectively. The median circumference value measured from the notching deformity was 0.4 cm less relative to measurements made from the proximal notch, as revealed with CIS and CT. Median measurements of the penile circumference made with CIS and CT from proximal and distal parts of the notching differed slightly (0.8 and 0.9 cm, respectively). Measurements of penile circumference from these 3 locations with CT yielded lower values compared with CIS. (Table 5).

## DISCUSSION

The mean age of patients with PD has been reported as  $54 \pm 24$  years (range 21–79 years) in the literature.<sup>12</sup> In this study, the mean age of the patients was  $58 \pm 8.25$  (36–72) years, consistent with the literature.<sup>2</sup> A small number of studies have evaluated penile deformity in patients with PD. However, the evaluation of penile deformity constitutes the most critical step in

the selection of treatment options.<sup>6</sup> Plication methods are recommended for patients with low-grade curvature, whereas penile prosthesis implantation is advised for patients with severe curvature, according to indications of graft surgeries or erectile capacity of the patient.<sup>4</sup>

In a study where 23 articles published within the last 15 years were reviewed, the degree of curvature had been measured after cavernosal injection in 78% of the articles included and after application of a vacuum erection device in 9%. In 61% of the articles, auto-photographing was used with other methods, whereas in 13% of them curvature was detected using only auto-photographing.<sup>13</sup> In the study by Bacal et al,<sup>14</sup> the authors compared the degree of penile curvature in patients with PD based on the patients' estimation and ICI measurements. According to the results of the study, 52% of the patients overestimated and 26% underestimated their penile curvatures, whereas 20% of them accurately predicted degrees of their penile curvatures. 44% of the patients who made erroneous predictions overestimated their degree of curvature by  $>20^\circ$ .<sup>14</sup>

**Table 2.** General correlation analysis to evaluate the penile curvatures of all patients using 3 methods

	Spearman's test	Auto-photography	CIS	CT
Auto-photography	Correlation coefficient	1.000	0.722	0.568
CIS	Correlation coefficient	0.722	1.000	0.786

CIS = combined intracavernous injection and stimulation test; CT = computed tomography.



**Table 3.** Evaluation of curvature measurements according to subgroups

	Correlation analysis			
	Dorsal	Ventral	Right-sided	Left-sided
Photo-CIS	0.77 ( <i>P</i> = .03)	0.71 ( <i>P</i> =.1)	0.50 ( <i>P</i> = .3)	0.82 ( <i>P</i> = .047)
Photo -CT	0.27 ( <i>P</i> = .4)	0.89 ( <i>P</i> = .016)	0.50 ( <i>P</i> = .3)	0.66 ( <i>P</i> = .15)
CIS-CT	0.68 ( <i>P</i> =.02)	0.94 ( <i>P</i> = .005)	0.94 ( <i>P</i> = .03)	0.79 ( <i>P</i> = .01)

CIS = combined intracavernous injection and stimulation test; CT = computed tomography.

The International Society for Sexual Medicine Guideline on Peyronie’s Disease recommends that the first evaluation of the patient at admission should be performed with digital auto-photographing (clinical principle) and then using ICI before an invasive intervention (expert opinion).<sup>4</sup>

Auto-photography is described as Kelami’s<sup>11</sup> technique, based on the principle of the patient’s self-photographing his erect penis from above, sides, and en face. The sociocultural level of the patient, and taking photos of the erect penis from each side, and en face create technical difficulties in obtaining satisfactory photos. Furthermore all patients may not able to reach the maximum erection at home while taking a photo. Therefore, the curvature degree may be underestimated when the auto-photographic method is used. In this study, only small degrees of penile deformities could be detected based on auto-photographic measurements in comparison with CIS and CT measurements. Penile curvature scores recorded for measurements based on auto-photography, CIS and CT were 0°–80° (24°), 0°–90° (40°), and 0°–80° (34°), respectively.

In addition, the degree of penile deformities with CT was smaller than with CIS (34° vs 40°). The differences may be related to the environmental issue (CT room) and a lack of self penile stimulation during 3D CT; consequently, maximal penile rigidity may not be reached in these patients.

**Table 4.** Correlation analysis between patients with and without ED

Correlation coefficient	Spearman test		
	Auto-photography	CIS	CT
Correlation analysis (angle of the deformity) ED(-)			
Auto-photography	1.000	0.925	0.672
CIS	0.925	1.000	0.813
Correlation analysis (angle of the deformity) (ED+)			
Auto-photography	1.000	0.629	0.552
CIS	0.629	1.000	0.694

CIS = combined intracavernous injection and stimulation test; CT = computed tomography; ED (+) = presence of erectile dysfunction; ED (-) = no erectile dysfunction.

In current studies, it has been shown that the degree of curvature has been underestimated when the auto-photographic method was used in comparison with measurements obtained after cavernosal injection. It has been reported that the appropriate type of surgery to be applied to the patient may not be optimally determined with the auto-photographic method.<sup>15</sup>

When all 3 methods were compared using general correlation analysis, a moderately strong correlation was detected between auto-photography and CIS, whereas a strong correlation was observed between CIS and CT. Correlation analysis of evaluation methods according to direction of the deformity revealed a strong relationship between auto-photography and CIS for only dorsal and left deformities. Measurements made with CIS and CT were strongly correlated in the evaluation of ventral and right- and left-sided deformities, although they were moderately correlated in the evaluation of dorsal deformities.

Because any other penile deformity evaluation method has not been described in the literature, the most frequently used CIS method, whose superiority over auto-photography has been demonstrated, was considered as a gold standard in this study.<sup>6</sup> When CIS was taken as a gold standard method, we concluded that CT is very reliable in the group with ventral and right-sided deformities, although it may be used reliably in the group with left-sided curvatures.

Ohebshalom et al<sup>16</sup> compared the 3 most frequently used methods of penile curvature measurement methods (auto-photography at home, VED, and intracavernosal injection method). They have shown that penile curvature measurements after ICI was more accurate than those obtained with auto-photography and VED measurements. They indicated that, in patients with good erectile function capacity and mild degrees of penile curvature, the auto-photography method may be used. However, they stated that the VED may mask the degree of curvature, because it causes erection by creating venous compression.<sup>16</sup>

The presence of ED is another important parameter that affects the surgical decision in PD.<sup>17</sup> In this study, when the patients were separated according to their erectile functions and then their penile deformities were compared using all 3 methods, it was found that the correlation between auto-photography and CIS decreased in the presence of ED. The results were found to be consistent with the current literature, and CT measurements were detected to be closer to those of CIS rather than

**Table 5.** Evaluation of patients complex deformity and notching

Parameters	Group 5 (Deformity and notching) N = 6
Measurement with auto-photography	
Presence of notching	4 (66.7%)
Measurements with CIS technique	
Presence of notching	6 (100%)
Penile circumference measured from notching	10.7 (1.21)
Penile circumference measured from a point proximal to the notching	12 (0.89)
Penile circumference measured from a point distal to the notching	11.2 (1.16)
Measurements with CT technique	
Presence of notching	5 (83.3%)
Penile circumference measured from notching	9.8 (4.02)
Penile circumference measured from a point proximal to the notching	11 (4.56)
Penile circumference measured from a point distal to the notching	10.1 (4.31)

CIS = combined intracavernous injection and stimulation test; CT = computed tomography.

auto-photography. In a similarly designed study published by Ohebshalom et al,<sup>16</sup> the authors indicated that the difference in measurements made using CIS and auto-photography were greater in patients with ED relative those without.

When the patients with complex deformities were evaluated, CIS revealed the notching deformities of all patients (6 of 6 [100%]), whereas CT and auto-photography disclosed these deformities in only 83% (5 of 6) and 67% (4 of 6) of the cases, respectively. CT could not demonstrate notching deformity in the proximal localization. In addition, penis size and thickness measurements can be performed with CIS and CT, but this was not possible with auto-photography. Apart from ours, none of the studies cited in the literature have evaluated the presence of notching deformities. In this study, it was found that CT and auto-photography could not yield accurate results in patients with complex deformities.

The limitations of the study were determined as patients' exposure—although clinically insignificant—to radiation, ranging between 2–10 mSv, and performing CT after CIS. In addition, because the PD-specific PDQ questionnaire form is not prevalently used as stated in International Society for Sexual Medicine guidelines, this form could not be used in this study. Another limitation of our study was the small sample size, because of the pilot nature of the study.

## CONCLUSION

The superiority of CT over auto-photography and its strong correlation with CIS in most parameters have been demonstrated. In addition, it has been thought that a 3D image obtained with CT can be useful in preoperative surgical planning. However, it was found that CT did not give more information than evaluation with CIS. CIS is the most cost-effective method of assessing PD curvature with the least amount of radiation.

**Corresponding Author:** Ateş Kadioğlu, MD, FESCM, Department of Urology, Istanbul Faculty of Medicine, Istanbul University, Istanbul Tıp Fakültesi Çapa – Millet Cad. Fatih/Istanbul, 34104, Turkey. Tel: 0090 5323638499; Fax: 0090 6351918; E-mail: [kadiogluates@ttmail.com](mailto:kadiogluates@ttmail.com)

*Conflicts of Interest:* The authors report no conflicts of interest.

*Funding:* None.

## STATEMENT OF AUTHORSHIP

### Category 1

#### (a) Conception and Design

Abdulkadir Özmez; Mazhar Ortac; Barış Bakır; Ateş Kadioğlu

#### (b) Acquisition of Data

Abdulkadir Özmez; Gokhan Cevik; Hakan Akdere; Barış Bakır

#### (c) Analysis and Interpretation of Data

Abdulkadir Özmez; Mazhar Ortac; Gokhan Cevik; Hakan Akdere; Barış Bakır; Ateş Kadioğlu

### Category 2

#### (a) Drafting the Article

Abdulkadir Özmez; Mazhar Ortac; Hakan Akdere; Ateş Kadioğlu

#### (b) Revising It for Intellectual Content

Abdulkadir Özmez; Mazhar Ortac; Ateş Kadioğlu

### Category 3

#### (a) Final Approval of the Completed Article

Abdulkadir Özmez; Mazhar Ortac; Gokhan Cevik; Hakan Akdere; Barış Bakır; Ateş Kadioğlu

## REFERENCES

1. Ralph D, Gonzalez-Cadavid N, Mirone V, et al. The management of Peyronie's disease: evidence-based 2010 guidelines. *J Sex Med* 2010;7:2359-2374.

2. Mulhall JP, Schiff J, Guhring P. An analysis of the natural history of Peyronie's disease. *J Urol* 2006;175:2115-2118; discussion 2118.
3. Smith JF, Walsh TJ, Conti SL, et al. Risk factors for emotional and relationship problems in Peyronie's disease. *J Sex Med* 2008;5:2179-2184.
4. Chung E, Ralph D, Kagioglu A, et al. Evidence-based management guidelines on Peyronie's disease. *J Sex Med* 2016;13:905-923.
5. Levine LA, Greenfield JM. Establishing a standardized evaluation of the man with Peyronie's disease. *Int J Impot Res* 2003;15(Suppl. 5):S103-S112.
6. Chen JY, Hockenberry MS, Lipshultz LI. Objective assessments of Peyronie's disease. *Sex Med Rev* 2018;6:438-445.
7. Shenoy-Bhangle A, Perez-Johnston R, Singh A. Penile imaging. *Radiol Clin North Am* 2012;50:1167-1181.
8. Kirkham AP, Illing RO, Minhas S, et al. MR imaging of nonmalignant penile lesions. *Radiographics* 2008;28:837-853.
9. Nehra A, Alterowitz R, Culkun DJ, et al. Peyronie's disease: AUA guideline. *J Urol* 2015;194:745-753.
10. Rosen RC, Riley A, Wagner G, et al. The international index of erectile function (IIEF): A multidimensional scale for assessment of erectile dysfunction. *Urology* 1997;49:822-830.
11. Kelami A. Autophotography in evaluation of functional penile disorders. *Urology* 1983;21:628-629.
12. Deveci S, Hopps CV, O'Brien K, et al. Defining the clinical characteristics of Peyronie's disease in young men. *J Sex Med* 2007;4:485-490.
13. Muller A, Mulhall JP. Peyronie's disease intervention trials: Methodological challenges and issues. *J Sex Med* 2009;6:848-861.
14. Bacal V, Rumohr J, Sturm R, et al. Correlation of degree of penile curvature between patient estimates and objective measures among men with Peyronie's disease. *J Sex Med* 2009;6:862-865.
15. Matsushita K, Stember DS, Nelson CJ, et al. Concordance between patient and physician assessment of the magnitude of Peyronie's disease curvature. *J Sex Med* 2014;11:205-210.
16. Ohebshalom M, Mulhall J, Guhring P, et al. Measurement of penile curvature in Peyronie's disease patients: Comparison of three methods. *J Sex Med* 2007;4:199-203.
17. Kadioglu A, Kucukdurmaz F, Sanli O. Current status of the surgical management of Peyronie's disease. *Nat Rev Urol* 2011;8:95-106.