

## The three-portal technique in arthroscopic lateral epicondylitis release

Ashok Gowda,<sup>1</sup> Gannon Kennedy,<sup>2</sup>  
Stacey Gallacher,<sup>3</sup> Jennie Garver,<sup>3</sup>  
Theodore Blaine<sup>3</sup>

<sup>1</sup>Orthopedic Surgery Department, Beaumont Health System, Royal Oak, MI; <sup>2</sup>Orthopaedic Surgery Department, New York Medical College, Westchester Medical Center, Valhalla, NY; <sup>3</sup>Orthopedic Surgery Department, Yale Medical School, Yale University, New Haven, CT, USA

### Abstract

Lateral epicondylitis, commonly referred to as tennis elbow, is a syndrome characterized by pain over the origin of the common extensor muscles of the fingers, hand and wrist at the lateral epicondyle. Reports of 70-90% response to conservative treatment at one year have been documented in the literature though refractory cases often require surgical management. Arthroscopic treatment of lateral epicondylitis allows for intra-articular visualization for concomitant pathology and localization of the Extensor Carpi Radialis Brevis tendon. Additionally, compared to the open technique, the arthroscopic technique has a lower morbidity and an earlier return to work and activity. Here we describe a three portal technique for improved visualization in arthroscopic lateral epicondylitis release.

### Introduction

Lateral epicondylitis, commonly referred to as tennis elbow, is a syndrome characterized by pain over the origin of the common extensor muscles of the fingers, hand and wrist at the lateral epicondyle. One to three percent of the general population and a greater percentage of manual laborers suffer from this condition.<sup>1,2</sup> Lateral epicondylitis occurs equally in men and women in their fifth decade and most commonly affects their dominant arm.<sup>1,3</sup>

Reports of 70-90% response to conservative treatment at one year have been documented in the literature.<sup>4,5</sup> For those who fail to improve with conservative treatment, open, percutaneous, and arthroscopic treatments exist.<sup>6-8</sup> Arthroscopic treatment of lateral epicondylitis allows for intra-articular visualization of concomitant pathology and localization of the Extensor Carpi Radialis Brevis (ECRB) tendon. Additionally, compared to the open

technique, the arthroscopic technique has a lower morbidity and an earlier return to work and activity.<sup>9</sup> While intra-articular visualization is improved with arthroscopic treatment, in our experience, redundancy of capsular tissue can make localization of ECRB from within the capsule difficult. We describe a three portal technique for improved visualization when utilizing the arthroscopic lateral epicondylitis release technique.

### Surgical technique

Arthroscopic lateral epicondylitis release is best performed in the lateral decubitus position with the affected extremity elevated as it provides arm stability. The involved extremity is flexed forward 90 degrees at the shoulder, internally rotated, and hung over a padded bolster flexing the elbow to 90 degrees. This position minimizes intra-articular pressure.<sup>10</sup> Care must be taken to not place the bolster too distally which decreases the available joint space. The primary advantage of the lateral decubitus position is to provide arm stability while allowing adequate airway access.

A tourniquet is placed on the arm and the elbow is prepped and draped in a sterile manner allowing access to both superior and inferior portal sites. Surface landmarks including the lateral epicondyle, medial epicondyle, radial head, capitellum, olecranon, and ulnar nerve are marked. An 18-gauge needle is used to inject up to 25 mL of saline through the anconeus triangle bordered by the lateral epicondyle, radial head, and the olecranon process to distend the joint (Figure 1a). A posteromedial portal is established 2 cm proximal to the medial epicondyle and 1 cm anterior to the intermuscular septum. A posterolateral portal is established 2 cm superior to the anterior aspect of lateral epicondyle (Figure 1b). A switching stick is introduced into the posterolateral portal and guided along the anterior joint capsule towards the medial aspect of the elbow. As the switching stick abuts the medial capsule, a skin incision is made allowing the switching stick to pass through the skin typically proximal and anterior to the posteromedial portal (Figure 1c). Laterally, the switching stick is intracapsular and is used to increase visualization through retraction of the anterior capsule (Figure 2). With the arthroscope in the posteromedial portal, an arthroscopic shaver is introduced through the lateral portal and, with the switching stick acting as an anterior capsule retractor, synovial tissue is debrided and a diagnostic arthroscopy including examination of the radiocapitellar joint and lateral capsule is performed.

Using an arthroscopic beaver blade (Figure 3) and 2.5 mm full radius resector, the lateral capsule is opened and the ECRB origin is released from the most proximal attachment to its inferior portion and along the condylar

Correspondence: Theodore Blaine, Department of Orthopaedic Surgery, Yale School of Medicine, Yale Physicians Building, 800 Howard Ave, New Haven, CT 06510, USA.  
Tel.: +1.203.785.2579 - Fax: +1.203.785.7132.  
E-mail: theodore.blaine@yale.edu

Key words: elbow, arthroscopy, epicondylitis, portal, technique.

Contributions: the authors contributed equally.

Conflict of interest: the authors declare no potential conflict of interest.

Received for publication: 23 September 2016.  
Accepted for publication: 6 December 2016.

This work is licensed under a Creative Commons Attribution NonCommercial 4.0 License (CC BY-NC 4.0).

©Copyright A. Gowda et al., 2016  
Licensee PAGEPress, Italy  
*Orthopedic Reviews* 2016;8:6081  
doi:10.4081/or.2016.6081

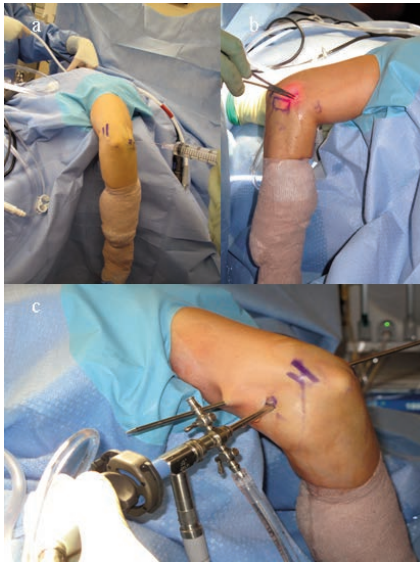
attachment to the radial head (Figure 4). Some surgeons advocate decorticating the lateral, nonarticular surface of the epicondyle with a shaver to promote bleeding.<sup>11</sup> A complete debridement and synovectomy is completed with attention to avoidance of the neurovascular structures and the overlying Extensor Carpi Radialis Longus (ECRL) muscle. Care must be taken with posterior resection adjacent to the radial head to avoid resecting below the equator to protect the lateral ulnar collateral ligament.

Postoperatively the patient is splinted in a neutral position for one week. Physical therapy is started at the first postoperative visit with anticipation of return to full activity at six weeks.

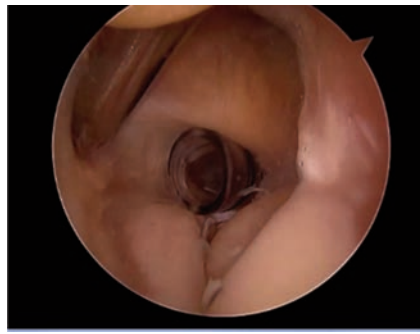
### Case Report

Recently, we performed this technique in a healthy 55-year old right-hand dominant female who presented with two years of left elbow pain, tenderness over the lateral epicondyle, and increased pain with resisted wrist extension. Prior to surgical intervention she received intra-articular corticosteroid injections and physical therapy without improvement in symptoms. At initial presentation she reported her pain to be 3/10 at rest and 7/10 with activity on the Pain Visual Analog Scale (VAS).

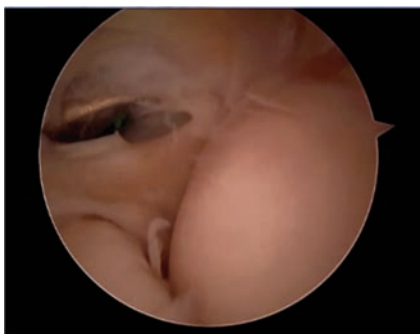
One week postoperatively, the patient demonstrated full range of motion and well-



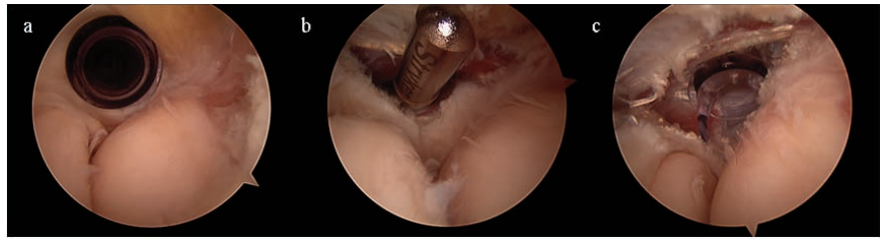
**Figure 1.** a) Positioning in the lateral decubitus position with joint distension through the anconeus triangle. b) After localization with an 18 gauge needle under direct visualization the posterolateral portal is established. c) A switching stick being passed medially to be used as an anterior capsule retractor.



**Figure 2.** Arthroscopic view of the switching stick acting as a retractor on the anterior capsule.



**Figure 3.** Arthroscopic view of Extensor Carpi Radialis Brevis release using an arthroscopic beaver blade.



**Figure 4.** a) Arthroscopic view of the radiocapitellar joint from the posteromedial portal with a cannula in the posterolateral portal. b) A resector through the posterolateral portal debriding the undersurface of the Extensor Carpi Radialis Brevis (ECRB) after opening the lateral joint capsule. c) Full debridement of the ECRB.

healing surgical incisions. At that point, physical therapy was started. At four months post-procedure, the patient stated her left elbow felt much improved with occasional aches. At greater than one year follow up, she reported her pain improved to 1/10 at rest and 4-5/10 with certain activities on the VAS. She continued to wear a counterforce brace as needed.

## Discussion

Pain in lateral epicondylitis is thought to be caused by pathologic degeneration from repetitive mechanical loading of the elbow resulting in cumulative microtrauma to the extensor tendon.<sup>4,6</sup> Histopathologic analysis of the tendinous origin demonstrates degeneration and vascular proliferation without appreciable inflammation.<sup>12</sup> Neovascularization is thought to represent a healing response.<sup>13</sup> Macroscopically, tendinosis appears as grey scar tissue and is friable or edematous.<sup>6</sup>

Boyd *et al.* have shown non-operative treatment to be effective in the majority of patients.<sup>14</sup> Treatment should be initiated with rest, modification of activity, bracing, acupuncture, cross-frictional massage, and, if needed, steroid injections. Surgical intervention is reserved for those who have not improved with nonsurgical treatment after a one-year duration. To date, a variety of surgical techniques have been described including fasciotomy, z-lengthening of the tendon, osteotomy of the lateral epicondyle with excision of the damaged portion of the ECRB, and open, percutaneous, or arthroscopic tenotomy.<sup>4,6,7,9,14-17</sup> Fasciotomy alone has shown 86% good to excellent results at 8 year follow up, open release 75-91% good to excellent results at 5 year follow up, percutaneous release 91-96% good to excellent results at 2-3 year follow up, and arthroscopic release 75-95% with improvement at 2 year follow up.<sup>7,9,15-20</sup> A Cochrane review concluded there was insufficient evidence to support any one surgical procedure at this time.<sup>21</sup>

The three portal arthroscopic lateral epi-

condylitis release has several advantages when compared to existing techniques. First, a comparison of arthroscopic to open and minimally invasive techniques reported earlier return to work and higher satisfaction with less invasive techniques.<sup>22,23</sup> Second, the use of a switching stick as a retractor in the arthroscopic technique allows for an increased area of visualization for confounding intra-articular pathology reported to be seen in at least 5% of all cases.<sup>24</sup> Third, the use of the switching stick as a retractor of the anterolateral intracapsular tissue significantly reduces capsular redundancy allowing for improved localization of the ECRB tendon and reducing the proximity of the tendon to the lateral ulnar collateral ligament.

## Conclusions

Lateral epicondylitis, or tennis elbow, is a common tendon injury treated by orthopedic surgeons that affects 1-3% of the population. Here we describe a three portal technique for better visualization in arthroscopic lateral epicondylitis release.

## References

1. De Smedt T, De Jong A, Van Leemput W, et al. Lateral epicondylitis in tennis: update on aetiology, biomechanics and treatment. *Br J Sports Med* 2007;41:816-9.
2. Shiri R, Viikari-Juntura E, Varonen H, Heliövaara M. Prevalence and determinants of lateral and medial epicondylitis: a population study. *Am J Epidemiol* 2006; 164:1065-74.
3. Lo MY, Safran MR. Surgical treatment of lateral epicondylitis: a systematic review. *Clin Orthop Relat Res* 2007;98-106.
4. Coonrad RW, Hooper WR. Tennis elbow: its course, natural history, conservative and surgical management. *J Bone Joint Surg Am* 1973;55:1177-82.
5. Boyer MI, Hastings II H. Lateral tennis

- elbow: Is there any science out there?. *J Shoulder Elbow Surg* 1999;8:481-91.
6. Nirschl RP, Pettrone FA. Tennis elbow. The surgical treatment of lateral epicondylitis. *J Bone Joint Surg Am* 1979;61:832-9.
  7. Baumgard SH, Schwartz DR. Percutaneous release of the epicondylar muscles for humeral epicondylitis. *Am J Sports Med* 1982;10:233-6.
  8. Baker Jr CL, Murphy KP, Gottlob CA, Curd DT. Arthroscopic classification and treatment of lateral epicondylitis: two-year clinical results. *J Shoulder Elbow Surg* 2000;9:475-82.
  9. Owens BD, Murphy KP, Kuklo TR. Arthroscopic release for lateral epicondylitis. *Arthroscopy* 2001;17:582-7.
  10. O'Driscoll SW, Morrey BF, An KA. Intraarticular pressure and capacity of the elbow. *Arthroscopy* 1990;6:100-3.
  11. Savoie Iii FH, VanSice W, O'Brien MJ. Arthroscopic tennis elbow release. *J Shoulder Elbow Surg* 2010;19:31-6.
  12. Kraushaar BS, Nirschl RP. Tendinosis of the elbow (Tennis elbow): clinical features and findings of histological, immunohistochemical, and electron microscopy studies. *J Bone Joint Surg Am* 1999;81:259-78.
  13. Clarke AW, Ahmad M, Curtis M, Connell DA. Lateral elbow tendinopathy: Correlation of ultrasound findings with pain and functional disability. *Am J Sports Med* 2010;38:1209-14.
  14. Boyd HB, McLeod Jr AC. Tennis elbow. *J Bone Joint Surg Am* 1973;55:1183-7.
  15. Posch JN, Goldberg VM, Larrey R. Extensor fasciotomy for tennis elbow: a long-term follow-up study. *Clin Orthop Relat Res* 1978;135:179-82.
  16. Yergler B, Turner T. Percutaneous extensor tenotomy for chronic tennis elbow: an office procedure. *Orthopedics* 1985;8:1261-3.
  17. Grundberg AB, Dobson JF. Percutaneous release of the common extensor origin for tennis elbow. *Clin Orthop Relat Res* 2000:137-40.
  18. Das D, Maffulli N. Surgical management of tennis elbow. *J Sports Med Phys Fitness* 2002;42:190-7.
  19. Goldberg EJ, Abraham E, Siegel I. The surgical treatment of chronic lateral humeral epicondylitis by common extensor release. *Clin Orthop Relat Rese* 1988:208-12.
  20. Kaleli T, Ozturk C, Temiz A, Tirelioglu O. Surgical treatment of tennis elbow: percutaneous release of the common extensor origin. *Acta Orthopaedica Belgica* 2004;70:131-3.
  21. Dunkow PD, Jatti M, Muddu BN. A comparison of open and percutaneous techniques in the surgical treatment of tennis elbow. *J Bone Joint Surg Br* 2004;86:701-4.
  22. Buchbinder R, Johnston RV, Barnsley L, et al. Surgery for lateral elbow pain. *Cochrane Database Syst Rev* 2011: CD003525.
  23. Peart RE, Strickler SS, Schweitzer Jr KM. Lateral epicondylitis: a comparative study of open and arthroscopic lateral release. *Am J Orthop (Belle Mead, NJ)* 2004;33: 565-7.
  24. Nirschl RP, Ashman ES. Tennis elbow tendinosis (epicondylitis). *Instr Course Lect* 2004;53:587-98.