

Contents lists available at [ScienceDirect](https://www.sciencedirect.com)

International Journal of Surgery Case Reports

journal homepage: www.casereports.com

Adult patient living 32 years with postduodenal remnant small bowel of only 35 cm in jejunocolic anastomosis type II weaned off parenteral nutrition. A case report

Etienne El-Helou^{a,*}, Mersad Alimoradi^a, Hassan Sabra^a, Jessica Naccour^b, Marwan M. Haddad^c, Georges Chahine^d

^a General Surgery Department, Faculty of Medical Sciences, Lebanese University, Mount Lebanon, Lebanon

^b Emergency Medicine Department, Faculty of Medical Sciences, Lebanese University, Mount Lebanon, Lebanon

^c Mount Lebanon Hospital, Head of Radiology Department, Mount Lebanon, Lebanon

^d Mount Lebanon Hospital, General Surgery Department, Mount Lebanon, Lebanon

ARTICLE INFO

Article history:

Received 10 July 2020

Received in revised form 10 August 2020

Accepted 12 August 2020

Available online 19 August 2020

Keywords:

Small bowel
Short bowel syndrome
Bowel length
Case report
Parenteral nutrition
Intestinal adaptation

ABSTRACT

INTRODUCTION: The small bowel is an essential organ for maintaining adequate nutrition. Decrease in length could be associated with malnutrition and may require that the patient receives parenteral nutritional support. We report a case of a 59-year-old man who survived 32 years with a short bowel of 35 cm length without any parenteral nutrition.

CASE PRESENTATION: A 59-year-old gentleman, with a history of hypercoagulable state, presented for severe abdominal pain and obstipation of one day's duration. Upon presentation, the patient was hemodynamically unstable, with abdominal guarding and tenderness upon physical examination. Laboratory studies showed metabolic acidosis with leukocytosis and electrolyte disturbances, and an abdominal CT scan showed thickening of the sigmoid and multiple air-fluid levels. The patient was operated urgently for suspicion of mesenteric ischemia, however, he was found intraoperatively to have a very short dilated small bowel with jejunotransverse anastomosis.

DISCUSSION: The necessity for surgical resection of the small bowel can arise for a sum of reasons. However, the removal of a big amount of small bowel may not be adaptive and appropriate digestion will no more be possible. In the aftermath of the resection, patients require parenteral nutrition for a certain period after which they may switch to enteral and oral nutrition, and subsequently intestinal adaptation by thickening and growth of the remaining intestinal villi.

CONCLUSION: Patients with a short bowel, particularly those surgically removed, can survive even with a very short remaining bowel length, as a result of intestinal adaptation, nutrition enhancement, and elimination of parenteral nutrition.

© 2020 The Author(s). Published by Elsevier Ltd on behalf of IJS Publishing Group Ltd. This is an open access article under the CC BY-NC-ND license (<http://creativecommons.org/licenses/by-nc-nd/4.0/>).

1. Introduction

Since the small bowel is an essential organ for digestion, its adaptation after volume resection is vital [1]. This adaptation allows for the improvement of nutrient and fluid absorption in the remaining bowel and achieves autonomy for enteral feeding [2]. We present in this report a case of a patient who had a good adapta-

tion and survived 32 years after massive bowel resection without any parenteral nutrition. The patient had a jejunocolic anastomosis (type II) with a small bowel measuring 35 cm in length. According to current literature, patients with this type of anastomosis require at least 60 cm of small bowel length to remain off parenteral nutrition. We report this case in detail and review relevant literature in this article.

This case was reported in line with SCARE criteria [3].

2. Case description

The patient discussed in this report is a 59 years old man, with a medical history of hypercoagulable state, multiple previous DVTs, and related mesenteric ischemia requiring bowel resection 32 years ago.

He presented for severe abdominal pain associated with obstipation and profuse vomiting for one day. He reported several years

Abbreviations: ABG, arterial blood gas; BaFT, barium follow-through; CRP, C-reactive protein; CT, computed tomography; DVT, deep venous thrombosis; ER, emergency room; ICU, intensive care unit; IF, intestinal failure; IV, intravenous; SBS, short bowel syndrome; TSBL, total small bowel length; VS, versus.

* Corresponding author.

E-mail addresses: etienne-elhelou@hotmail.com (E. El-Helou), alimoradi.mersad@gmail.com (M. Alimoradi), Hassan_sabra_14@hotmail.com (H. Sabra), jessicanaccour14@hotmail.com (J. Naccour), m.haddad@hotmail.com (M.M. Haddad), georges.chahine@gmail.com (G. Chahine).

<https://doi.org/10.1016/j.ijscr.2020.08.017>

2210-2612/© 2020 The Author(s). Published by Elsevier Ltd on behalf of IJS Publishing Group Ltd. This is an open access article under the CC BY-NC-ND license (<http://creativecommons.org/licenses/by-nc-nd/4.0/>).

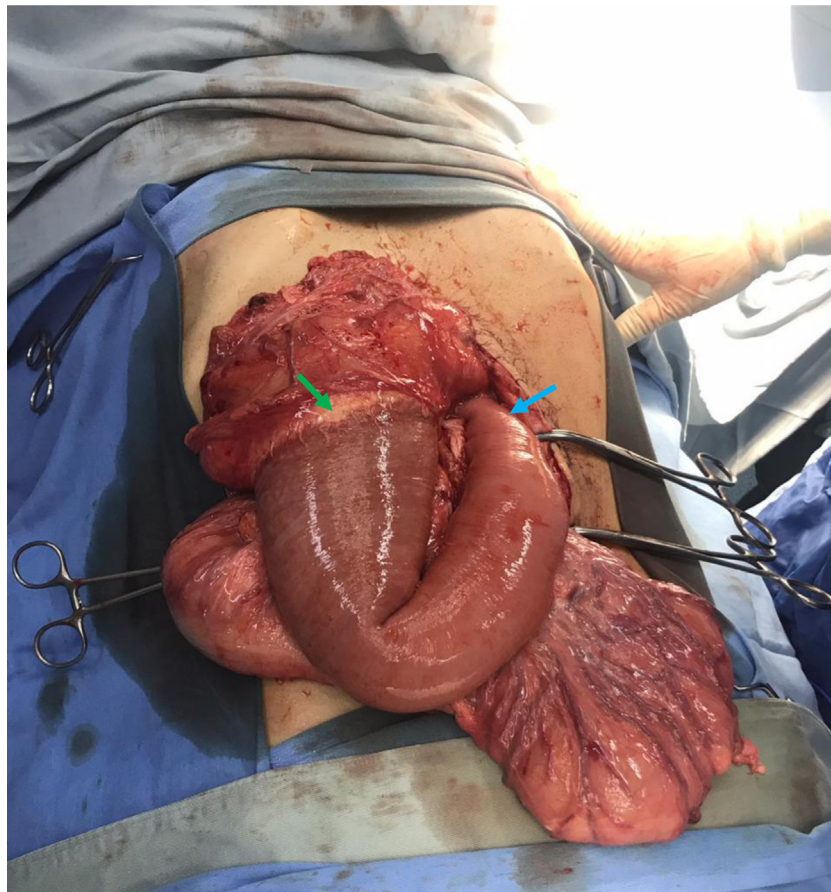


Fig. 1. Intraoperative image of short small bowel with jejunotransverse anastomosis (Green Arrow: Ileotransverse anastomosis, Blue Arrow: Treitz Ligament).

of chronic diarrhea, however, he had perturbation of his bowel habits in the last few days. The review of system was otherwise negative.

On physical examination, he was hypotensive, afebrile, and tachycardic. The abdominal exam was remarkable for abdominal distention, voluntary guarding, and tenderness, mainly over the pelvic area. Bilateral lower limb pitting edema was also noted. The rest of the physical exam was otherwise normal.

The patient's laboratory studies showed leukocytosis with a left neutrophil shift and an elevated CRP. Severe electrolyte disturbances were noted: hypokalemia (2.5 mmol/L), Hypocalcaemia (4.4 mg/dL), Hypomagnesaemia (0.5 mg/dL), and were associated with an increase in creatinine. ABGs showed metabolic acidosis (pH 7.19, HCO_3^- 12.9 mmol/L, P_{CO_2} 35.2 mmHg). Serum Lactate was not ordered in the ER.

A non-enhanced abdominal and pelvic CT scan was performed and it showed thickening of the sigmoid colon indicative of a tumoral or an inflammatory condition, associated with dilatation of the descending and transverse colon (6.5 cm maximal diameter). Multiple air-fluid levels were observed at this level. Irregularity of the colon at the splenic flexure was noted, which could be a result of prior surgery or a fluid collection. A dilated small bowel loop was identified proximally reaching 3.3 cm in diameter with a collapsed distal ileum. No gastric distension was observed. Mild ascitic fluid was noted in the Douglas pouch. No pneumoperitoneum and no hemoperitoneum were noted. Apparent Omental thickening and prominent retroperitoneal lymph nodes were seen. The exam was limited by the lack of IV contrast administration and the absence of a previous exam for comparison.

In front of this presentation and the prior medical history, the patient was admitted for urgent laparotomy to rule out mesenteric

ischemia as a probable cause of the bowel obstruction, acidosis, and altered general status of the patient. A midline laparotomy was done. No ischemic bowels were identified. To our surprise, a very short small bowel of 35 cm with jejunotransverse anastomosis was discovered (Fig. 1). Exploration of the abdomen revealed no other abnormalities explaining the patient's condition, and therefore, a decision to abort surgery was done.

The patient was transferred to the ICU to be treated as a severe case of short bowel syndrome. He was started on total parenteral nutrition immediately. On postoperative day 5, liquid diet was started. Progression to a regular solid diet was achieved by day 9. The patient tolerated progression and was improving, therefore, a decision was taken to stop parenteral nutrition on day 10. After 3 more days of observation, and after all the electrolyte disturbances were normalized, the patient was discharged home without any further complications.

3. Discussion

The small intestine is an essential constituent of the digestive system. Its function is an association of a complex system of muscles, nerves, and blood vessels, and it is divided into the duodenum, jejunum, and the ileum [4]. The small intestines play a major role in the absorption of lipids, carbohydrates, and proteins, in addition to vitamins and minerals [5].

The total small bowel length (TSBL) have a wide variation in living humans. In a recent study, Bekheit et al. reported a range of TSBL from 2.5 to 13 m with a mean length of 630 ± 175 cm [6]. The vast majority of nutrients are absorbed in the first one hundred centimeters of the jejunum [7]. An adequate TSBL is important

since malabsorption due to short bowels can cause great burdens in a patient's life, affecting their ability to go about their quotidian doings [5].

In surgical practice, small bowel resection is commonly performed for multiple indications such as obstruction, malignancy, perforation, necrosis, and others. However, infrequently, this compromises the gastrointestinal absorptive function due to the postoperative remnant length [8]. Acute mesenteric ischemia remains an emergency condition causing disruption of the vascular supply to the small bowels, and is, therefore, a highly morbid malady. Some findings are predictive of irreversible intestinal necrosis, and thus surgical resection is obligatory, combined with medical and revascularization practices to rescue the viable bowels [9].

The clinical manifestations after resection are influenced by the functional capability of the remaining gastrointestinal tract to compensate and to familiarize with the reduced total length [10]. The remnant bowel compensates by a process of adaptation which is regarded as deepening and elongation of crypts and villi respectively. This increases the ability for absorption and digestion per each unit of bowel length [11]. This phase usually lasts for one to two years [10].

On the other hand, failure to adapt and the inadequate nutritional supply can result in short bowel syndrome (SBS), which denotes a severe and infrequent disorder described by decreased absorption of nutrients, leading to malnutrition and intestinal failure (IF), anemia, and continuous weight loss [12]. To prevent IF, patients with short bowel syndrome should be monitored closely with adequate intravenous replacement of fluids and electrolytes and parenteral nutrition to achieve a hemodynamic balance and proper delivery of tissue needs. The duration of parenteral nutrition depends on the length and location of the resected bowels and the presence of the ileocecal valve. Switching to enteral feeding is essential and promotes adaptation [10].

Thus, surgical resection of the small bowel results in a decrease in the absorptive surface and a rapid transit [7]. According to surgical measurement, 73.1 ± 37.2 cm is the average length of the intestinal remnant in patients who develop SBS [13].

Therefore, some studies relate the manifestations to anatomical impairment; enteral nutritional support may be needed in adult patients with remaining 180 to 200 cm of small bowel, whereas in patients with a less than 90 cm small bowel remnant, parenteral nutrition may be needed for a certain period of time. In contrast, patients with less than 60 cm of small bowels are likely to require parenteral nutrition indefinitely [7]. A study done by Buchman et al. reported that the minimal indispensable length for nutritional autonomy is at least 115 cm in patients with an end enterostomy (Type I), 60 cm in case of a jejuno-colic anastomosis (type II) and 35 cm if a jejuno-ileal anastomosis is present with an intact colon (type III) [14]. However, parenteral nutrition is still an important cause of medical complications, financial burden, and impairment in quality of life. Newly presented pharmacological drugs begin to raise an opportunity of decreasing parenteral nutrition necessities, reducing these burdens [10]. If the bowels fail to adapt, bowel lengthening surgical procedures can be considered [12]. Small bowel transplant is reserved for patients who fail total parenteral nutrition and develop severe life-threatening complications [15].

To our knowledge, our patient is the only reported case surviving with only 35 cm of small bowel in jejuno-colic anastomosis (type II) with complete nutritional autonomy.

Funding

This research did not receive any specific grant from funding agencies in the public, commercial, or not-for-profit sectors.

Ethical approval

The study type is exempt from ethical approval.

Consent

Written informed consent was obtained from the patient for publication of this case report and accompanying images.

A copy of the written consent is available for review by the Editor-in-Chief of this journal on request.

Author contribution

Writing the paper, Study Concept: Etienne El-Helou, Jessica Naccour.

Data collection, Study Concept: Mersad Alimoradi, Hassan Sabra.

Supervision: Georges Chahine, Marwan M. Haddad.

Registration of research studies

- 1 Name of the registry: N/A
- 2 Unique identifying number or registration ID: N/A
- 3 Hyperlink to your specific registration (must be publicly accessible and will be checked): N/A

Guarantor

Dr Georges Chahine.

Provenance and peer review

Not commissioned, externally peer-reviewed.

Declaration of Competing Interest

The authors report no declarations of interest.

Acknowledgments

We would like to thank the doctors and staff at our institution and the members of the Lebanese University for their continuous support and guidance.

References

- [1] B.W. Warner, The pathogenesis of resection-associated intestinal adaptation, *Cell. Mol. Gastroenterol. Hepatol.* 2 (4) (2016) 429–438, <http://dx.doi.org/10.1016/j.jcmgh.2016.05.001>.
- [2] K.A. Tappenden, Intestinal adaptation following resection, *JPEN J. Parenter. Enteral Nutr.* 38 (1 Suppl) (2014) 23S–31S, <http://dx.doi.org/10.1177/0148607114525210>.
- [3] R.A. Agha, A.J. Fowler, A. Saeta, I. Barai, S. Rajmohan, D.P. Orgill, SCARE Group, The SCARE statement: consensus-based surgical case report guidelines, *Int. J. Surg. (Lond. Engl.)* 34 (2016) 180–186, <http://dx.doi.org/10.1016/j.ijsu.2016.08.014>.
- [4] J.T. Collins, A. Nguyen, M. Badireddy, *Anatomy, Abdomen and Pelvis, Small Intestine*, StatPearls, StatPearls Publishing, Treasure Island (FL), 2020.
- [5] E.M. Fish, B. Burns, *Physiology, Small Bowel*, StatPearls, StatPearls Publishing, Treasure Island (FL), 2020.
- [6] M. Bekheit, M.Y. Ibrahim, W. Tobar, I. Galal, A.S. Elward, Correlation between the total small bowel length and anthropometric measures in living humans: cross-sectional study, *Obes. Surg.* 30 (2) (2020) 681–686, <http://dx.doi.org/10.1007/s11695-019-04238-z>.
- [7] B. Guillen, N.S. Atherton, *Short Bowel Syndrome*, StatPearls, StatPearls Publishing, 2020.
- [8] B. Clatterbuck, L. Moore, *Small Bowel Resection*, StatPearls, StatPearls Publishing, Treasure Island (FL), 2020.
- [9] A. Nuzzo, A. Huguet, O. Corcos, *Prise en charge moderne des ischémies mésentériques [Modern treatment of mesenteric ischemia]*, *Presse Med.* 47 (6) (2018) 519–530, <http://dx.doi.org/10.1016/j.lpm.2018.03.019>.

- [10] S. Massironi, F. Cavalcoli, E. Rausa, P. Invernizzi, M. Braga, M. Vecchi, Understanding short bowel syndrome: current status and future perspectives, *Dig. Liver Dis.* 52 (3) (2020) 253–261, <http://dx.doi.org/10.1016/j.dld.2019.11.013>.
- [11] B.W. Warner, The pathogenesis of resection-associated intestinal adaptation, *Cell. Mol. Gastroenterol. Hepatol.* 2 (4) (2016) 429–438, <http://dx.doi.org/10.1016/j.jcmgh.2016.05.001>.
- [12] A. Lauro, R. Coletta, A. Morabito, Restoring gut physiology in short bowel patients: from bench to clinical application of autologous intestinal reconstructive procedures, *Expert Rev. Gastroenterol. Hepatol.* 13 (8) (2019) 785–796, <http://dx.doi.org/10.1080/17474124.2019.1640600>.
- [13] W. Cheng, S. Zhang, J. Wang, C. Zhou, Y. Li, J. Li, Three-dimensional CT enterography versus barium follow-through examination in measurement of remnant small intestinal length in short bowel syndrome patients, *Abdom. Radiol. (NY)* 43 (11) (2018) 2955–2962, <http://dx.doi.org/10.1007/s00261-018-1597-x>.
- [14] A.L. Buchman, Intestinal failure and rehabilitation, *Gastroenterol. Clin. North Am.* 47 (2) (2018) 327–340, <http://dx.doi.org/10.1016/j.gtc.2018.01.006>.
- [15] S. Kesseli, D. Sudan, Small bowel transplantation, *Surg. Clin. North Am.* 99 (1) (2019) 103–116, <http://dx.doi.org/10.1016/j.suc.2018.09.008>.

Open Access

This article is published Open Access at [sciencedirect.com](https://www.sciencedirect.com). It is distributed under the [IJSCR Supplemental terms and conditions](#), which permits unrestricted non commercial use, distribution, and reproduction in any medium, provided the original authors and source are credited.