



## SHORT REPORT

## Daratumumab for the treatment of refractory ANCA-associated vasculitis

Lennard Ostendorf <sup>1,2</sup>, Marie Burns,<sup>2</sup> Dimitrios Laurin Wagner,<sup>3,4,5,6</sup> Philipp Enghard,<sup>1,2</sup> Kerstin Amann,<sup>7</sup> Henrik Mei,<sup>2</sup> Kai-Uwe Eckardt,<sup>1</sup> Evelyn Seelow,<sup>1</sup> Adrian Schreiber <sup>1,8</sup>

**To cite:** Ostendorf L, Burns M, Wagner DL, *et al.* Daratumumab for the treatment of refractory ANCA-associated vasculitis. *RMD Open* 2023;**9**:e002742. doi:10.1136/rmdopen-2022-002742

Received 19 September 2022  
Accepted 23 December 2022

## ABSTRACT

**Objective** Treatment-refractory antineutrophil cytoplasmic antibody (ANCA)-associated vasculitis (AAV) is a life-threatening condition without evidence-based treatment options. One emerging treatment option for several antibody-mediated autoimmune diseases is the anti-CD38 antibody daratumumab, which depletes autoantibody-secreting plasma cells.

**Methods** We treated two patients with severe life-threatening AAV with renal and pulmonary manifestation despite induction therapy with rituximab and cyclophosphamide with four to eight doses of 1800 mg daratumumab. We followed clinical and immunological responses.

**Results** The first patient with myeloperoxidase-ANCA-positive microscopic polyangiitis had resolution of pneumonitis and pleuritis and stabilisation of kidney function after daratumumab. The second patient with proteinase 3-ANCA-positive granulomatosis with polyangiitis, diffuse alveolar haemorrhage necessitating extracorporeal membrane oxygenation (ECMO) and acute kidney failure, requiring kidney replacement therapy, was weaned off ECMO, mechanical ventilation and dialysis and discharged home after daratumumab. Clinical improvement was paralleled by a strong reduction in serum ANCA levels as well as total IgG, indicating depletion of plasma cells. Apart from the depletion of CD38<sup>+</sup> natural killer cells, blood leucocyte levels were not notably influenced by daratumumab. Only mild adverse events, such as hypogammaglobulinaemia and an upper respiratory tract infection occurred.

**Conclusion** Daratumumab was safe and effective in inducing remission in two patients with severe treatment-refractory AAV, warranting prospective clinical trials to establish safety and efficacy.

## BACKGROUND

Antineutrophil cytoplasmic antibody (ANCA)-associated vasculitis (AAV) is a group of autoimmune diseases mediated by autoantibodies against either myeloperoxidase (MPO) or proteinase 3 (PR3).<sup>1</sup> These autoantibodies activate myeloid cells (neutrophils and monocytes) and thus induce small vessel vasculitis, resulting in inflammation and damage of the kidney, lung, skin and other organs.

## WHAT IS ALREADY KNOWN ON THIS TOPIC

⇒ Long-lived plasma cells contribute to the pathogenesis of antineutrophil cytoplasmic antibody-associated vasculitis, and the anti-CD38 antibody daratumumab has been used to target long-lived plasma cells in some autoantibody-mediated diseases.

## WHAT THIS STUDY ADDS

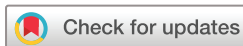⇒ This study reports two patients with refractory ANCA-associated vasculitis successfully treated with daratumumab.

## HOW THIS STUDY MIGHT AFFECT RESEARCH, PRACTICE OR POLICY

⇒ Daratumumab could be useful in the treatment of ANCA-associated vasculitis, but clinical trials will be needed to establish safety and efficacy.

The standard of care for the treatment of AAV includes induction therapy, a combination of glucocorticoids and either the anti-CD20 antibody rituximab or cyclophosphamide.<sup>1</sup> While the induction treatment with rituximab leads to clinical remission in approximately two-thirds of patients,<sup>2</sup> some have ongoing disease activity despite complete B cell depletion in the peripheral blood. AAV that shows ongoing active, inflammatory disease despite both first-line induction treatments is associated with significant mortality and persistent morbidity, including chronic kidney failure and pulmonary fibrosis.<sup>3</sup> In this situation, no evidence-based treatment options exist.

The failure of standard induction therapies can, in part, be explained by long-lived plasma cells (LLPCs): LLPCs are terminally differentiated, antibody-secreting cells that do not express CD20 and thus are not targeted by rituximab. LLPCs contribute to the pathogenesis of various antibody-mediated autoimmune diseases<sup>4</sup> and are a challenging treatment target as they do not proliferate and



© Author(s) (or their employer(s)) 2023. Re-use permitted under CC BY-NC. No commercial re-use. See rights and permissions. Published by BMJ.

For numbered affiliations see end of article.

## Correspondence to

Dr Lennard Ostendorf;  
lennard.ostendorf@charite.de

reside in various tissues and in dedicated survival niches within the bone marrow. Different approaches have been investigated in order to specifically target plasma cells in autoantibody-mediated diseases such as immunoablation followed by autologous stem cell transplantation<sup>5</sup> or the proteasome inhibitor bortezomib.<sup>6,7</sup> The monoclonal anti-CD38 antibody daratumumab, licensed for use in multiple myeloma, also depletes non-malignant plasma cells and its successful use has been reported in cases of refractory autoimmune haemolytic anaemia,<sup>8</sup> autoimmune encephalitis,<sup>9</sup> immune thrombocytopenia<sup>10</sup> and systemic lupus erythematosus (SLE).<sup>11</sup> Here we report two cases of refractory AAV successfully treated with daratumumab.

## METHODS

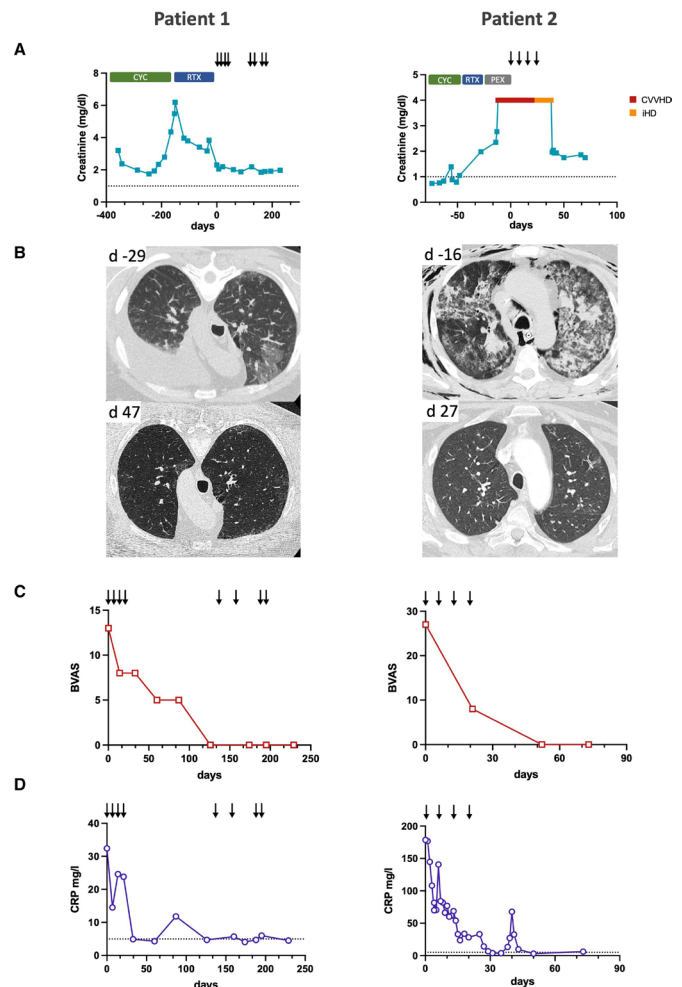
Written informed consent for off-label treatment and publication was obtained from the patients or their legal guardian. Daratumumab was administered as a 1800 mg fixed-dose subcutaneous injection once weekly, according to the standard protocol for multiple myeloma treatment and was administered with the recommended co-medication of methylprednisolone, paracetamol and dimentidene. Infection prophylaxis with trimethoprim sulfamethoxazole and acyclovir was initiated or continued, and the previous glucocorticoid treatment was continued. Clinical disease activity was evaluated by the Birmingham Vasculitis Activity Score (BVAS) V.3.

Paraffin sections of a kidney biopsy from patient 1, obtained shortly before the initiation of daratumumab treatment, were stained for the presence of B and plasma cells using a commercially available antibody against CD20 (Dako, Glostrup, Denmark) and CD138 (Zytomed, Berlin, Germany, clone B-A38) or antibody cocktails for detection of kappa (Dako, Glostrup, Denmark) and lambda (Dako, Glostrup, Denmark and Monosan, Am Uden, The Netherlands, Cat. No. MONX10620) and routine staining protocols on Ventana BenchMark Ultra stainers (Roche, Switzerland) as described before.<sup>12</sup>

In order to investigate the immunological changes under daratumumab treatment, we cryopreserved whole blood of patient 1, using the Proteomic Stabilizer (Smart Tube, Las Vegas, USA) and performed mass cytometric immunosurveillance as previously reported.<sup>13</sup> We used a multi-epitope CD38 antibody (Cytognos, Salamanca, Spain) to detect CD38 even in the presence of daratumumab. We measured MPO-ANCA and PR3-ANCA by ELISA (EUROIMMUN, Lübeck, Germany). We provide clinical and immunological follow-up data up to 7 months after the initiation of treatment.

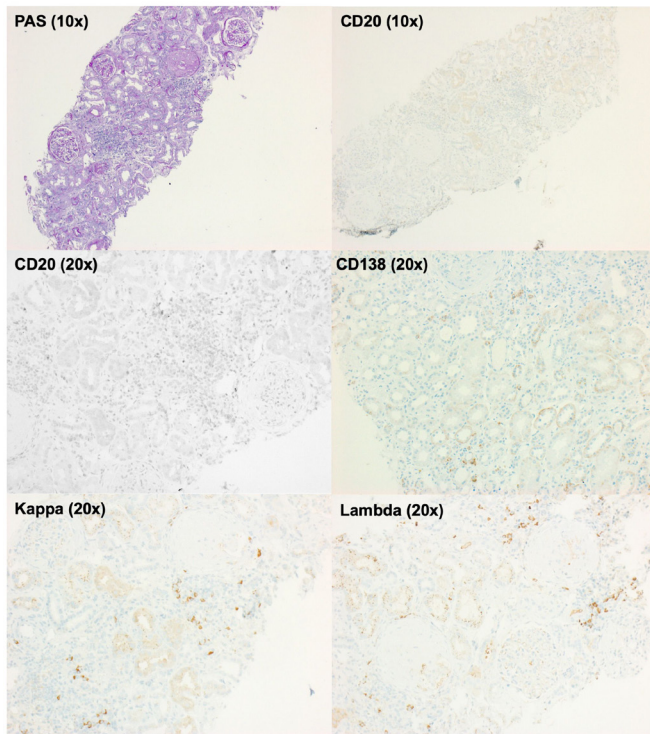
## RESULTS

Patient 1 was a 57-year-old male patient with a treatment-refractory MPO-ANCA-positive microscopic polyangiitis. The patient had been diagnosed 1 year prior, when he presented with crescentic glomerulonephritis. Despite



**Figure 1** Improvement of antineutrophil cytoplasmic antibody-associated vasculitis (AAV) disease activity after daratumumab treatment. (A) Serum creatinine levels before and after daratumumab treatment. Previous induction therapies with cyclophosphamide (CYC), rituximab (RTX) and plasma exchange (PEX) did not lead to clinical remission or stabilisation of kidney function. Arrows indicate daratumumab doses, the dotted line indicates the upper normal limit for serum creatinine. Patient 2 underwent renal replacement therapy with continuous veno-venous haemodialysis (CVVHD) and intermittent haemodialysis (IHD). (B) CT of lung sections showing pleural effusion and alveolitis (patient 1) and AAV-induced acute respiratory distress syndrome and ventilator-associated soft tissue emphysema (patient 2). Only some fibrotic changes remain after daratumumab treatment. (C) Birmingham Vasculitis Activity Score (BVAS) shows clinical remission after daratumumab treatment. (D) C reactive protein (CRP) levels in both patients decline to normal levels after daratumumab treatment, the dotted line indicates the upper normal limit.

treatment with cyclophosphamide and rituximab, he never reached remission. At the time of evaluation for daratumumab treatment, he presented with worsening dyspnoea due to refractory pleural effusions, alveolitis and worsening kidney function with a nephritic urinary microscopy (figure 1A,B). The BVAS initially was 13 (figure 1C). A repeat kidney biopsy revealed ongoing



**Figure 2** CD20-negative antibody-secreting cells are present in the kidney after rituximab treatment. Tissue sections of a kidney biopsy from patient 1 24 days before the initiation of daratumumab show ongoing crescentic glomerulonephritis (PAS, periodic acid–Schiff staining ( $\times 10$ )). No CD20-positive cells were detected in the kidney (10 $\times$ , 20 $\times$ ), consistent with previous rituximab treatment. However, antibody-secreting cells, indicated by their expression of the kappa or lambda immunoglobulin light chains and CD138 ( $\times 20$ ), are still found in the kidney.

crescentic pauci-immune glomerulonephritis. Immunohistochemistry showed a plasma cell-dominant interstitial infiltrate positive for kappa and lambda light chains but without evidence of CD20<sup>+</sup> B cells, with complete absence of B cells in the peripheral blood, indicating that rituximab treatment had depleted B cells but not CD20<sup>+</sup> antibody-secreting cells in the kidney (figure 2). The patient initially received 1800 mg daratumumab in four weekly doses.

Already at completion of the initial four daratumumab doses, the patient showed an improvement of kidney function and resolution of alveolitis and pleural effusion (figure 1B). Four months after the last dose, as ANCA levels were still elevated and ongoing haematuria present, the patient received a second cycle of four doses of daratumumab. After dose 5, treatment was halted for 4 weeks due to an upper respiratory tract infection that did not require specific treatment. At the most recent follow-up 8 months after the initiation of daratumumab treatment, the patient remained in complete remission with stable kidney function and no sign of active pulmonary disease. During the course of the treatment, no serious adverse events occurred.

Patient 2 was a 41-year-old male patient with refractory PR3-ANCA-positive granulomatosis with polyangiitis, who had been diagnosed 4 months prior with renal, pulmonary and upper respiratory tract manifestations. Despite induction therapy with cyclophosphamide and prednisolone, he presented with diffuse alveolar haemorrhage requiring mechanical ventilation and acute kidney injury. Even with additional therapy with methylprednisolone pulses, rituximab and plasma exchange, his illness further progressed and he developed severe acute respiratory distress syndrome requiring extracorporeal membrane oxygenation (ECMO) and progressive kidney failure with need for continuous kidney replacement therapy, despite complete depletion of B cells in the peripheral blood (figure 1A,B). Furthermore, he developed a severe aortic stenosis. He received four doses of daratumumab. Within 2 weeks following initiation of daratumumab treatment, the patient was weaned from ECMO and lung and kidney function improved substantially. Eight weeks after the start of daratumumab treatment, he was discharged home without the need for oxygen supplementation or kidney replacement therapy. He remained in complete remission 4 months later and is currently being evaluated for an aortic valve replacement. Apart from hypogammaglobulinaemia without signs of infection requiring prophylactic intravenous supplementation twice, no adverse events occurred.

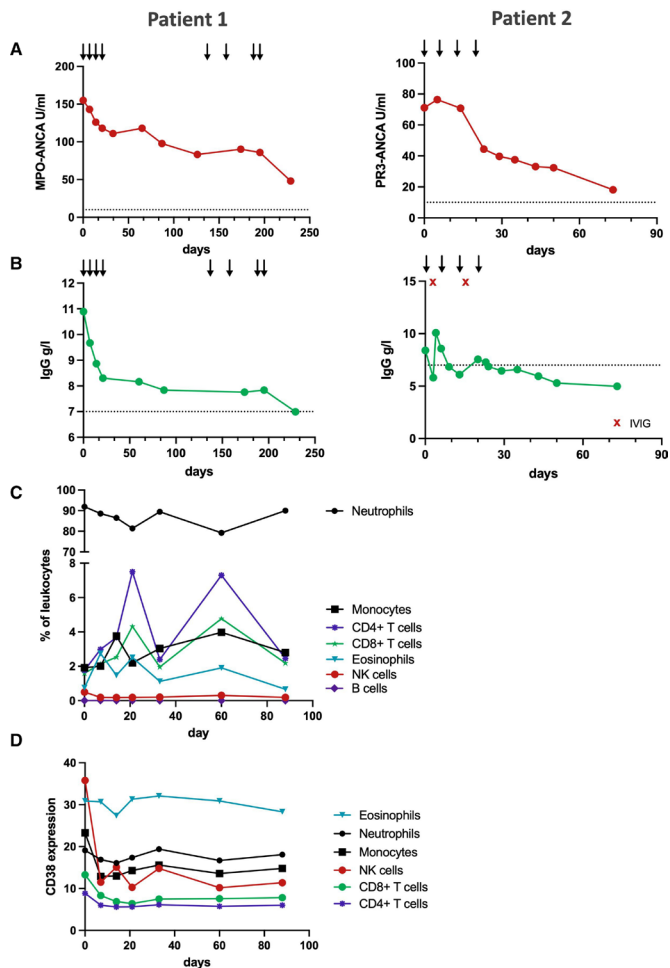
Both patients showed a significant reduction in ANCA levels after initiation of daratumumab (patient 1: 69%, patient 2: 74%), consistent with the depletion of autoantibody-secreting plasma cells (figure 3A). Total immunoglobulin levels similarly initially declined, but remained stable after the initial treatment phase (figure 3B).

In our analysis of peripheral blood leucocytes of patient 1, we observed mostly stable counts of leucocyte subsets with the exception of natural killer cells, which were depleted after daratumumab administration due to their high CD38 expression.<sup>14</sup> CD19<sup>+</sup> B cells were absent in the peripheral blood, consistent with the previous rituximab treatment (figure 3C).

Measurement of leucocyte CD38 expression after daratumumab showed a sustained suppression of CD38 levels on long-lived lymphoid cells (figure 3D).

## DISCUSSION

We report two cases of severe treatment-refractory AAV successfully treated with the anti-CD38 antibody daratumumab. Both patients had persistently high ANCA levels despite induction treatment with both rituximab and cyclophosphamide. As ANCAs are usually depleted after B cell-targeted therapies, most of ANCA production in most cases is likely attributable to CD20<sup>+</sup> B cells. Refractory cases might represent those, where long-lived plasma cells (LLPCs) are contributing more to the ANCA production. LLPCs are refractory to both CD20-targeted treatments and antiproliferative drugs, and



**Figure 3** Immunological effects of daratumumab treatment. (A) Antibody levels of myeloperoxidase (MPO)-antineutrophil cytoplasmic antibody (ANCA) and proteinase-3 (PR3)-ANCA after daratumumab treatment. Arrows indicate daratumumab doses, the dotted line indicates the upper normal limit for ANCA. (B) Total serum IgG levels decline under daratumumab treatment. The dotted line indicates the lower limit of normal IgG levels, red x indicates intravenous IgG (IVIG) supplementation. (C) Relative levels of major leucocyte subsets in the peripheral blood remain stable under daratumumab treatment of patient 1. (D) Mean signal intensity of surface CD38 expression of major leucocyte subsets in the peripheral blood of patient 1 as measured with a polyclonal antibody that binds independent of daratumumab presence. NK, natural killer.

thus represent a promising new treatment target.<sup>7 15</sup> It will thus be important to investigate the relative contributions of plasma cells and B cell to AAV, in order to identify patients who would benefit from a plasma cell-targeted therapy. In patient 1, a kidney biopsy after rituximab showed an abundance of infiltrating antibody-secreting cells negative for CD20, which may suggest the need for plasma cell-targeted therapies. However, future investigation should be conducted to investigate the role of kidney-infiltrating plasma cells and if their detection should necessitate plasma cell-targeted therapies.

Our findings complement previous reports of the successful use of the anti-CD38 antibody daratumumab

for plasma cell depletion in other autoantibody-mediated diseases, such as SLE<sup>11</sup> and autoimmune haemolytic anaemia.<sup>8</sup>

In the two patients reported here, daratumumab treatment was associated with fast clinical and immunological response with only mild adverse effects (uncomplicated upper respiratory tract infection, hypogammaglobulinaemia). However, we cannot exclude a confounding delayed treatment effect of previous therapies. Rituximab is known to induce a delayed response, and time between rituximab and daratumumab was short in patient 2 due to the dynamic worsening of his disease. While we did not observe significant adverse events, daratumumab treatment was associated with an increased risk of infection in systematic studies for multiple myeloma<sup>16</sup> and in case reports in autoimmune diseases.<sup>9 17</sup>

Prospective clinical trials will be needed to investigate the safety and efficacy of daratumumab in AAV and to identify patients who could benefit from a plasma cell-targeting drug.

#### Author affiliations

- Department of Nephrology and Medical Intensive Care Medicine, Charité – Universitätsmedizin Berlin, corporate member of Freie Universität Berlin and Humboldt-Universität zu Berlin, Berlin, Germany
- Deutsches Rheuma-Forschungszentrum Berlin, Berlin, Germany
- BIH Center for Regenerative Therapies (BCRT), Berlin Institute of Health (BIH) at Charité - Universitätsmedizin Berlin, Berlin, Germany
- Berlin Center for Advanced Therapies (BeCAT), Charité - Universitätsmedizin Berlin, corporate member of Freie Universität Berlin, Humboldt-Universität zu Berlin, and Berlin Institute of Health (BIH), Berlin, Germany
- Institute of Transfusion Medicine, Charité – Universitätsmedizin Berlin, corporate member of Freie Universität Berlin and Humboldt-Universität zu Berlin, Berlin, Germany
- Institute of Medical Immunology, Charité – Universitätsmedizin Berlin, corporate member of Freie Universität Berlin and Humboldt-Universität zu Berlin, Berlin, Germany
- Department of Nephropathology, Friedrich-Alexander University Erlangen-Nuremberg, Erlangen, Germany
- Experimental and Clinical Research Center, Max Delbrück Center for Molecular Medicine in the Helmholtz Association (MDC) and Charité - Universitätsmedizin Berlin, Corporate Member of Freie Universität Berlin and Humboldt-Universität zu Berlin, Berlin, Germany

**Acknowledgements** We thank our patients and their families for trusting us with their care and allowing us to publish this report. We thank the many physicians of the Department of Nephrology and Medical Intensive Care at Charité-Universitätsmedizin Berlin involved in the care of the patients. We also thank Alexander Kühnl (EUROIMMUN) for the analysis of ANCA levels and Heike Hirseland for technical assistance.

**Contributors** LO and AS conceptualised the study, LO, MB, DLW, PE, KA, HM and ES collected data and performed experiments. K-UE and AS supervised the work. LO wrote the first draft of the manuscript. All authors contributed to the revision of the manuscript.

**Funding** This work was supported by grants from the Deutsche Forschungsgemeinschaft with grant SCHR 771/8-1 to AS, grant 394046635-SFB 1365 to AS, grant 387509280, SFB 1350 to KA, and grant Me3644/8-1 to HM and ECRC grants to AS, as well as by funding from the European Union Innovative Medicines Initiative 2 Joint Undertaking under grant agreements no. 777357 (RTCure) and no. 831434 (3TR).

**Competing interests** None declared.

**Patient consent for publication** Obtained.

**Ethics approval** This study involves human participants and was approved by the ethics committee of Charité-Universitätsmedizin Berlin (EA2/103/17) and of

Friedrich-Alexander-Universität Erlangen-Nürnberg (reference number 4415). Participants gave informed consent to participate in the study before taking part.

**Provenance and peer review** Not commissioned; externally peer reviewed.

**Open access** This is an open access article distributed in accordance with the Creative Commons Attribution Non Commercial (CC BY-NC 4.0) license, which permits others to distribute, remix, adapt, build upon this work non-commercially, and license their derivative works on different terms, provided the original work is properly cited, appropriate credit is given, any changes made indicated, and the use is non-commercial. See: <http://creativecommons.org/licenses/by-nc/4.0/>.

#### ORCID iDs

Lennard Ostendorf <http://orcid.org/0000-0003-3553-6406>

Adrian Schreiber <http://orcid.org/0000-0003-1244-6379>

## REFERENCES

- 1 Kitching AR, Anders H-J, Basu N, *et al*. ANCA-associated vasculitis. *Nat Rev Dis Primers* 2020;6:71.
- 2 Stone JH, Merkel PA, Spiera R, *et al*. Rituximab versus cyclophosphamide for ANCA-associated vasculitis. *N Engl J Med* 2010;363:221–32.
- 3 Flossmann O, Berden A, de Groot K, *et al*. Long-term patient survival in ANCA-associated vasculitis. *Ann Rheum Dis* 2011;70:488–94.
- 4 Maschmeyer P, Chang H-D, Cheng Q, *et al*. Immunological memory in rheumatic inflammation — a roadblock to tolerance induction. *Nat Rev Rheumatol* 2021;17:291–305.
- 5 Alexander T, Thiel A, Rosen O, *et al*. Depletion of autoreactive immunologic memory followed by autologous hematopoietic stem cell transplantation in patients with refractory SLE induces long-term remission through de novo generation of a juvenile and tolerant immune system. *Blood* 2009;113:214–23.
- 6 Alexander T, Sarfert R, Klotsche J, *et al*. The proteasome inhibitor bortezomib depletes plasma cells and ameliorates clinical manifestations of refractory systemic lupus erythematosus. *Ann Rheum Dis* 2015;74:1474–8.
- 7 Novikov P, Moiseev S, Bulanov N, *et al*. Bortezomib in refractory ANCA-associated vasculitis: a new option? *Ann Rheum Dis* 2016;75:e9.
- 8 Schuetz C, Hoenig M, Moshous D, *et al*. Daratumumab in life-threatening autoimmune hemolytic anemia following hematopoietic stem cell transplantation. *Blood Adv* 2018;2:2550–3.
- 9 Scheibe F, Ostendorf L, Prüss H, *et al*. Daratumumab for treatment-refractory antibody-mediated diseases in neurology. *Eur J Neurol* 2022;29:1847–54.
- 10 Canales-Herrerias P, Crickx E, Broketa M, *et al*. High-affinity autoreactive plasma cells disseminate through multiple organs in patients with immune thrombocytopenic purpura. *J Clin Invest* 2022;132:e153580.
- 11 Ostendorf L, Burns M, Durek P, *et al*. Targeting CD38 with Daratumumab in refractory systemic lupus erythematosus. *N Engl J Med* 2020;383:1149–55.
- 12 Büttner-Herold M, Kriegelstein N, Chuva T, *et al*. Light chain restriction in proximal Tubules—Implications for light chain proximal Tubulopathy. *Front. Med.* 2022;9:723758.
- 13 Burns M, Ostendorf L, Biesen R, *et al*. Dysregulated CD38 expression on peripheral blood immune cell subsets in SLE. *Int J Mol Sci* 2021;22:2424.
- 14 Casneuf T, Xu XS, Adams HC, *et al*. Effects of daratumumab on natural killer cells and impact on clinical outcomes in relapsed or refractory multiple myeloma. *Blood Adv* 2017;1:2105–14.
- 15 Bontscho J, Schreiber A, Manz RA, *et al*. Myeloperoxidase-specific plasma cell depletion by bortezomib protects from anti-neutrophil cytoplasmic Autoantibodies-Induced glomerulonephritis. *JASN* 2011;22:336–48.
- 16 Johnsrud JJ, Susanibar S, Jo-Kamimoto J, *et al*. Infection risk associated with Daratumumab. *Open Forum Infect Dis* 2017;4:S702–3.
- 17 Scheibe F, Ostendorf L, Reincke SM, *et al*. Daratumumab treatment for therapy-refractory anti-CASPR2 encephalitis. *J Neurol* 2020;267:317–23.