



A preliminary nomogram constructed for early diagnosis of bronchitis obliterans in children with severe pneumonia

Chao Sun, Silei Yan, Kun Jiang, Chao Wang, Xiaoyan Dong

Department of Respiratory Medicine, Shanghai Children's Hospital, Shanghai Jiao Tong University, Shanghai, China

Contributions: (I) Conception and design: K Jiang, X Dong; (II) Administrative support: C Sun, S Yan; (III) Provision of study materials or patients: S Yan; (IV) Collection and assembly of data: C Sun, S Yan; (V) Data analysis and interpretation: C Wang; (VI) Manuscript writing: All authors; (VII) Final approval of manuscript: All authors.

Correspondence to: Kun Jiang. Department of Respiratory Medicine, Shanghai Children's Hospital, Shanghai Jiao Tong University, 355 Luding Road, Shanghai 200062, China. Email: jkjk_032@163.com.

Background: To establish and internally validate a nomogram for early diagnosis of bronchitis obliterans in children with severe pneumonia.

Methods: The diagnostic model was established using a dataset of 147 pediatric patients with severe pneumonia. The clinical characteristics of bronchitis obliterans were determined using the least absolute shrinkage and selection operator method. According to the results of the multivariate logistic regression analysis, an individual nomogram was established, the C-index, calibration plot, and decision curve analysis were used to evaluate the performance of the nomogram.

Results: Adenovirus infection, length of symptoms, percentage of macrophages in bronchial alveolar lavage fluid, and mucosal abnormalities were all important clinical characteristics included in the nomogram. According to internal validation, the C-index of nomogram was 0.91 (C-index, 0.878 to 0.942), suggesting that the nomogram has excellent discrimination. The nomogram showed good calibration with the Hosmer-Lemeshow test demonstrating no statistical significance. The net reclassification index was 0.2022 (95% CI, 0.008 to 0.3968; $P=0.042$), and the integrated discrimination improvement was 0.0975 (95% CI, 0.026 to 0.169; $P=0.008$). Decision curve analysis showed that the nomogram is clinically useful.

Conclusions: This nomogram can help clinicians make early diagnoses of bronchitis obliterans in children for whom membranous tissue has not yet formed.

Keywords: Bronchitis obliteration; bronchoscopy; pneumonia; children

Submitted Aug 27, 2020. Accepted for publication Jan 04, 2021.

doi: 10.21037/tp-20-272

View this article at: <http://dx.doi.org/10.21037/tp-20-272>

Introduction

Approximately 450 million people worldwide are diagnosed with pneumonia every year, and 4 million die of the disease (1,2). There are 156 million children diagnosed with pneumonia worldwide yearly, 151 million of whom live in developing countries such as China. Outcomes of pneumonia are determined by factors such as age, familial economic status, nutritional status, immune status, types of pathogenic viruses, and co-infection with bacterial pathogens (3,4). Bronchitis obliterans is a rare and severe

chronic childhood lung disease caused by several types of lower respiratory tract injury. Bronchitis obliterans is different from bronchiolitis obliterans in that the latter is a clinically distinct disease involving smaller airways that cannot be seen on bronchoscopy (5). Obstructive bronchitis describes inflammatory responses to various stimuli that give rise to narrowing of large and small airways (6); membranous tissue forms within the lumen of the segmental and subsegmental bronchi, and these membranes are visualized using flexible bronchoscopy.

The etiologies of bronchitis obliterans are unclear.

Initially, it was considered a congenital disease only; later reports described it as a condition where irritation of the airways resulted from chronic inflammation (7). In pneumoconiosis, some authors reported obliterative central bronchitis as a result of long-term inhalation of mineral dust, including severe stenosis and large lobar or segmental bronchial occlusion (8,9). Others reported that bronchitis obliterans was related to chronic inflammatory conditions—chronic suppurative lung disease or cystic fibrosis (6,10). A number of bacteria and viruses, including *Mycobacterium tuberculosis* (11), *Mycoplasma* (12), *Chlamydia* (13), influenza A (14), and severe infection [e.g., *Staphylococcus aureus* (15), *Mycobacterium avium intracellulare* (6)] have been associated with severe lung injury leading to bronchitis obliterans. In reviews of the literature, the treatment of bronchitis obliterans evolved from active intervention for transcatheter rupture or transthoracic intervention (6) to no intervention at all (16).

The clinical diagnosis of bronchitis obliterans is relatively easy using flexible bronchoscopy after membranous tissue has formed; however, the diagnosis is rather difficult if membranous tissues have not formed. The early diagnosis of bronchitis obliterans is challenging for pediatricians and radiologists. Our current understanding of bronchitis obliterans is based on small case series in which the risk factors are not clearly identified. Therefore, an accurate and reusable model is required to more accurately and comprehensively identify bronchitis obliterans in the context of severe pneumonia. To fill this knowledge gap, we conducted a study of pediatric patients with severe pneumonia to establish and validate a diagnostic nomogram based on individual clinical characteristics for early diagnosis of bronchitis obliterans in patients with severe pneumonia.

We present the following article in accordance with the TRIPOD reporting checklist (available at <http://dx.doi.org/10.21037/tp-20-272>).

Methods

Patients

This retrospective study involved medical records of children treated between January 2017 and December 2019 at Shanghai Children's Hospital, Shanghai Jiao Tong University, Shanghai, China. A total of 147 pediatric patients (mean age 67.1 ± 31.6 months; range 4 to 149 months) diagnosed with severe pneumonia were enrolled.

Patient-related information, including gender, age of diagnosis, clinical course, etiology, imaging characteristics, and treatment and clinical results were extracted from the medical records. The need for fiberoptic bronchoscopic examination was based on the following: (I) signs and symptoms of obvious airway obstruction (e.g., reduced or absent breath sounds, tubular breath sounds, repeated fixed wheezing sounds); (II) recurrent pneumonia (\geq two episodes) in the same lobe within one month; (III) imaging examination suggesting atelectasis, unilateral or bilateral consolidation; (IV) imaging revealing lung consolidation or atelectasis after medical treatment; and (V) exclusion of foreign body when high resolution computed tomography of the chest showed that a single lobe was involved.

Identification of severe pneumonia and bronchitis obliterans

According to the WHO guidelines for severe pneumonia in children, the diagnostic criteria for severe pneumonia were based on symptoms and signs, as well as on radiological and laboratory investigations (17). The diagnosis of bronchitis obliterans was based on bronchoscopic examination (10). When the general condition of the patient was stable, flexible bronchoscopy was performed under general inhaled anesthesia by the same respiratory pediatrician. The bronchoscope entered the airway through a port in the mask connector. After light aspiration, the anatomical site and lesion type were recorded. Normal saline at 37 °C was injected rapidly through the operation channel to assess airway obliteration or closure. When the airway opening was absent or significantly reduced, the bronchus was considered to be obliterative-like. Bronchoscopic airway lavage fluid (BALF) was collected by injecting 37 °C normal saline through the bronchoscope working passage, and then back through the suction apparatus with a negative pressure of 100–200 mmHg. The selected negative pressure value was appropriate to ensure that the lumen did not collapse during suction). The re-absorption rate of lavage fluid was at least 40%. Collected specimens were routinely cultured, and cell sorting and counting were performed simultaneously.

Bronchitis obliterans were included if they underwent multiple bronchoscopy examinations (2–4 times) until membranous tissue was identified. If membranous tissue was found on the first examination, the patient was excluded.

Exclusion criteria were as follows: congenital heart disease; immunodeficiency; congenital bronchopulmonary

dysplasia; hereditary metabolic disease; tuberculosis; diffuse interstitial lung disease; and long-term use of immunosuppressive agents.

Written informed consent was obtained from each set of parents prior to bronchoscopy. The study was conducted in accordance with the Declaration of Helsinki (as revised in 2013) and was approved by the institutional ethics committee of Shanghai Children's Hospital (No. 2020R164-E01).

Inflammatory cytokine assays

BALF was collected from the first bronchoscopy examination, and was used for assays of inflammatory cytokines. Levels of interleukin (IL)-8, IL-1 β , IL-6, IL-2, IL-10, IL-4, IL-5, IL-12p70, IL-17A, IL-18, TNF- α , γ -INF, IL-2R, and procalcitonin (PCT) were tested using enzyme-linked immunoassay (ELISA). White blood cells, neutrophils, macrophages, and lymphocytes in BALF samples were counted using a light microscope. Blood was collected on the day of admission.

Etiological diagnosis

Once the diagnosis of severe pneumonia was verified, serum and sputum or BALF specimens were collected. Gram staining, serum and sputum or BALF culture were carried out to identify the bacterial strains (*Streptococcus pneumoniae*, *Streptococcus viridans*, *Klebsiella pneumoniae*, *Haemophilus influenzae*, and *Moraxella catarrhalis*). The diagnostic criteria for *Mycoplasma pneumoniae* pneumonia were as follows: serum or BAL IgM antibody >1:160, or single IgM antibody positive. According to standard procedures, if the virus antigen or multiplex PCR was positive, the diagnosis of viral infection was established.

Data collection

Data were extracted from medical records, including patient gender, age, symptoms and signs, length of fever, shortness of breath, use of intravenous immunoglobulin, use of systemic corticosteroids, hypoxemia, erythrocyte sedimentation rate (ESR), D-dimer, lactate dehydrogenase (LDH), ferritin, mycoplasma co-infection, and C-reactive protein.

Statistical analysis

All data were analyzed using R software (version 3.6.1).

Count data were expressed as number and percentage. Results in two groups were compared using Chi-square test or Fisher test. Normally distributed data were expressed as mean \pm SD, and the non-normally distributed data were expressed as Media (Q1, Q3). Results in different groups were compared using the Student *t*-test or Wilcoxon's rank test. A P value of 0.05 or less was considered statistically significant.

Using least absolute shrinkage and selection operator (LASSO) analysis, the most meaningful clinical characteristics for the diagnosis of bronchitis obliterans were selected (18). The clinical characteristics that may affect patients with bronchitis obliterans were screened out using univariate logistic regression analysis. Multivariate logistic regression analysis was used to identify the independent clinical characteristics for diagnosis of bronchitis obliterans, and a diagnostic model was developed. These independent clinical characteristics were represented with a nomogram. The calibration, discrimination, and clinical usefulness of the nomogram were also assessed.

Clinical use

To test the clinical usefulness of the nomogram, by quantifying the net benefits under various threshold probabilities, decision curve analysis (DCA) was used to draw the decision curves, and this along with the clinical impact curve were used to assess the calibration of the nomogram (19). Receiver operating characteristic (ROC) curves were generated to assess the values of various models that might help distinguish bronchitis obliterans from severe pneumonia. The true positive rate (TPR) and false positive rate (FPR) were also calculated at various threshold probabilities. The corrected number of positive patients using the nomogram and the number of actual positive patients were calculated using bootstrapping validation (1,000 bootstrap resamples).

Results

Clinical characteristics of patients with and without bronchitis obliterans

There were 31 children with bronchitis obliterans (bronchitis obliterans group) and 116 with severe pneumonia (non-bronchitis obliterans group). The general demographics and clinical characteristics of the children in both groups are displayed in [Table S1](#).

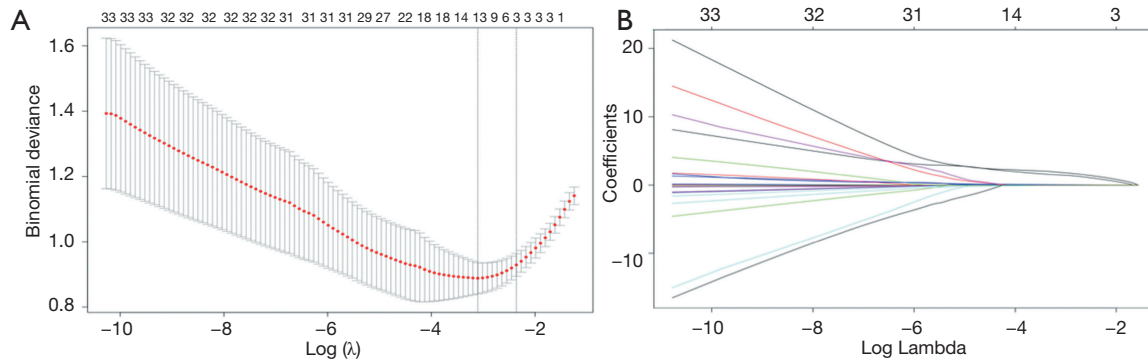


Figure 1 Thirty-nine variables selected using LASSO binary logistic regression analysis. (A) Tuning parameter (λ) selection using 10-fold cross-validation via minimum criteria to select the best penalty parameter lambda. (B) LASSO coefficient profiles of 39 variables. LASSO, least absolute shrinkage and selection operator.

Table 1 Logistic regression analysis of clinical characteristics associated with bronchitis obliterans

Variable	Univariate analysis		Multivariate analysis	
	HR (95% CI)	P	HR (95% CI)	P
Adenoviral	2.526 (1.597–3.992)	<0.001	2.259 (1.409–3.622)	<0.001
Length of symptoms (days)	1.034 (1.012–1.056)	<0.001	1.024 (1.004–1.044)	0.019
Mucosal abnormality	2.425 (1.497–3.929)	<0.001	1.802 (1.099–2.954)	0.02
BALF macrophages (%)	0.982 (0.974–0.991)	<0.001	0.987 (0.978–0.996)	0.003

HR, hazard ratio; CI, confidence interval; BALF, bronchoscopic airway lavage fluid.

Independent diagnostic factors and model construction

After application of the LASSO logistic regression analysis, four of the 39 clinical candidate parameters were used to develop the nomogram (Figure 1). The results of the univariate and multivariate analyses are displayed in Table 1. Multivariate analyses demonstrated that adenoviral infection, length of symptoms, the percentage of macrophages in BALF, and mucosal abnormalities (including bronchial mucosa hyperemia, swelling, erosion, and mucosal shedding) were independent clinical characteristics of bronchitis obliterans. A model containing these four independent clinical characteristics was constructed and visualized using a nomogram (Figure 2).

Validation of the nomogram

Internal bootstrapping validation was used to evaluate the performance of the nomogram. The C-index of the constructed nomogram was 0.91 (95% CI, 0.878 to 0.942), and the Akaike information criterion (AIC) was 66.484.

The calibration curve showed that the deviation was very slight, and there was good agreement between the diagnostic probability and the actual probability (Figure 3). The Hosmer-Lemeshow test demonstrated no statistical significance (Chi-square =0.798, P=0.5443), demonstrating that there was no departure from perfect fit.

Comparison with different models

To assess the values of different models that might help distinguish bronchitis obliterans from severe pneumonia, we compared two models. Model 1 involves clinical parameters, and model 2 involves clinical parameters with addition of bronchoscopy (Table 2). The areas under the ROC curves (AUC) for models 1 and 2 were 0.882 (95% CI, 0.811 to 0.954) and 0.909 (95% CI, 0.844 to 0.974), respectively (Figure 4).

The C-index of the model with addition of bronchoscopy was significantly higher (0.91; 95% CI, 0.878 to 0.942), suggesting that, if mucosal abnormality and the percentage of macrophages in BALF were integrated into the diagnostic

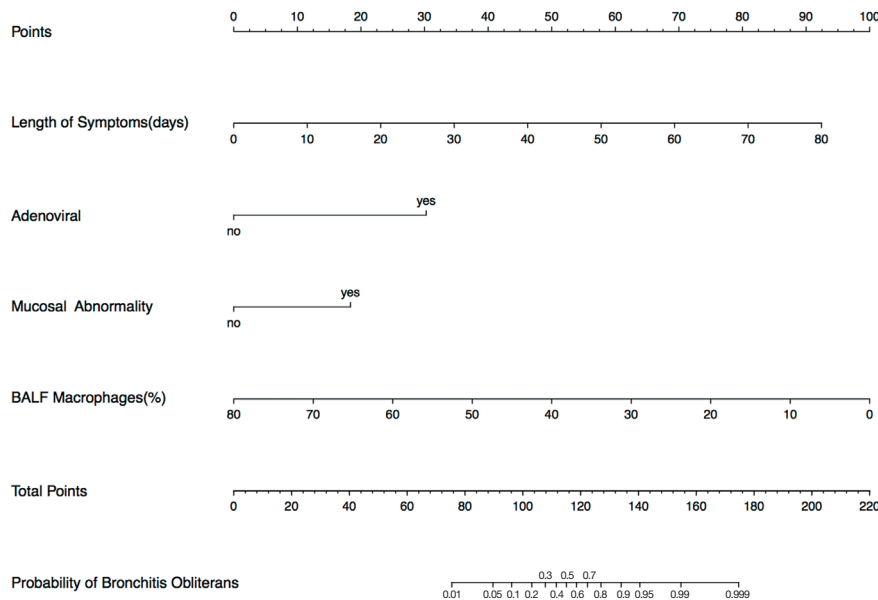


Figure 2 Nomograms to predict the risk of bronchitis obliterans.

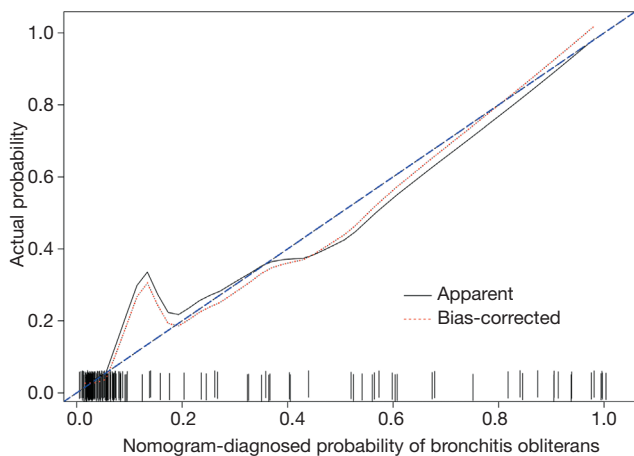


Figure 3 The calibration curve of the nomogram for diagnosis of bronchitis obliterans.

model, the performance of the diagnostic model would be significantly improved. The net reclassification index (NRI) was 0.2022 (95% CI, 0.008 to 0.3968; P=0.042). The integrated discrimination improvement (IDI) was 0.0975 (95% CI, 0.026 to 0.169; P=0.007).

Clinical use

DCA was used to evaluate the quality of the two models. The decision curves of the model with bronchoscopy

(nomogram) and the model without bronchoscopy are shown in *Figure 5*. The decision curves implied that if the threshold probability of a patient is >7%, using the nomogram to diagnose bronchitis obliterans was more beneficial than using either treat-all-patients or treat-none schemes.

Clinical impact curves demonstrated that there was a good consistency between the number of diagnosed positive patients on the nomogram and the actual number of positive patients (*Figure 6A*). TPR and FPR suggested that diagnosis of bronchitis obliterans at various threshold probabilities was adequate (*Figure 6B*).

Discussion

We developed and internally validated an effective nomogram using clinical characteristics for early diagnosis of bronchitis obliterans in children with severe pneumonia. Adenoviral infection, length of symptoms, the percentage of macrophages in BALF, and mucosal abnormalities were incorporated in the nomogram to identify bronchitis obliterans using a database from our hospital. The constructed nomogram provided a new, easy-to-use, tool for diagnosing bronchitis obliterans. Internal validation revealed that the nomogram showed good discrimination and calibration power. The C-index of the constructed nomogram was 0.91 (95% CI, 0.878 to 0.942), suggesting

Table 2 Different models for diagnosis of bronchitis obliterans in children with severe pneumonia

Intercept and variable	Model 1			Model 2		
	β	HR (95% CI)	P	β	HR (95% CI)	P
Intercept	-4.407	-	<0.001	-1.749	-	<0.001
Adenoviral	2.791	2.537 (1.597–4.029)	<0.001	3.508	2.259 (1.409–3.622)	<0.001
Length of symptoms (days)	0.175	1.031 (1.011–1.052)	0.002	0.134	1.024 (1.004–1.044)	0.019
Mucosal abnormality	-	-	-	2.128	1.802 (1.099–2.954)	0.02
BALF macrophages (%)	-	-	-	-0.145	0.987 (0.978–0.996)	0.003
C-index	-	0.884 (0.849–0.919)	-	-	0.91 (0.878–0.942)	-
AIC	-	100.41	-	-	66.48	-
NRI	-	0.2022 (0.0075–0.3968)	-	-	-	0.0481
IDI	-	0.0975 (0.026–0.169)	-	-	-	0.0075

β , regression coefficient; HR, hazard ratio; CI, confidence interval; BALF, bronchoscopic airway lavage fluid; AIC, Akaike information criterion; NRI, net reclassification index; IDI, integrated discrimination improvement.

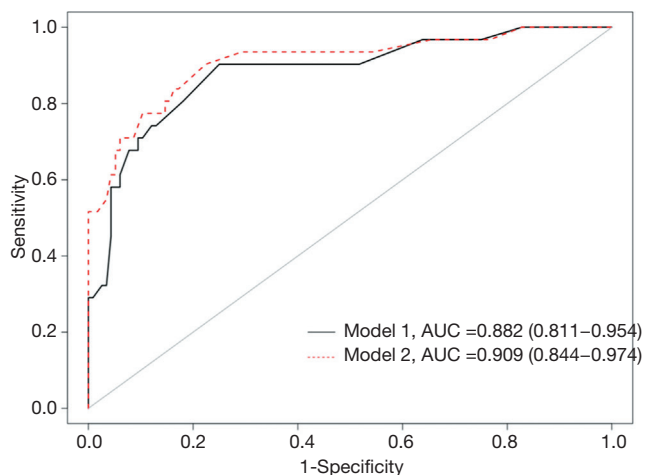


Figure 4 AUC of the models in diagnosis of bronchitis obliterans. The black solid line indicates the model without bronchoscopy. The red dotted line indicates the model with addition of bronchoscopy. AUC, area under curve.

that the nomogram could be used for large sample sizes, and could be widely and accurately used clinically.

A total of 51.6% of patients (16/31) with bronchitis obliterans underwent diagnostic tests for adenovirus infection, and multivariate analyses demonstrated that adenoviral infection was an independent clinical characteristic, suggesting that this can be used as one of the independent clinical characteristics to diagnose bronchitis obliterans in children with severe pneumonia.

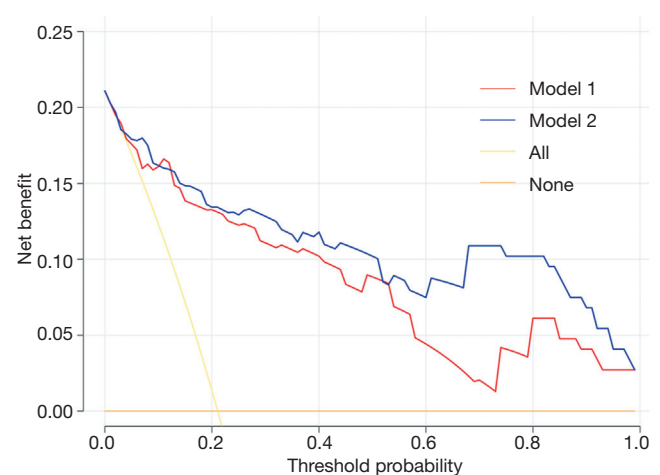


Figure 5 DCA for the model without bronchoscopy and the model with addition of bronchoscopy. The red line indicates the model without bronchoscopy, and the blue line indicates the model with bronchoscopy. The yellow line assumes that all patients have bronchitis obliterans, and the orange line assumes that no patients have bronchitis obliterans. The y-axis measures the net benefit. DCA, decision curve analysis.

The etiologies of bronchitis obliterans are unclear; bacteria, mycoplasma, and viruses have been associated with bronchitis obliterans (10,12,14). Many studies found that the most common diagnosis in the adenoviral-positive cases was pneumonia (86.11%); however, some adenoviral-positive cases presented with severe pneumonia

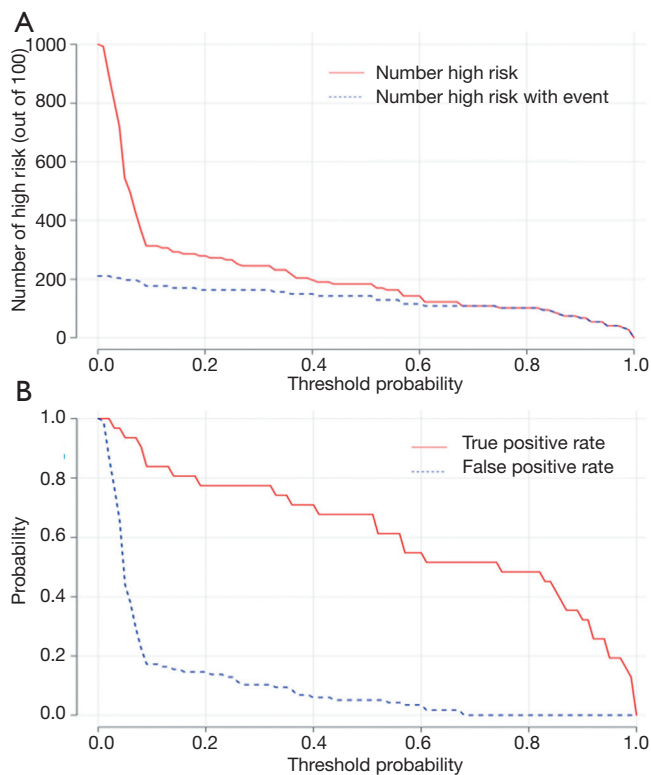


Figure 6 Clinical impact curves of the nomogram for diagnosis of bronchitis obliterans. (A) The number of diagnosed patients using the nomogram and the number of actual patients with bronchitis obliterans at various threshold probabilities. (B) TPR and FPR to predict bronchitis obliterans at various threshold probabilities. TPR, true positive rate; FPR, false positive rate.

or bronchiolitis obliterans (20). Factors such as age, environmental conditions, socioeconomic status, and immunological characteristics all would affect the severity of adenovirus infection. Sun et al. found that IL-6 and ESR were associated with the severity of adenoviral-7 respiratory infections; adenovirus infection could occur along the airway, and when the lesion involved the bronchioles, it developed rapidly (21). Severe pneumonia is therefore often associated with bronchiolitis obliterans, bronchitis obliterans, bronchiectasis, and pulmonary fibrosis.

In our study, duration of symptoms was another independent clinical characteristic. The duration of symptoms was longer in the bronchitis obliterans group (mean time 15 days; range, 11 to 23 days) than in the non-bronchitis obliterans group (mean time 10 days; range, 7 to 13 days). Among the 31 children with bronchitis obliterans, seven were infected with adenovirus alone and

20 (64.5%) were co-infected (mycoplasma-bacterial, viral-mycoplasma, viral-bacterial, or viral-viral infection). Some scholars reported that, compared with other viral infections, adenovirus infection is usually associated with longer fever duration and stronger inflammatory responses. The clinical manifestations of adenovirus infections are often similar to those of bacterial infections (22). Xie *et al.* compared the clinical characteristics of two groups of patients with single adenovirus and mixed bacterial infections and found that, compared with the single adenovirus group, the mixed bacterial infection group had longer hospital stays; however, oxygen treatment and pediatric intensive care unit admission rates were not significantly different between the groups (23). Considering that many patients with bronchitis obliterans often have multi-pathogen infections, the length of symptoms was longer in the bronchitis obliterans group. We assume that infection with multiple pathogens can suppress the innate immune response, resulting in slower pathogen clearance by the immune system, and therefore the length of symptoms of bronchitis obliterans would be longer.

We defined bronchial mucosal abnormality as bronchial mucosa hyperemia, swelling, erosion, or mucosal shedding. In our study, 17 of 31 patients with bronchitis obliterans had bronchial mucosal abnormalities on bronchoscopy. Several authors proposed that inflammation results in granulation tissue formation, protrusion of small polyp-like structures, and continued inward growth of granulation tissue resulting in obstruction; these findings are based on histologic findings of granulation tissue with occasional inflammatory cells; subsequently, these affected airways became totally occluded by membranes (6,16). Multiple fiberoptic examinations revealed that membranous tissue formed in all 31 children with bronchitis obliterans.

We compared the performance of two diagnosis models. Model 1 involved only clinical parameters, and model 2 involved clinical parameters with the addition of bronchoscopy. Compared with the two models, the NRI was 0.2022 (95% CI, 0.008 to 0.3968; $P=0.042$) and the IDI was 0.0975 (95% CI, 0.026 to 0.169; $P=0.007$). The accuracy of model 2 was increased by 9.75%. All patients with bronchitis obliterans were followed up for 1–3 years with high resolution computed tomography of the chest. We found that 23 of 31 children with bronchitis obliterans had inner bronchial diameters that were larger than those of adjacent (normal) bronchi (ratio >1).

There are some limitations in this study. First, the data were only based on a single hospital in Shanghai. Our

results reflected the characteristics of children in this area; therefore, external validation of findings would be desirable. Second, this was a retrospective study, and this too may introduce bias. Third, due to the ages of the children, patients with bronchitis obliterans could not perform pulmonary function testing. Some patients lacked pathological diagnosis due to the risk of biopsy in symptomatic patients or the unwillingness of their parents. Specific serotypes, genotypes, and molecular epidemiology of adenoviruses were not examined. Further prospective studies and external validation are needed to validate our model in other patients with bronchitis obliterans.

Conclusions

We constructed a nomogram on the basis of clinical characteristics to diagnose bronchitis obliterans. The nomogram can help clinicians to make early diagnoses in children in whom membranous tissue has not yet formed.

Acknowledgments

We acknowledge all patients and their parents involved in the study, and Dr. Quan Lu for his review of the manuscript.

Funding: None.

Footnote

Reporting Checklist: The authors have completed the TRIPOD reporting checklist. Available at <http://dx.doi.org/10.21037/tp-20-272>

Data Sharing Statement: Available at <http://dx.doi.org/10.21037/tp-20-272>

Conflicts of Interest: All authors have completed the ICMJE uniform disclosure form (available at <http://dx.doi.org/10.21037/tp-20-272>). The authors have no conflicts of interest to declare.

Ethical Statement: The authors are accountable for all aspects of the work in ensuring that questions related to the accuracy or integrity of any part of the work are appropriately investigated and resolved. The study was conducted in accordance with the Declaration of Helsinki (as revised in 2013). The study was approved by the institutional ethics committee of Shanghai Children's

Hospital (No. 2020R164-E01) and individual consent for this retrospective analysis was waived.

Open Access Statement: This is an Open Access article distributed in accordance with the Creative Commons Attribution-NonCommercial-NoDerivs 4.0 International License (CC BY-NC-ND 4.0), which permits the non-commercial replication and distribution of the article with the strict proviso that no changes or edits are made and the original work is properly cited (including links to both the formal publication through the relevant DOI and the license). See: <https://creativecommons.org/licenses/by-nc-nd/4.0/>.

References

1. Walker CLF, Rudan I, Liu L, et al. Global burden of childhood pneumonia and diarrhoea. *Lancet* 2013;381:1405-16.
2. Bhutta ZA, Das JK. Global burden of childhood diarrhea and pneumonia: what can and should be done? *Pediatrics* 2013;131:634-6.
3. Floyd J, Wu L, Hay Burgess D, et al. Evaluating the impact of pulse oximetry on childhood pneumonia mortality in resource-poor settings. *Nature* 2015;528:S53-9.
4. Chiu CY, Chen CJ, Wong KS, et al. Impact of bacterial and viral coinfection on mycoplasmal pneumonia in childhood community-acquired pneumonia. *J Microbiol Immunol Infect* 2015;48:51-6.
5. Hardy KA, Schidlow DV, Zaeri N. Obliterative bronchiolitis in children. *Chest* 1988;93:460-6.
6. Colin AA, Tsiligiannis TT, Nose V, et al. Membranous obliterative bronchitis: a proposed unifying model. *Pediatr Pulmonol* 2006;41:126-32.
7. Perlman EJ, Lederman HM, Taylor GA. "Bronchitis" obliterans and prolonged transient hypogammaglobulinemia in a child. *Pediatr Pulmonol* 1993;16:375-9.
8. Kampalath BN, McMahon JT, Cohen A, et al. Obliterative central bronchitis due to mineral dust in patients with pneumoconiosis. *Arch Pathol Lab Med* 1998;122:56-62.
9. Meysman M, Monsieur I, Noppen M, et al. Localised obliterative bronchitis due to non-occupation mineral dust inhalation. *Acta Clin Belg* 2000;55:341-3.
10. Chang AB, Boyce NC, Masters IB, et al. Bronchoscopic findings in children with non-cystic fibrosis chronic suppurative lung disease. *Thorax* 2002;57:935-8.
11. Ip MS, So SY, Lam WK, et al. Endobronchial tuberculosis revisited. *Chest*. 1986;89:727-30.

12. Edwards C, Penny M, Newman J. Mycoplasma pneumoniae, Stevens-Johnson syndrome, and chronic obliterative bronchitis. *Thorax* 1983;38:867-9.
13. Andersen P. Pathogenesis of lower respiratory tract infections due to Chlamydia, Mycoplasma, Legionella and viruses. *Thorax* 1998;53:302-7.
14. Quizon A, Minic P, Pohunek P, et al. Obliterative lower airway lesions in childhood: bronchoscopic diagnosis and clinical spectrum. *Pediatr Pulmonol* 2014;49:E27-34.
15. Medrek S, Bandi V, Xu Y, et al. Fatal progressive membranous obliterative bronchitis: a sequela of influenza? *J Bronchology Interv Pulmonol* 2017;24:88-91.
16. Chang AB, Masters IB, Everard ML. RE: membranous obliterative bronchitis: a proposed unifying model. *Pediatr Pulmonol* 2006;41:904; author reply 905-6.
17. WHO Organization Technical basis for the WHO recommendations on the management of pneumonia in children at first level health facilities. Geneva: World Health Organization, 1991.
18. Sauerbrei W, Royston P, Binder H. Selection of important variables and determination of functional form for continuous predictors in multivariable model building. *Stat Med* 2007;26:5512-28.
19. Vickers AJ, Cronin AM, Elkin EB, et al. Extensions to decision curve analysis, a novel method for evaluating diagnostic tests, prediction models and molecular markers. *BMC Med Inform Decis Mak* 2008;8:53.
20. Yao LH, Wang C, Wei TL, et al. Human adenovirus among hospitalized children with respiratory tract infections in Beijing, China, 2017-2018. *Virology* 2019;16:78.
21. Sun J, Xiao Y, Zhang M, et al. Serum inflammatory markers in patients with adenovirus respiratory infection. *Med Sci Monit* 2018;24:3848-55.
22. Korppi M, Leinonen PH, Launiala K. Mixed infection is common in children with respiratory adenovirus infection. *Acta Paediatr Scand* 1991;80:413-7.
23. Xie L, Zhang B, Zhou J, et al. Human adenovirus load in respiratory tract secretions are predictors for disease severity in children with human adenovirus pneumonia. *Virology* 2018;15:123.

Cite this article as: Sun C, Yan S, Jiang K, Wang C, Dong X. A preliminary nomogram constructed for early diagnosis of bronchitis obliterans in children with severe pneumonia. *Transl Pediatr* 2021;10(3):485-493. doi: 10.21037/tp-20-272