

Article

18 months computed tomography follow-up after Covid-19 interstitial pneumonia

Michela Barini,^{1*} Ilaria Percivale,^{1*} Pietro S.C. Danna,¹ Vittorio Longo,¹ Pietro Costantini,¹ Andrea Paladini,¹ Chiara Airoidi,² Mattia Bellan,² Luca Saba,³ Alessandro Carriero¹

¹Department of Diagnosis and Treatment Services, Radiodiagnostics, Azienda Ospedaliero Universitaria Maggiore della Carità, Novara; ²Department of Translational Medicine, University of Piemonte Orientale, Novara; ³Department of Medical Science, University of Cagliari, Italy

*These authors contributed equally to this work

Abstract

Background: Our aim is to evaluate the possible persistence of lung parenchyma alterations, in patients who have recovered from Covid-19.

Design and methods: We enrolled a cohort of 115 patients affected by Covid-19, who performed a chest CT scan in the Emergency Department and a chest CT 18 months after hospital discharge. We performed a comparison between chest CT scan 18 months after discharge and spirometric data of patients enrolled. We obtained quantitative scores related to well-aerated parenchyma, interstitial lung disease and parenchymal consolidation. A radiologist recorded the characteristics indicated by the Fleischner Society and “fibrotic like” changes, expressed through a CT severity score ranging from 0 (no involvement) to 25 (maximum involvement).

Results: 115 patients (78 men, 37 women; mean age 60.15 years old \pm 12.52). On quantitative analysis, after 18 months, the volume of normal ventilated parenchyma was significantly increased (16.34 points on average \pm 14.54, $p < 0.0001$). Ground-glass opacities and consolidation values tend to decrease (-9.80 and -6.67 points, $p < 0.0001$). On semiquantitative analysis, pneumonia extension, reactive lymph nodes and crazy paving reached statistical significance ($p < 0.0001$). The severity score decreased by 2.77 points on average (SD 4.96; $p < 0.0001$). There were not statistically significant changes on “fibrotic-like” changes correlated with level of treatment and there was not a statistically significant correlation between CT lung score and spirometric results obtained 18 months after discharge.

Conclusions: Patients recovered from Covid-19 seem to have an improvement of ventilated parenchyma and “fibrotic-like” alterations. The level of treatment does not appear to influence fibrotic changes.

Introduction

From November 2019, Coronavirus Disease 2019 (Covid-19) caused by SARS-CoV-2 has become a global pandemic, affecting over 123.902.242 people with 2.727.837 deaths according to the World Health Organization.¹ The clinical course of infection is extremely variable, from asymptomatic to severe pneumonia with multi-organ failure requiring critical care. SARS-CoV-2 was reported to utilize angiotensin-converting enzyme-2 (ACE2), as the cell receptor in humans,² causing pulmonary interstitial damages and subsequent parenchymal changes; consequently, lung injury is a predominant feature of acute SARS-CoV-2 infection.³

No data exist about the natural history of inflammatory infiltrates during recovery from SARS-CoV-2 nor the utility of any treatment in patients with persistent inflammatory interstitial lung disease (ILD) following infection with coronavirus.³ Recent publications showed that about 94% of hospitalized patients have persistent lung damage on their discharge computed tomography (CT) scan. Although we are aware that there is no consensus concerning this alteration nomenclature, as long as the Fleischner glossary for CT signs of fibrosis was developed in the setting of chronic fibrotic disease⁴ and was not based on CT features during recovery from acute lung injury, and apparent fibrosis on CT is not synonymous with true fibrosis,⁵ which is defined histologically and generally get worse, we decided to adopt a general terminology as “fibrotic-like” changes. According to Han *et al.*,⁶ in the 4th week after the first CT scan, bronchiectasis was identified in 15.4% and evidence of pulmonary fibrosis in 23.7% of patients. Lung fibrosis included parenchymal bands, traction bronchiectasis, irregular interfaces, and honeycombing.⁷ 62% of SARS patients evidenced fibrosis on CT after discharge. On a six-months follow-up, there was a significant decrease in the incidence of ground-glass opacities (GGO), consolidation, and pleural effusion

Significance for public health

After more than a year from first SARS-CoV-2 infection cases in Europe, alongside the always current problems of diagnosis and clinical management, a new criticism is emerging: the possible long-term outcomes that Covid-19 patients may have. To try to answer at least in part this question, in agreement with the pulmonologists of our center, we decided to select a group of patients who have overcome Covid-19, with heterogeneous levels of intensity of care, and to perform a radiological and clinical 18 months follow-up. In this paper we made a comparison between the chest CT performed at the onset of the disease and the CT performed after 18 months, evaluating the evolution of the parenchymal alterations. We hope that the results obtained in this study can provide useful information in the future follow-up of patients affected by Covid-19, a central issue of public health in the coming years in many areas of the world.

compared to the recovery CT scan, while nodules, pleural traction, pulmonary atelectasis, and bronchiectasis were significantly higher.⁷ Pan *et al.* reported one year follow-up after Covid-19 diagnosis: chest CT showed abnormal findings in 25% of patients associated with subpleural reticular/cystic lesions in 13% of them. Older patients affected by severe Covid-19 or acute respiratory distress syndrome were more likely to develop lung sequelae 1 year after diagnosis.⁸

Fibrotic changes seem to appear frequently in patients overcoming serious forms of disease, especially those who required intensive care unit (ICU) recovery, longer hospitalizations, and/or with a higher inflammatory load. It is not clear the role of the virus itself and adjuvants factors such as over-infections, far-toxicities, or mechanical ventilation.⁹

Nowadays very little is known about the long-term outcome of Covid-19 infection, in particular about the permanent fibrotic changes that the virus may induce in the lung. Due to the high number of affected patients, understanding the longer-term implications is critical. The purpose of this study is to describe the evolution of lung disease on an 18-month follow-up chest CT scan in patients affected by Covid-19 pneumonia correlating CT results with clinical evaluation based on spirometric analysis 18 months after discharge.

Design and methods

This prospective study obtained ethical approval by the local ethical committee (IRB code CE 117/20) and has been conducted in accordance with the principles of the Declaration of Helsinki. Informed consent has been signed by patients enrolled in the study. We enrolled a cohort of 115 patients (Figure 1) affected by Covid-19 (78 men, 37 women; mean age 60,15 years; range 29-86 years) with the following inclusion criteria: Patients ≥ 18 years old; Patients with a chest CT scan in the emergency department (ED) at the onset of symptoms; Patients with one or two RT-PCR assays within 7 days of the first CT scan (confirmed diagnosis); Patients

with a follow-up chest CT scan 18 months after hospital discharge.

The exclusion criteria were: Patients diagnosed with SARS-CoV-2 pneumonia who did not get a CT scan in the ED; Patients without clinical data and whose information about respiratory therapy were not reported.

All chest CT scans were performed during a single full inspiratory breath-hold in supine position; the ED scans were performed on a 64-slice CT (PHILIPS Ingenuity), while the follow-up Chest CT scans were performed on a 256-slice CT (PHILIPS Brilliance ICT). The scan technical average parameters were: tube voltage: 120 kV; tube current modulation: 142 mAs; spiral pitch factor: 1.420; collimation width 0.625, matrix 512 (mediastinal window) and 768 (lung window). All images were reconstructed with a slice thickness of 1 mm. The images in Digital Imaging and Communications in Medicine (DICOM) extension files were transferred to the Picture Archiving and Communication System (PACS) of our institution and then analyzed into a workstation equipped with two 35×43 cm monitors (produced by Eizo, with 2048×1536 matrix). Both a quantitative and a semiquantitative scoring system were used to estimate the extension of pulmonary involvement of all the findings.

Quantitative analysis: method of lung segmentation

CT images acquired were processed via 3D slicer software (Figure 2). The three main characteristics analyzed on lungs affected by Covid-19 pneumonia were: 1) well-aerated parenchyma; 2) interstitial lung disease, including both ground-glass opacities and crazy paving; 3) parenchymal consolidation.

The lung parenchyma segmentation was performed by a software-based evaluation on a dedicated workstation using the open-source 3D Slicer Software (version 4.10.2, <https://www.slicer.org>),¹⁰ using the software tools called “Segment Editor” and “Segment Quantification”.

To segment the lungs affected by Covid-19 pneumonia, we decided to use the threshold-based method that creates binary partitions based on image attenuation values in a simple, fast and effective way, thanks to the well-defined densitometric difference between air and lung.

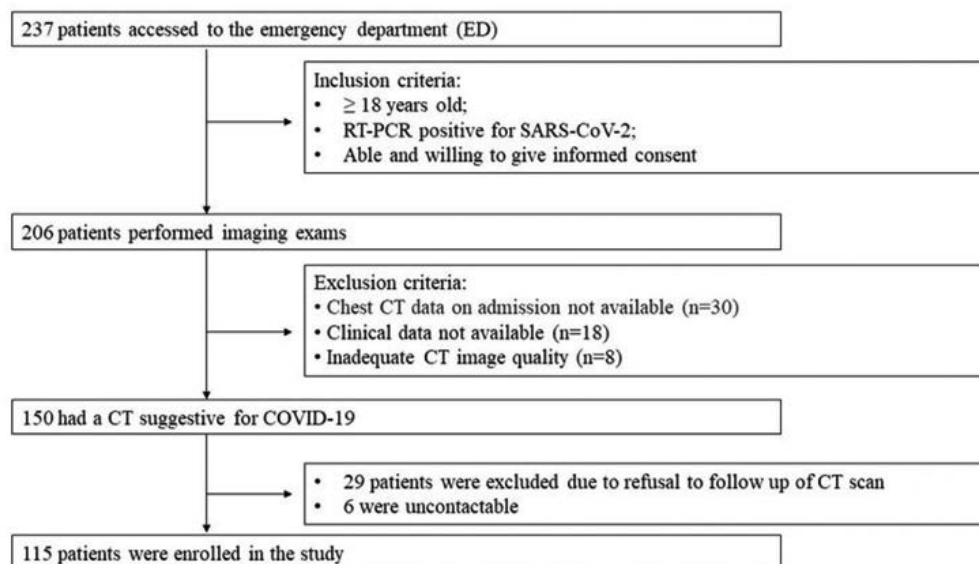


Figure 1. Participant flow diagram.

Semiquantitative analysis

All CT scans have been evaluated by a radiologist with more than 10 years of experience in chest CT scan and who was not involved in the final image interpretation. Both lung (width, 1600 HU; level, - 550 HU) and mediastinal (width, 400 HU; level, 40 HU) window settings were evaluated. For each patient the predominant CT patterns according to Fleischner Society⁴ have been identified (Figure 3):

- GGO opacities
- Consolidation
- Presence of crazy paving
- Presence of reverse halo sign
- Bilateral involvement
- Lymphadenopathy
- Pleural effusion
- Pericardial effusion

CT patterns have been classified, according to the RSNA consensus statement on Reporting Chest CT Findings Related to COVID-19, as “typical appearance”, “indeterminate appearance”, “atypical appearance” and “negative for pneumonia”.¹¹ GGO

opacities, crazy paving, and parenchymal consolidation have been scored with “3D Slicer software” and confirmed by the radiologist.

According to Han⁷ and Fleischner Society glossary,⁴ the evidence of “fibrotic-like” changes, was defined as the presence of:

- Honeycombing
- Bronchiectasis
- Lung distortion

To evaluate “fibrotic-like” alterations, each of the five pulmonary lobes was visually scored from 0 to 5 as (0) no involvement, (1) less than 10% involvement, (2) 10–25% involvement, (3) 26–50% involvement, (4) 51–75% involvement, and (5) 76–100% involvement. The scores were added together to provide a total CT severity score ranging from 0 (no involvement) to 25 (maximum involvement).

In order to better compare “fibrotic-like” changes we identified 3 categories of lung involvement on the basis of fibrotic score: mild alteration (score 0-5), moderate (score 6-15), and severe (score 16-25) (Figure 4); given that the third group (severe score) was few, we added together the moderate and severe groups for a statistical purpose.

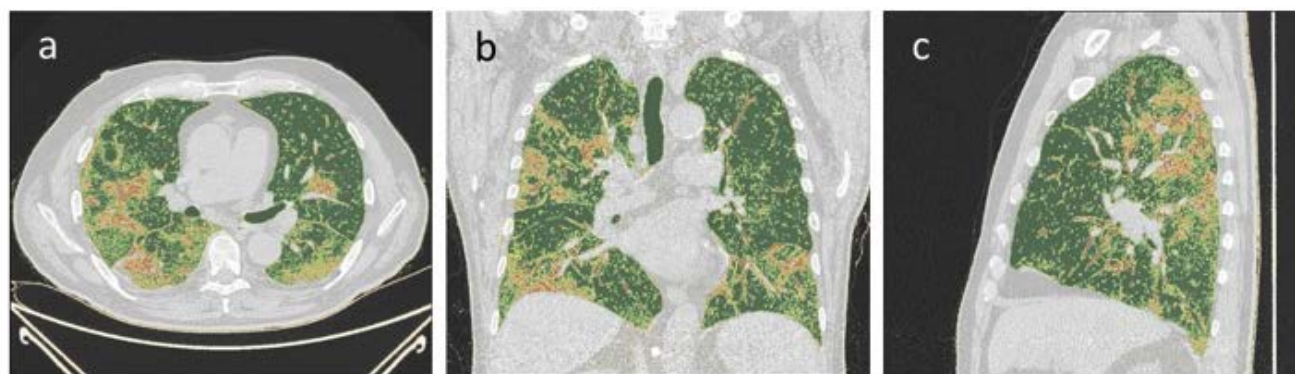


Figure 2. CT scan of a 45-year-old man analyzed with 3D slicer. a) The axial thin-section scan shows ground-glass opacities highlighted in yellow by the operator. Then, the program calculates the volume of the healthy lung parenchyma, the percentage of lung parenchyma occupied by the ground-glass opacities, and the percentage of consolidation. b,c) Coronal and sagittal thin-section scan, red areas indicate consolidation.

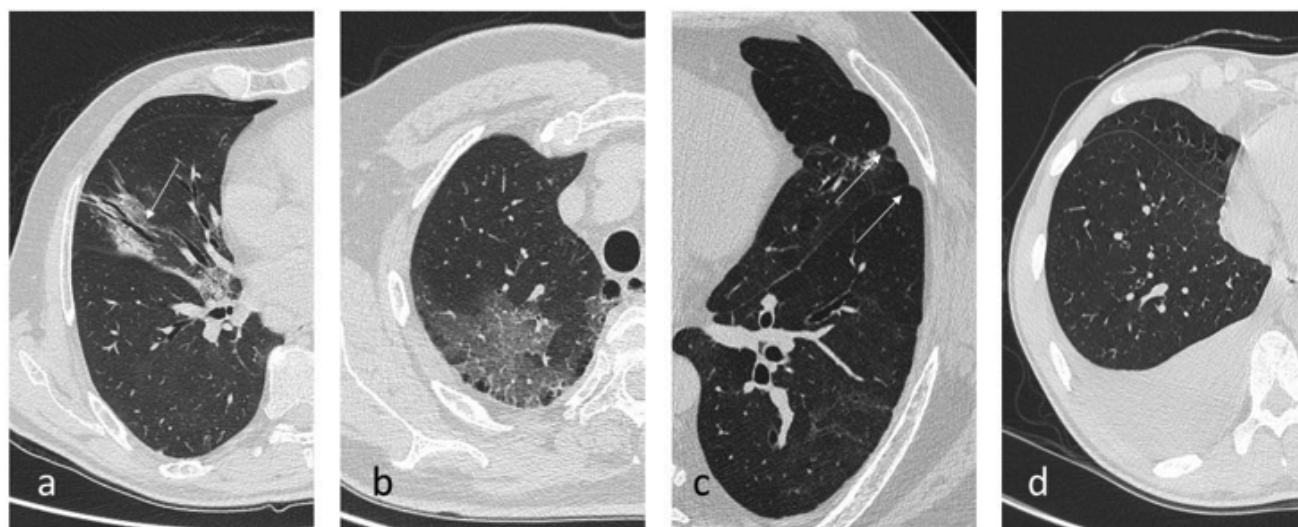


Figure 3. Chest CT findings of COVID-19 pneumonia. a) Traction bronchiectasis. b) Ground-glass opacities. c) Pleural effusion.

Clinical analysis

All Patients enrolled have been evaluated by a physician with more than 10 years of experience in respiratory disease and who did not know Ct scan results. A quantitative analysis was performed through spirometry 18 months after discharge. FEV₁, FVC, TLC and DLCO were evaluated.

Outcome analysis

Clinical data and prognosis have been reported for each patient admitted to ED. In particular, the authors evaluated if patients needed hospitalization or home therapy (consisting of azithromycin, paracetamol, corticosteroid, and anticoagulant only in selected patients, following national guidelines) and the use of oxygen therapy, or invasive ventilation or not.

Statistics analysis

Descriptive statistics were conducted considering the whole sample; absolute and relative frequencies were presented for categorical variables while for numerical ones we reported mean and standard deviation and median and interquartile range [Q1-Q3]. To evaluate the difference in time (18 months follow-up vs baseline) of continuous variables we used parametric and non-parametric paired tests, based on the normality assumption. Moreover, time changing of categorical variables was assessed using Mc Nemar test. Then, a model (Figure 5) was performed considering as outcome the fibrosis score measured at 18 months follow-up CT scan, and as covariate the type of respiratory therapy and the score at baseline. A graphic model has been built for correlation between

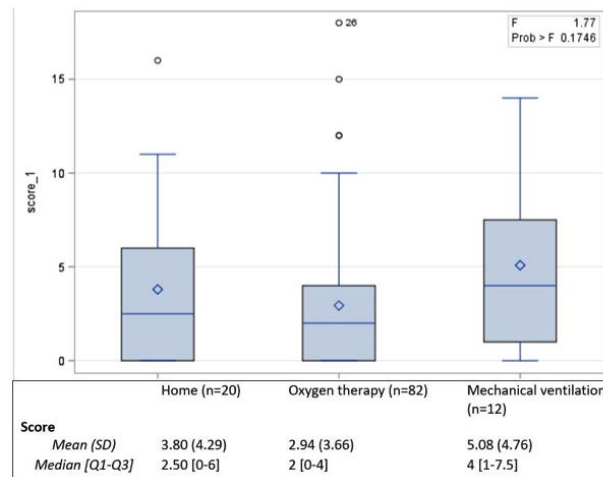


Figure 4. Statistical model of correlation between fibrotic score and respiratory therapy.

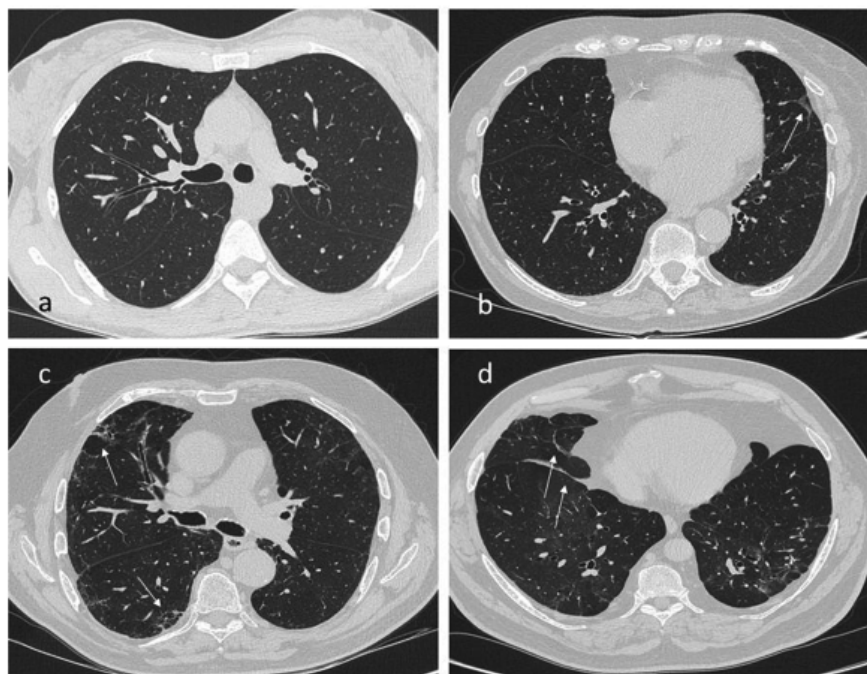


Figure 5. Subdivision according to parenchymal bands severity degree at 18 months CT. a) No visible alterations. b) Mild parenchymal bands. c) Moderate degree. d) Severe parenchymal bands.

spirometric data and Chest CT scan, in order to describe or not a linear correlation. The statistical significance was set at 0.05 (two tails) and all analyses were conducted using software SAS 9.4.

Results

Patients

115 patients who underwent a chest CT scan without contrast medium have been enrolled between March and May 2020. 18 months follow-up chest CT examination has been performed between 351 and 409 days after baseline (median = 366 days),

between March and April 2021. Patients included in the study were between 29 and 86 years old (60.15 years old on average) at the baseline and were predominantly male (67.83%). Among them, 82 (71.30%) people required oxygen therapy, 20 (17.39%) were discharged home and 12 (10.43%) required mechanical ventilation.

3D slicer pulmonary analysis

A 3D slicer analysis was performed on lungs affected by Covid-19 pneumonia at the baseline and 18 months follow-up. As reported in Table 1, normal ventilated lung parenchyma share tends to increase by 16.34 points on average (SD 14.54) with a statistically significant p-value (<0.0001). Consequently, pulmonary volume increased by 769.64 cm³ on average 18 months after

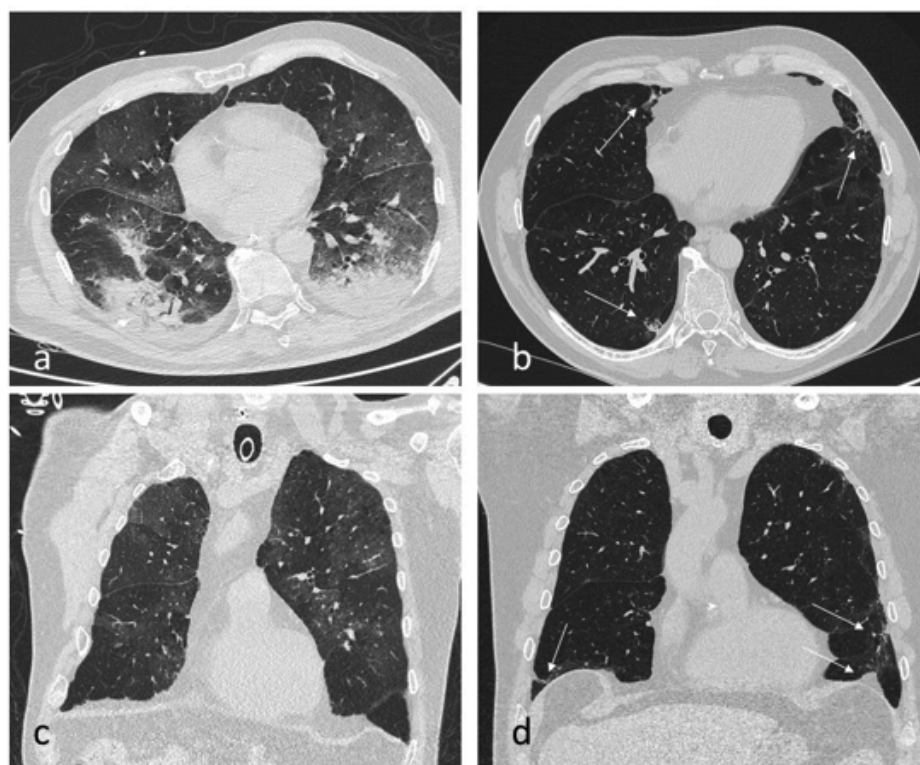


Figure 6. CT scan of a 69-year-old man with severe COVID-19 pneumonia. a,c) The axial and coronal thin-section scans, performed at our Emergency Department, showed multiple bilateral ground-glass opacities and parenchymal consolidation. b,d) The axial and coronal thin-section scans obtained 547 days after the first acquisition showed the persistence of some parenchymal bands.

Table 1. 3D slicer analysis at baseline and at 18 months follow-up.

3D slicer	Baseline	18 months follow-up	Difference	p-value
Healthy parenchyma (%)				
Mean (SD)	71.46 (14.86)	87.80 (6.31)	16.34 (14.54)	<0.0001
Median [Q1-Q3]	75 [63-83]	89 [87-92]	15 [6-26]	
GGO (%)				
Mean (SD)	20.92 (11.16)	11.12 (5.55)	-9.80 (10.44)	<0.0001
Median [Q1-Q3]	18 [12-27]	10 [8-12]	-7 [-16; -2]	
Consolidation (%)				
Mean (SD)	7.71 (6.80)	1.03 (1.68)	-6.67 (7.07)	<0.0001
Median [Q1-Q3]	6 [3-10]	0 [0-1]	-5 [-9; -2]	
Pulmonary volume				
Mean (SD)	4747.75 (1452.21)	5527.39 (1332.29)	779.64 (1240.44)	<.0001
Median [Q1-Q3]	4626 [3690-5642]	5386 [4601-6151]	741 [-93; 1479]	
Min-Max	2018-8864	2454-9464	-2982; 5511	

Covid-19 pneumonia ($p < 0.0001$). On the other hand, GGO and consolidation values tend to have an average decrease of respectively -9.80 (10.44%) and -6.67 (7.07%) points (median of -7 and -5 respectively) with a p-value statistically significant for both parametric and non-parametric tests.

Lung changes

Radiological changes in the pleuro-parenchymal and thoracic findings (unilateral or bilateral pneumonia, pleural effusion, reactive lymph nodes, pericardial effusion, crazy paving, reverse halo sign, bronchiectasis, and pleural retraction) were examined and reported in Table 2. On 115 patients enrolled, 8 patients affected by unilateral pneumonia and 81 patients affected by bilateral pneumonia at the first CT scan, showed a complete resolution at 18 months

CT follow-up. In 6 patients affected by bilateral pneumonia at the baseline, unilateral pneumonia was detected at 18 months CT follow-up. Finally, 19 patients did not improve their radiological condition and reported a bilateral pneumonia impairment both at baseline and at 18 months chest CT follow-up (Figure 6). All these data are statistically significant ($p < 0.0001$). A complete resolution of crazy paving sign and reverse halo sign was reported in 60 patients ($p < 0.0001$) and 4 patients ($p = 0.0455$) compared to baseline. We also detected a reduction of reactive lymph nodes. At 18 months chest CT follow-up, only 8.7% of patients had mediastinal reactive lymph nodes. Regarding pleural and pericardial effusion, a complete resolution was reported in all subjects (5 patients and 4 patients respectively). An important analysis related to “fibrotic-like” changes is about bronchiectasis: 11 patients showed complete

Table 2. CT changes at baseline and at 18 months follow-up.

Pneumonia		No	18 months follow-up		Total	p-value
			Unilateral	Bilateral		
Baseline		No	1	0	0	1 (0.87)
<0.0001						
	Unilateral	8	0	0	8 (6.96)	
	Bilateral	81	6	19	106 (92.17)	
		90 (78.26)	6 (5.22)	19 (16.52)	115	
Pleural effusion		No	Yes	Total		
Baseline	No	110	0	110 (95.65)		0.0253
	Yes	5	0	5 (4.35)		
		115 (100)	0	115		
Reactive lymph nodes		No	Yes	Total		
Baseline	No	76	2	78 (67.83)		<0.0001
	Yes	29	8	37 (32.17)		
		105 (91.30)	10 (8.70)	115		
Pericardial effusion		No	Yes	Total		
Baseline	No	111	0	111 (96.52)		0.0455
	Yes	4	0	4 (3.48)		
		115 (100)	0	115		
Crazy paving		No	Yes	Total		
Baseline	No	55	0	55 (47.93)		<0.0001
	Yes	60	0	60 (52.17)		
		115 (100)	0	115		
Reverse halo sign		No	Yes	Total		
Baseline	No	111	0	111 (96.52)		0.0455
	Yes	4	0	4 (3.48)		
		115 (100)	0	115		
Bronchiectasis		No	Yes	Total		
Baseline	No	92	6	98 (85.22)		0.2253
	Yes	11	6	17 (14.78)		
		103 (89.57)	12 (10.43)	115		
Score (categorical)		0-5	6-25			
Baseline	0-5	46	7	53 (46.09)		<0.0001
	6-25	46	16	62 (53.91)		
		92 (80.00)	23 (20.00)	115		

Table 3. Semiquantitative score at baseline and at 18 months follow-up.

Semi-quantitative	Baseline	18 months follow-up	Difference	p-value
Total score				
Mean (SD)	6.05 (4.30)	3.29 (3.92)	-2.77 (4.96)	
Median [Q1-Q3]	6 [3-9]	2 [0-4]	-3 [-6; 0]	<0.0001
Min-Max	0-20	0-18	-19; 13	

resolution while 6 patients still had bronchiectasis at 18 months chest CT follow-up. On the other hand, 6 patients who did not have bronchiectasis at baseline showed them at 18 months follow-up.

Score analysis

“Fibrotic-like” alterations (honeycombing, bronchiectasis, and lung distortion) have been evaluated through a score for each pulmonary lobe (from 0 to 5 for each lobe with a result ranging from 0 to 25 for each Patient) both at baseline and at 18 months follow-up. This score was correlated to the therapeutic management of patients (three categories of patients: non-hospitalized, hospitalized in low-intensity wards, and requiring mechanical ventilation). In conclusion, the score decreased by 2.77 points on average (SD 4.96; $p < 0.0001$), which, correlated with the initial score, represents a 46% reduction; it means that most patients had a significant improvement in lung parenchyma status (Table 3). The final score is slightly higher in patients treated with mechanical ventilation, although it is not statistically significant ($p = 0.2512$). This result could be basically due to a high fibrotic score at baseline ($p = 0.0057$), rather than to the therapeutic management.

Clinical analysis

To obtain a significative statistical correlation between radiological and clinical point of view, Authors analyzed spirometric data of patients 18 months after hospital discharge. In particular, we focused on FEV₁, FVC, TLC and DLCO data, trying to correlate results with CT score. FEV₁ was considered as normal if $> 80\%$, pathological if $< 50\%$ ($< 30\%$ is severe) and mild when included between 80% and 50%. TLC was considered as normal if included between 80% and 120%, pathological if $< 80\%$ or $> 120\%$. DLCO and FVC were considered as normal if $> 80\%$ or pathological if $< 80\%$. As far as spirometry 18 months after hospital discharge, 102 patients had a normal FEV₁, 104 patients had a normal TLC, 102 patients had a normal FVC and 63 patients a normal DLCO; 8 patients reported pathological FEV₁ values, 6 patients had pathological TLC values, 47 patients had pathological DLCO values and 8 patients pathological FVC values; 5 patients enrolled in this study were not able to perform spirometry.

Unfortunately, it was impossible to evaluate spirometric changes before and after SARS-CoV-2 infection because none of patients had never performed spirometry before. Therefore, we could not assert that pathological spirometric values were related to SARS-CoV-2 infection. The authors performed statistical analysis to understand if a correlation between lung CT score and spirometry could be detected; p -value obtained through Spearman correlation analysis was not significative.

Discussion

Although several studies in literature deal with the natural history and evolution of SARS-CoV-2 infection, there are still no papers concerning the evolution of radiological signs and Chest-CT patterns in Covid-19 pneumonia at mid/long-term (> 6 months).

In this paper, we report our experience on long-term chest CT follow-up in patients affected by Covid-19 pneumonia admitted to our ED. Following RSN consensus statement on reporting chest CT findings related to Covid-19⁵ and Fleischner society glossary,⁴ radiological signs (CT patterns) and clinical analysis (obtained through spirometry) have been analyzed at baseline (only radiological data) and 18 months after patient discharge. Starting from the point that Covid-19 pneumonia leads to “fibrotic-like” changes that might be irreversible, it is important to report the most important studies that influenced our analysis to better understand the way the authors built this paper. Pan *et al.* identified four CT stages of disease from the

onset of the initial symptoms: stage 1 (0-4 days), stage 2 (5-8 days), stage 3 (9-13 days), and stage 4 (more than 14 days). The number and severity of lesions at CT increase in the first 10 days, followed by a plateau phase and a gradual decrease in abnormalities.¹² The multicenter cohort study by Zhao *et al.*¹³ reported a high percentage of patients affected by abnormalities on chest CT scan 3 months after discharge. However, the rate of these abnormalities is lower than another study³ performed 7 days after patients’ admission, suggesting that lung abnormalities caused by Covid-19 infection might get better over time. Moreover, many publications found that a huge number of hospitalized patients (62%) have evidence of fibrosis after discharge.¹³ Han *et al.* performed a study where 35% of patients recovered for Covid-19 pneumonia developed fibrotic changes on 6-months follow-up, but it was not clear whether these changes represent an irreversible lung disease or not.⁷ However, it has been reported in literature a one-year follow-up experience where abnormal lung findings were just detected in 25% of patients affected by Covid-19 diagnosis.⁸ In particular, in 13% of patients with residual CT findings, subpleural reticular/cystic lesions were reported. As in the main studies concerning Covid-19 disease,¹⁴ in this paper, there was a male prevalence (78/115) with a mean age of 60,15 years. It is important to underline that only 18 months surviving and discharged patients who could perform a follow-up CT exam at 18 months were included in this report. In previous studies, indeed, patients affected by Covid-19 disease were enrolled without considering the prognosis.

Moreover, only patients with a baseline CT scan in the ED at the beginning of the disease were analyzed. This could be a selection bias because patients affected by mild diseases (who did not need a chest CT) were not included in this study. In this paper, the authors report interesting results concerning chest CT scan signs and patterns and their evolution during COVID-19 pneumonia. As far as lung parenchymal involvement is concerned, an increase in the amount of normal parenchymal lung and its volume has been reported. On the other hand, many typical COVID-19 pneumonia’ signs - such as GGO and pulmonary consolidation - had a significant decrease in the 18 months follow-up Chest CT-scan. Our results suggest a further improvement in pulmonary involvement compared to what Han *et al.*⁷ reported in six months control. In this paper, the authors report a decrease in “fibrotic-like” changes (evaluated with the score mentioned above) among the chest CT at baseline and 18 months follow-up CT. This result is different from Han *et al.* study⁶ where “fibrotic-like” alterations and correlated signs had an increase in six months chest CT follow-up.

Despite not being statistically significant, a reduction in bronchiectasis has been reported in our study. Probably the statistical analysis test was performed on a little sample, excluding Patients where these CT signs did not decrease. Consequently, a bigger sample could demonstrate the reduction of these CT signs at 18 months chest CT follow-up with a statistically significant p -value. Spirometric evaluation 18 months after discharge has been performed but unfortunately any statistical correlation with CT score decrease has been demonstrated. Another important suggestion reported in the study of Han *et al.*,⁶ is that the severity of pulmonary “fibrotic-like” changes could directly be related to the use of mechanical ventilation during treatment. Thanks to the statistical analysis and correlation among clinical and radiological variables, we found out that therapeutic management (none, mechanical ventilation, or oxygen therapy) did not influence the severity of “fibrotic-like” alterations on CT. Moreover, we maintain that the presence and the severity of “fibrotic-like” changes in the 18 months chest CT follow-up are only due to the severity of fibrotic chest CT pattern at baseline.

This study has several limitations. First, many clinical data have not been evaluated in this paper (such as the presence or not of smoking in anamnesis and other comorbidities) and that could influence

the evolution of “fibrotic-like” changes during and after Covid-19 pneumonia. Second, our sample probably excluded very mild cases of Covid-19 pneumonia who did not require a CT scan or ED access. Third, the authors do not have any clinical evaluation or spirometric data of patients enrolled before SARS-CoV-2 infection. Therefore, the authors could not analyze a statistical variation before and after disease. In addition, many severe cases who could not perform the 18 months CT scan were not included. Although it would be more appropriate to acquire CT scans at disease nadir, the exams were performed at ED access. Finally, the lack of a CT scan performed before the ED access is a limitation, because it is not possible to determine whether some findings could be present before Covid-19 infection.

In conclusion, follow-up CT scans obtained 18 months from disease onset show a significant improvement of lung fibrotic changes, thus suggesting the possibility of complete recovery from Covid-19 infection. Other studies are necessary to demonstrate the complete resolution of lung abnormalities through a longer radiological follow-up, in order to understand if there could be or not risk factors (clinical or not) that may lead to permanent pulmonary impairment.

Correspondence: Ilaria Percivale, Department of Diagnosis and Treatment Services, Radiodiagnostics, Azienda Ospedaliero Universitaria Maggiore della Carità, Novara, Italy.
E-mail: ilaperci@gmail.com

Key words: COVID; coronavirus; CT; lung; pneumonia.

Contributions: MB, IP, conceptualized and designed the study, drafted the initial manuscript, and reviewed and revised the manuscript; PSCD, VL, AP, PC, collected data, carried out the initial analyses, and reviewed and revised the manuscript; CA, analyzed data, reviewed and revised the manuscript; LS, AC, MB, participated to interpretation of data, coordinated, and supervised data collection, and critically reviewed the manuscript for important intellectual content. All the authors have read and approved the final version of the manuscript and agreed to be accountable for all aspects of the work.

Conflict of interest: The authors declare that they have no competing interests, and all authors confirm accuracy.

Availability of data and materials: All data generated or analyzed during this study are included in this published article.

Ethics approval and consent to participate: This prospective study obtained Ethical Approval by the Local Ethical Committee (IRB code CE 117/20) and has been conducted in accordance with the principles of the Declaration of Helsinki. Informed consent has been signed by patients enrolled in the study.

Informed consent: Written informed consent was obtained from a legally authorized representative for anonymized patient information to be published in this article.

Received for publication: 16 December 2021.

Accepted for publication: 10 January 2022.

©Copyright: the Author(s), 2022

Licensee PAGEPress, Italy

Journal of Public Health Research 2022;11:2782

doi:10.4081/jphr.2022.2782

This work is licensed under a Creative Commons Attribution NonCommercial 4.0 License (CC BY-NC 4.0).

References

1. World Health Organization. Coronavirus disease (COVID-19) pandemic. Available from: who.int/emergencies/diseases/novel-coronavirus-2019
2. Xu X, Chen P, Wang J, et al. Evolution of the novel coronavirus from the ongoing Wuhan outbreak and modeling of its spike protein for risk of human transmission. *Sci China Life Sci* 2020;63:457-60.
3. Myall KJ, Mukherjee B, Castanheira AM, et al. Persistent post-COVID-19 inflammatory interstitial lung disease: an observational study of corticosteroid treatment. *Ann Am Thorac Soc* 2021;18:799-806.
4. Hansell DM, Bankier AA, MacMahon H, et al. Fleischner Society: Glossary of terms for thoracic imaging. *Radiology* 2008;246:697-722.
5. Wells AU, Devaraj A, Desai SR. Interstitial lung disease after COVID-19 infection: A catalog of uncertainties. *Radiology* 2021;299:e216-8.
6. Han X, Cao Y, Jiang N, et al. Novel coronavirus pneumonia (COVID-19) progression course in 17 discharged patients: Comparison of clinical and thin-section CT features during recovery. *Clin Infect Dis* 2020;71:723-31.
7. Han X, Fan Y, Alwalid O, et al. Six-months follow-up chest CT findings after severe COVID-19 pneumonia. *Radiology* 2021;299:e177-86.
8. Pan F, Yang L, Liang B, et al. Chest CT patterns from diagnosis to 1 year of follow-up in COVID-19. *Radiology* 2022;302:709-19.
9. Alarcón-Rodríguez J, Fernández-Velilla M, Ureña-Vacas A, et al. [Manejo y seguimiento radiológico del paciente post-COVID-19]. [Article in Spanish]. *Radiologia* 2021;63:258-69.
10. Fedorov A, Beichel R, Kalpathy-Cramer J, et al. 3D Slicer as an image computing platform for the Quantitative Imaging Network. *Magn Reson Imaging* 2012;30:1323-41.
11. Simpson S, Kay FU, Abbara S, et al. Radiological Society of North America Expert Consensus Statement on Reporting Chest CT Findings Related to COVID-19. Endorsed by the Society of Thoracic Radiology, the American College of Radiology, and RSNA - Secondary Publication. *J Thorac Imaging* 2020;35:219-27.
12. Pan F, Ye T, Sun P, et al. Time course of lung changes at chest CT during recovery from coronavirus disease 2019 (COVID-19). *Radiology* 2020;295:715-21.
13. Zhao YM, Shang YM, Song WB, et al. Follow-up study of the pulmonary function and related physiological characteristics of COVID-19 survivors three months after recovery. *EclinicalMedicine* 2020;25:100463.
14. Han X, Cao Y, Jiang N, et al. Novel coronavirus disease 2019 (COVID-19) pneumonia progression course in 17 discharged patients: Comparison of clinical and thin-section computed tomography features during recovery. *Clin Infect Dis* 2020;71:723-31.