

## Reports and Recommendations

# Diagnosis and Management of Tumor-induced Osteomalacia: Perspectives From Clinical Experience

Kathryn Dahir,<sup>1</sup> María Belén Zanchetta,<sup>2</sup> Irinel Stanciu,<sup>3</sup> Cemre Robinson,<sup>4</sup> Janet Y. Lee,<sup>5</sup> Ruban Dhaliwal,<sup>6</sup> Julia Charles,<sup>7</sup> Roberto Civitelli,<sup>8</sup> Mary Scott Roberts,<sup>9</sup> Stan Krolczyk,<sup>9</sup> and Thomas Weber<sup>10</sup>

<sup>1</sup>Vanderbilt University Medical Center, Nashville, TN 37232, USA; <sup>2</sup>IDIM, Universidad del Salvador, C1055 AAG, Buenos Aires, Argentina; <sup>3</sup>Panorama Orthopedics and Spine Center, Golden, CO 80401, USA; <sup>4</sup>Icahn School of Medicine at Mount Sinai, New York, NY 10029, USA; <sup>5</sup>University of California, San Francisco, CA 94143, USA; <sup>6</sup>State University of New York Upstate Medical University, Syracuse, NY 13210, USA; <sup>7</sup>Brigham and Women's Hospital, Harvard Medical School, Boston, MA 02115, USA; <sup>8</sup>Washington University in St. Louis, St. Louis, MO 63130, USA; <sup>9</sup>Ultragenyx Pharmaceutical Inc., Novato, CA 94949, USA; and <sup>10</sup>Duke University School of Medicine, Durham, NC 27710, USA

**ORCID numbers:** 0000-0002-9980-9138 (K. Dahir); 0000-0002-9397-1847 (M. B. Zanchetta); 0000-0003-4813-6356 (C. Robinson); 0000-0002-3563-8843 (J. Y. Lee); 0000-0003-4179-4006 (R. Dhaliwal); 0000-0002-5875-314X (J. Charles); 0000-0003-4076-4315 (R. Civitelli); 0000-0001-6343-8649 (M. S. Roberts).

**Abbreviations:** 1,25(OH)<sub>2</sub>D, 1,25-dihydroxyvitamin D; 25-OH-D, 25-hydroxyvitamin D; <sup>68</sup>Ga-DOTA, Gallium 68 DOTATATE; FGF-23, fibroblast growth factor 23; PET/CT, positron emission tomography/computed tomography; SPECT/CT, single-photon emission computed tomography with computed tomography; TIO, tumor-induced osteomalacia; TmP/GFR, tubular maximum reabsorption rate of phosphate to glomerular filtration rate; XLH, X-linked hypophosphatemia

Received: 15 March 2021; Editorial Decision: 23 May 2021; First Published Online: 2 June 2021; Corrected and Typeset: 15 July 2021.

## Abstract

**Purpose:** Tumor-induced osteomalacia (TIO) is a rare paraneoplastic syndrome of abnormal phosphate and vitamin D metabolism caused by typically small endocrine tumors that secrete fibroblast growth factor 23 (FGF23). TIO is characterized clinically by progressive musculoskeletal pain, fatigue, proximal muscle weakness, and multiple fractures, leading to long-term disability. Misdiagnosis and delayed diagnosis are common because of the nonspecific symptoms, and several years may elapse before patients receive an accurate diagnosis and appropriate treatment. Thus, it is vital that awareness of the appropriate recognition and management of TIO is increased among healthcare professionals who may encounter patients with suspected TIO.

**Methods:** A roundtable meeting was held on 10 January 2020 in Dallas, TX, USA, to gather perspectives on the diagnosis and treatment of TIO. The following topics were considered: clinical presentation, patient history, differential diagnosis, laboratory assessment, imaging, venous sampling, and treatment.

**Results:** This report provides a summary of our collective experiences in the management of TIO.

**Main conclusions:** Laboratory tests are mandatory to expedite TIO diagnosis and should include measurement of fasting serum phosphorus, renal phosphate reabsorption, serum 1,25-dihydroxyvitamin D, and serum FGF23 levels. Functional and anatomical imaging are essential to locate the FGF23-secreting tumor(s) causing TIO. Surgical resection is often a curative treatment when the tumor can be localized; however, better management of patients who cannot be operated on with targeted therapies is needed. Further efforts to increase awareness of TIO within the medical community, and education on recommended diagnostic and treatment pathways are required to improve the management of this debilitating disease.

**Key Words:** hypophosphatemia, oncogenic osteomalacia, FGF23, muscle weakness, musculoskeletal pain, burosumab

Tumor-induced osteomalacia (TIO), also known as oncogenic osteomalacia, is a paraneoplastic syndrome of abnormal phosphorus and vitamin D metabolism caused by small, benign endocrine tumors that secrete the phosphaturic hormone, fibroblast growth factor 23 (FGF23), leading to impaired bone metabolism [1, 2]. TIO is characterized by progressive musculoskeletal pain, fatigue, proximal muscle weakness, gait disturbance, and multiple fractures [3, 4], which are a consequence of severe hypophosphatemia and may lead to long-term disability and prolonged morbidity [5].

TIO is a rare disease, with only approximately 1000 cases reported worldwide to date [1]. However, this likely represents an underestimation because no global population-based epidemiologic study has been conducted and the exact prevalence is unknown. The signs and symptoms of TIO are not specific for this condition and, consequently, >95% of cases may be misdiagnosed and treated incorrectly [3]; indeed, patients often wait several years to receive an accurate diagnosis [3]. Difficulty in localizing the tumor can further delay treatment.

As a rare disease likely to be encountered infrequently by most treating physicians, it is vital to exchange knowledge of treating TIO to help guide appropriate clinical decision making. This article aims to describe the clinical presentation of TIO and to provide a summary of the authors' collective experiences in the diagnosis and treatment of TIO.

## Methods

An industry-sponsored roundtable meeting on the diagnosis and management of TIO was held on 10 January 2020 in Dallas, TX, USA. Attendees were endocrinologists, rheumatologists, or oncologists experienced in the clinical diagnosis and management of TIO in the United States and Latin America. Raising awareness of the optimal pathway for the diagnosis and treatment of TIO was identified as an important initiative. Thus, this manuscript, which is based on

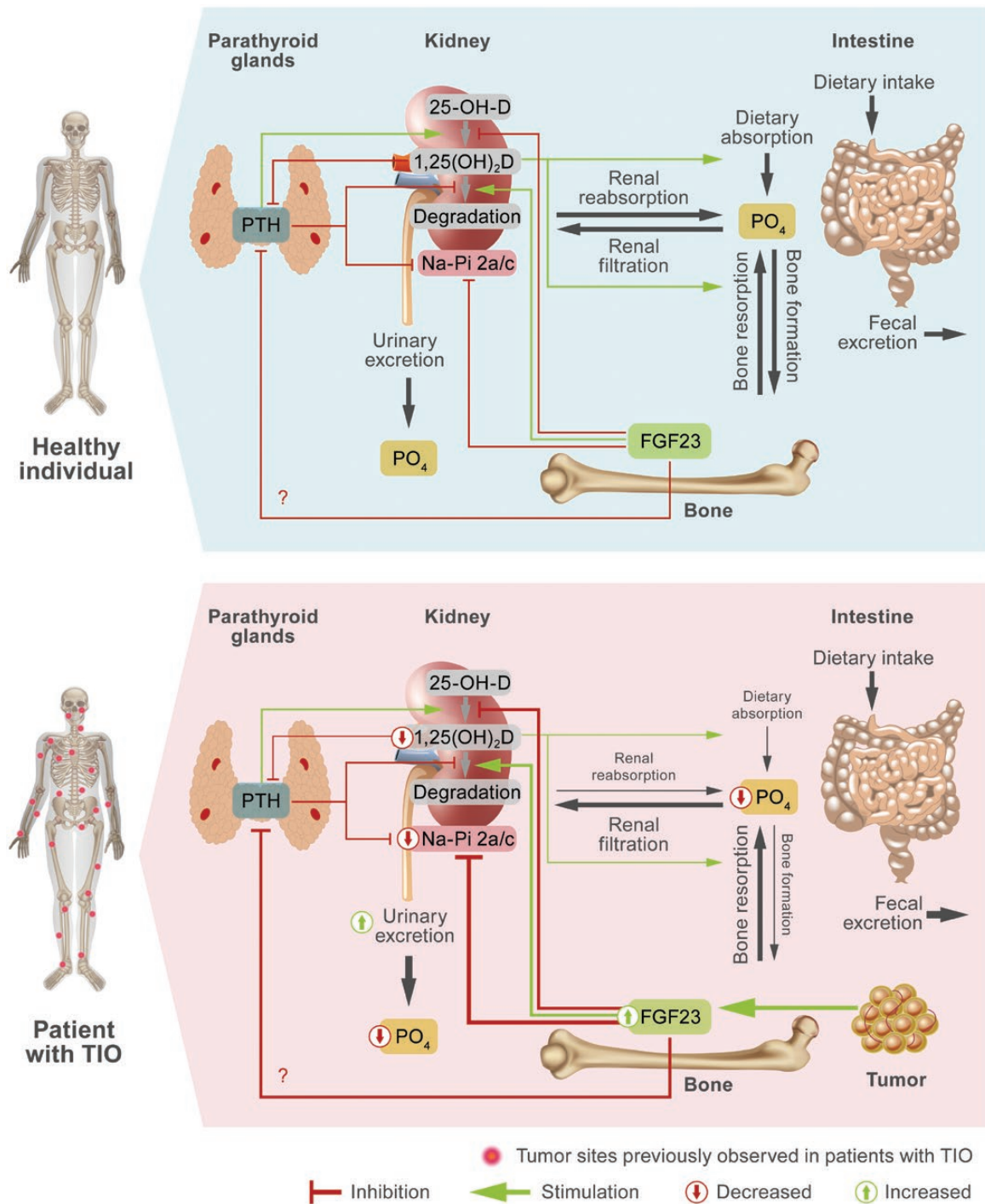
the discussions that took place among the authors during the meeting and subsequent conference calls, was conceived.

## Pathophysiology

An understanding of the key underlying disease processes (Fig. 1) is essential to appreciate the diagnostic and therapeutic approach to TIO.

Phosphorus is vital for normal physiology, including intracellular signaling, membrane function, energy metabolism, and bone mineralization [5, 10]. Phosphate homeostasis is regulated by intestinal uptake, exchange of phosphate between extracellular and bone storage pools, and renal reabsorption [5, 10]. Renal excretion, the primary mode of phosphate clearance, is under the control of PTH and FGF23 [5, 10].

In patients with TIO, lesions are typically small, benign mesenchymal tumors [11]. The key pathogenetic mechanism of TIO is uncontrolled tumoral production of FGF23 [12], which enhances phosphate wasting and reduces intestinal phosphate absorption, leading to chronic hypophosphatemia, decreased bone mineralization (osteomalacia), and other signs and symptoms of TIO [10, 13]. In 1 large series of 72 patients with TIO, nearly 50% of the 73 tumor samples analyzed were found to carry translocations between *FN1* (encoding fibronectin) and either *FGFR1* (encoding fibroblast growth factor receptor 1), or *FGF1* (encoding fibroblast growth factor 1), resulting in expression of abnormal chimeric proteins that are capable of ligand-independent signaling or autodimerization and binding to FGF23 [14]. These processes can lead to abnormal activation of FGFR1 signaling and, in turn, FGF23 overexpression, which further enhances signaling and FGF23 hyperproduction in a feed-forward autocrine/paracrine loop that not only drives the pathobiology of TIO, but may also be implicated in tumorigenesis [15].



**Figure 1.** Phosphate homeostasis in healthy patients and in tumor-induced osteomalacia. In patients with tumor-induced osteomalacia, increased secretion of FGF23 drives decreased renal phosphate reabsorption (shown with weighted lines) and decreased synthesis of  $1,25(OH)_2D$ , leading to reduced serum phosphate levels and a decreased rate of bone mineralization [4-10]. ?, The effect of FGF23 on PTH regulation is yet to be determined;  $1,25(OH)_2D$ , 1,25-dihydroxyvitamin D;  $25-OH-D$ , 25-hydroxyvitamin D; FGF23, fibroblast growth factor 23;  $Na-Pi$  2a/c, sodium/phosphate cotransporter 2a and 2c;  $PO_4$ , phosphate; PTH, parathyroid hormone; TIO, tumor-induced osteomalacia.

### Clinical Presentation

The onset of TIO is subacute in most cases, and initial symptoms may include musculoskeletal pain, fatigue, and proximal muscle weakness and/or atrophy, particularly in the lower extremities (Table 1). In a retrospective analysis

of 144 cases of TIO treated at a Chinese hospital, 99% presented with bone pain, 93% presented with difficulty walking, and 80% presented with stress or insufficiency fractures, primarily affecting the lower extremities [3]. Although approximately 80% of cases occur in adults

**Table 1.** Checklist of common signs and symptoms of tumor-induced osteomalacia

Symptom	Questions to consider	Proportion of patients presenting with symptom (%) <sup>a</sup>
Bone pain	Does the patient have a history of musculoskeletal pain, particularly in the lower extremities? Does the patient have tenderness to palpation over sites of suspected fracture?	99
Difficulty in walking	Has the patient reported difficulty with walking? Are any changes in gait apparent? If pediatric, does the patient have a wide-based nonantalgic gait? Does the patient require assistance with walking (eg, wheelchair, walking stick)?	93
Insufficiency fracture	Does the patient have a history of fractures? Is there evidence of multiple fractures on imaging?	80
Height loss	Does the patient have short stature? Is there any evidence of height loss?	69
Muscle weakness	Does the patient have proximal muscle weakness? Is there any evidence of muscle atrophy? Does the patient have symmetric motor weakness on sit-to-stand assessment?	65
Thoracic deformity	Is there any evidence of pectus carinatum? Is there any evidence of rickets?	33
Spinal deformity	Is there any evidence of kyphosis?	27
Abnormal oral cavity/dentition	Is there evidence of oral lesions? Are any teeth missing or loose? Is there any evidence of dental abscesses?	17
Local lump	Is there evidence of lumps on physical examination, particularly in the soft tissues of the lower extremities?	15

<sup>a</sup>Based on a retrospective analysis of 144 cases of tumor-induced osteomalacia treated at Peking Union Medical College Hospital, China, between December 1982 and December 2014 [3].

aged 20 years or older [9], TIO can present at any age, which can lead to potential misdiagnosis of X-linked hypophosphatemia (XLH) or other genetic causes of FGF23-mediated hypophosphatemia when TIO presents in younger individuals before growth-plate closure. In such cases, rickets, growth delay, and a wide-based, nonantalgic gait may occur, making the distinction from XLH even harder [4, 16]. As the duration and severity of hypophosphatemia increases, adult patients often present with height loss, kyphosis, and pectus carinatum (pigeon chest) resulting from multiple vertebral compression fractures [5], which have a catastrophic impact on patients' quality of life [17]. In severe cases, patients may require walking assistance [10].

### Patient Pathway

The signs and symptoms that may trigger a visit to a physician are not specific to the disease. TIO may often be confused with various musculoskeletal ailments and/or rheumatologic or neurologic disorders. In a retrospective study of 144 patients, the initial misdiagnosis rate was 95%; intervertebral disc herniation, spondyloarthritis, and osteoporosis were the most common misdiagnoses [3]. The mean time between symptom onset and a correct diagnosis

of TIO is 2.9 years [3], and in some cases has been up to 26 years [18]. Consequently, patients with TIO often cycle through several different medical specialties, including primary care physicians, rheumatologists, orthopedists, neurologists, chronic pain specialists, and psychologists before receiving an accurate diagnosis.

The omission of phosphorus from standard routine blood chemistry assessment panels in most institutions means that hypophosphatemia is likely to go undetected during routine assessments. The rarity of TIO and the low awareness of this condition within the medical community also contribute to delays in diagnosis. Increasing awareness of TIO is essential. When there is suspicion or confirmation of hypophosphatemia concomitant with common musculoskeletal symptoms, the patient should be referred to a metabolic bone specialist for appropriate diagnosis.

### Diagnosis

Although the clinical presentation outlined here should raise suspicion of TIO, a definitive diagnosis relies on a combination of thorough medical history, physical examination, laboratory tests, and imaging. In some cases, venous sampling, bone biopsy, and genetic analysis (chromogenic

in situ hybridization or RNA sequencing of the tumor) may be required. Obtaining detailed medical, family, and medication histories is also important to rule out other causes of hypophosphatemia. Useful algorithms for guiding the appropriate diagnosis of TIO have been published previously [1, 10].

### Patient history

A detailed medical history should be taken, including a review of symptom history and prior biochemistry, to evaluate onset of hypophosphatemia to assist in establishing the diagnosis of TIO. Medical care providers should rule out the more common causes of osteomalacia, including vitamin D deficiency, before unnecessarily undertaking the potentially expensive imaging (and/or invasive) assessments required to confirm the diagnosis of TIO.

Ruling out other causes of hypophosphatemia is also vital, including inherited FGF23-mediated phosphate metabolism disorders such as XLH and more rare diseases such as autosomal dominant hypophosphatemic rickets and autosomal recessive hypophosphatemic rickets. TIO can be distinguished from these disorders by the lack of family history, negative genetic testing, and previous history of normal phosphorus levels [5]. A history of multiple dental abscesses in childhood may point more toward a diagnosis of XLH rather than TIO [19, 20], whereas fractures in a pediatric patient are more likely to support the diagnosis of TIO. Generally, the younger the patient at presentation, the more likely hypophosphatemia is due to a genetic etiology rather than TIO [5]. Other relevant histories to capture include parental heights to determine mid-parental target height.

Acquired hypophosphatemia as a result of certain intravenous iron preparations or direct renal tubular damage by a toxin or a drug such as tenofovir should be considered [1]. In addition to a thorough review of concomitant medications, the key factor in discriminating these disorders from TIO is circulating FGF23, which is low in cases of tubular damage and high or inappropriately normal in TIO [5].

### Physical examination

A complete head-to-toe physical examination should be performed, including the skin and oral cavity, to potentially identify the underlying causative tumor, which can occur anywhere in the body. In an analysis of 287 patients with TIO, the most common tumor locations were the lower extremities (59.6%), followed by craniofacial regions (24.0%), torso (9.4%), and upper extremities (6.9%) [21]. Some of the key questions/physical

assessments to consider during physical examination are summarized in Table 1.

### Laboratory investigation

#### Serum tests

The panel of biochemical tests and example reference ranges useful for the diagnosis of TIO is shown in Table 2. Reference ranges may vary between laboratories.

Fasting serum phosphorus should be the first step for the diagnosis of TIO and other hypophosphatemic disorders. In patients with TIO, serum phosphorus levels are abnormally low [5]; in general, <3 mg/dL should raise suspicion of hypophosphatemia, <2.5 mg/dL is considered low, and <1.0 mg/dL is life threatening. Measurement should take place in a fasting state because food can affect serum phosphate by causing a shift from plasma into cells [25]. Once hypophosphatemia is established, 1,25-dihydroxyvitamin D (1,25(OH)<sub>2</sub>D) levels should also be measured. Low or inappropriately normal 1,25(OH)<sub>2</sub>D levels are consistent with FGF23 inhibition of 1 $\alpha$ -hydroxylation of 25-hydroxyvitamin D (25-OH-D) in kidney proximal tubule cells [5].

Repeat biochemical assessment with concurrent measurement of serum FGF23 and fasting phosphorus is an essential part of the diagnostic workup of patients with suspected TIO. Although FGF23 is generally measured using an antibody against the C-terminus, an assay that measures intact FGF23 is now available for clinical use. Intact FGF23 concentrations are not affected by iron deficiency or the presence of proinflammatory cytokines, which may cause falsely elevated levels with C-terminal assays [26-28]. FGF23 levels within the normal range are considered to be inappropriately normal in the presence of hypophosphatemia and should prompt further investigation because FGF23 should be suppressed in this context. An intact FGF23 level measured by the Kainos ELISA of >30 pg/mL is sensitive for the diagnosis of FGF23-mediated hypophosphatemia [29].

Other biochemical findings in patients with TIO typically include normal serum calcium and 25-OH-D, and elevated alkaline phosphatase [5]. If vitamin D deficiency is detected during biochemical evaluation of TIO, it should be adequately treated to normalize serum calcium and address potential impacts on intact PTH levels. Even in the setting of normal serum calcium and 25-OH-D, intact PTH may be elevated in patients with TIO because of inhibition of 1,25(OH)<sub>2</sub>D production by the excess FGF23, resulting in decreased intestinal calcium absorption [10]. These compensatory increases in intact PTH further worsen hypophosphatemia by promoting renal phosphate wasting

**Table 2.** Example reference ranges for common laboratory serum and urine tests (in practice, it is important to use reference ranges at the laboratory conducting the test to ensure accuracy)

Test	Normal range <sup>a</sup>		Direction of change in TIO
	Adult	Pediatric	
<i>Serum</i>			
Inorganic phosphate	2.5-4.5 mg/dL	4.0-7.0 mg/dL (1 d-1 y) 3.1-5.4 mg/dL (1-17 y)	↓
Calcium	8.6-10.7 mg/dL	7.3-11.9 mg/dL (1 d-1 mo) 8.7-11.0 mg/dL (1 mo-1 y) 9.3-10.6 mg/dL (1-17 y)	↔
PTH	15-65 pg/mL	15-65 pg/mL	↔
25-hydroxyvitamin D	20-50 ng/mL	20-50 ng/mL	↔
1,25-dihydroxyvitamin D	18-64 pg/mL (males) 18-78 pg/mL (females)	24-86 pg/mL (<16 y)	↓ or ↔
FGF23 (C-terminal fragment) <sup>b</sup>	≤180 RU/mL	≤230 RU/mL (3 mo-17 y) <sup>c</sup>	↑
FGF23 (intact) <sup>d</sup>	≤59 pg/mL	≤52 pg/mL (<18 y)	↑
Alkaline phosphatase	40-129 U/L (≥19 y; males) 35-104 U/L (≥17 y; females)	83-248 U/L (0-14 d) 122-469 U/L (15 d-1 y) 142-335 U/L (1-10 y) 129-417 U/L (10-13 y) 116-468 U/L (13-15 y; males) 57-254 U/L (13-15 y; females) 82-331 U/L (15-17 y; males) 50-117 U/L (15-17 y; females) 55-149 U/L (17-19 y; males)	↑
<i>Urine</i>			
%TRP	>80%	>80%	↓
TRP% = 100 × (1 - ((urine phosphate/urine creatinine) × (serum creatinine/serum phosphate)))			
TmP/GFR <sup>e</sup>	3.33-5.9 mg/dL (16-25 y; males)	5.7-8.1 mg/dL (newborn)	↓
if TRP is ≤0.86 (86%), then TmP/GFR = TRP × phosphate; if TRP is >0.86 (86%), then TmP/GFR = 0.3 × TRP / (1 - 0.8 × TRP) × phosphate	3.18-6.41 mg/dL (16-25 y; females) 3.09-4.18 mg/dL (25-45 y; males) 2.97-4.45 mg/dL (25-45 y; females) 2.78-4.18 mg/dL (45-65 y; males) 2.72-4.39 mg/dL (45-65 y; females) 2.47-4.18 mg/dL (65-75 y; males) 2.47-4.18 mg/dL (65-75 y; females)	3.6-5.4 mg/dL (1 month-2 y) 3.8-5.0 mg/dL (2-12 y) 3.4-4.6 mg/dL (12-16 y)	

%TRP, percent tubular reabsorption of phosphate; FGF23, fibroblast growth factor 23; GFR, glomerular filtration rate; IU, international unit; PTH, parathyroid hormone; RU, relative units; TIO, tumor-induced osteomalacia; TmP, tubular maximum reabsorption rate of phosphate.

<sup>a</sup>Unless otherwise stated, reference ranges based on normal ranges for common laboratory tests published by Mayo Clinic Laboratories (available at: <https://www.mayocliniclabs.com/test-catalog/index.html>), Rush University Medical Center (available at: <https://rml.rush.edu/Pages/RMLRanges.aspx>), and Global RPh (available at: <https://globalrph.com/>) but may vary depending on laboratory.

<sup>b</sup>Based on Immunotopics human FGF23 (C-Term) ELISA Kit, Quidel Corporation (2015).

<sup>c</sup>May be significantly elevated in healthy children aged <3 months.

<sup>d</sup>Based on Medfrontier FGF23 Intact assay (2019).

<sup>e</sup>Normal ranges based on the following references: [22-24].

in TIO patients with normal renal function. Elevations in intact PTH may be further exacerbated by long-term treatment with oral phosphate supplements, as is sometimes observed in XLH [30]. Indeed, cases of tertiary hyperparathyroidism have been reported in patients with TIO receiving long-term phosphate supplementation [31-35].

### Urine tests

Laboratory urine testing is often conducted in parallel with repeat serum testing. Assessing the tubular maximum reabsorption rate of phosphate to glomerular filtration rate (TmP/GFR) provides an estimate of renal phosphate handling and a direct measure of phosphorus loss [5].

The percentage tubular reabsorption of phosphate can be used instead when precise assessment of TmP/GFR is not possible [5]. Both methods offer a relatively simple and inexpensive method of diagnosing phosphaturic hypophosphatemia, particularly at centers where measurement of other biochemical markers may not be available. The method used is collection of fasting 2-hour urine for phosphorus and creatinine and simultaneously measuring serum phosphorus and creatinine.

In patients with suspected TIO, it is vital that the calculations of percentage tubular reabsorption of phosphate and TmP/GFR are done in the absence of phosphate supplementation to avoid the artificial elevation of urinary phosphate [5].

## Imaging

### Tumor imaging

A combination of functional (to detect metabolically active cells) and subsequent anatomical (to locate the tumor) imaging techniques are generally employed in patients with TIO (Table 3).

Functional imaging techniques use single-photon emission computed tomography with computed tomography (SPECT/CT) or positron emission tomography with CT (PET/CT) combined with different radioactive compounds, scanning the entire body to identify sites of high metabolic activity.  $^{18}\text{F}$ -fluorodeoxyglucose positron emission tomography with CT, can be a sensitive method for localizing tumors [39]. However, it is also nonspecific and identifies areas of metabolic activity that are not tumors, especially in patients with areas of active fracture healing [5]. Indium 111 octreotide (which has a high affinity for the somatostatin receptors present on many tumors) [40] combined with SPECT/CT (OctreoScan-SPECT/CT) is frequently used in patients with suspected TIO [41]. Gallium 68 DOTA ( $^{68}\text{Ga}$ -DOTA)-based somatostatin analogs ( $^{68}\text{Ga}$ -DOTA-Tyr<sup>3</sup>-octreotate,  $^{68}\text{Ga}$ -DOTA-Phe<sup>1</sup>-Tyr<sup>3</sup>-octreotide, and  $^{68}\text{Ga}$ -DOTA-Nal<sup>3</sup>-octreotide) are also available for imaging [1]. Inclusion of the positron emitter  $^{68}\text{Ga}$  allows for the combination of PET and CT for anatomical localization and resolution. A recent meta-analysis showed that  $^{68}\text{Ga}$ -DOTA-based PET/CT scans outperformed  $^{18}\text{F}$ -fluorodeoxyglucose positron emission tomography with CT and OctreoScan-SPECT/CT in the detection of TIO [21].  $^{68}\text{Ga}$ -DOTA-based PET/CT scans may also be more cost effective in the long run when compared with the alternative of repeated negative imaging that fails to confirm the diagnosis. However, access to this specialized imaging modality may be limited at some centers, may be cost prohibitive, and reimbursement may be restricted. Anecdotal reports of a number of other techniques, including  $^{201}\text{Tl}$  and  $^{99\text{m}}\text{Tc}$  methoxyisobutylisonitrile

scintigraphy, being used for tumor localization, have been published previously [42, 43]. Although not routinely performed, bone scintigraphy may also be useful for baseline assessment of patients with TIO because it can identify fractures missed on X-ray and potentially aid in tumor identification. However, radiation exposure can be more than 300 times higher than a chest radiograph [44].

Anatomical imaging may be used to confirm the specific location of the tumor and its surrounding tissues after suspicious lesions have been identified by functional imaging, and is helpful when consulting surgeons to discuss potential surgical approach to tumor resection. Several standard techniques can be used to localize tumors anatomically, including contrast-enhanced CT and magnetic resonance imaging [1]. The suspected anatomical location of the tumor, radiation exposure, access, cost, and risk/benefit should be considered when choosing the appropriate modality (Table 3).

The frequency of follow-up imaging is at the discretion of the treating physician.

### Skeletal imaging

Although it is commonly used in the assessment of bone density, which is decreased in patients with TIO [45], dual-energy X-ray absorptiometry does not exclude nonmineralized bone and so is not a good measure of bone mass in osteomalacia [10]. However, it can be safely and reliably used to monitor mineralization of the osteoid during treatment, an important measure of bone disease healing [46].

### Venous sampling

In most cases, the combination of functional and anatomical imaging will locate the FGF23-secreting tumor. However, if additional confirmation is required, venous sampling for assessment of FGF23 levels may be considered [47, 48]. If more than 1 lesion is found on functional imaging, or the suspected lesion is in an area where surgery may pose a high risk to the patient, venous sampling may be indicated to pinpoint the exact location of the FGF23-secreting tumor [47]. In patients without a suspected tumor location, the reported success of blind venous sampling has been inconsistent [47, 49]. Before undertaking venous sampling, the potential risks of this invasive procedure should be balanced against the expected benefits.

### Bone biopsy

Bone histomorphometry remains the gold standard for diagnosis of osteomalacia and to assess the severity of bone disease in TIO [10]. However, obtaining a bone biopsy is impractical and seldom necessary for a diagnosis of TIO.

**Table 3.** Imaging modalities commonly used in the management of patients with tumor-induced osteomalacia and their advantages and disadvantages based on the collective experiences of the authors

Modality	Advantages	Disadvantages	Radiation exposure per scan (mSv) [36-38]
<i>Functional imaging</i>			
<sup>68</sup> Ga-DOTA-based PET/CT	<ul style="list-style-type: none"> <li>Higher sensitivity than <sup>18</sup>F-FDG-PET/CT and <sup>111</sup>In octreotide SPECT/CT</li> <li>Quick (1.5-2 h)</li> <li>Cost effective</li> </ul>	<ul style="list-style-type: none"> <li>Accessibility</li> <li>Expensive</li> <li>Reimbursement challenges</li> </ul>	3
• <sup>68</sup> Ga-DOTA-Tyr <sup>3</sup> -octreotate [TATE]			
• <sup>68</sup> Ga-DOTA-Phe <sup>1</sup> -Tyr <sup>3</sup> -octreotide [TOC]			
• <sup>68</sup> Ga-DOTA-NaI <sup>3</sup> -octreotide [NOC]			
<sup>18</sup> F-FDG-PET/CT	<ul style="list-style-type: none"> <li>Widely available</li> </ul>	<ul style="list-style-type: none"> <li>Relatively high radiation exposure</li> <li>Expensive</li> <li>Low specificity</li> </ul>	22
<sup>111</sup> In octreotide SPECT/CT	<ul style="list-style-type: none"> <li>High sensitivity</li> </ul>	<ul style="list-style-type: none"> <li>Accessibility</li> <li>Time consuming (2 days)</li> <li>Very expensive</li> </ul>	12
Bone scintigraphy	<ul style="list-style-type: none"> <li>High sensitivity (in areas of increased bone turnover such as fractures, tumors, inflammation, etc.)</li> </ul>	<ul style="list-style-type: none"> <li>Relatively high radiation exposure</li> <li>Accessibility</li> <li>Expensive</li> <li>Low specificity</li> </ul>	4.2
<i>Anatomical imaging</i>			
CT	<ul style="list-style-type: none"> <li>Widely available</li> <li>Short evaluation time</li> <li>3D images</li> <li>High resolution</li> </ul>	<ul style="list-style-type: none"> <li>Relatively expensive</li> <li>Radiation exposure</li> </ul>	7.0 <sup>a</sup>
MRI	<ul style="list-style-type: none"> <li>No radiation exposure</li> <li>High resolution</li> <li>3D images</li> </ul>	<ul style="list-style-type: none"> <li>Expensive</li> <li>Long evaluation time</li> <li>Cannot be used in patients with implants</li> <li>Accessibility</li> <li>Sedation may be required, especially for younger patients</li> </ul>	0
<i>Other modalities</i>			
Dual-energy X-ray absorptiometry	<ul style="list-style-type: none"> <li>Short evaluation time</li> <li>High resolution of bone</li> <li>Intermediate price</li> </ul>	<ul style="list-style-type: none"> <li>2D images</li> <li>Low resolution of soft tissues</li> <li>Radiation exposure</li> <li>Not particularly helpful in the setting of osteomalacia</li> </ul>	0.001
Plain radiographs	<ul style="list-style-type: none"> <li>Widely available</li> <li>Inexpensive</li> <li>Short evaluation time</li> </ul>	<ul style="list-style-type: none"> <li>2D images</li> <li>Radiation exposure</li> <li>Poor resolution</li> </ul>	0.1 <sup>a</sup>

Abbreviations: <sup>18</sup>F-FDG-PET/CT, <sup>18</sup>F-fluorodeoxyglucose positron emission tomography with CT; 2D, 2-dimensional; 3D, 3-dimensional; <sup>68</sup>Ga-DOTA, Gallium 68 DOTA; <sup>111</sup>In, indium 111; CT, computed tomography; FDG, fluorodeoxyglucose; MRI, magnetic resonance imaging; PET, positron emission tomography; SPECT, single-photon emission computed tomography.

<sup>a</sup>Based on a single scan of the chest.

A bone biopsy should be considered when the diagnosis is not certain, or when defective healing of bone disease is suspected.

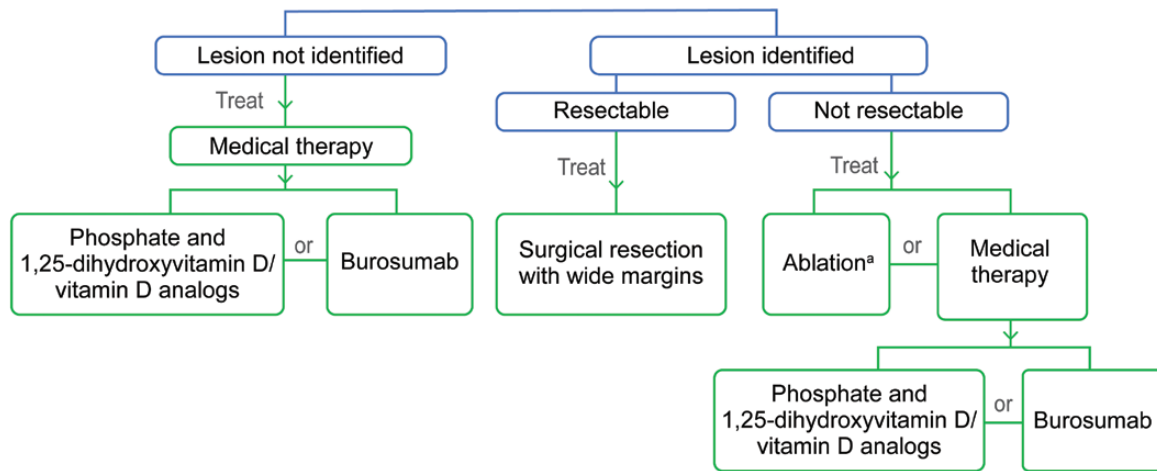
## Treatment

Surgical resection of the tumor remains the recommended first-line therapy for patients with TIO in whom the tumor can be identified and is considered operable (Fig. 2).

Complete removal of the tumor by wide resection is usually curative and prevents tumor recurrence [5, 10, 16]. Histologic assessment of the tumor can also confirm the diagnosis of TIO.

Following successful surgery, recovery can be rapid, with FGF23 and serum phosphate levels often returning to normal within days or weeks [41, 50]. The osteomalacic bone starts remineralizing immediately after normal phosphorus homeostasis is reestablished, and can





**Figure 2.** Tumor-induced osteomalacia treatment algorithm. When the lesion can be identified, surgical resection with wide margins is the recommended treatment. Medical therapy, with either burosumab or phosphate and 1,25-dihydroxyvitamin D/vitamin D analogs, should be considered in patients in whom the lesion cannot be identified or is not resectable. <sup>a</sup>Ablation may also be considered for nonresectable lesions, although the long-term efficacy of this approach is unknown.

result in very rapid and large increases in bone density [16, 45]. However, it may take up to a year for more substantial clinical improvement to occur, depending on the severity of the disease [5]. Follow-up monitoring of biochemistry is required after surgical success to confirm initial and continued remission; some physicians may also choose to assess bone mineral density via dual-energy X-ray absorptiometry to assure full skeletal remineralization. In a retrospective study of 230 patients with confirmed TIO, after primary surgery, the majority of cases remained in remission, but 11% of cases persisted and 7% of cases recurred with a median time of recurrence of 33 months [51].

When a localized tumor is not amenable to definitive resection because of anatomical location or risk of significant morbidity following surgical resection, less invasive modalities such as radiotherapy or CT-guided radiofrequency ablation can be considered. A recent case series showed that CT-guided radiofrequency ablation was effective and well tolerated in patients with TIO [52], although long-term efficacy is unknown. Radiotherapy has been described in cases of incompletely resected tumors, to avoid recurrence or metastases [48, 53].

In patients in whom the tumor cannot be identified or completely resected, pharmacotherapy is initiated. Standard treatment for adults is oral phosphate (1-3 g/d divided into 4 to 5 doses) and 1,25(OH)<sub>2</sub>D (0.75-3 µg/d divided into 2 to 3 doses) [5]. The goal of treatment is to achieve the low end of normal for age-appropriate range of phosphorus [5]. Administration is divided into several doses a day as the serum phosphate level decreases 1 to 2 hours after administration. The maximum dosage of oral phosphate may be limited by

development of secondary hyperparathyroidism, which, when not addressed, may progress to tertiary hyperparathyroidism.

Frequent monitoring and dose adjustment are required to avoid hypercalcemia, hypercalciuria, nephrolithiasis, nephrocalcinosis, and hyperparathyroidism [4, 5]. Serum calcium, phosphorus, creatinine, alkaline phosphatase and PTH, and 24-hour urinary excretion of calcium and creatinine should be measured within 4 to 6 weeks of initiation. Increased PTH, but normal serum calcium and urine calcium  $\leq 3.0$  mg/kg body weight/24 hours, suggests a sub-optimal dose of 1,25(OH)<sub>2</sub>D, which should be increased in 0.25-µg/d increments every 3 to 4 weeks until normal levels are reached. If the patient is hypercalciuric and serum PTH is normal/low 4 to 6 weeks after a dose change, the 1,25(OH)<sub>2</sub>D dose should be reduced. Once stable dosing of 1,25(OH)<sub>2</sub>D and phosphorus is achieved, frequent laboratory monitoring every 3 to 4 months for the first year of treatment and every 6 to 9 months thereafter should be performed in an effort to avoid hypercalcemia and hypercalciuria.

Although phosphate and 1,25(OH)<sub>2</sub>D treatment often results in biochemical and clinical improvements, patients may experience an incomplete clinical response, with subnormal phosphorus levels. Compliance to oral phosphorus is challenging because of the high doses required, its unpleasant taste, and possible gastrointestinal side effects. Thus, more effective pharmacotherapies for TIO are needed, especially for patients who cannot be cured by surgery.

Burosumab, a fully human monoclonal antibody against FGF23 [54], was approved in June 2020 for the treatment of adult and pediatric patients with TIO [55]. The starting

dose is 0.5 mg/kg every 4 weeks, which may be increased to 2 mg/kg (not exceeding 180 mg) every 2 weeks [56]. It is also approved in the United States for the treatment of XLH [54]. In a 144-week, open-label, phase 2 study in 14 adult patients with TIO in the United States, burosumab (0.3-2.0 mg/kg subcutaneously every 4 weeks) improved several measures of disease, including: phosphorus homeostasis through week 144; osteomalacia on bone biopsy at week 48; fracture healing and a reduction in the number of new fractures at week 144; and symptoms and physical function [57]. Burosumab had no significant changes in frequency, type, or severity of adverse events reported through 144 weeks [57]. Similar results were observed with burosumab in Japanese and Korean patients with TIO in a phase 2 open-label study [58].

Although no other therapeutic options are currently approved for the treatment of TIO, a number of alternative approaches have been investigated with mixed results, including chemotherapy, octreotide, and cryoablation [59-62]. Cinacalcet, an agonist of the calcium-sensing receptor, has shown some benefit in increasing renal phosphate reabsorption when used as adjuvant therapy with conventional treatments [63]. Promising results have also recently been published with the pan-FGFR tyrosine kinase inhibitor, infigratinib, in a case of metastatic TIO [64].

For patients who experience pain, referral to physiatry, occupational therapy, or physical therapy should be considered to address functional deficits, and referral to pain specialists may also be appropriate. Occupational therapy or physical therapy may be particularly important in postsurgical recovery, especially in severe cases where there was a long period of immobilization that resulted in muscle atrophy and general deconditioning.

## Conclusions

To expedite diagnosis of TIO, fasting serum phosphorus, renal phosphate reabsorption, serum 1,25(OH)<sub>2</sub>D, and serum FGF23 levels should be measured. The appropriate use of imaging, in particular <sup>68</sup>Ga-DOTA-based PET/CT scanning in conjunction with anatomical imaging when available, is essential to locate the FGF23-secreting tumor(s) driving TIO. Although surgical resection is often curative for operable tumors, improved medical management of nonlocalizable/nonresectable tumors is needed. The availability of targeted therapies such as burosumab is a promising new approach for such patients. Although this article offers advice regarding the diagnosis and management of TIO based on current practice, several potential opportunities to improve treatment are apparent, including generation of reliable epidemiologic data to better understand

the natural history of disease, as well as improved tumor localization strategies. Increased awareness of TIO within the medical community is vital to reduce the time it takes to reach a firm diagnosis. Ongoing research efforts will attempt to answer these and other open questions in the hope of furthering our understanding of TIO and improving treatment outcomes of this debilitating disease.

## Acknowledgments

The meeting where this article was conceived was funded by Ultragenyx Pharmaceutical Inc., in partnership with Kyowa Kirin International plc.

Medical writing assistance was provided by Ben Drever (Comradis, an AMICULUM agency), funded by Ultragenyx Pharmaceutical Inc., in partnership with Kyowa Kirin International plc.

## Additional Information

**Correspondence:** Kathryn Dahir, MD, 21st Avenue South, Medical Center East 8210, Nashville, TN, USA, 37232-8148. Email: [kathryn.dahir@vumc.org](mailto:kathryn.dahir@vumc.org).

**Disclosures:** K.D. has received research support from Ultragenyx Pharmaceutical and is a consultant for Ultragenyx Pharmaceutical. M.B.Z. has received research support from Ultragenyx Pharmaceutical paid to her institution, and has served on advisory boards for Ultragenyx Pharmaceutical. I.S. has been a speaker for Alexion and Radius, and has served on advisory boards for Ultragenyx Pharmaceutical. C.R. has served on advisory boards for Ultragenyx Pharmaceutical. J.Y.L. has served on advisory boards for Ultragenyx Pharmaceutical. R.D. has served as a scientific advisory board member/consultant for Ultragenyx Pharmaceutical and Radius Health. J.C. has served as an advisory board member for Ultragenyx Pharmaceutical and receives author royalties from Up To Date. R.C. has received research support from Mereo Biopharma and Amgen. M.S.R. and S.K. are employees of Ultragenyx Pharmaceutical. T.W. has received research funding from Ultragenyx Pharmaceutical and is a consultant to Ultragenyx Pharmaceutical, Pharmacosmos and Lakeside Life Science.

**Data Availability:** Data sharing is not applicable to this article as no datasets were generated or analyzed during the current study.

## References

1. Florenzano P, Hartley IR, Jimenez M, Roszko K, Gafni RI, Collins MT. Tumor-induced osteomalacia. *Calcif Tissue Int*. 2021;108(1):128-142.
2. Folpe AL. Phosphaturic mesenchymal tumors: a review and update. *Semin Diagn Pathol*. 2019;36(4):260-268.
3. Feng J, Jiang Y, Wang O, et al. The diagnostic dilemma of tumor induced osteomalacia: a retrospective analysis of 144 cases. *Endocr J*. 2017;64(7):675-683.
4. Jan de Beur SM. Tumor-induced osteomalacia. *JAMA*. 2005;294(10):1260-1267.
5. Chong WH, Molinolo AA, Chen CC, Collins MT. Tumor-induced osteomalacia. *Endocr Relat Cancer*. 2011;18(3):R53-77.

6. Schiavi SC. Fibroblast growth factor 23: the making of a hormone. *Kidney Int.* 2006;69(3):425-427.
7. Fukumoto S. Phosphate metabolism and vitamin D. *Bonekey Rep.* 2014;3:497.
8. Martin A, Quarles LD. Evidence for FGF23 involvement in a bone-kidney axis regulating bone mineralization and systemic phosphate and vitamin D homeostasis. *Adv Exp Med Biol.* 2012;728:65-83.
9. Drezner MK. Tumor-induced osteomalacia. *Rev Endocr Metab Disord.* 2001;2(2):175-186.
10. Minisola S, Peacock M, Fukumoto S, et al. Tumour-induced osteomalacia. *Nat Rev Dis Primers.* 2017;3:17044.
11. Weidner N, Santa Cruz D. Phosphaturic mesenchymal tumors. A polymorphous group causing osteomalacia or rickets. *Cancer.* 1987;59(8):1442-1454.
12. Shimada T, Mizutani S, Muto T, et al. Cloning and characterization of FGF23 as a causative factor of tumor-induced osteomalacia. *Proc Natl Acad Sci U S A.* 2001;98(11):6500-6505.
13. Gohil A, Imel EA. FGF23 and associated disorders of phosphate wasting. *Pediatr Endocrinol Rev.* 2019;17(1):17-34.
14. Lee JC, Su SY, Changou CA, et al. Characterization of FN1-FGFR1 and novel FN1-FGF1 fusion genes in a large series of phosphaturic mesenchymal tumors. *Mod Pathol.* 2016;29(11):1335-1346.
15. Yin Z, Du J, Yu F, Xia W. Tumor-induced osteomalacia. *Osteoporos Sarcopenia.* 2018;4(4):119-127.
16. Dadonienė J, Miglinas M, Miltiniene D, et al. Tumour-induced osteomalacia: a literature review and a case report. *World J Surg Oncol.* 2016;14(1):4.
17. Jerkovich F, Nuñez S, Mocarbel Y, et al. Burden of disease in patients with tumor-induced osteomalacia. *JBMR Plus.* 2021;5(2):e10436.
18. Colazo JM, DeCorte JA, Gillaspie EA, Folpe AL, Dahir KM. Hiding in plain sight: Gene panel and genetic markers reveal 26-year undiagnosed tumor-induced osteomalacia of the rib concurrently misdiagnosed as X-linked hypophosphatemia. *Bone Rep.* 2021;14:100744.
19. Batra P, Tejani Z, Mars M. X-linked hypophosphatemia: dental and histologic findings. *J Can Dent Assoc.* 2006;72(1):69-72.
20. Baroncelli GL, Angiolini M, Ninni E, Galli V, Saggese R, Giuca MR. Prevalence and pathogenesis of dental and periodontal lesions in children with X-linked hypophosphatemic rickets. *Eur J Paediatr Dent.* 2006;7(2):61-66.
21. Jiang Y, Hou G, Cheng W. Performance of 68Ga-DOTA-SST PET/CT, octreoscan SPECT/CT and 18F-FDG PET/CT in the detection of culprit tumors causing osteomalacia: a meta-analysis. *Nucl Med Commun.* 2020;41(4):370-376.
22. Stark H, Eisenstein B, Tieder M, Rachmel A, Alpert G. Direct measurement of TP/GFR: a simple and reliable parameter of renal phosphate handling. *Nephron.* 1986;44(2):125-128.
23. Alon U, Hellerstein S. Assessment and interpretation of the tubular threshold for phosphate in infants and children. *Pediatr Nephrol.* 1994;8(2):250-251.
24. Payne RB. Renal tubular reabsorption of phosphate (TmP/GFR): indications and interpretation. *Ann Clin Biochem.* 1998;35(Pt 2):201-206.
25. Bansal VK. Chapter 198: serum inorganic phosphorus. In: Walker HK, Hall WD, Hurst JW, eds. *Clinical Methods: The History, Physical, and Laboratory Examinations.* 3rd ed. Oxford, UK: Butterworths; 1990.
26. Imel EA, Peacock M, Gray AK, Padgett LR, Hui SL, Econs MJ. Iron modifies plasma FGF23 differently in autosomal dominant hypophosphatemic rickets and healthy humans. *J Clin Endocrinol Metab.* 2011;96(11):3541-3549.
27. Ito N, Wijenayaka AR, Prideaux M, et al. Regulation of FGF23 expression in IDG-SW3 osteocytes and human bone by pro-inflammatory stimuli. *Mol Cell Endocrinol.* 2015;399:208-218.
28. David V, Martin A, Isakova T, et al. Inflammation and functional iron deficiency regulate fibroblast growth factor 23 production. *Kidney Int.* 2016;89(1):135-146.
29. Endo I, Fukumoto S, Ozono K, et al. Clinical usefulness of measurement of fibroblast growth factor 23 (FGF23) in hypophosphatemic patients: proposal of diagnostic criteria using FGF23 measurement. *Bone.* 2008;42(6):1235-1239.
30. DeLacey S, Liu Z, Broyles A, et al. Hyperparathyroidism and parathyroidectomy in X-linked hypophosphatemia patients. *Bone.* 2019;127:386-392.
31. Huang QL, Feig DS, Blackstein ME. Development of tertiary hyperparathyroidism after phosphate supplementation in oncogenic osteomalacia. *J Endocrinol Invest.* 2000;23(4):263-267.
32. Tartaglia F, Minisola S, Sgueglia M, et al. Tumor-induced hypophosphatemic osteomalacia associated with tertiary hyperparathyroidism: a case report. *G Chir.* 2006;27(1-2):9-13.
33. Olefsky J, Kempson R, Jones H, Reaven G. "Tertiary" hyperparathyroidism and apparent "cure" of vitamin-D-resistant rickets after removal of an ossifying mesenchymal tumor of the pharynx. *N Engl J Med.* 1972;286(14):740-745.
34. Wyman AL, Paradinas FJ, Daly JR. Hypophosphatemic osteomalacia associated with a malignant tumour of the tibia: report of a case. *J Clin Pathol.* 1977;30(4):328-335.
35. Reid IR, Teitelbaum SL, Dusso A, Whyte MP. Hypercalcemic hyperparathyroidism complicating oncogenic osteomalacia. Effect of successful tumor resection on mineral homeostasis. *Am J Med.* 1987;83(2):350-354.
36. Tolomeo A, Lopopolo G, Dimicoli V, Perioli L, Modoni S, Scilimati A. Impact of 68Ga-DOTATOC PET/CT in comparison to 111In-Octreotide SPECT/CT in management of neuro-endocrine tumors: a case report. *Medicine (Baltimore).* 2020;99(7):e19162.
37. Li Y, Jiang L, Wang H, Cai H, Xiang Y, Li L. Effective radiation dose of 18F-Fdg PET/CT: How much does diagnostic CT contribute? *Radiat Prot Dosimetry.* 2019;187(2):183-190.
38. Lin EC. Radiation risk from medical imaging. *Mayo Clin Proc.* 2010;85(12):1142-1146.
39. Yang M, Doshi KB, Roarke MC, Nguyen BD. Molecular imaging in diagnosis of tumor-induced osteomalacia. *Curr Probl Diagn Radiol.* 2019;48(4):379-386.
40. Duet M, Kerkeni S, Sfar R, Bazille C, Liote F, Orcel P. Clinical impact of somatostatin receptor scintigraphy in the management of tumor-induced osteomalacia. *Clin Nucl Med.* 2008;33(11):752-756.
41. Chong WH, Andreopoulou P, Chen CC, et al. Tumor localization and biochemical response to cure in tumor-induced osteomalacia. *J Bone Miner Res.* 2013;28(6):1386-1398.

42. Kimizuka T, Ozaki Y, Sumi Y. Usefulness of 201Tl and 99mTc MIBI scintigraphy in a case of oncogenic osteomalacia. *Ann Nucl Med.* 2004;**18**(1):63-67.
43. Hodgson SF, Clarke BL, Tebben PJ, Mullan BP, Cooney WP 3rd, Shives TC. Oncogenic osteomalacia: localization of underlying peripheral mesenchymal tumors with use of Tc 99m sestamibi scintigraphy. *Endocr Pract.* 2006;**12**(1):35-42.
44. Fazel R, Krumholz HM, Wang Y, et al. Exposure to low-dose ionizing radiation from medical imaging procedures. *N Engl J Med.* 2009;**361**(9):849-857.
45. Piemonte S, Romagnoli E, Cipriani C, et al. Six-year follow-up of a characteristic osteolytic lesion in a patient with tumor-induced osteomalacia. *Eur J Endocrinol.* 2014;**170**(1):K1-4.
46. Colangelo L, Pepe J, Nieddu L, et al. Long-term bone mineral density changes after surgical cure of patients with tumor-induced osteomalacia. *Osteoporos Int.* 2020;**31**(7):1383-1387.
47. Andreopoulou P, Dumitrescu CE, Kelly MH, et al. Selective venous catheterization for the localization of phosphaturic mesenchymal tumors. *J Bone Miner Res.* 2011;**26**(6):1295-1302.
48. Tarasova VD, Trepp-Carrasco AG, Thompson R, et al. Successful treatment of tumor-induced osteomalacia due to an intracranial tumor by fractionated stereotactic radiotherapy. *J Clin Endocrinol Metab.* 2013;**98**(11):4267-4272.
49. Ito N, Shimizu Y, Suzuki H, et al. Clinical utility of systemic venous sampling of FGF23 for identifying tumours responsible for tumour-induced osteomalacia. *J Intern Med.* 2010;**268**(4):390-394.
50. Colangelo L, Cipriani C, Pepe J, et al. A challenging case of tumor-induced osteomalacia: pathophysiological and clinical implications. *Calcif Tissue Int.* 2018;**103**(4):465-468.
51. Li X, Jiang Y, Huo L, et al. Nonremission and recurrent tumor-induced osteomalacia: a retrospective study. *J Bone Miner Res.* 2020;**35**(3):469-477.
52. Mishra SK, Kuchay MS, Sen IB, Garg A, Baijal SS, Mithal A. Successful management of tumor-induced osteomalacia with radiofrequency ablation: a case series. *JBMR Plus.* 2019;**3**(7):e10178.
53. Hautmann AH, Schroeder J, Wild P, et al. Tumor-induced osteomalacia: increased level of FGF-23 in a patient with a phosphaturic mesenchymal tumor at the tibia expressing periostin. *Case Rep Endocrinol.* 2014;**2014**:729387.
54. Lamb YN. Burosumab: first global approval. *Drugs.* 2018;**78**(6):707-714.
55. US Food and Drug Administration. FDA approves first therapy for rare disease that causes low phosphate blood levels, bone softening [press release]. 18 June 2020. <https://www.fda.gov/news-events/press-announcements/fda-approves-first-therapy-rare-disease-causes-low-phosphate-blood-levels-bone-softening>. Accessed March 15, 2021.
56. Ultragenyx Pharmaceutical Inc. Crysvida US prescribing information 2020. [https://www.ultragenyx.com/file.cfm/29/docs/Crysvida\\_Full\\_Prescribing\\_Information.pdf](https://www.ultragenyx.com/file.cfm/29/docs/Crysvida_Full_Prescribing_Information.pdf). Accessed March 15, 2021.
57. Jan De Beur S, Miller P, Weber T, et al. OR13-1 Burosumab improves the biochemical, skeletal, and clinical symptoms of tumor-induced osteomalacia syndrome. *J Endocr Soc.* 2019;**3**(Suppl\_1):OR13-1.
58. Imanishi Y, Ito N, Rhee Y, et al. Interim analysis of a phase 2 open-label trial assessing burosumab efficacy and safety in patients with tumor-induced osteomalacia. *J Bone Miner Res.* 2021;**36**(2):262-270.
59. Peters KB, McLendon R, Morse MA, Vredenburg JJ. Treatment of recurrent intracranial hemangiopericytoma with SRC-related tyrosine kinase targeted therapy: a case report. *Case Rep Oncol.* 2010;**3**(1):93-97.
60. Case records of the Massachusetts General Hospital. Weekly clinicopathological exercises. Case 29-2001. A 14-year-old boy with abnormal bones and a sacral mass. *N Engl J Med.* 2001;**345**(12):903-908.
61. Seufert J, Ebert K, Muller J, et al. Octreotide therapy for tumor-induced osteomalacia. *N Engl J Med.* 2001;**345**(26):1883-1888.
62. Tella SH, Amalou H, Wood BJ, et al. Multimodality image-guided cryoablation for inoperable tumor-induced osteomalacia. *J Bone Miner Res.* 2017;**32**(11):2248-2256.
63. Geller JL, Khosravi A, Kelly MH, Riminucci M, Adams JS, Collins MT. Cinacalcet in the management of tumor-induced osteomalacia. *J Bone Miner Res.* 2007;**22**(6):931-937.
64. Hartley IR, Miller CB, Papadakis GZ, et al. Targeted FGFR blockade for the treatment of tumor-induced osteomalacia. *N Engl J Med.* 2020;**383**(14):1387-1389.