

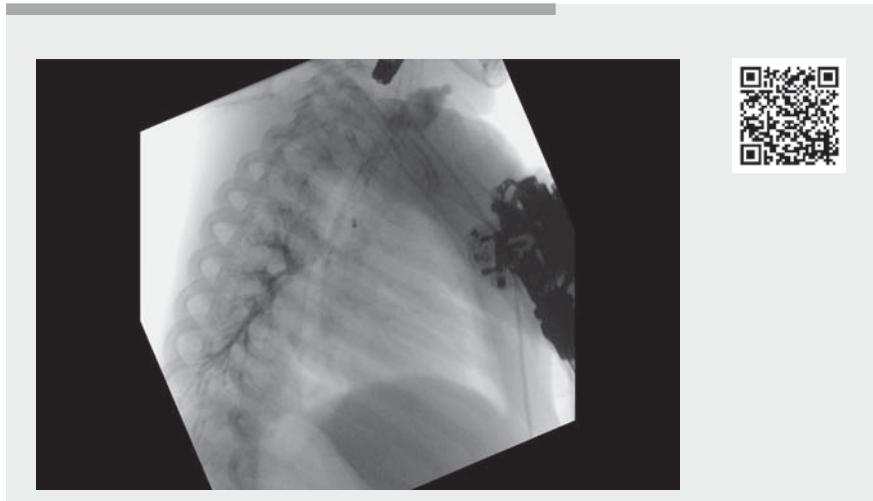
Biliary stent placement with modified Shim technique in a child with tracheoesophageal fistula and esophageal stricture

OPEN
ACCESS

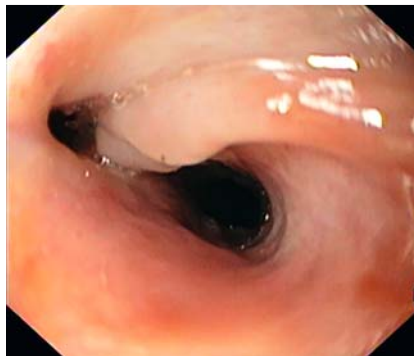
A 2-year-old boy was admitted as an emergency because of ingestion of a button battery. Upper endoscopy revealed a foreign body and circumferential mucosal necrosis at the proximal esophagus. The battery was removed using foreign-body forceps, and esophagography 1 week later showed no complications.

However, a further week later, the child returned with oral intolerance and respiratory distress. Endoscopy revealed a tracheoesophageal fistula (TEF), and he underwent surgery with tracheal and esophageal suturing with muscle flap interposition. There was no clinical improvement and esophagography confirmed persistence of the TEF. The child was referred to us for endoscopic closure (▶ **Video 1**).

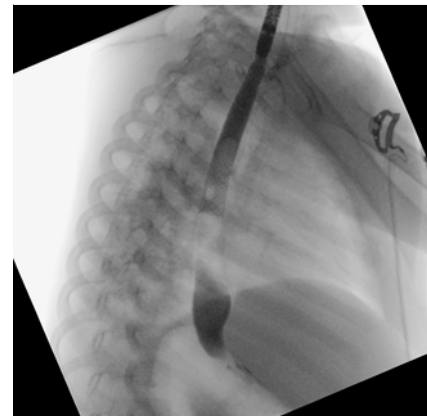
Upper endoscopy revealed a 4-mm esophageal stricture with associated TEF (▶ **Fig. 1**). A fully covered 10×60-mm biliary self-expandable metal stent was placed, traversing the stricture and covering the TEF orifice; contrast extravasation was not seen (▶ **Fig. 2**). A modified Shim technique [1] was applied to avoid stent migration: an endloop attached to a silk thread was attached to the proximal stent lasso (▶ **Fig. 3**), with the other end of the silk thread being taken round the patient's ear. Despite initial clinical improvement, a later increase of tracheal secretions as well as computed tomography scan confirmed TEF persistence. Upper endoscopy revealed no stent migration but incomplete apposition between the stent and mucosa (▶ **Fig. 4**). Foreign-body forceps were used to reposition the stent 2 cm proximally; fluoroscopy showed no contrast extravasation (▶ **Fig. 5**). Despite clinical improvement, the patient later underwent surgery again, with esophageal suturing, interposition graft with tibial periosteum tissue, and stent removal. The boy remains well 4 months later, without TEF recurrence and with stricture resolution.



▶ **Video 1** Placement of a biliary stent with a modified Shim technique in a child with tracheoesophageal fistula and esophageal stricture allowed sealing of the fistula and remodeling of the structure without stent migration.



▶ **Fig. 1** Endoscopic image of proximal esophagus with a 4-mm esophageal stricture and associated tracheoesophageal fistula (TEF) in a 2-year-old boy. He had previously undergone surgical repair of the TEF, which had been caused by ingestion of a button battery.

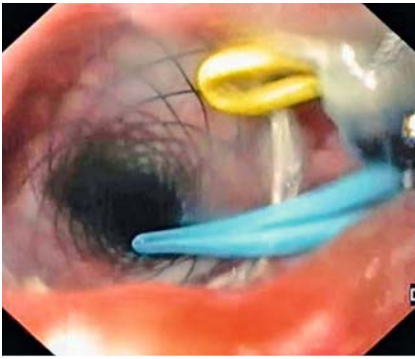


▶ **Fig. 2** Fluoroscopic image showing absence of contrast extravasation after biliary stent placement in the esophagus.

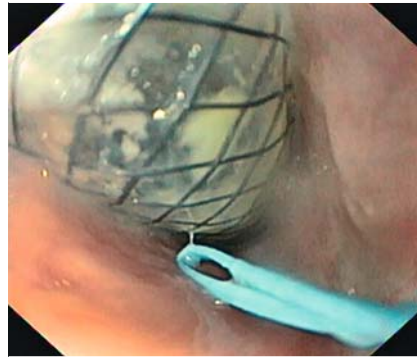
The small size of the pediatric esophagus and unavailability of dedicated pediatric stents makes esophageal stenting in small children challenging. Most of the literature reports describe treatment of strictures refractory to dilation [2]; however stent migration may occur in up to 29% of pediatric patients [3]. In this case,

we were able to seal a TEF and remodel an esophageal stricture using a modified Shim technique [1] that effectively prevented biliary stent migration.

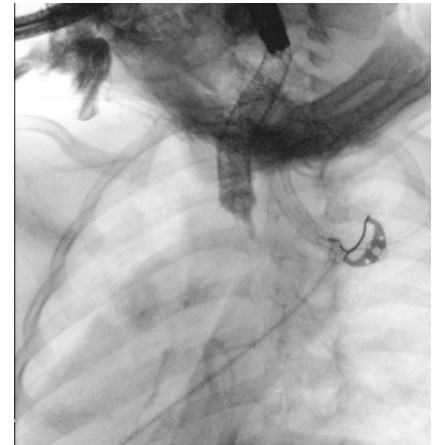
Endoscopy_UCTN_Code_TTT_1AO_2AI



► **Fig. 3** Endoscopic image showing correct biliary stent placement, with an endoloop attached to a silk thread at the proximal stent lasso.



► **Fig. 4** Endoscopic image showing incomplete apposition between the stent and mucosa, without stent migration.






► **Fig. 5** Fluoroscopy showed no contrast extravasation after repositioning of the stent.

Competing interests

The authors declare that they have no conflict of interest.

The authors

Joel Ferreira-Silva , **Eduardo Rodrigues-Pinto** , **Filipe Vilas-Boas** , **Guilherme Macedo**
Gastroenterology Department, Centro Hospitalar São João, Porto, Portugal

Corresponding author

Eduardo Rodrigues-Pinto, MD
Gastroenterology Department, Centro Hospitalar São João, Al. Prof. Hernâni Monteiro 4200, 319 Porto, Portugal
Fax: +351-22-5513601
edu.gil.pinto@gmail.com

References

- [1] Shim CS. Esophageal stent for cervical esophagus and esophagogastric junction. *Clin Endosc* 2012; 45: 235–239
- [2] Best C, Sudel B, Foker JE et al. Esophageal stenting in children: Indications, application, effectiveness, and complications. *Gastrointest Endosc* 2009; 70: 1248–1253
- [3] Kramer RE, Quiros JA. Esophageal stents for severe strictures in young children: Experience, benefits, and risk. *Curr Gastroenterol Rep* 2010; 12: 203–210

Bibliography

Endoscopy 2022; 54: E904–E905
DOI 10.1055/a-1860-2031
ISSN 0013-726X
published online 1.7.2022
© 2022. The Author(s).

This is an open access article published by Thieme under the terms of the Creative Commons Attribution-NonDerivative-NonCommercial License, permitting copying and reproduction so long as the original work is given appropriate credit. Contents may not be used for commercial purposes, or adapted, remixed, transformed or built upon. (<https://creativecommons.org/licenses/by-nc-nd/4.0/>)
Georg Thieme Verlag KG, Rüdigerstraße 14, 70469 Stuttgart, Germany



ENDOSCOPY E-VIDEOS

<https://eref.thieme.de/e-videos>



Endoscopy E-Videos is an open access online section, reporting on interesting cases and new techniques in gastroenterological endoscopy. All papers include a high quality video and all contributions are freely accessible online. Processing charges apply (currently EUR 375), discounts and waivers acc. to HINARI are available.

This section has its own submission website at <https://mc.manuscriptcentral.com/e-videos>