

IMMUNOPATHOLOGY OF LYMPHOCYTIC CHORIOMENINGITIS
VIRUS INFECTION OF NEWBORN MICE

ANTITHYMOCYTE SERUM EFFECTS ON GLOMERULONEPHRITIS AND
WASTING DISEASE

BY MARTIN S. HIRSCH, M.D., FREDERICK A. MURPHY, Ph.D.,
AND MARTIN D. HICKLIN, M.D.

*(From the United States Department of Health, Education, and Welfare,
Public Health Service, National Communicable Disease Center,
Atlanta, Georgia 30333)*

PLATES 86-89

(Received for publication 18 December 1967)

Lymphocytic choriomeningitis (LCM) virus infection in mice can take several clinical and histologic forms, depending on the immune status of the host (1). Mice with a mature and functioning cellular immune system respond to initial intracerebral inoculation of virus with a fatal choroiditis and meningitis. Animals that are immunologically depressed or immature, however, respond by developing a state of persistent viremia with vertical transmission of virus to offspring.

In a previous communication (2), rabbit anti-mouse thymocyte (RAMT) serum was shown to significantly modify the course of LCM virus infection in adult mice. Suppression of cellular responsiveness prevented clinical and histologic signs of infection, despite the presence of high titers of virus. Viremia in these animals gradually diminished and by 76 days after virus inoculation, no virus was detectable in either blood or brain.

In the present report RAMT serum, when administered during the 1st wk of life, is shown to permit the development of persistent carriage and vertical transmission of LCM virus. It does this by inducing a state of split-tolerance, involving depression of cellular, but not humoral responsiveness. One-fifth of the animals so treated developed a severe wasting disorder between 1 and 2 months of age, characterized histologically by reticular cell hyperplasia and infiltration. The remaining animals developed a type of glomerulonephritis by 3 months of age.

Materials and Methods

Newborn ICR mice of both sexes were used in all experiments. RAMT serum was prepared as described by Levey and Medawar (3), by immunizing rabbits with two intravenous inoculations of 10^9 dispersed viable ICR mouse thymus cells. Its effectiveness was assayed by its

ability (a) to diminish peripheral blood lymphocyte counts by 50% within 4 hr following a single intraperitoneal inoculation of 0.3 ml, and (b) to double the mean survival time of AKR skin grafts on C₃H mice following three daily intraperitoneal inoculations of 0.3 ml. All RAMT sera were shown to be free of anti-LCM activity by mouse neutralization and indirect immunofluorescent assays. The virus used was the Armstrong E-350 strain in a mouse brain suspension; it contained 10⁶ LD₅₀ per 0.03 ml when titrated by intracerebral inoculation of 1-wk-old ICR mice. No other pathogenic agent could be isolated from this material, despite repeated passages in newborn and adult mice, adult rabbits, and various cultured cells, including baby hamster kidney (BHK-21), African green monkey kidney (BSC-1), human embryonic lung (WI-38), primary mouse macrophage, and primary monkey kidney. Electron microscopic observation of specimens from these various infected animals and cultures also failed to reveal any other agent.

The design of the experiments performed is shown in Table I. All mice received three intraperitoneal inoculations (0.05 ml) of either RAMT serum or normal rabbit serum (NRS) at 3-day intervals, beginning on the day of birth. 1 day following the final inoculation i.e., day 7, groups A and B were injected intracerebrally with 1000 LD₅₀ of LCM virus. Animals were observed twice daily for signs of acute LCM infection; i.e., convulsions induced by

TABLE I
General Experimental Design for Comparison of Rabbit Anti-Mouse Thymocyte (RAMT) Serum and Normal Rabbit Serum (NRS) on LCM Virus Infection of Newborn Mice

Group	No. of mice	Treatment
A	65	0.05 ml RAMT serum on days 0, 3, 6; LCM virus on day 7
B	32	0.05 ml NRS on days 0, 3, 6; LCM virus on day 7
C	25	0.05 ml RAMT serum on days 0, 3, 6.

spinning, ruffled fur, hunched posture. Animals were sacrificed at intervals and individual blood and brain specimens tested for the presence of virus. Surviving animals were mated at 3 months and pregnant mice were individually isolated. Term fetuses and offspring at various ages (10–40 days) were tested for presence of virus in blood and brain.

Complement fixation tests on sera of surviving animals and their offspring were performed by Dr. Helen Casey of the National Communicable Disease Center, using the LBCF micro-technique (4), with a sucrose-acetone-extracted LCM antigen prepared according to the method of Gresikova and Casals (5).

Light microscopic histological examinations were performed on all sacrificed animals. Sections of heart, lungs, pancreas, liver, brain, kidney, spleen, lymph node, thymus, bone marrow, skeletal muscle, synovium, bone, and skin were routinely stained with hematoxylin and eosin, and when indicated with Mallory's phosphotungstic acid hematoxylin, crystal violet, periodic acid-Schiff, and Giemsa stains.

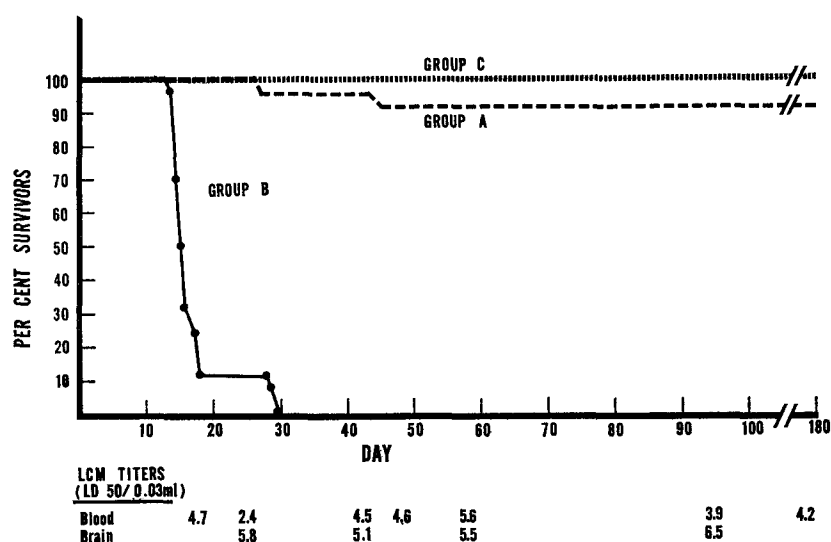
Immunofluorescent studies were performed on kidneys from all groups for detection of LCM virus (using a fluorescein isothiocyanate, FITC, conjugated hyperimmune mouse ascitic fluid), mouse gamma globulin (using FITC goat anti-mouse globulin), and rabbit globulin (using FITC goat anti-rabbit globulin).

RESULTS

Clinical Observations.—Survival curves for animals that were not sacrificed are illustrated in Text-fig. 1. Normal rabbit serum (NRS) had no effect on the

development of LCM virus infection, which was uniformly fatal in group B animals, usually by 12 days following virus inoculation. Animals of this group developed characteristic signs of choriomeningitis (convulsions, ruffled fur, death with hind legs extended). On the other hand, none of the animals pre-treated with RAMT serum developed signs of choriomeningitis (group A). The majority appeared healthy throughout the course of the experiment.

12 of the 65 animals in group A (18%) developed a wasting syndrome between 1 and 2 months of age. This was characterized by marked growth retardation, hunched posture, alopecia (initially over the dorsal cervical area, but



TEXT-FIG. 1. Survival curves of groups A, B, and C. Group A was treated with RAMT serum and LCM virus; group B, LCM virus alone; and group C, RAMT serum alone. Virus titers recorded for group A animals.

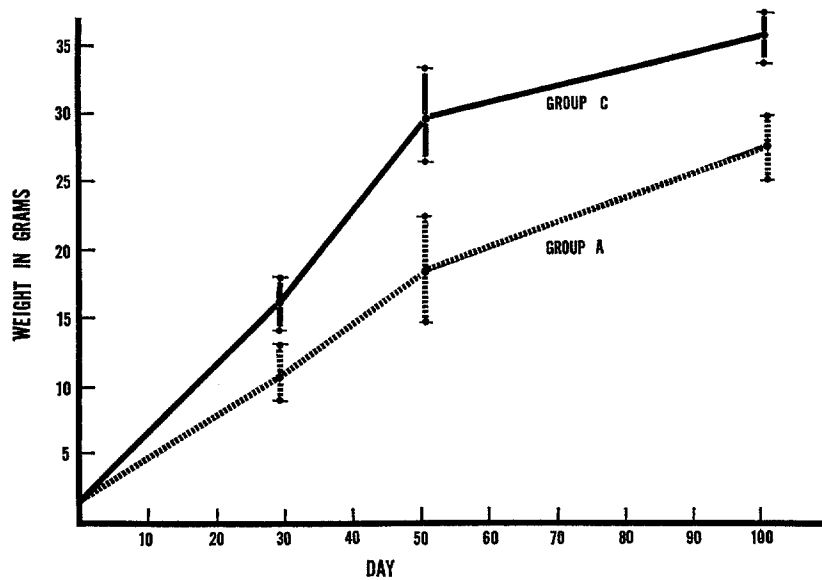
later generalized), and oily skin (Fig. 1). They developed a mincing gait and in later stages, joint stiffness and ataxia. Several wasted animals developed facial edema, particularly evident in periorbital tissues (Fig. 2). None of the control animals, treated with RAMT serum alone, developed any evidence of wasting.

Wasted group A animals did not exceed 20 g in body weight. However, even when these animals were excluded from consideration, group A mice still were significantly lighter in weight than the group C, uninfected animals (Text-fig. 2).

Virologic Observations.—In mice receiving both RAMT serum and virus (group A), viremia persisted for the duration of the experiment, whether the animals were wasted or not. Virus titers ranged between $10^{2.4}$ and $10^{5.6}$ LD₅₀ per

0.03 ml (all eight fetuses tested carried the virus). Living offspring, tested at various times after birth all also exhibited viremia, with titers averaging $10^{5.6}$ LD₅₀ per 0.03 ml.

Serologic Observations.—Despite persistent viremia in animals that received RAMT serum and virus (group A), complement-fixing antibody production against LCM virus was not prevented; titers in 15 individual sera tested from these animals ranged from 1:4 to 1:256. Offspring of these animals in no instance had complement-fixing antibodies in sera taken after weaning (six animals tested).



TEXT-FIG. 2. Weight curves of groups A and C. Wasted animals are excluded. Vertical bars represent standard deviations.

Histopathologic and Immunofluorescent Observations.—The only consistent lesions in all 23 nonwasted group A animals autopsied were in the kidneys. The earliest renal lesions consisted of a membranous glomerulonephritis (Fig. 3) with variable basement membrane thickening, endothelial cell proliferation, and often obliteration of subcapsular spaces secondary to proliferation of capsular epithelium and formation of synechia. Occasionally fibrinoid material was focally deposited in glomeruli, and in later stages the affected glomeruli appeared sclerotic. Perivascular infiltration was usually absent; when present it was composed of lymphocytes and larger mononuclear cells, and was of mild to moderate severity. No similar findings were present in any of the control group C animals, receiving RAMT serum without virus. Mice

treated with normal rabbit serum and LCM virus (group B) had characteristic choriomeningitis and no other significant histologic lesions.

Mouse gamma globulin was deposited in the glomerular tufts of nephritic group A animals, as demonstrated by immunofluorescence (Fig. 4). Similar depositions were not present in mice treated with only RAMT serum (group C). Similarly, LCM viral antigen could be found as punctate particles in cytoplasm of both glomerular and tubular cells in group A, but not group C animals. Rabbit globulin could not be demonstrated by immunofluorescent techniques in either group, despite three inoculations of rabbit serum during the 1st wk of life.

In the wasted group A animals, the most prominent findings were hyperplasia of reticular cells and apparent infiltration of these large mononuclear cells into tissues throughout the body. These infiltrations were composed almost entirely of uniform cells with abundant, homogeneous pale cytoplasm, and prominent irregular nuclei with frequent mitoses. Plasma cells were occasionally present, whereas other inflammatory cells and necrosis were absent. No signs of reticular cell hyperplasia were seen in animals receiving only RAMT serum (group C).

Lung: Accumulations of reticular cells were prominent in all wasted animals. They occurred surrounding medium-sized arteries and veins as well as in peribronchial and peribronchiolar connective tissue (Fig. 5). The infiltrates, both hilar and peripheral, were frequently nodular in appearance.

Heart: Cardiac muscle and valves were normal. Adventitial tissue was occasionally heavily infiltrated by the large reticuloendothelial cells.

Liver: Portal areas were involved by intense reticular cell activity, surrounding both arteries and veins. Along with the larger mononuclear cells, plasma cells were also present. No necrotic foci were present, and hepatic parenchymal cells were normal in appearance.

Pancreas: Extensive reticular cell infiltration occurred in periductal and perivascular areas (Fig. 6). Rarely, these infiltrations extended to the periphery of the pancreas. Fibrinoid material was occasionally seen in areas of heavy cellular infiltration. Acinar cells and island cells were normal in appearance. Peripancreatic fat and connective tissues were also heavily infiltrated by the large mononuclear cells.

Kidney: Some of the wasted animals had glomerular lesions comparable with those seen in the nonwasted group A animals, consisting of thickened basement membranes, hypercellular tufts, adhesions, and epithelial crescents. In addition, these mice had extensive reticular cell infiltrations along interlobar, arcuate, and intralobular arteries (Figs. 7 and 8). These infiltrations occasionally extended into the parenchyma, giving the appearance of a focal interstitial nephritis. At times they also appeared to invade glomeruli with destruction of the tufts. Perinephric fat tissue was also heavily invaded by these large mononuclear cells.

Brain: Only one animal had involvement of the brain. In this animal there was mild perivascular reticular cell cuffing, and mild choroiditis.

Skin: Marked reticular cell infiltration was observed in dermal and subcutaneous tissue, principally in perivascular and perifollicular areas. Many follicles were atrophic, and mast cells were markedly increased. Hyperkeratosis and parakeratosis were present.

Musculoskeletal system: Occasional mice had reticular cell infiltrations involving skeletal muscle, while synovium was uniformly uninvolved. Adipose tissue in periarticular areas was frequently heavily infiltrated with reticular cells and plasma cells. No lesions were found in bone.

Lymphoid organs: Lymph node architecture was nearly obscured by large reticular cells. No germinal centers, and practically no small lymphocytes were present. Changes in spleens varied from mild to marked reduction in small lymphocytes and replacement of these by large reticular cells. Thymus cortex size was decreased, while in medullary areas there was marked hyperplasia of large reticular cells. Occasionally these cells extended to the periphery of the gland. Perithymic connective tissue was heavily infiltrated by the large mononuclear cells. No morphologic alterations were observed in sections of femoral bone marrow.

DISCUSSION

Persistent Viral Carriage.—Neonatal tolerance to LCM virus is characterized by persistent undiminishing viremia, absence of specific detectable cellular or humoral responsiveness to the virus, and ability to transmit the virus carrier state vertically to offspring. The optimum age to establish tolerance by parenteral inoculation is within the first 24 hr of life (6, 7). By 4 days of age it is rarely possible to establish a truly tolerant state. As demonstrated in this study, however, cellular tolerance can be established at an older age, if antithymocyte serum is administered regularly, beginning on the day of birth. This tolerant state is characterized by undiminishing viremia and vertical transmission to offspring, but not by humoral unresponsiveness. Complement-fixing antibodies to an LCM virus antigen are produced, despite the continued presence of high titers of infectious virus. Neonatal thymectomy has also been shown to prevent cellular, but not humoral responsiveness to the virus (8). In addition, neonatally infected mice have recently been demonstrated to possess glomerular, but not circulating antibodies to LCM virus (9). The phenomenon of split tolerance, involving depression of cellular delayed hypersensitivity, but not of humoral antibody formation, has been described with various antigen-host combinations (10–12); the findings of the present study would appear to meet the criteria for this designation, although the specific tolerance-inducing antigens have not been characterized. Similarly, these results support the dissociation of the two types of immune response (13, 14), and emphasize the relative resistance of humoral responsiveness to the suppressive effects of antithymocyte serum.

Effects of Circulating Antibody and Antigen.—It would appear from studies, both with antithymocyte serum and neonatal thymectomy, that the presence of circulating complement-fixing antibody has little influence on the course of viremia in LCM virus infection. Results reported on the ineffectiveness of passively transferred immune serum on viremia in neonatally tolerant mice (15) support the view that the presence of circulating antibody is not sufficient to end a state of LCM tolerance. However, the long-term effects of the presence of both circulating virus and antibody are not known. Since animals treated with RAMT serum and LCM virus had both mouse gamma globulin and LCM virus in glomeruli by immunofluorescence, and also developed a type of glomerulonephritis, it appears that antigen-antibody complexes may be a factor in the pathogenesis of the renal lesions. Hotchin has described identical renal lesions in LCM-tolerant mice occurring between 1 and 2 yr of age (16). The glomerulonephritis was followed by diminution in urea and creatinine clearances (17), and in some cases by a "late disease," characterized by weight loss, alopecia, degenerative skin changes, and stiff joints (1). He hypothesized that the sequence of glomerulonephritis leading to late disease might be a manifestation of gradual loss of tolerance. The similarity of the renal lesions in this study, together with the findings of circulating antigen and antibody, suggests that in both cases the lesions may be secondary to immunopathologic mechanisms initiated by antigen-antibody complexes. That virus-antibody complexes can persist in the blood of apparently healthy mice for long periods of time has been well shown in the case of lactic dehydrogenase (LDH) virus (18). Evidence supporting the antigen-antibody complex hypothesis has recently been presented by Oldstone and Dixon (9), who demonstrated that gamma globulin anti-LCM antibody was, in fact, deposited in glomeruli. They proposed that the deposition of antigen-antibody complexes may be one of the causes of renal lesions found in these animals. It is intriguing to speculate that the more rapid onset of glomerulonephritis in RAMT serum-treated animals, compared with that in animals neonatally inoculated with virus, is attributable to the increased amount of circulating antibody present. This, in turn, would lead to more rapid deposition of antigen-antibody complexes and earlier nephritis. This hypothesis may also help explain the discrepancies reported between the findings of Hotchin and other investigators who have failed to reproduce the glomerulonephritis and late disease phenomenon (19, 20). It may be that the presence and amount of circulating and nephritogenic antibody is dependent on various factors, such as timing of inoculation, strain of virus, or strain of mouse used. On the other hand, the establishment of both cellular and humoral tolerance, e.g. by repeated vertical transmission of the virus, would eliminate the possibility of late antigen-antibody-induced disease and lead to an apparently nonpathogenic relationship between host and virus.

Wasting Disease.—Clinical wasting or runting syndromes following LCM virus infection have been shown to occur subsequent to neonatal inoculation

(1), following neonatal thymectomy and virus inoculation at weaning (21) and following a short course of antithymocyte serum (present report). Whether the histologic findings and pathogenesis of these syndromes are identical has not been adequately explored. However, all of these situations have in common a poorly functioning cellular immune system. The reticular cell hyperplasia and infiltrations in the present cases suggest that such an infiltration of organs and tissues may play a part in the pathogenesis of the disease. Other studies of wasting syndromes have also suggested a direct correlation between reticulo-endothelial functional hyperactivity and degree of wasting (22-24). There are at least three possible mechanisms by which LCM virus could induce reticulo-endothelial hyperactivity. Viral antigens, nearly ubiquitous in LCM-carrier mice (25), could themselves stimulate reticular cell hyperplasia and infiltration. Alternatively, the viruses could affect cellular activity so as to result in the release of new or altered cellular antigens which might initiate a reticular cell response on the part of the host. A third mechanism would be alteration of reticular cells so that they would react against their normal host. Immunologic deficiency, e.g. following antithymocyte serum administration or neonatal thymectomy, would potentiate the latter effect by preventing immune elimination of altered aggressor cells. An analogous mechanism in which altered immune cells initiate wasting has been suggested by Stanley and Walters (26) in the case of reovirus type 3.

SUMMARY

Antithymocyte serum, when administered neonatally to mice, delayed the maturation of the lymphoid system, permitting development of cellular tolerance to LCM virus at an older age than is ordinarily possible. Humoral antibody formation was not prevented and the animals exhibited the paradox of high titers of both circulating virus and antibody. This, in turn, was followed by a chronic immunopathologic glomerulonephritis in most animals. Some animals developed wasting disease between 1 and 2 months of age, characterized by reticular cell hyperplasia and widespread infiltration into tissues and organs.

BIBLIOGRAPHY

1. Hotchin, J. 1962. The biology of lymphocytic choriomeningitis infection: virus induced immune disease. *Cold Spring Harbor Symp. Quant. Biol.* **27**:479.
2. Hirsch, M. S., F. A. Murphy, H. P. Russe, and M. D. Hicklin. 1967. Effects of anti-thymocyte serum on lymphocytic choriomeningitis (LCM) virus infection in mice. *Proc. Soc. Exptl. Biol. Med.* **125**:980.
3. Levey, R. H., and P. B. Medawar. 1966. Nature and mode of action of anti-lymphocytic antiserum. *Proc Natl. Acad. Sci. U.S.A.* **56**:1130.
4. Standardized diagnostic complement fixation method and adaptation to microtest. *In* Public Health Monograph No. 74, PHS Publication No. 1228, U.S. Government Printing Office, Washington, D.C. 1965.

5. Gresikova, M., and J. Casals. 1963. A simple method of preparing a complement-fixing antigen for lymphocytic choriomeningitis virus. *Acta Virol. (Prague)* **7**:380.
6. Volkert, M., and J. Hannover Larsen. 1965. Studies on immunological tolerance to LCM virus. 5. The induction of tolerance to the virus. *Acta Pathol. Microbiol. Scand.* **63**:161.
7. Hotchin, J. E., and H. Weigand. 1961. Studies on lymphocytic choriomeningitis in mice. The relationship between age at inoculation and outcome of infection. *J. Immunol.* **86**:392.
8. Rowe, W., P. Black, and R. H. Levey. 1963. Protective effect of neonatal thymectomy on mouse LCM infection. *Proc. Soc. Exptl. Biol. Med.* **114**:248.
9. Oldstone, M. B. A., and F. J. Dixon. 1967. Lymphocytic choriomeningitis: production of antibody by "tolerant" mice. *Science.* **158**:1193.
10. Crowle, A. J., and C. C. Hu. 1966. Split tolerance affecting delayed hypersensitivity and induced in mice by pre-immunization with protein antigens in solution. *Clin. Exptl. Immunol.* **1**:323.
11. Borel, Y., M. Fauconnet, and P. S. Miescher. 1966. Selective suppression of delayed hypersensitivity by the induction of immunologic tolerance. *J. Exptl. Med.* **123**:585.
12. Dvorak, H. F., J. B. Billote, J. S. McCarthy, and M. H. Flax. 1965. Immunologic unresponsiveness in the adult guinea pig. 1. Suppression of delayed hypersensitivity and antibody formation to protein antigens. *J. Immunol.* **94**:966.
13. Leskowitz, S. 1967. Tolerance. *Ann. Rev. Microbiol.* **21**:157.
14. Miller, J. F. A. P., and D. Osoba. 1967. Current concepts of the immunological function of the thymus. *Physiol. Rev.* **47**:437.
15. Volkert, M., and J. Hannover Larsen. 1965. Immunological tolerance to viruses. *Progr. Med. Virol.* **7**:161.
16. Hotchin, J., and D. N. Collins. 1964. Glomerulonephritis and late onset disease of mice following neonatal virus infection. *Nature.* **203**:1357.
17. Baker, F. D., and J. Hotchin. 1967. Slow virus kidney disease of mice. *Science.* **158**:502.
18. Notkins, A. L., S. Mahar, C. Scheele, and J. Goffman. 1966. Infectious virus-antibody complex in the blood of chronically infected mice. *J. Exptl. Med.* **124**:81.
19. Traub, E. 1961. Can LCM virus cause lymphomatosis in mice? *Arch. Ges. Virusforsch.* **11**:667.
20. Volkert, M., J. Hannover Larsen, and C. J. Pfau. 1964. Studies on immunological tolerance to LCM virus. 4. The question of immunity in adoptively immunized virus carriers. *Acta Pathol. Microbiol. Scand.* **61**:268.
21. Szeri, I., Z. Banos, P. Anderlik, M. Balazs, and P. Foldes. 1966. Pathogenesis of the wasting syndrome following neonatal thymectomy. *Acta Microbiol. Acad. Sci. Hung.* **13**:255.
22. Schooley, J. C., L. S. Kelley, E. L. Dobson, C. R. Finney, V. W. Havens, and L. N. Cantor. 1965. Reticuloendothelial activity in neonatally thymectomized mice and irradiated mice thymectomized in adult life. *J. Reticuloendothelial Soc.* **2**:396.
23. Miller, J. F. A. P., and J. G. Howard. 1964. Some similarities between the neonatal

- thymectomy syndrome and graft-versus-host disease. *J. Reticuloendothelial Soc.* **1**:369.
24. de Vries, M. J., L. M. van Putten, H. Halner, and D. W. van Bekkum. 1964. Lesions suggerant une reactivite autoimmune chez des souris atteintes de la "runt disease" apres thymectomie neonatale. *Rev. Franc. Etudes Clin. Biol.* **9**:381.
25. Mims, C. A. 1966. Immunofluorescence study of the carrier state and mechanism of vertical transmission in lymphocytic choriomeningitis virus infection in mice. *J. Pathol. Bacteriol.* **91**:389.
26. Stanley, N. F., and N. I. M. Walters. 1966. Virus induction of autoimmune disease and neoplasia. *Lancet.* **1**:962.

EXPLANATION OF PLATES

PLATE 86

FIG. 1. 6-wk-old wasted mouse (group A), treated with RAMT serum and LCM virus. Mouse has marked weight loss, alopecia, oily skin, and stiff tail.

FIG. 2. 6-wk-old wasted mouse (group A). Periorbital edema, weight loss, and early dorsal alopecia.

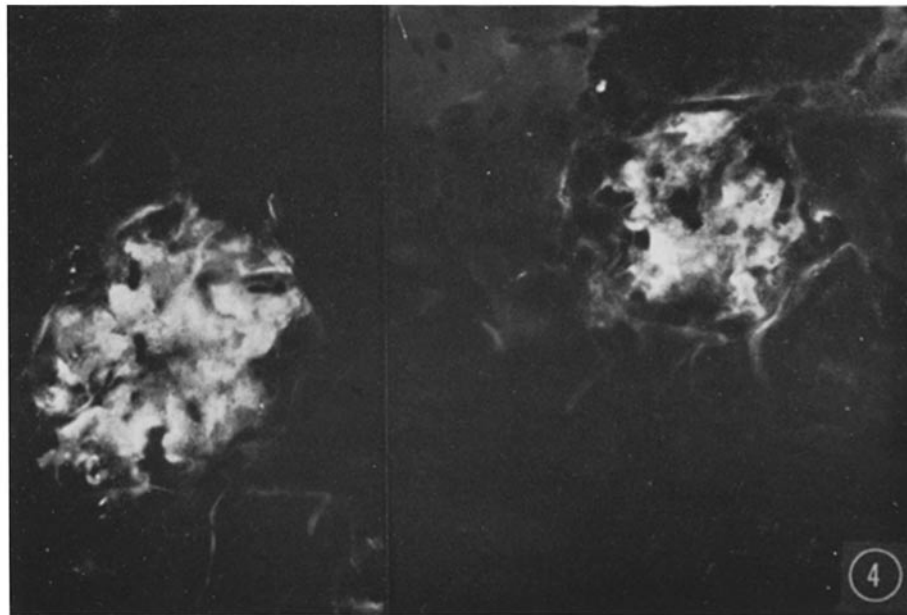
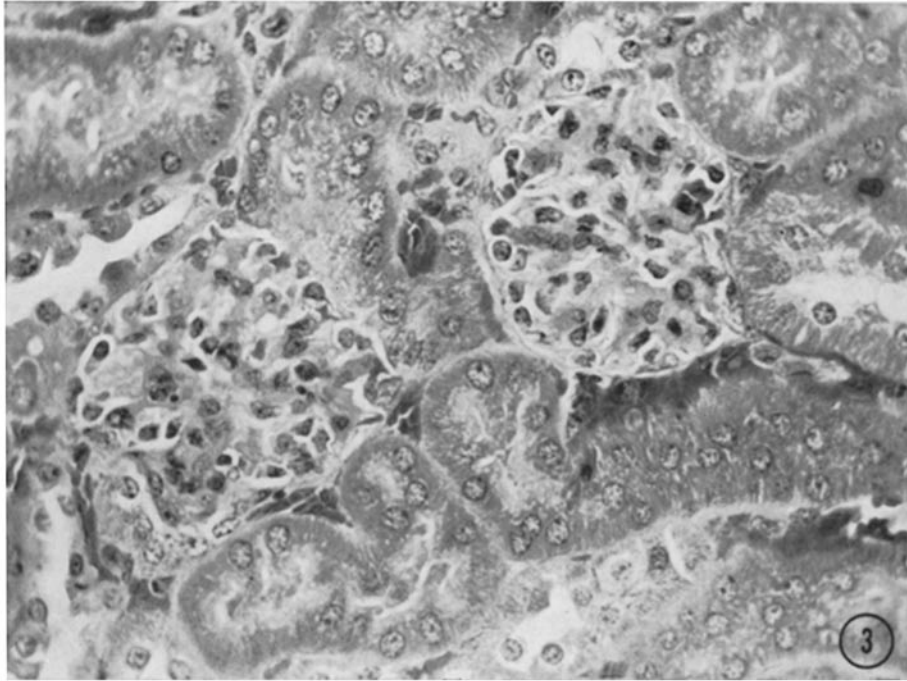


(Hirsch et al.: Lymphocytic choriomeningitis virus infection)

PLATE 87

FIG. 3. Kidney of nonwasted group A mouse. Glomerular hypercellularity, basement membrane thickening, and adhesions present. Hematoxylin and eosin. $\times 500$.

FIG. 4. Fluorescence micrograph of kidney from a group A mouse, showing deposition of mouse gamma globulin in glomerular tufts. Fluorescein isothiocyanate-conjugated goat anti-mouse globulin. $\times 500$.

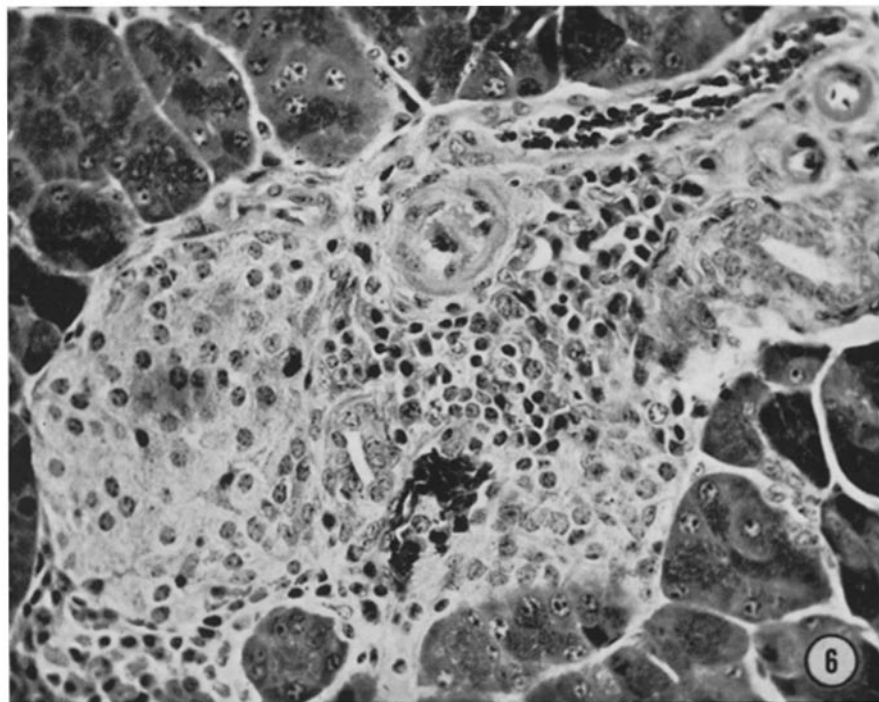
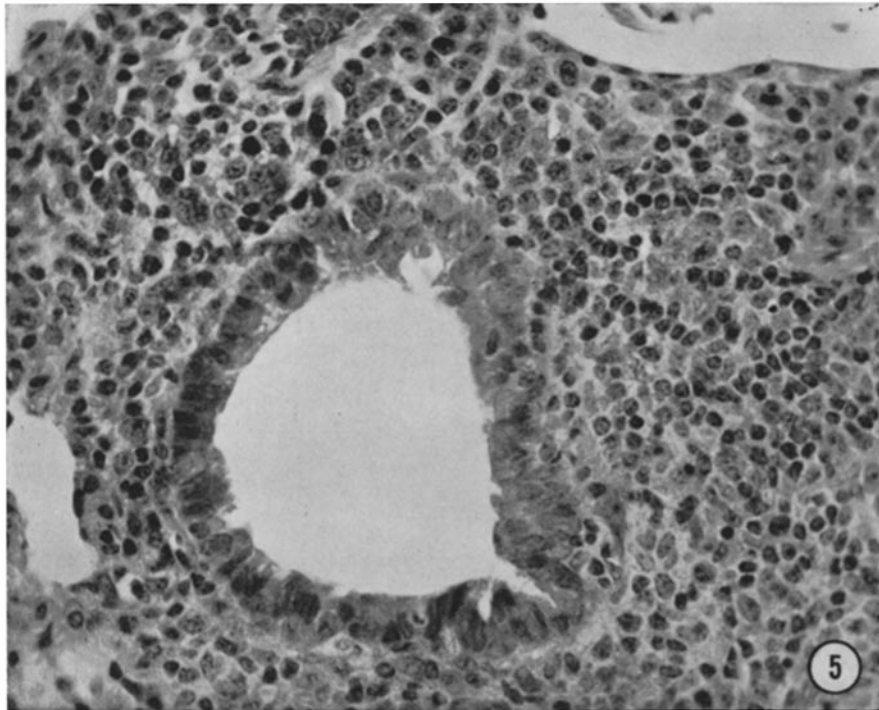


(Hirsch et al.: Lymphocytic choriomeningitis virus infection)

PLATE 88

FIG. 5. Lung from a wasted group A mouse. Peribronchiolar area infiltrated with large reticular cells. Hematoxylin and eosin. $\times 350$.

FIG. 6. Pancreas from a wasted group A mouse. Infiltrations of reticular cells surround vessels and ducts. Island on left and acinar tissue are not involved. Hematoxylin and eosin. $\times 350$.

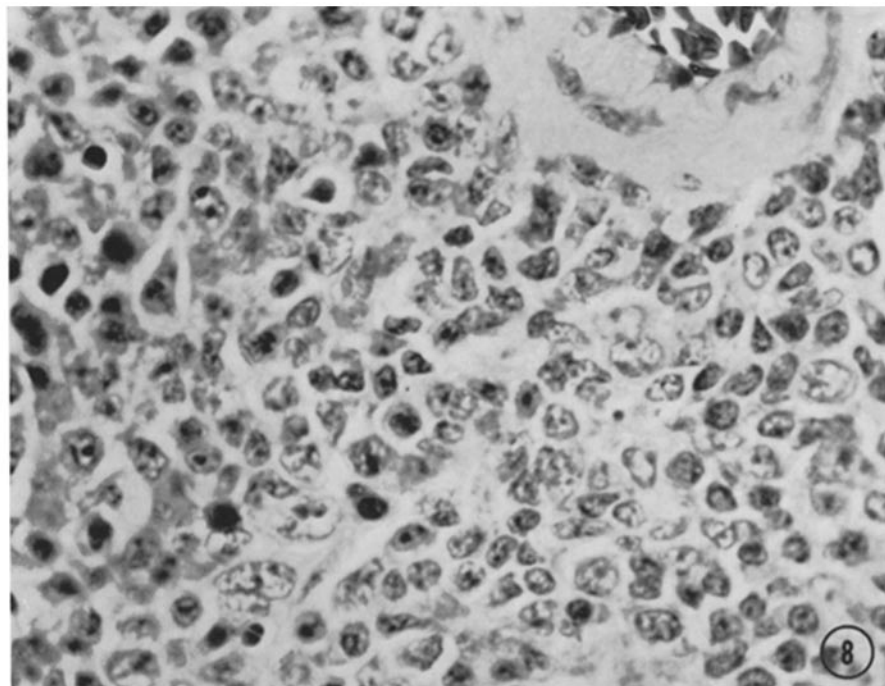
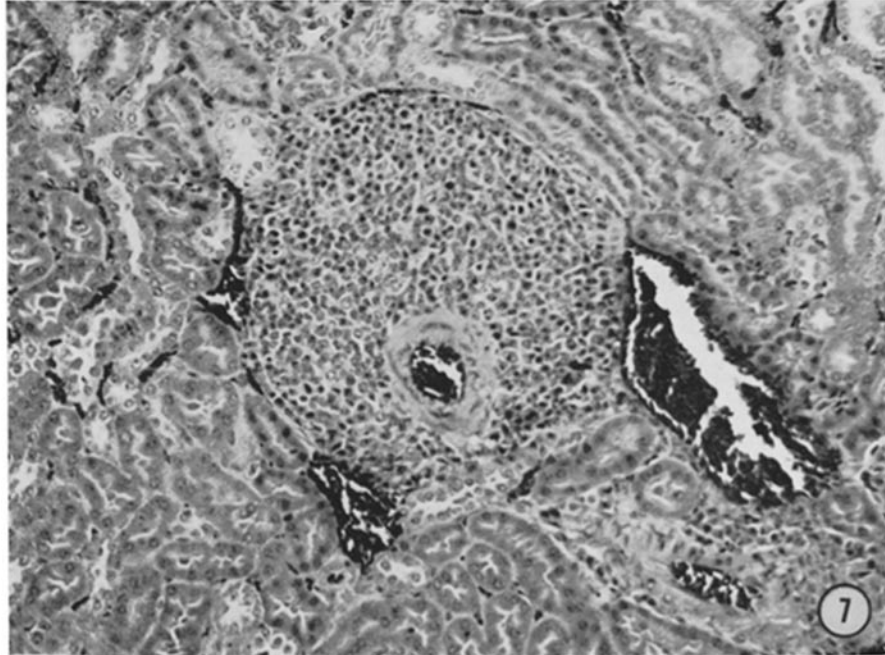


(Hirsch et al.: Lymphocytic choriomeningitis virus infection)

PLATE 89

FIG. 7. Kidney from a wasted group A mouse. Marked perivascular infiltration of reticular cells. Hematoxylin and eosin. $\times 200$.

FIG. 8. High power of same area of infiltration, showing large cells with abundant pale cytoplasm, large irregular nuclei, and occasional mitoses. Hematoxylin and eosin. $\times 800$.



(Hirsch et al.: Lymphocytic choriomeningitis virus infection)