



Pediatrics

Pedunculated and obstructive Wilms' tumor: A rare presentation in a 2 year-old male



Leor T. Arbel, Morris Jessop*, Osama Al-Omar

Department of Urology, West Virginia University School of Medicine, PO Box 9238, Morgantown, WV 26506, USA

ARTICLE INFO

Keywords:
Wilms' tumor
Pediatric urology
Nephrectomy
Cancer

ABSTRACT

Wilms' tumor manifesting as an obstructing ureteral mass is extremely rare. Herein, we report an unusual case in which a child presented with a clinical picture concerning for and suggestive of ureteropelvic junction obstruction (UPJO), but was instead found to have an intrapelvic pedunculated Wilms' tumor with extension into the proximal ureter. We discuss the patient's diagnostic workup, radiographic, operative and pathologic findings, as well as important lessons learned from this unusual case.

Introduction

Wilms' tumor is the most common renal malignancy in children under 15 years old and affects approximately 1 in 10,000 children worldwide. Most cases are diagnosed before 5 years old. Typically, Wilms' tumors occur sporadically, with a family history significant for the condition in just 1–2% of patients.¹ Although Wilms' tumor usually presents as an isolated disease, it occurs as part of a multiple malformation syndrome in approximately 10% of patients including but are not limited to WAGR, Denys-Drash, and overgrowth syndromes such as Beckwith-Wiedemann and Perlman syndromes. Additionally, congenital anomalies such as cryptorchidism, horseshoe kidney and hypospadias are observed in up to 13.4% of patients with Wilms' tumor. Chromosomes 11p13 (WT1 locus) and 11p15.5 (WT2 locus) are among the most commonly implicated loci in this pathogenic process.²

The most common presentation of Wilms' tumor is an asymptomatic abdominal mass discovered incidentally by a family member or physician. Less commonly, Wilms' tumor may present as hypertension or hematuria. Other symptoms such as fever, anorexia, and weight loss have been noted in approximately 10% of patients. On physical exam, a firm, nontender mass may be palpable that does not cross the midline.^{3,4} Atypical presentations of the condition are usually the result of compression or invasion of adjacent structures.

Herein, we report an unusual case in which a child presented with a clinical picture suggestive of ureteropelvic junction obstruction (UPJO), but was instead found to have an intrapelvic Wilms' tumor with extension into the proximal ureter.

Case report

A 2 year-old Caucasian male presented for evaluation of acute left sided abdominal pain and suspected UPJO. He was treated previously for recurrent abdominal pain secondary to constipation. A renal ultrasound and non-contrast CT were obtained, which demonstrated grade 4 left hydronephrosis, normal renal parenchyma and echogenic debris with suggested blood clots in the left collecting system (Fig. 1).

Upon admission, the patient was found to be afebrile and was vitally stable. On exam, no mass was palpable. Urinalysis demonstrated microscopic hematuria (10 RBC per high-power field) but was otherwise within normal limits. Routine labs including CBC and basic metabolic panel were obtained and found to be normal as well. Additional diagnostic studies including a voiding cystourethrogram (VCUG) and a mercaptoacetyltriglycine (MAG3) renal scan were ordered. The VCUG was unremarkable; the renogram, however, demonstrated an obstructive pattern in the left kidney. The patient then underwent cystoscopy with left retrograde ureteropyelography, which was remarkable for a filling defect with near complete obstruction at the level of the UPJ and proximal ureter. Ureteroscopy and stent placement were not successful as we were unable to place a guide wire past the obstruction. Consequently, a CT scan with contrast was obtained. The images were concerning for severe hydronephrosis with parenchymal thinning and a renal pelvis tissue mass extending into the proximal ureter with no obvious renal parenchymal involvement (Fig. 2). To help with further diagnosis of the mass, an interventional radiology guided biopsy was attempted. Unfortunately, the biopsy was non-diagnostic.

As a result of our findings, an open left radical nephrectomy, proximal ureterectomy and lymph node dissection was performed.

* Corresponding author.

E-mail addresses: arbel@knights.ucf.edu (L.T. Arbel), mjessop@gmail.com (M. Jessop), osalomar@hsc.wvu.edu (O. Al-Omar).

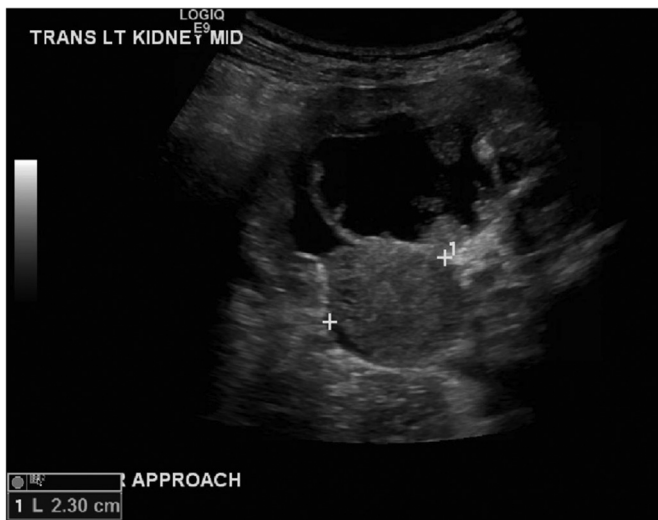

Fig. 1. Renal US demonstrating a 2.3 cm hemorrhagic debris-filled focus within the left UPJ and proximal ureter, obstructing the renal pelvis.

Intraoperatively, an abnormal left renal pelvis containing a large mass that was originating from the mid-pole of the kidney and extending into the ureter was observed (Fig. 3). Gross pathology demonstrated a 7.2 × 6.0 × 5.0 cm, pedunculated smooth pink and yellowish tumor which microscopically demonstrated the classic triphasic pattern of Wilms' tumor with favorable histology (Fig. 4). The margins were uninvolved and lymph nodes were negative. The stage was upgraded to stage III due to the patient's pre-operative biopsy. He was subsequently treated with chemoradiation and is reportedly doing well.

Discussion

Wilms' tumor classically originates from the renal parenchyma and spreads by expansion into surrounding tissue. However as in our case, it may appear as an obstructive pedunculated mass with no obvious parenchymal involvement that occupying the renal pelvis and extending into the proximal part of the ureter. A recent literature review only identified 7 known cases of Wilms' tumors with a similar pattern of extension. However, the tumors in those cases differed in their imaging and gross appearance from that of our patient's. Rather than a pedunculated smooth yellowish and pink mass with no renal parenchymal

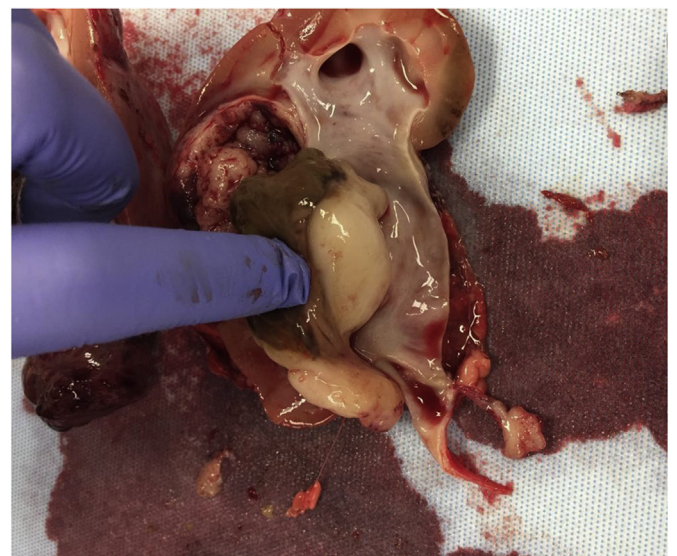


Fig. 3. Specimen from left nephrectomy. The mass has a friable pink peripheral rim with both solid and cystic components. (For interpretation of the references to colour in this figure legend, the reader is referred to the Web version of this article.)

involvement, these tumors were characterized by large inhomogeneous masses that extend from the renal parenchyma to the renal pelvis and the entire ureter with numerous round protuberances and were thus classified as Botryoid Wilms' tumors.⁵

We identified two important lessons to learn from this case; first, preoperative recognition of atypical presentation of Wilms' tumor as a pedunculated obstructive mass without obvious renal parenchymal involvement on imaging, like in our case, would eliminate preoperative percutaneous biopsy which has serious implication on final Wilms' tumor stage. Because of the preoperative biopsy, our patient was upgraded to stage 3 rather than stage 1. Second, the preoperative recognition of the ureteral extension of tumor was important to achieve adequate surgical resection.

Conclusion

In conclusion, clinicians should be aware that Wilms' tumor may present as an obstructive renal pelvic lesion with extension into the

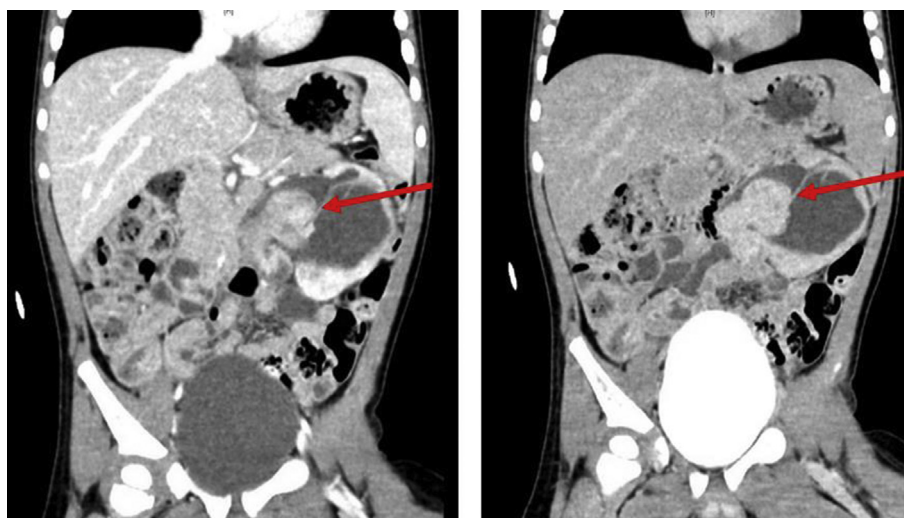


Fig. 2. CT with contrast arterial phase (left) and delayed phase (right) demonstrated an enhancing, rounded mass at the level of the left UPJ with extension into the proximal ureter along with several other smaller enhancing mass-like lesions within the lower pole collecting system.

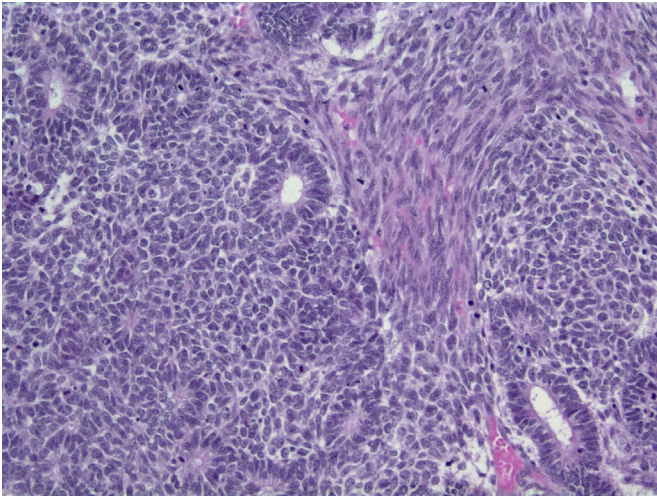


Fig. 4. Microscopic image at 200 \times . Triphasic pattern with blastemal, epithelial and stromal components.

ureter, and may have no parenchymal involvement on preoperative imaging. Preoperative recognition will eliminate the need for needle

biopsy and potential upgrading of the tumor stage and will assist in planning for adequate resection of the mass.

Funding

This research did not receive any specific grant from funding agencies in the public, commercial, or not-for-profit sectors.

Appendix A. Supplementary data

Supplementary data related to this article can be found at <http://dx.doi.org/10.1016/j.eucr.2018.06.004>.

References

1. Breslow N, Olshan A, Beckwith JB, Green DM. Epidemiology of Wilms tumor. *Med Pediatr Oncol.* 1993;21(3):172–181.
2. Coppes MJ, Haber DA, Grundy PE. Genetic events in the development of Wilms' tumor. *N Engl J Med.* 1994;331(9):586–590.
3. Ritchey ML, Shamberger RC. Pediatric Urologic Oncology: Renal and Adrenal. *Campbell-Walsh Urology*, 11e: Elsevier, Inc: p3559–3581.
4. Konety BR, Vaena DA, Williams RD. Chapter 22. Renal parenchymal neoplasms. In: McAninch JW, Lue TF, eds. *Smith & Tanagho's General Urology*, 18e. New York, NY: The McGraw-Hill Companies; 2013.
5. Xu G, Hu J, Wu Y, Xiao Y, Xu M. Botryoid Wilms' tumor: a case report and review of the literature. *World J Surg Oncol.* 2013;11(102):102.