

CASE REPORT

A Case of Acrodermatitis Continua of Hallopeau Following Chronic Pustular Cheilitis

Mariachiara Arisi · Maria Teresa Rossi · Raffaella Sala ·
Giulia Petrilli · Daniela Marocolo · Marco Ungari · Fabio Facchetti ·
Pier Giacomo Calzavara-Pinton

To view enhanced content go to www.dermtherapy-open.com
Received: November 26, 2015 / Published online: February 26, 2016
© The Author(s) 2016. This article is published with open access at Springerlink.com

ABSTRACT

We describe the case of a young male affected by chronic pustular psoriasis of the lips that remained the only manifestation of acrodermatitis continua of Hallopeau (ACH) for years before the onset of the characteristic hand lesions.

Keywords: Acrodermatitis continua; Cheilitis; Hallopeau; Psoriasis

INTRODUCTION

Acrodermatitis continua of Hallopeau (ACH), also known as dermatitis repens or pustular

acrodermatitis, is an uncommon clinical variant of pustular psoriasis.

Clinical presentation is quite monotonous with chronic recurrent pustulation of the nail fold, nail bed and tip of one or more fingers or toes.

With time, it spreads proximally with destruction of the nail matrix, and sometimes it causes osteolysis and bone reabsorption. Other modalities of clinical presentation have not been reported so far [1].

We describe the case of a 25-year-old male affected by chronic pustular psoriasis of the lips that remained the only manifestation of ACH for years before the onset of the characteristic clinical hand lesions.

CASE REPORT

A 25-year-old male presented with a 2-year history of erythematous and desquamative cheilitis with pustules. The lesions were not responsive to several treatment cycles with corticosteroids and emollients.

Clinical examination showed that the upper lip was erythematous, fissured and covered by thick white-yellowish scales with small noncoalescing pustules. Skin examination was

M. Arisi (✉) · M. T. Rossi · R. Sala ·
P. G. Calzavara-Pinton
Department of Dermatology, Spedali Civili di
Brescia, University of Brescia, Brescia, Italy
e-mail: mariachiara.arisi@gmail.com

G. Petrilli · D. Marocolo · F. Facchetti
Department of Pathology, Spedali Civili di Brescia,
University of Brescia, Brescia, Italy

M. Ungari
Department of Pathology, Ospedale di Cremona,
Cremona, Italy

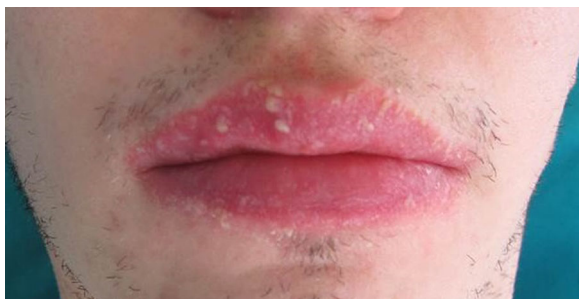

Fig. 1 Erythema, edema and scaling with small pustular lesions of the lips

otherwise normal, and the oral mucosa, tongue and nails did not present any lesions (Fig. 1).

The patient was otherwise in good health. He reported no personal or family history of psoriasis or any other dermatological conditions and no history of smoking. He denied any history of lip licking or contact with lipstick, topical antibiotics and steroids, or other cosmetics.

Findings of routine hematology and biochemistry tests, total IgE serum level and IgE microarray ImmunoCap assay were within normal ranges. Bacteriological investigations of the pustules were negative as well.

Patch testing with the standard series and series of dental materials recommended by the Italian Society of Occupational and Environmental Allergological Dermatology (SIDAPA) did not show contact allergic sensitization [2].

A biopsy sample of the upper lip was obtained for histopathologic evaluation; the analysis showed a stratified squamous epithelium with confluent parakeratosis and focal loss of the granular cell layer. Acanthosis and irregular elongation of the rete ridges were also noted, with ectatic vessels and a lymphocytic inflammatory cell infiltrate. There were collections of neutrophils, with the aspect of both Munro microabscesses (accumulation of polymorphs within the parakeratotic stratum

corneum) and spongiform pustules of Kogoj (small accumulation of neutrophils and occasional lymphocytes beneath the keratin layer). No fungi or spirochetes were found with specific stainings (Fig. 2a–c).

A diagnosis of psoriasiform cheilitis was made.

The lip lesions were treated with calcipotriol ointment twice daily for a month without any improvement. Topical tacrolimus 0.1% ointment twice daily for a month was ineffective as well.

At the 4-month follow-up erythematous and desquamative plaques with pustules developed on the thenar eminence of the right hand and fifth fingertip of the left hand (Fig. 3a, b). A skin biopsy of the palm showed regular acanthosis of the epidermis, with elongation of the rete ridges, which tended to fuse with each other. The overlying hyperkeratosis, ortho- and para-, was filled with small aggregates of neutrophils, observed even in the subcorneal location. Some suprapapillary plates were thin, and the dermal papillae were expanded by tortuous vessels; there was an inflammatory infiltrate composed of small lymphocytes, with mild exocytosis and perivascular disposition (Fig. 4a, b).

The histological findings were consistent with psoriasis.

Oral cyclosporine (200 mg/day) for 6 months led to a complete remission of the lesions of the lip and hands. However, 2 months after interruption a relapse was seen. Low-dose oral acitretin (25 mg/day) was administered, which quickly cleared the pustular lesions of the lips and hands, although a mild xerotic cheilitis developed.

Compliance with Ethics Guidelines

Informed consent was obtained from the patient for inclusion in the study.

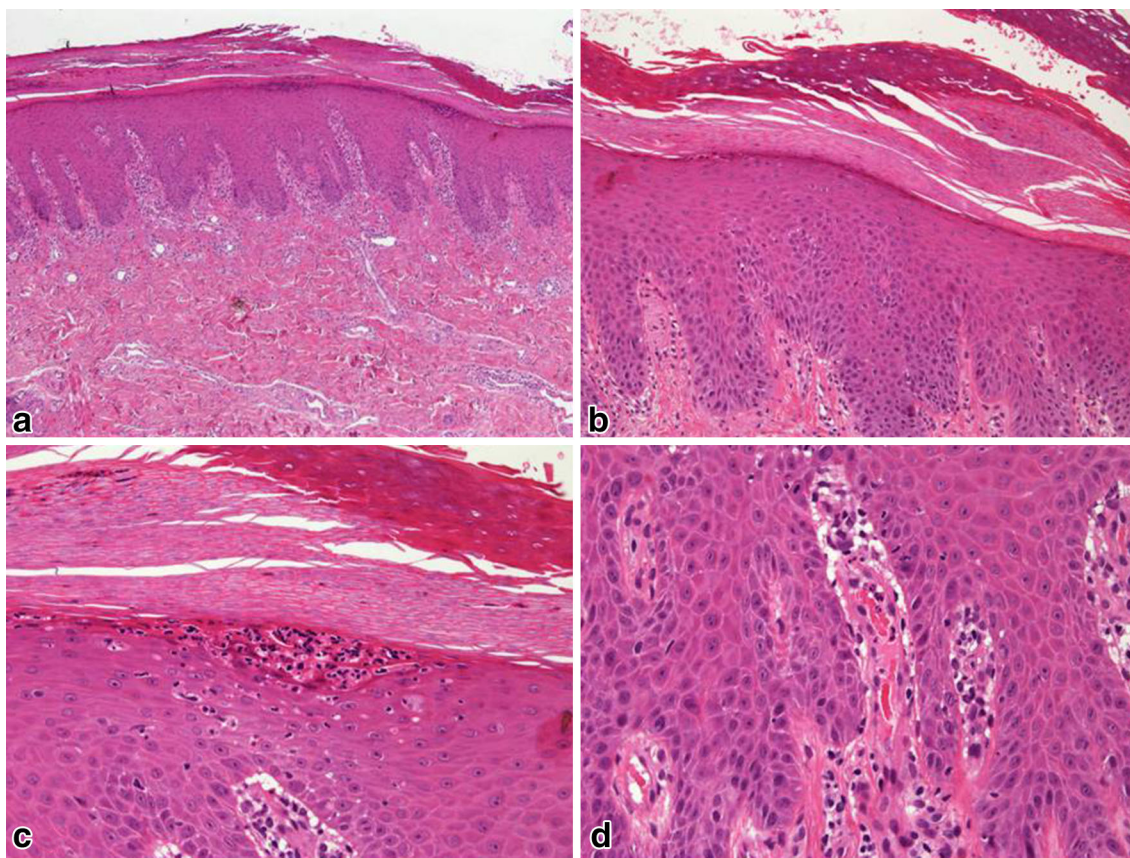


Fig. 2 **a** Histological image of the skin biopsy of the upper lip ($\times 4$). **b** Parakeratosis and focal loss of the granular cell layer ($\times 10$). **c** Spongiform pustules of Kogoj ($\times 20$). **d** Ectatic vessels and neutrophilic infiltrate ($\times 20$)

DISCUSSION

We have reported for the first time to our knowledge a case of pustular acrodermatitis of Hallopeau following chronic pustular cheilitis [3].

Labial psoriatic lesions as the first manifestation of plaque type psoriasis have been described in only seven patients so far [4]. In these cases, chronic erythema, crackling and scaling of the lips without pustulation developed months to years before lesions in other body areas appeared. Among these patients, exclusive lip involvement was reported in five cases with no lesions appearing in other body sites [4, 5]. To the best of our knowledge, only one case of acrodermatitis continua of Hallopeau preceded

by papular and pustular psoriatic lesions of the lower half of the face has been reported [6]. This clinical course supports ACH as an acral variant of pustular psoriasis.

Plaque type psoriasis of the lips has been described in association with psoriasis of the tongue, presenting whitish or grayish roundish polycyclic or annular plaques with an erythematous halo of the tongue, palate and gingiva and a fissured or geographic tongue [7, 8]. The clinical differential diagnosis must consider irritative cheilitis, chronic eczema, leucoplakia, actinic cheilitis and chronic candidiasis [9]. In our case, these conditions were not supported by histology.

Recent findings on the biology of psoriasis can explain the rarity of oral and labial

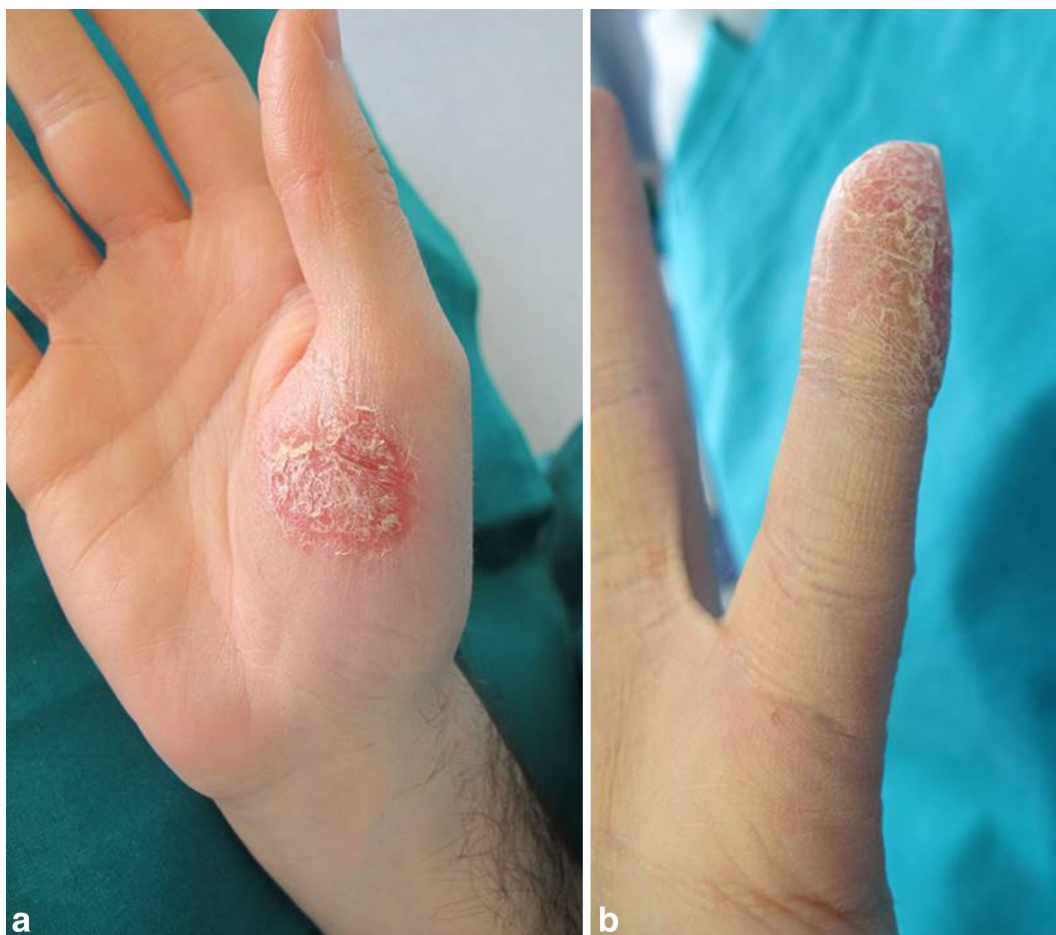

Fig. 3 Erythematous and desquamative plaques with pustules developed on the thenar eminence of the right hand (a) and fifth fingertip of the left hand (b)

localizations. Indeed, unlike keratinized stratified squamous epithelium of the skin, the transitional and mucosal epithelia do not contain corneodesmosin, an epidermal glycoprotein involved in keratinocyte adhesion, an allelic variant of which has been strongly associated with the development of psoriasis [8, 10]. It is well known that traumas, stress and streptococcal infection can precipitate psoriasis; therefore mild traumas, e.g., chronic friction from protruding teeth, or environmental changes in infection can lead to psoriatic lesions on the lips, especially in a genetically predisposed subject [9, 11].

Isolated labial localization of plaque-type psoriasis was reported successfully treated with topical treatment with fluticasone propionate cream [12], tacrolimus ointment [4] and triamcinolone acetonide ointment [9]; however, the pustular lesions of the present patient were resistant to topical therapies but responsive to both oral cyclosporine and acitretin.

Our case shows an unusual clinical manifestation of pustular acrodermatitis of Hallopeau and indicates that psoriasis of the lips can be the sole presentation of psoriasis, preceding the appearance of more typical lesions by years.

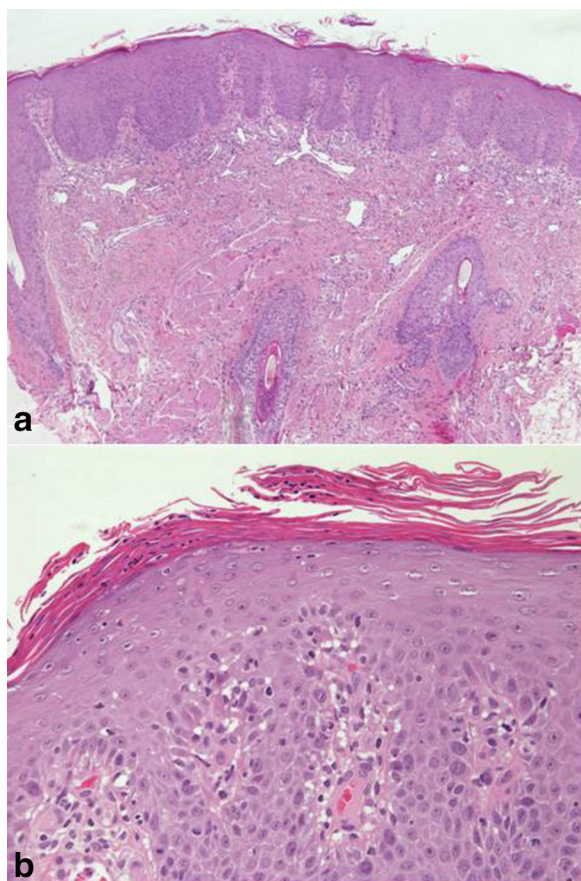


Fig. 4 **a** Skin biopsy of the left palm ($\times 4$). **b** Parakeratosis and small neutrophil aggregates ($\times 20$)

Therefore, in chronic or recurrent eczema-like labial lesions, resistant to topical therapies, psoriasis should be suspected as the differential diagnosis.

ACKNOWLEDGMENTS

No funding or sponsorship was received for this study or publication of this article. All named authors meet the International Committee of Medical Journal Editors (ICMJE) criteria for authorship for this manuscript, take responsibility for the integrity of the work as a whole and have given final approval for the version to be published. The corresponding

author would like to thank nurse A. Bertolotti for her professionalism and collaboration in patient management and in everyday clinical practice.

Disclosures. Mariachiara Arisi, Maria Teresa Rossi, Raffaella Sala, Giulia Petrilli, Daniela Marocolo, Marco Ungari, Fabio Facchetti and PierGiacomo Calzavara-Pinton have nothing to disclose.

Compliance with Ethics Guidelines. Informed consent was obtained from the patient for inclusion in the study.

Open Access. This article is distributed under the terms of the Creative Commons Attribution-NonCommercial 4.0 International License (<http://creativecommons.org/licenses/by-nc/4.0/>), which permits any noncommercial use, distribution, and reproduction in any medium, provided you give appropriate credit to the original author(s) and the source, provide a link to the Creative Commons license, and indicate if changes were made.

REFERENCES

1. Wolff K, Allen Jhonson R, Suurmond D. Fitzpatrick's color atlas and synopsis of clinical dermatology: Fifth ed. McGraw-Hill ed. 2001. p. 66.
2. Schena D, Fantuzzi F, Girolomoni G. Contact allergy in chronic eczematous lip dermatitis. *Eur J Dermatol.* 2008;18:688–92.
3. Martì N, Pinazo I, Revert A, Jordà E. Psoriasis of the lips. *J Dermatol Case Rep.* 2009;3:50–2.
4. Apalla Z, Sotiriou E, Trigoni A, Ioannides D. Psoriatic Cheilitis: a report of 2 cases treated successfully with topical tacrolimus and a review of the literature. *Acta Derm Sifil.* 2015;106:687–8.
5. Robinson CM, DiBiase AT, Leigh IM, Williams DM, Thornhill MH. Oral psoriasis. *Br J Dermatol.* 1996;134:347–9.

-
6. Iijima S, Okazaki Y, Watanabe S, Maruyama Y. Case of acrodermatitis continua of Hallopeau following psoriasis with atypical clinical presentation. *J Dermatol*. 2014;41:1006–8.
 7. Prignano F, D'Erme AM, Bonciolini V, Lotti T. Mucosal psoriasis: a new insight toward a systemic inflammatory disease. *Int J Dermatol*. 2011;50:1579–81.
 8. Yesudian PD, Chalmers RJG, Warren RB, Griffiths CEM. In search of oral psoriasis. *Arch Dermatol Res*. 2012;304:1–5.
 9. Rahman MA, Fikree M. Perioral psoriasis. *J Eur Acad Dermatol Venereol*. 2000;14:513–22.
 10. Allen M, Ishida-Yamamoto A, McGrath J, Davison S, Iizuka H, Simon M, et al. Corneodesmosin expression in psoriasis vulgaris differs from normal skin and other inflammatory skin disorders. *Lab Invest*. 2001;81:969–76.
 11. Brenner S, Lipitz R, Illie B, Krakowski A. Psoriasis of the lips: the unusual Köebner phenomenon caused by protruding upper teeth. *Dermatologica*. 1982;164:413–6.
 12. Ersoy-Evans S, Nuralina L, Erkin G, Ozkaya O. Psoriasis of the lips: a rare entity. *J Eur Acad Dermatol Venereol*. 2007;21:142–3.