

Original Article

The Use of Balloon-assisted Enteroscopy at a Large Volume Centre: A Retrospective Analysis

Amine Benmassaoud MD¹, Mark Solomon Sasson¹, Jean Caroll Pamphile MD¹,
Myriam Martel MS¹, Peter L. Lakatos MD^{1,2}, Alan N. Barkun MD¹,
Constantine Soulellis MD¹, Talat Bessissow MD¹

¹Division of Gastroenterology, McGill University Health Center, 1650 Cedar Avenue, Montreal, Canada H3G 1A4;

²First Department of Medicine, Semmelweis University, Korányi S. 2/A, H-1083 Budapest, Hungary

Correspondence: Talat Bessissow, MD, Division of Gastroenterology, Montreal General Hospital, McGill University Health Center, 1650 Cedar Avenue C7-200, Montreal, Quebec (Canada), H3G 1A4, e-mail talat.bessissow@mcgill.ca

ABSTRACT

Objectives: Balloon-assisted enteroscopy (BAE) is increasingly used for the evaluation of small bowel disorders. We quantified local diagnostic and therapeutic yields of BAE in patients with suspected small bowel diseases.

Methods: Adult patients undergoing BAE between January 2010 and July 2015 at McGill University Health Centre were included. Procedures were identified using a prospectively maintained database. Patients were excluded if procedure report was unavailable. Electronic medical records were reviewed. Analyses were restricted to patients who did not have a previous BAE.

Results: BAE was performed in 453 patients, including 421 antegrade cases. Patients had a mean age of 61.0 ± 17.5 years. Most common indications for referral were obscure gastrointestinal bleeding (OGIB) (n=207, 45.7%), abnormal imaging (n=88, 19.4%), suspected small bowel neoplasia (SBN) (n=39, 8.6%) and Crohn's disease (CD) (n=31, 6.8%). A diagnosis was established in 216 procedures (47.7%). A pre-endoscopic indication of CD (odds ratio [OR]: 3.78; 95% Confidence Interval [CI], 1.60–8.90), OGIB (OR: 3.69, 95% CI, 2.03–6.71), suspected SBN (OR: 2.45; 95% CI, 1.06–5.65) and previous VCE (OR: 9.33; 95% CI, 3.24–26.90) were associated with abnormal findings. A therapeutic procedure was performed in 126 cases (28.3%). OGIB (OR: 7.00; 95% CI, 3.83–12.81), previous video capsule endoscopy (VCE) (OR: 7.86; 95% CI, 2.93–21.04) and suspected SBN (OR: 6.30; 95% CI, 2.58–21.04) were associated with performance of a therapeutic intervention. Complication rate was 1.6%, with bleeding in seven cases and one perforation.

Conclusions: In carefully selected patients, such as those with OGIB, Crohn's disease and previous VCE, BAE was a safe procedure that led to the identification of abnormal findings and therapeutic interventions.

Keywords: *Diagnostic yield; Endoscopy; Small intestine; Therapeutic yield*

INTRODUCTION

The endoscopic evaluation of the small bowel has gone through a major revolution with the development of balloon-assisted enteroscopy (BAE) (1, 2). BAE is most commonly used in the evaluation of obscure gastrointestinal bleeding (OGIB) with reported diagnostic and therapeutic yields of 45% to 87% and

57% to 80%, respectively (3–9). The most commonly used therapeutic interventions are targeted to the treatment of vascular lesions (10). In patients with Crohn's disease (CD), BAE can detect small bowel lesions and provide endotherapy to manage bleeding, dilatation of small bowel strictures and retrieval of a foreign body, such as in cases of video capsule impaction

(11–16). Furthermore, BAE also allows for the detection and tissue sampling of small bowel tumors and may even allow for stent placement in cases of obstruction (17–20).

Since its introduction, BAE has been associated with complications. The reported incidences of minor and major complications are 9% and 0.72%, respectively (21). Complications such as bleeding and perforation are more frequent when the procedure is combined with a therapeutic intervention (22). Furthermore, sedation-related adverse events are seen in 17% of procedures (23). BAE has also been associated with cases of procedure-related pancreatitis in about 0.49% of patients (21). The most widely postulated mechanism suggests that mechanical stress on the pancreas or papilla caused by the pull-and-push motion leads to focal points of pancreatic ischemic necrosis.

Given the emergence of this endoscopic technique, BAE has been included in guidelines related to the management of suspected small bowel disease (24, 25). The main objective of our study is to better quantify the diagnostic and therapeutic yields of BAE in a high-volume centre and identify key pre-endoscopic factors that are associated with its optimal use.

METHODS

Study population and source

We performed a single-center retrospective cohort study conducted at the McGill University Health Center (MUHC, Montreal, Canada) that included all consecutive adult patients who underwent a BAE between January 2010 and July 2015. Patients were identified using Endoworks™ (Olympus, Central Valley, Pennsylvania, USA), a software used in the division of gastroenterology at the MUHC to prospectively document endoscopic procedures. Patients were excluded if the procedure was misclassified or if the enteroscopy report was unavailable.

Primary study objectives

Our primary objectives were to calculate the diagnostic and therapeutic yields of BAE in the evaluation of small bowel diseases at our centre.

Secondary study objectives

Secondary objectives included the identification of pre-endoscopic factors associated with improved diagnostic and therapeutic yields, determining the rate of procedural complications, describing the impact of BAE on management and identifying factors that would be associated with a change in management.

Definitions

The diagnostic yield was defined as the proportion of procedures with an endoscopic finding. Accepted endoscopic findings were classified as vascular lesions, ulcers or erosions, polyps, stricture, cancer, impacted video capsule, or others,

depending on the endoscopic description on the procedure report (26). The therapeutic yield was defined as the proportion of procedures where an endoscopic therapeutic intervention was carried out over the total number of procedures performed. Accepted therapeutic interventions included epinephrine injection, endoclips, APC, bipolar electrocoagulation, hemostatic powder, stent deployment, endoscopic dilatation, tattooing, polypectomy and foreign body retrieval. Therapeutic interventions were further classified as unsuccessful if on the procedure report, the therapeutic intervention was not able to achieve its intended purpose during the procedure.

The impact of BAE on management was assessed on a per procedure basis and was defined as the presence of clear recommendations in the procedural report that assisted in the care of the patient that would otherwise not have been planned for. These recommendations were then classified into medical, endoscopic, surgical or radiological. Medical recommendations were defined as the need for general medical care, including hospitalization, transfusions and prescribing or holding certain medications. Endoscopic recommendations were defined as the need for repeat endoscopic evaluation, including enteroscopy or video capsule endoscopy. Surgical recommendations were defined as the referral to a surgical service for further assessment or management. Radiological recommendations were defined as the referral to diagnostic or interventional radiology for further assessment or management. Procedural complication was defined as the occurrence of pancreatitis, bleeding or bowel perforation immediately following or within four weeks of the procedure.

Data collection

Demographic and clinical data were collected into dedicated standardized forms for each procedure through electronic chart review performed by trained research personnel. Endoscopic reports included patient characteristics, indication for procedure, medication use, technical procedural data, a description of the endoscopic findings and therapeutic interventions performed, direct complications, and recommendations in the management of the patient.

BAEs were performed by one of two expert gastroenterology endoscopists with training in BAE (TB, CAS) after they had screened the referrals. Patients referred for OGIB would need to have undergone a gastroscopy, a colonoscopy to the cecum with satisfactory views and preparation, and small bowel imaging prior to the referral. For other referrals, an accompanying small bowel imaging was requested. Accepted small bowel imaging modalities included VCE, computed tomography (CT) of the abdomen or enterography, magnetic resonance of the abdomen or enterography or small bowel follow-through. Single-balloon enteroscopy (SBE) has been performed at our centre since January 2011 using equipment consisting of the

SIF-Q180 enteroscopy (Olympus, Tokyo, Japan), the overtube balloon control unit (Olympus Balloon Control Unit) and a disposable silicone splinting tube with balloon (ST-SB1). Double-balloon enteroscopy (DBE) was performed using the Fujinon system (Fujinon, Saitama, Japan) until December 2010. For anterograde BAE, patients were asked to fast for at least 6 hours before the procedure. For retrograde BAE, patients had to drink a colonic cleansing preparation using split dose Pico-Salax, similar to a colonoscopy, and were asked to fast for at least 2 hours prior to the procedure. Sedation was administered using fentanyl and midazolam; buscopan was also administered to selected patients at the discretion of the endoscopist.

Statistical analysis

Considering that some patients may have more than one BAE, and that it may bias our results, we have decided to conduct our analysis on patients with no prior BAE. Therefore, the results reported will focus on BAE-naïve patients. Data analysis included descriptive statistics computed for continuous variables including means and standard deviations (SD). Percentages were used for categorical variables. Between-groups comparisons were performed using χ^2 , Fishers exact test, t-test or Wilcoxon rank testing, as appropriate. The clinical variables included in the multivariable analysis were chosen based on possible predictors identified in the literature and guided by the univariable analysis (attached in Appendix A). Multivariable logistic regression analyses were used to identify possible variables associated with the presence of endoscopic findings and therapeutic intervention. All analyses were done using SAS software version 9.4 (SAS Institute, Cary, NC, USA). A P value of less than or equal to 0.05 was considered significant.

Ethical considerations

The study was conducted according to the ethical principles stated in the Declaration of Helsinki (2008) and approved by the McGill University Health Center Institutional Review Board (15-173-MUHC).

RESULTS

There were 543 BAEs performed on 453 individual patients during the study period with a mean number of 1.3 ± 0.7 procedure per patient. When we focused our analyses to patients at their first BAE, the mean age was 61.0 ± 17.5 years, 242 patients were male (53.4%), and 429 procedures were performed on outpatients (94.9%) (Table 1), while 421 (94.4%) of the procedures were anterograde. Forty-five procedures were performed using the DBE system between January and December 2010, and 408 procedures were performed using the SBE system between January 2011 and July 2015. The most common indication for BAE was occult gastrointestinal bleed (OGIB), either

overt or obscure, (n=207, 45.7%), followed by assessment of abnormal small bowel imaging (n=88, 19.4%), suspected small bowel neoplasia (n=39, 8.6%) and CD (n=31, 6.8%) (Table 1). Furthermore, endoscopic evaluation predating BAE was reported in 324 cases (70.9%), which was most often with a gastroscopy or a colonoscopy. In patients with OGIB, 76.8% of patients had previous endoscopic evaluation recorded. Only 65 (14.4%) patients had a video capsule endoscopy before BAE (Table 1). Imaging was available in 212 (46.4%) cases, with 172 (38.0%) being from computed tomography of the abdomen, and 29 (6.4%) from magnetic resonance of the abdomen (Table 1). Further information on the baseline characteristics of the patients included in our cohort can be found in Table 1.

Primary and secondary outcomes

An abnormal endoscopic finding was reported in 216 procedures, with an overall diagnostic yield of 47.7%. The most common findings were vascular lesions (n=94, 43.5%), followed by ulcers (n=78, 36.1%) or polypoid lesions (n=30, 13.9%). A more complete list of findings is listed in Table 2. Overall, patients with OGIB had a diagnostic yield of 58%. In patients with OGIB, the presence of small bowel imaging, including VCE before BAE, did not increase the diagnostic yield (55.3% versus 60.6%, $p=0.483$). When further analyzing patient with OGIB who underwent a VCE before BAE, the diagnostic yield was 56.8% compared with 58.2% for those with or without a prior VCE, respectively ($p=1$). Amongst patients with CD or suspected tumor evaluation, the presence of VCE or imaging prior to the enteroscopy tended towards increased diagnostic yield, but was not statistically significant (69.7% versus 48.7%, $p=0.07$).

A therapeutic intervention was carried out in 128 procedures, with an overall therapeutic yield of 28.3%. Amongst patients with a therapeutic intervention, the most common treatment modality was argon plasma coagulation (n=56, 43.8%), followed by epinephrine injection (n=23, 18.0%), polypectomy (n=18, 14.1%), bipolar electrocoagulation (n=13, 10.2%) and clipping (n=11, 8.6%) (Table 3). In patients with an abnormal endoscopic finding, a therapeutic intervention was deemed necessary and was performed in 56.4% of patients.

BAE led to a change in management in 270 (59.6%) cases. Medical optimization was recommended in 100 (22.1%) cases, followed by a radiological intervention in 60 (13.3%) or surgical intervention in 56 (12.4%) cases. Video capsule endoscopy was recommended in only 25 (5.5%) cases following enteroscopy (Figure 1).

Factors associated with improved diagnostic or therapeutic yields and impact on management

Results of the univariate analysis are presented in Appendix A. The following results pertain to the multivariate analysis. The diagnostic yield improved with increased age (odds ratio [OR]:

Table 1. Baseline characteristics of the primary cases of balloon assisted enteroscopy performed at our centre

Variables	Total (N=453), n (%)
Age, years (SD)	61.0 (17.5)
Male sex	242 (53.4)
Outpatient	429 (94.9)
Anterograde BAE	421 (94.4)
Previous endoscopy	324 (70.9)
Gastroscopy	40 (8.8)
Colonoscopy	59 (13.0)
Gastroscopy and colonoscopy	176 (38.9)
Video capsule endoscopy	65 (14.4)
Prior imaging	212 (46.4)
Computed tomography	172 (38.0)
Magnetic Resonance	29 (6.4)
Indication for BAE	
Obscure Gastrointestinal Bleeding	207 (45.7)
Abnormal imaging	88 (19.4)
Suspected small bowel neoplasia	39 (8.6)
Crohn's disease	31 (6.8)
Diarrhea	30 (6.6)
Abnormal video capsule	25 (5.5)
Abdominal pain	21 (4.6)
Other	31 (6.8)

1.02; 95% confidence interval [CI], 1.01–1.03), indication of OGIB (OR: 3.69; 95% CI, 2.03–6.71), CD (OR: 3.78; 95% CI, 1.60–8.90), suspected small bowel neoplasia (OR: 2.45; 95% CI, 1.06–5.65) and previous VCE (OR: 9.33; 95% CI, 3.24–26.90) (Table 4).

The therapeutic yield increased with increasing age (OR: 1.03; 95% CI, 1.02–1.05), indication of OGIB (OR: 7.21; 95% CI, 3.94–13.22), suspected small bowel neoplasia (OR: 6.97; 95% CI, 2.90–16.77) and previous video capsule (OR: 7.95; 95% CI 2.97–21.27) (Table 5).

The impact of BAE on the management of the patient was not significantly higher in patients with a pre-endoscopic diagnosis of suspected small bowel neoplasia (OR: 1.73; 95% CI, 0.83–3.57), nor with male gender (OR: 1.19; 95% CI, 0.81–1.74).

Table 2. Breakdown of the endoscopic findings identified in procedures with a positive finding

Endoscopic finding	Number of cases (%) N=216
Vascular lesion	94 (43.5)
Ulcer	78 (36.1)
Polypoid lesion	30 (13.9)
Stricture	11 (5.1)
Cancer	2 (0.9)
Other	19 (8.8)

but was significantly lower in patients with a pre-endoscopic diagnosis of CD (OR: 0.42; 95% CI, 0.20–0.88). A pre-endoscopic diagnosis of OGIB had no impact on the subsequent management of patient.

Medication usage

Conscious sedation was the preferred method of sedation. Midazolam and fentanyl were the two most commonly used medications in 89.2% of cases, with mean doses of 3.30 ± 1.32 mg and 101.9 ± 38.2 mcg respectively. Buscopan was used in 20.1% of cases with a mean dose of 15.5 ± 7.0 mg. Nonsignificant higher doses of buscopan were used when an endoscopic finding was identified or a therapeutic intervention was carried out (16.0 ± 7.2 mg and 14.2 ± 6.4 mg, $p=0.13$), although higher doses of fentanyl were required when there were no endoscopic findings on BAE (109.0 ± 39.7 mcg versus 98.5 ± 40.9 mcg, $p<0.01$).

Safety

Complications were reported in 1.6% of cases. Bleeding occurred in seven cases (1.6%), and perforation in one case (0.2%). There were no reported cases of pancreatitis or sedation-related adverse events in our cohort. Bleeding was more likely to occur after a therapeutic intervention, although not significantly different (3.1% versus 0.9%, $p=0.10$). The three cases of bleeding that occurred during the diagnostic procedure were from Mallory Weiss tears; however, the cases reported after therapeutic enteroscopy were due to bleeding after treatment of a vascular lesion. The only perforation was successfully managed conservatively with endoclip application. Perforation was not associated with a therapeutic intervention or older age.

DISCUSSION

The use of BAE has revolutionized the evaluation of small bowel diseases (1). First with a double-balloon system, the

Table 3. Breakdown of the endotherapy carried out in procedures with a therapeutic intervention

Therapeutic intervention	Number of cases (%) N=128
Argon plasma coagulation	56 (43.8)
Injection	23 (18.0)
Polypectomy	18 (14.1)
Bipolar electrocoagulation	13 (10.2)
Clipping	11 (8.6)
Tattoo	10 (7.8)
Stricture dilatation	2 (1.6)
Hemospray	1 (0.8)
Unsuccessful	4 (3.1)

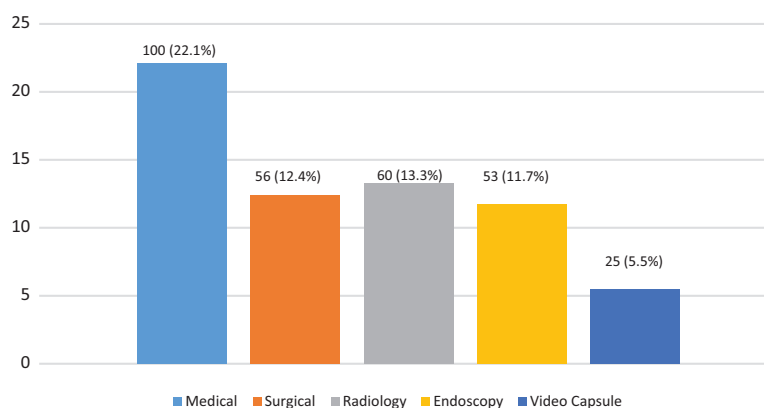


Figure 1. Impact of BAE on the management of patients.

development of SBE has subsequently allowed for similar diagnostic yield, therapeutic yield, procedure time, insertion depth, but possibly lower total enteroscopy rates (2, 27–31). Given the similarities between the two techniques, the choice of enteroscopy depends largely on local expertise and availability.

In this study, we report on the largest single Canadian centre experience on the use of BAE, including both DBE and SBE, from the McGill University Health Centre, Montreal, Canada. At our centre, we performed 543 BAEs on 453 individual patients over a 5-year period. Our results show that our diagnostic yield and therapeutic yield were 47.7% and 28.3% in BAE naïve patients, respectively. It is important to note that we restricted our analysis to patients at their first BAE in order to minimize any falsely inflated diagnostic or therapeutic yield.

Consistent with the literature, the main indication for BAE was for evaluation of OGIB, in 46% of cases (32). In this patient population, we could achieve higher diagnostic and therapeutic yields compared to all other indications. Our findings characterize a patient population that would benefit most from this type of investigation, both from diagnostic and therapeutic standpoints. Despite being commonly compared to video capsule endoscopy, BAE allows for targeted therapy of the identified bleeding lesion during the same session (33). It is important to remember that in cases of OGIB, VCE may miss lesions that could be identified on BAE in about 20–30% of cases (34, 35). A cost-effectiveness analysis showed that a DBE-first approach may be more advantageous than a VCE-first approach,

especially in patients with a higher likelihood of ongoing bleeding (34). This is most likely due to the fact that if a patient has a higher chance of ongoing OGIB, going for an intervention with a therapeutic capacity, such as BAE, may save costs. On the other hand, in patients less likely to have a bleeding source, the cost-saving advantage of VCE is thought to be related to the decrease in balloon enteroscopy workload (34). Furthermore, as we showed in our study, a previous VCE itself tended to increase the diagnostic yield of BAE—more so in patients with CD or suspected small bowel neoplasia, but not in patients with OGIB. Our study also notes that a previous VCE examination also increases the likelihood of performing a therapeutic procedure (36). In carefully selected patients, such as those with ongoing bleeding, a BAE-first approach may be acceptable and potentially cost-saving (24, 25).

The second-most common indication for BAE was for the evaluation of abnormal small bowel imaging of the small bowel. Patients with abnormal small bowel imaging studies seem to have a lower incidence of abnormal findings detected on BAE, potentially due to the poor specificity of the abnormal findings on imaging. We also diagnosed one case of metastatic melanoma. Although it was not associated with a higher diagnostic yield, BAE was still able to identify important findings and provide samples for histological evaluation and potentially prevent intraoperative exploration. In this situation, proceeding with a BAE depends on the cumulative body of evidence pointing toward a true pathological process.

We also report that the use of BAE impacts on the care pathway of patients in 59.6% of cases. These recommendations

Table 4. Multivariable analysis for improved diagnostic yield

Variable	Odds ratio (95% CI)
Previous VCE	9.33 (3.24–26.90)
Crohn's Disease	3.78 (1.60–8.90)
OGIB	3.69 (2.03–6.71)
Suspected small bowel neoplasia	2.45 (1.06–5.65)
Abnormal imaging	1.60 (0.82–3.11)
Age	1.02 (1.01–1.03)

Table 5. Multivariable analysis for improved therapeutic yield

Variable	Odds ratio (95% CI)
Previous VCE	7.86 (2.93–21.04)
OGIB	7.00 (3.81–12.83)
Suspected small bowel neoplasia	6.30 (2.58–21.04)
Age	1.03 (1.02–1.05)

were most often medical, including advice on the cessation or resumption of anticoagulants or antiplatelet agents and transfusion of blood products, followed by suggestions of further imaging, and lastly, a referral for surgical opinion. Patients with CD were less likely to have recommendations to change their management. This is most likely because patients with CD would usually follow up with their treating physician who would then decide on the best change in management after synthesizing all the available information. Our data seem to indicate that having an endoscopist review the clinical scenario and perform an investigation with BAE can provide further medical assessment of a patient's condition and suggest therapeutic interventions subsequent to the endoscopy. Furthermore, our study reinforces that BAE is a safe procedure. We report seven cases of bleeding and one perforation, for a complication rate of 1.6%, similar to rates previously published in the literature to date (22).

Our study has certain limitations mainly related to its retrospective nature. Furthermore, we determined the impact of BAE on the management of patients retrospectively using the procedural reports, making this a posteriori analysis. Since we receive many referrals from other hospitals, endoscopic evaluations may not be repeated at our centre, explaining the 77% pre-BAE endoscopic evaluation. Lastly, since we chose to analyze our data in patients that were BAE-naïve, it may not reflect the overall clinical course of a patient with multiple balloon enteroscopies. Despite these limitations, the validity of our findings is supported by similar reports on diagnostic yield, therapeutic yield and complication rate of BAE published in previous large series.

In conclusion, BAE is a very useful endoscopic technique that facilitates the diagnosis of small bowel disorders and the application of targeted endotherapy impacting favorably on the care of a majority of patients. Our study also identified key pre-endoscopic factors associated with increased diagnostic and therapeutic yields. As its availability depends on local expertise, choosing patients wisely for this procedure is paramount in order to maximize both the diagnostic and therapeutic yield. Further studies looking at the need for pre-BAE VCE in selected patients with OGIB are still warranted.

SUPPLEMENTARY DATA

Supplementary data are available at *Journal of the Canadian Association of Gastroenterology* online.

ACKNOWLEDGEMENTS

All authors contributed significantly to the manuscript and approved the final version. The study was conducted according to the ethical principles stated in the Declaration of Helsinki (2008) and approved by the McGill University Health Center Institutional Review Board (15-173-MUHC).

Conflicts of interest

PLL has served as a speaker and/or advisory board member for AbbVie, EGIS, Falk Pharma GmbH, Ferring, Genetech, Janssen, Kyowa Hakko Kirin Pharma, Mitsubishi Tanabe Pharma Corporation, MSD, Otsuka Pharma, Pharmacosmos, Pfizer, Roche, Shire and Takeda; PLL has received unrestricted research funding from AbbVie, MSD and Pfizer. ANB has served as a consultant and/or advisory committee member of Cook, Olympus and Pendopharm, and has received research support from Boston Scientific, Cook, and Pendopharm. TB has served as a speaker, a consultant, and an advisory board member for Janssen, Abbvie, Takeda, Pfizer, Ferring, Pendopharm, Shire, and has received research funding from Abbvie and Janssen. AB, MSS, JCP, MM, CAS have no conflicts of interest to disclose.

Authors contribution

Conception and design (AB, CAS, TB); analysis and interpretation of the data (AB, MSS, JCP, MM, PLL, ANB, CAS, TB); drafting of the article (AB, MSS, MM); critical revision of the article for important intellectual content (AB, MM, PLL, ANB, CAS, TB); final approval of the article (AB, MSS, JCP, MM, PLL, ANB, CAS, TB).

REFERENCES

1. Yamamoto H, Sekine Y, Sato Y, et al. Total enteroscopy with a non-surgical steerable double-balloon method. *Gastrointest Endosc.* 2001;53(2):216–20.
2. Hartmann D, Eickhoff A, Tamm R, et al. Balloon-assisted enteroscopy using a single-balloon technique. *Endoscopy.* 2007;39(Suppl 1):E276.
3. Godeschalk MF, Mensink PB, van Buuren HR, et al. Primary balloon-assisted enteroscopy in patients with obscure gastrointestinal bleeding: Findings and outcome of therapy. *J Clin Gastroenterol.* 2010;44(9):e195–200.
4. Li X, Dai J, Lu H, et al. A prospective study on evaluating the diagnostic yield of video capsule endoscopy followed by directed double-balloon enteroscopy in patients with obscure gastrointestinal bleeding. *Dig Dis Sci.* 2010;55(6):1704–10.
5. Ohmiya N, Yano T, Yamamoto H, et al. Diagnosis and treatment of obscure GI bleeding at double balloon endoscopy. *Gastrointest Endosc.* 2007;66(Suppl 3):S72–7.
6. Arakawa D, Ohmiya N, Nakamura M, et al. Outcome after enteroscopy for patients with obscure GI bleeding: Diagnostic comparison between double-balloon endoscopy and videocapsule endoscopy. *Gastrointest Endosc.* 2009;69(4):866–74.
7. Hadithi M, Heine GD, Jacobs MA, et al. A prospective study comparing video capsule endoscopy with double-balloon enteroscopy in patients with obscure gastrointestinal bleeding. *Am J Gastroenterol.* 2006;101(1):52–7.
8. Aniwat S, Viriyautsahakul V, Angsuwatcharakon P, et al. Comparison of urgent video capsule endoscopy and urgent double-balloon endoscopy in massive obscure gastrointestinal bleeding. *Hepatogastroenterology.* 2014;61(135):1990–4.
9. Kaffes AJ, Siah C, Koo JH. Clinical outcomes after double-balloon enteroscopy in patients with obscure GI bleeding and a positive capsule endoscopy. *Gastrointest Endosc.* 2007;66(2):304–9.

10. Bollinger EE, Spera MA, Raines DL. Device-assisted enteroscopy for obscure gastrointestinal bleeding in the setting of thienopyridine antiplatelet therapy. *J Clin Gastroenterol*. 2017;51(1):e1–4.
11. Jang HJ, Choi MH, Eun CS, et al. Clinical usefulness of double balloon enteroscopy in suspected Crohn's disease: The KASID multi-center trial. *Hepatogastroenterology*. 2014;61(133):1292–6.
12. Seiderer J, Herrmann K, Diepolder H, et al. Double-balloon enteroscopy versus magnetic resonance enteroclysis in diagnosing suspected small-bowel Crohn's disease: results of a pilot study. *Scand J Gastroenterol*. 2007;42(11):1376–85.
13. Schulz C, Monkemuller K, Salheiser M, et al. Double-balloon enteroscopy in the diagnosis of suspected isolated Crohn's disease of the small bowel. *Dig Endosc*. 2014;26(2):236–42.
14. Zuber-Jerger I, Gelbmann CM, Endlicher E, et al. Complicated wireless capsule enteroscopy in a patient with Crohn's disease. *Eur J Gastroenterol Hepatol*. 2009;21(8):952–4.
15. Hayashi Y, Yamamoto H, Yano T, et al. A calibrated, small-caliber tip, transparent hood to aid endoscopic balloon dilation of intestinal strictures in Crohn's disease: Successful use of prototype. *Endoscopy*. 2013;45(Suppl 2)UCTN:E373–4.
16. Pasha SF, Leighton JA. Enteroscopy in the diagnosis and management of Crohn disease. *Gastrointest Endosc Clin N Am*. 2009;19(3):427–44.
17. Cangemi DJ, Patel MK, Gomez V, et al. Small bowel tumors discovered during double-balloon enteroscopy: analysis of a large prospectively collected single-center database. *J Clin Gastroenterol*. 2013;47(9):769–72.
18. Manno M, Riccioni ME, Cannizzaro R, et al. Diagnostic and therapeutic yield of single balloon enteroscopy in patients with suspected small-bowel disease: Results of the Italian multicentre study. *Dig Liver Dis*. 2013;45(3):211–5.
19. Kida A, Matsuda K, Noda Y. Endoscopic metallic stenting by double-balloon enteroscopy and its overtube for malignant gastrointestinal obstruction as palliative treatment. *Dig Endosc*. 2013;25(5):552–3.
20. Chen WG, Shan GD, Zhang H, et al. Double-balloon enteroscopy in small bowel tumors: A Chinese single-center study. *World J Gastroenterol*. 2013;19(23):3665–71.
21. Xin L, Liao Z, Jiang YP, et al. Indications, detectability, positive findings, total enteroscopy, and complications of diagnostic double-balloon endoscopy: A systematic review of data over the first decade of use. *Gastrointest Endosc*. 2011;74(3):563–70.
22. Mensink PB, Haringsma J, Kucharzik T, et al. Complications of double balloon enteroscopy: A multicenter survey. *Endoscopy*. 2007;39(7):613–5.
23. Sethi S, Thaker AM, Cohen J, et al. Monitored anesthesia care without endotracheal intubation is safe and efficacious for single-balloon enteroscopy. *Dig Dis Sci*. 2014;59(9):2184–90.
24. Pennazio M, Spada C, Eliakim R, et al. Small-bowel capsule endoscopy and device-assisted enteroscopy for diagnosis and treatment of small-bowel disorders: European Society of Gastrointestinal Endoscopy (ESGE). *Clinical Guideline Endoscopy*. 2015;47(4):352–76.
25. Committee ASOP, Khashab MA, Pasha SF, et al. The role of deep enteroscopy in the management of small-bowel disorders. *Gastrointest Endosc*. 2015;82(4):600–7.
26. Yano T, Yamamoto H, Sunada K, et al. Endoscopic classification of vascular lesions of the small intestine (with videos). *Gastrointest Endosc*. 2008;67(1):169–72.
27. Domagk D, Mensink P, Aktas H, et al. Single- vs. double-balloon enteroscopy in small-bowel diagnostics: a randomized multicenter trial. *Endoscopy*. 2011;43(6):472–6.
28. Takano N, Yamada A, Watabe H, et al. Single-balloon versus double-balloon endoscopy for achieving total enteroscopy: A randomized, controlled trial. *Gastrointest Endosc*. 2011;73(4):734–9.
29. Efthymiou M, Desmond PV, Brown G, et al. SINGLE-01: A randomized, controlled trial comparing the efficacy and depth of insertion of single- and double-balloon enteroscopy by using a novel method to determine insertion depth. *Gastrointest Endosc*. 2012;76(5):972–80.
30. Lipka S, Rabbanifard R, Kumar A, et al. Single versus double balloon enteroscopy for small bowel diagnostics: A systematic review and meta-analysis. *J Clin Gastroenterol*. 2015;49(3):177–84.
31. Wadhwa V, Sethi S, Tewani S, et al. A meta-analysis on efficacy and safety: Single-balloon vs. double-balloon enteroscopy. *Gastroenterol Rep (Oxf)*. 2015;3(2):148–55.
32. Lin MC, Chen PJ, et al. Outcome and safety of antegrade and retrograde single-balloon enteroscopy: Clinical experience at a tertiary medical center in Taiwan. *PLoS One*. 2016;11(8):e0161188.
33. Pasha SF, Leighton JA, Das A, et al. Double-balloon enteroscopy and capsule endoscopy have comparable diagnostic yield in small-bowel disease: A meta-analysis. *Clin Gastroenterol Hepatol*. 2008;6(6):671–6.
34. Gerson LB. Small bowel endoscopy: Cost-effectiveness of the different approaches. *Best Pract Res Clin Gastroenterol*. 2012;26(3):325–35.
35. Teshima CW, May G. Small bowel enteroscopy. *Can J Gastroenterol*. 2012;26(5):269–75.
36. Sethi S, Cohen J, Thaker AM, et al. Prior capsule endoscopy improves the diagnostic and therapeutic yield of single-balloon enteroscopy. *Dig Dis Sci*. 2014;59(10):2497–502.