

## CASE REPORT

# Pneumoparotid related to obstructive sleep apnea syndrome treated by oral appliance with anterior opening to reduce intraoral pressure

Kazuya Yoshida 

Department of Oral and Maxillofacial Surgery, National Hospital Organization, Kyoto Medical Center, Kyoto, Japan

**Correspondence**

Kazuya Yoshida, Department of Oral and Maxillofacial Surgery, National Hospital Organization, Kyoto Medical Center, 1-1 Mukaihata-cho, Fukakusa, Fushimi-ku, Kyoto 612-8555, Japan.  
Email: [yoshida.kazuya.ut@mail.hosp.go.jp](mailto:yoshida.kazuya.ut@mail.hosp.go.jp)

**Funding information**

This study was supported by JSPS KAKENHI Grant Numbers JP24592946 and JP22111201

**Abstract**

Pneumoparotid is associated with retrograde air insufflation in Stensen's duct and the parotid gland. A 57-year-old man experienced swelling and pain in the right parotid region after sleeping during a flight. Pneumoparotid and obstructive sleep apnea syndrome were diagnosed. Pneumoparotid was suspected as caused by increased intraoral pressure during sleep; thus, an oral appliance to reduce intraoral pressure was effective. After 9 years, the symptoms recurred on the left side. The appliance was reinserted and helped substantially. This is the first case report of obstructive sleep apnea syndrome accompanying pneumoparotid, treated effectively with an oral appliance, with a 10-year follow-up.

**KEYWORDS**

obstructive sleep apnea syndrome, oral appliance therapy, parotid gland, parotid swelling, pneumoparotid

## 1 | INTRODUCTION

Swelling or pain in the parotid region is a relatively common complaint in the clinical practice of otolaryngology, internal medicine, and oral and maxillofacial surgery. There are many causes of parotid gland swelling, including inflammation, viral infection, sialoliths, benign or malignant tumors, autoimmune diseases, and endocrine disorders. Pneumoparotid is one of the causes of parotid gland swelling, which refers to the retrograde insufflation of air inside the parotid gland or Stensen's duct. The pneumoparotid was first described by Hyrtl<sup>1</sup> in 1865 in wind instrument players. Moreover, until the first half of the 20th century, pneumoparotid has been recognized as a typical occupational disease in glassblowers.<sup>2-4</sup> However, the other etiologies of pneumoparotid vary and include

self-induction,<sup>5-11</sup> abnormal habit,<sup>12-14</sup> coughing attack,<sup>15-17</sup> nervous tic,<sup>5,18,19</sup> and iatrogenic causes such as dental treatment,<sup>19-22</sup> continuous positive pressure,<sup>23,24</sup> and spirometry.<sup>25</sup>

Apnea is defined as the cessation of airflow ( $\geq 90\%$  decrease in airflow compared to baseline) lasting at least 10 s.<sup>25</sup> Apneas are classified as obstructive, central, or mixed based on the pattern of respiratory effort.<sup>25</sup> An obstructive apnea is associated with continued or increased inspiratory effort throughout the entire period of absent airflow.<sup>25</sup> A central apnea is associated with absent inspiratory effort throughout the entire period of absent airflow.<sup>25</sup> Mixed apneas are associated with absent inspiratory effort in the initial portion of the event, followed by resumption of inspiratory effort in the second portion of the event.<sup>25</sup> Typical subjective complaints of sleep apnea

This is an open access article under the terms of the [Creative Commons Attribution-NonCommercial-NoDerivs](https://creativecommons.org/licenses/by-nc-nd/4.0/) License, which permits use and distribution in any medium, provided the original work is properly cited, the use is non-commercial and no modifications or adaptations are made.

© 2022 The Authors. *Clinical Case Reports* published by John Wiley & Sons Ltd.

syndrome are excessive daytime sleepiness, loud and irregular snoring, disturbed nighttime sleep, mental deterioration, and depression.<sup>26–30</sup> A recent systematic review highlighted that the overall prevalence of obstructive sleep apnea ranges from 9% to 38% in the general adult population.<sup>31</sup>

Continuous positive airway pressure is an effective treatment option for this condition. However, problems associated with its use leading to noncompliance include nasal congestion, discomfort secondary to pressure sensation and air leak, and mask intolerance.<sup>30,31</sup> In 1984, Meier-Ewert et al.<sup>32</sup> first described an oral appliance for obstructive sleep apnea syndrome. Oral appliances are an important treatment choice and maybe the preferred initial treatment for mild-to-moderate obstructive sleep apnea syndrome or snoring.

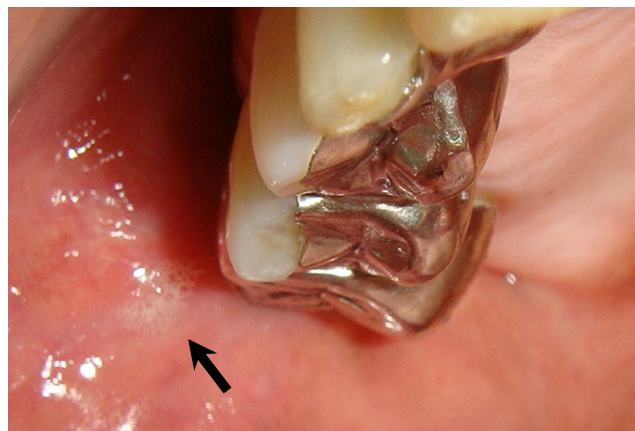
In this study, we describe the case of a patient with pneumoparotid related to obstructive sleep apnea syndrome and oral appliance therapy. A plausible relationship between pneumoparotid and sleep apnea syndrome is discussed.

## 2 | CASE PRESENTATION

Pneumoparotid refers to retrograde insufflation of air inside the parotid gland. In a patient with pneumoparotid accompanying sleep apnea syndrome, an oral appliance with an anterior opening to reduce intraoral pressure can be effective.

A 57-year-old man was referred to the Department of Oral and Maxillofacial Surgery, Kyoto Medical Center, with a chief complaint of recurrent swelling of the right parotid region. Four years before the first visit, he developed bilateral parotid gland swelling and was prescribed antibiotics (cefditoren pivoxil) by his otolaryngologist, and the symptoms disappeared. Three years later, the patient experienced rapid swelling and pain in the right parotid region during sleep, when he boarded an airplane and landed. The patient was prescribed antibiotics in a landed country. The symptoms disappeared gradually and spontaneously; however, 3 weeks before the first visit to our department, severe symptoms recurred in the same region, and he visited an otolaryngologist. He took antibiotics (cefditoren pivoxil) for 2 weeks without improvement; he was advised to visit a dentist, following which the dentist introduced him to our department.

The right parotid gland was slightly swollen and tender. He had no fever, and no abnormalities such as redness were observed on the skin of the cheek. Blood tests revealed no evidence of inflammation. Crepitus was generated by light compression of the right parotid gland, and frothy saliva with fine air bubbles was discharged from

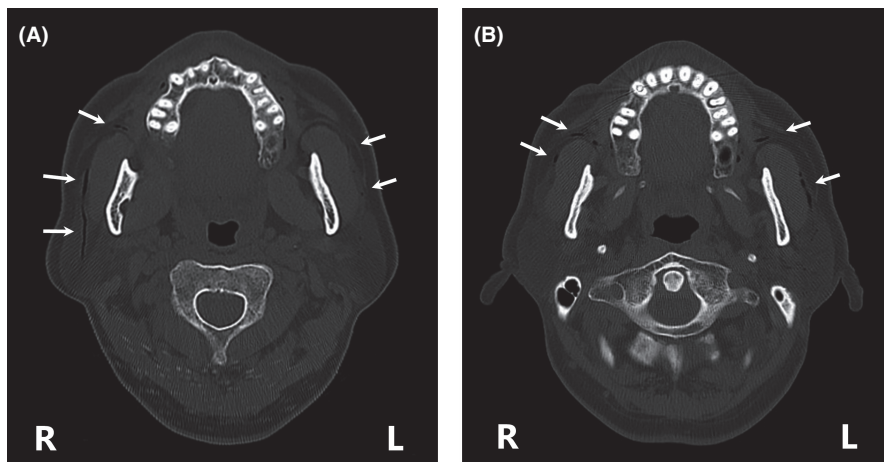


**FIGURE 1** Air bubbles from the orifice of Stensen's duct

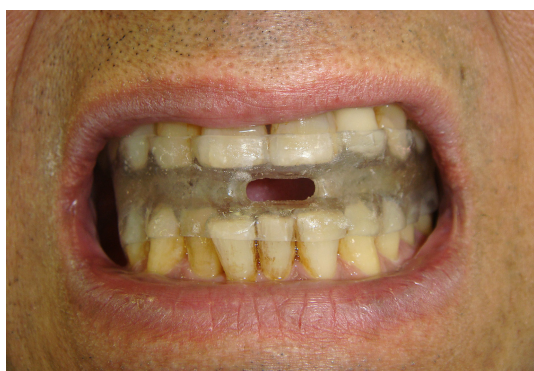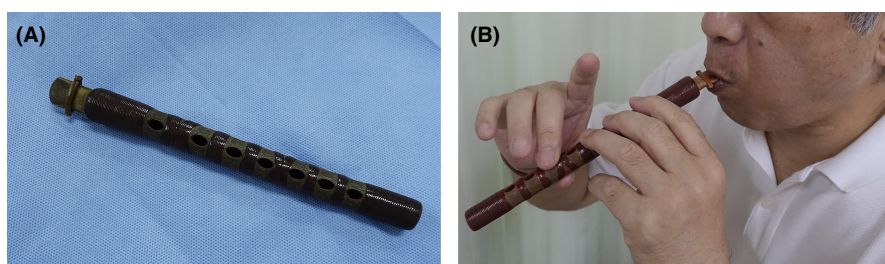
the papilla of the right parotid gland (Figure 1). Crepitus and swelling in the parotid region were prominent during waking up. Computed tomography showed air predominantly on the right side of both parotid glands and ducts and no sialoliths (Figure 2). The patient was on oral medication because of hypertension. However, the history of mumps remains unclear. For 20 years, from the age of 7 years, he played a traditional Japanese wind instrument, hichiriki (Figure 3). He did not snore. He had gained 4 kg in the last 5 years. His body mass index was 24.1. Because the patient complained of daytime sleepiness, sleep apnea syndrome was suspected. A sleep study was performed for three nights at home using a pulse oximeter (Pulsox-300; Konica Minolta). The examination revealed a mean apnea-hypopnea index [The number of Apneas plus the number of Hypopneas during the entire sleeping period, times 60, divided by total sleep time in minutes; unit: event per hour<sup>25</sup>] of 10.3 and a mean minimal oxygen saturation of 81.0%. The patient was diagnosed with mild sleep apnea syndrome.

As crepitus and swelling in the parotid region were prominent during waking, it was postulated that desaturation events could be related to a rapid increase in intraoral pressure. Therefore, an oral appliance to prevent obstruction of the upper airway and reduce intraoral pressure (Figure 4) was fabricated, as described previously.<sup>29–31</sup> The mandibular position was 6 mm, protruding from the intercuspal position. An anterior opening was made between the upper and lower incisors (Figure 4). After insertion of the oral appliance, sleep variables improved considerably (mean apnea-hypopnea index, 2.9; mean minimal oxygen saturation, 90.8%). One month later, the pneumoparotid symptoms disappeared completely. The patient was followed up with the appliance. After a few years, the patient discontinued the appliance as the symptoms disappeared. After 4 years, the patient had bilateral parotid gland swelling, and antibiotics were prescribed for 1 week by an otolaryngologist. After

**FIGURE 2** Axial sections of a CT scan show air in both parotid glands and ducts at first visit (A) and 9 years later (B). Air in the parotid glands or ducts (arrows)



**FIGURE 3** Hichiriki (A) is a traditional Japanese wind instrument with 1400 years of history. The patient playing the hichiriki (B)



**FIGURE 4** Oral appliance to reduce intraoral pressure in place

9 years, the patient experienced tenderness and swelling of the left parotid gland. The patient revisited our department for re-examination. The left parotid gland was tender. No abnormalities were observed in the parotid gland skin. Blood tests revealed no evidence of inflammation. Crepitus was detected by compression of the left parotid gland, and frothy saliva with fine air bubbles was discharged from the left parotid gland papilla. Computed tomography revealed the presence of air in both ductal systems, with more prominent findings in the left parotid gland (Figure 2b). A sleep study was also conducted. The test revealed a mean apnea-hypopnea index of 10.1 and mean minimal oxygen saturation of

79.8%. The results were remarkably similar to those 9 years prior. The oral appliance was inserted again, and sleep variables improved (mean apnea-hypopnea index, 3.1; mean minimal oxygen saturation, 90.3%). Symptoms related to sleep apnea syndrome and pneumoparotid disappeared completely. The patient was followed up for 10 years from the first visit. Relapse of these entities has not been observed until now.

### 3 | DISCUSSION

This study is the first to report a patient with obstructive sleep apnea syndrome accompanying pneumoparotid who was treated effectively with an oral appliance and was followed up for 10 years.

Pneumoparotid describes the presence of air within the duct system and/or parenchyma of the parotid gland secondary to its reflux through Stensen's duct. Parotitis associated with pneumoparotid is referred to as pneumoparotitis. Pneumoparotid has been observed in glassblowers until the first half of the 20th century.<sup>2-4</sup> In those days, 6%–10% of glassblowers had symptoms of suspected pneumoparotid.<sup>4</sup> More pressure is required to produce larger glassware than delicate work and is more likely to cause pneumoparotid.<sup>3,4</sup> Fortunately, subsequent innovations and mechanization have dramatically reduced pneumoparotid as an occupational disease in glass workers.



Previous studies have indicated an association between playing wind instruments, such as the trumpet,<sup>1,33,34</sup> horn,<sup>1,8,35</sup> tuba,<sup>36</sup> clarinet,<sup>8</sup> flute,<sup>37</sup> and recorder.<sup>38</sup> Stensen's duct valve prevents reflux into the parotid gland by the smaller diameter of the orifice, which is covered by redundant mucosal layers. The duct is laterally compressed by the masseter muscle and buccinator muscle contraction with an increase in oral pressure. If the intraoral pressure exceeds the protective mechanism, pneumoparotid can occur. Hyrtl<sup>1</sup> stated that when pressure in the oral cavity increases while playing a wind instrument, air can enter retrogradely from the orifice of Stensen's duct. He added that it is easier for beginners to pull in the air when they blow with their cheeks full and less likely to occur when they learn the appropriate embouchure technique.<sup>1</sup>

Gazia et al.<sup>39</sup> reviewed 49 reports and analyzed 54 patients with pneumoparotid or pneumoparotitis. The most frequent etiology is self-induction by blowing the cheeks, which mainly involves children for conflicts with parents, excuses for not going to school, and nervous tics.<sup>39</sup> Antibiotics and steroidal anti-inflammatory drugs are the most commonly used treatments. Behavioral therapy is used to remove bad habits such as blowing cheeks; in some cases, supportive psychotherapy is necessary.<sup>7,8,10,11,34</sup>

The relationship between pneumoparotid and sleep apnea syndrome remains to be elucidated. This patient played a traditional Japanese wind instrument, hichiriki (Figure 4), for 20 years from the age of 7 years. The hichiriki is made of bamboo and is small compared with other wind instruments (Figure 3); however, it requires considerably high pressure to play and emits a very large sound. Kreuter et al.<sup>40</sup> reported the intraoral pressure while playing various wind instruments; however, hichiriki was not included. Although the patient had seldom played hichiriki for 30 years after the age of 27, it might be a predisposing factor for enlargement of the orifice of Stensen's duct. It was suspected that air reflux occurred during sleep, as crepitus and swelling in the parotid region were prominent when waking up. The patient noticed the first swelling in the right parotid region when he boarded an airplane and slept, and the airplane landed. The sleep test indicated that the patient had mild obstructive sleep apnea syndrome. Playing hichiriki could be a predisposing factor, and the first occurrence of pneumoparotid was triggered by an increase in the barometric pressure on the board. Given that the patient boarded only once and pneumoparotid recurred, an increase in intraoral pressure could be a plausible cause of developing or maintaining pneumoparotid. Cabello et al.<sup>22</sup> reported a case of pneumoparotid that blew severely overnight. The patient in the present study did not snore. He may have been blown during sleep. The oral appliance with

an anterior opening might have helped prevent the oral cavity from increasing intraoral pressure during sleep. Oxygen saturation was considerably reduced, and intraoral pressure increased during sleep apnea, resulting in pneumoparotid disease.

In 1995, the American Sleep Disorders Association issued guidelines stating that oral appliances are indicated for snoring, mild obstructive sleep apnea, and moderate-to-severe sleep apnea if continuous positive airway pressure is not accepted or if surgery is not appropriate.<sup>22</sup> Various oral appliances have been increasingly used for the treatment of sleep apnea syndrome. Several randomized trials have confirmed the effects of oral appliances.<sup>41-47</sup> Recent guidelines have extended indications to patients with moderate and severe sleep apnea when a patient refuses continuous positive airway pressure therapy after being informed about the risks.<sup>48</sup> All appliances for the treatment of sleep apnea syndrome are constructed with the goal of advancing the position of the mandible and tongue to enlarge the airway or reduce its collapsibility.<sup>27-31,49</sup> This may lead to an improvement in the upper airway dimensions and possible effects on upper airway and masticatory muscle tone.<sup>50</sup> Suppression of events that increase intraoral pressure in patients is indispensable. This is the first to report an oral appliance to reduce intraoral pressure with anterior opening for the treatment of pneumoparotid (Figure 4). Some researchers have reported patients with pneumoparotid accompanied by obstructive sleep apnea syndrome.<sup>22-24</sup> Long-term use of oronasal continuous positive airway pressure<sup>23,24</sup> or mandibular advancement devices<sup>22</sup> can be a potential cause of pneumoparotid. In a recent review,<sup>39</sup> 24.1% of patients with pneumoparotid disease had an unknown etiology. The average age of the idiopathic cases was 28.6 years.<sup>39</sup> In some patients, pneumoparotid gland involvement may be associated with sleep apnea syndrome. Further studies using polysomnography in larger cases may be necessary to clarify this hypothesis.

## ACKNOWLEDGMENTS

The author would like to thank Ms. Kumiko Yasui (Library of Kyoto Medical Center) for collecting the literature.

## AUTHOR CONTRIBUTION

K.Y. diagnosed and treated the patient, analyzed the results, and wrote the manuscript.

## CONFLICT OF INTEREST

The author declares no conflict of interest.

## CONSENT

Written informed consent was obtained from the patient for the publication of this case report.

## DATA AVAILABILITY STATEMENT

The data of this study are available from the author upon request. However, confidential patient data cannot be shared.

## ORCID

Kazuya Yoshida  <https://orcid.org/0000-0002-2985-4347>

## REFERENCES

- Hyrtil J, ed. Vordere Mundhöhle. In: *Handbuch der topographischen Anatomie und ihrer praktisch medicinisch-chirurgischen Anwendungen* 5th ed. Braumüller; 1865:390.
- Deichmüller. Luftgeschwulst der Wange (Pneumatozele). *Berl Klin Wochenschr.* 1890;54:1226.
- Scheele. Über Glasbläsern und seine Komplikationen. *Berl Klin Wochenschr.* 1900;10:207-210, 241-244.
- Scheier M. Über die Krankheiten der Mundhöhle bei Glasbläsern. *Arch f Laryngol.* 1907;19:472-496.
- Rysenaer L, van Deirse J, Stuyt LB. Pneumo-parotidite récidivante. *Pract Oto Rhinologyngol.* 1963;25:128-131.
- Rupp RN. Pneumoparotid. *Arch Otolaryngol.* 1963;77:111.
- Calcaterra TC, Pneumoparotiditis LJ. An unusual case of parotid gland swelling. *Arch Otolaryngol.* 1973;97:468-469.
- Watt J. Benign parotid swellings: a review. *Proc R Soc Med.* 1977;70:483-486.
- Markowitz-Spence L, Brodsky L, Seidell G, Stanievich JF. Self-induced pneumoparotitis in an adolescent. Report of a case and review of the literature. *Int J Pediatr Otorhinologyngol.* 1987;14:113-121.
- Goguen LA, April MM, Karmody CS, Carter BL. Self-induced pneumoparotitis. *Arch Otolaryngol Head Neck Surg.* 1995;121:1426-1429.
- Golz A, Joachims HZ, Netzer A, et al. Pneumoparotitis: diagnosis by computed tomography. *Am J Otolaryngol.* 1999;20:68-71.
- Komori T, Sato O, Mori Y, et al. Emphysema of the parotid gland induced by abnormal habit: report of a case. *J Jpn Stomatol Soc.* 1988;37:696-701.
- Mandel L, Kaynar A, Wazen J. Pneumoparotid: a case report. *Oral Surg Oral Med Oral Pathol.* 1991;72:22-24.
- Sittel C, Jungehülsing M, Fischbach R. High-resolution magnetic resonance imaging of recurrent pneumoparotitis. *Ann Otol Rhinol Laryngol.* 1999;108:816-818.
- Garber MW. Pneumoparotitis: an unusual manifestation of hay fever. *Am J Emerg Med.* 1987;5:40-41.
- Cook JN, Layton SA. Bilateral parotid swelling associated with chronic obstructive pulmonary disease. A case of pneumoparotid. *Oral Surg Oral Med Oral Pathol.* 1993;76:157-158.
- Martin-Granizo R, Herrera M, García-González D, Mas A. Pneumoparotid in childhood: report of two cases. *J Oral Maxillofac Surg.* 1999;57:1468-1471.
- Ferlito A, Andretta M, Baldan M, Candiani F. Non-occupational recurrent bilateral pneumoparotitis in an adolescent. *J Laryngol Otol.* 1992;106:558-560.
- Gudlaugsson O, Geirsson AJ, Benediksdóttir K. Pneumoparotitis: a new diagnostic technique and a case report. *Ann Otol Rhinol Laryngol.* 1998;107:356-358.
- Takenoshita Y, Kawano Y, Oka M. Pneumoparotitis, an unusual occurrence of parotid gland swelling during dental treatment. Report of a case with a review of the literature. *J Craniomaxillofac Surg.* 1991;19:362-365.
- Brown FH, Ogletree RC, Houston GD. Pneumoparotitis associated with the use of an air-powder prophylaxis unit. *J Periodontol.* 1992;63:642-644.
- Cabello M, Macías E, Fernández-Flórez A, et al. Pneumoparotid associated with a mandibular advancement device for obstructive sleep apnea. *Sleep Med.* 2015;16:1011-1013.
- Abdullayev R, Saral FC, Kucukebe OB, et al. Bilateral parotitis in a patient under continuous positive airway pressure treatment. *Braz J Anesth.* 2016;66:661-663.
- Goates AJ, Lee DJ, Maley JE, et al. Pneumoparotitis as a complication of long-term oronasal positive airway pressure for sleep apnea. *Head Neck.* 2018;40:E5-E8.
- Kirsch CM, Shinn J, Porzio R, et al. Pneumoparotid due to spirometry. *Chest.* 1999;116:1475-1478.
- American Academy of Sleep Medicine. *AASM manual for the scoring of sleep and associated events: rules, terminology and technical specifications. Version 2.6.* American Academy of Sleep Medicine; 2020.
- Yoshida K. Prosthetic therapy for sleep apnea syndrome. *J Prosthet Dent.* 1994;72:296-302.
- Yoshida K. Influence of sleep posture on response to oral appliance therapy for sleep apnea syndrome. *Sleep.* 2001;24:538-544.
- Yoshida K. Effect on blood pressure of oral appliance therapy for sleep apnea syndrome. *Int J Prosthodont.* 2006;19:61-66.
- Yoshida K. Treatment and research of sleep apnea syndrome from clinical and neurophysiological aspects in the stomatognathic system. *Int J Med Biol Front.* 2011;17:1-88.
- Yoshida K. Treatment and research of sleep apnea syndrome from clinical and neurophysiological aspects in the stomatognathic system. Accessed March 8, 2022. <https://sites.google.com/site/sleepapneasyndrome/>
- Meier-Ewert K, Schäfer H, Kloss W. Treatment of sleep apnea by a mandibular protracting device. Proceedings of the seventh European sleep congress. München, 217, 1984.
- Gaus W. Seltene Spätfolge nach Parotis epidemica. *Zeitschr Für Hals-, Nasen, Ohrenheilkunde.* 1941;47:97-102.
- Nassimbeni G, Ventura A, Boehm P, et al. Self-induced pneumoparotitis. *Clin Pediatr.* 1995;34:160-162.
- Saunders HF. Wind parotitis. *N Engl J Med.* 1973;289:698.
- Mukundan D, Jenkins O. Images in clinical medicine. A tuba player with air in the parotid gland. *N Engl J Med.* 2009;360:710.
- Moëne KB, Cordero JT, Poli CH. Neumoparotiditis o neumoparótida en el niño: un diagnóstico diferencial a considerar. *Rev Chilena Infectol.* 2009;26:555-559.
- Kyung SK, Heurtebise F, Godon A, et al. Head-neck and mediastinal emphysema caused by playing a wind instrument. *Eur Ann Otorhinologyngol Head Neck Dis.* 2010;127:221-223.
- Gazia F, Freni F, Galletti C, et al. Pneumoparotid and pneumoparotitis: a literary review. *Int J Environ Res Public Health.* 2020;17:3936.
- Kreuter M, Kreuter C, Herth F. Pneumologische Aspekte des Musizierens auf einem Blasinstrument—physiologische, pathophysiologische und therapeutische Gesichtspunkte. *Pneumologie.* 2008;62:83-87.
- American Sleep Disorders Association Standards of Practice Committee. Practice parameters for the treatment of

- snoring and obstructive sleep apnea with oral appliances. *Sleep*. 1995;18:511-513.
42. Barnes M, McEvoy RD, Banks S, et al. Efficacy of positive airway pressure and oral appliance in mild to moderate obstructive sleep apnea. *Am J Respir Crit Care Med*. 2004;170:656-664.
  43. Hoekema A, Stegenga B, Wijkstra PJ, et al. Obstructive sleep apnea therapy. *J Dent Res*. 2008;87:882-887.
  44. Andrén A, Hedberg P, Walker-Engström ML, et al. Effects of treatment with oral appliance on 24-h blood pressure in patients with obstructive sleep apnea and hypertension: a randomized clinical trial. *Sleep Breath*. 2013;17:705-712.
  45. Phillips CL, Grunstein RR, Darendeliler MA, et al. Health outcomes of continuous positive airway pressure versus oral appliance treatment for obstructive sleep apnea: a randomized controlled trial. *Am J Respir Crit Care Med*. 2013;187:879-887.
  46. Marklund M, Carlberg B, Forsgren L, et al. Oral appliance therapy in patients with daytime sleepiness and snoring or mild to moderate sleep apnea: a randomized clinical trial. *JAMA Intern Med*. 2015;175:1278-1285.
  47. Sharples LD, Clutterbuck-James AL, Glover MJ, et al. Meta-analysis of randomised controlled trials of oral mandibular advancement devices and continuous positive airway pressure for obstructive sleep apnoea-hypopnoea. *Sleep Med Rev*. 2016;27:108-124.
  48. Gagnadoux F, Pépin J-L, Vielle B, et al. Impact of mandibular advancement therapy on endothelial function in severe obstructive sleep apnea. *Am J Respir Crit Care Med*. 2017;195:1244-1252.
  49. Ramar K, Dort LC, Katz SG, et al. Clinical practice guideline for the treatment of obstructive sleep apnea and snoring with oral appliance therapy: an update for 2015. *J Clin Sleep Med*. 2015;11:773-827.
  50. Yoshida K. Effect of a prosthetic appliance for treatment of sleep apnea syndrome on masticatory and tongue muscle activity. *J Prosthet Dent*. 1998;79:537-544.

**How to cite this article:** Yoshida K. Pneumoparotid related to obstructive sleep apnea syndrome treated by oral appliance with anterior opening to reduce intraoral pressure. *Clin Case Rep*. 2022;10:e05816. doi:[10.1002/ccr3.5816](https://doi.org/10.1002/ccr3.5816)