



# Primary bronchial carcinoma associated with bone marrow metastasis and paraneoplastic monoclonal gammopathy in a cat

*Journal of Feline Medicine and Surgery*  
*Open Reports*  
 1–5

© The Author(s) 2016  
 Reprints and permissions:  
[sagepub.co.uk/journalsPermissions.nav](http://sagepub.co.uk/journalsPermissions.nav)  
 DOI: 10.1177/2055116916668200  
[jfmsopenreports.com](http://jfmsopenreports.com)

This paper was handled and processed by the European Editorial Office for publication in JFMS Open Reports



Mario Cervone<sup>1</sup> and Stéphanie Beurlet<sup>2</sup>

## Abstract

**Case summary** Herein we describe an unusual metastatic pattern and paraneoplastic manifestation of a bronchial carcinoma in a cat. An 8 year-old cat presented with a diminished appetite, dysphagia, weight loss, lethargy and coughing. Thoracic radiographs revealed a lung mass. Bronchial carcinoma was diagnosed on the basis of histology and was associated with a lymphoplasmocytic infiltration of the fibrovascular stroma. Biochemistry showed hyperproteinaemia. Serum protein electrophoresis showed a narrow spike in the gamma region. Bone marrow cytology revealed an infiltrate with numerous clustered epithelial cells. The cat was euthanased 2 months later because of anorexia and poor general condition.

**Relevance and novel information** To the best of our knowledge, this is the first clinical description of primary bronchial carcinoma associated with bone marrow metastases and paraneoplastic monoclonal gammopathy in a cat.

**Accepted:** 16 August 2016

## Introduction

A monoclonal gammopathy is identified by the presence of a narrow spike both in the beta ( $\beta$ ) region and gamma ( $\gamma$ ) region on serum protein electrophoresis. Clonal immunoglobulins are produced by a single B-lymphocyte clone, which yields an excessive amount of immunoglobulins or subunits thereof, such as kappa ( $\kappa$ ) or lambda ( $\lambda$ ) light chains and heavy chains.<sup>1</sup> Tumours support a complex microenvironment characterised by many immune cell populations, reflecting the capacity of the immune system to interact with tumour cells.<sup>2</sup> In human lung cancers, tumour-infiltrating lymphocytes (TILs) are positively correlated with a pathological complete response rate and increased patient survival.<sup>2,3</sup> TILs may be classed as tertiary lymphoid structures (TLS) recently identified in human solid-organ tumours, including lung-cell carcinomas.<sup>2,3</sup> Primary lung tumours are rare in cats and represent a sporadic geriatric disease with a mean age of onset of 12 years, an incidence of 2.2 per 100,000 cats<sup>4</sup> and an overall prevalence of less than 0.5%.<sup>5</sup> In cats, the most commonly recognised primary lung tumours are adenocarcinomas.<sup>6</sup>

We describe a case of primary bronchial carcinoma in a cat associated with bone marrow suppression and a paraneoplastic monoclonal gammopathy.

## Case description

An 8-year-old, female, neutered, domestic shorthair cat was admitted for appetite loss, dysphagia, weight loss, lethargy and coughing. Its body condition was 2/9 on the World Small Animal Veterinary Association score (Global Nutrition Committee). Clinical examination revealed dyspnoea and a non-productive cough. No other abnormalities were detected on physical examination.

<sup>1</sup>Small Animal Veterinary Clinic, Paris, France

<sup>2</sup>Laboratoire Vebio, Arceuil, France

### Corresponding author:

Mario Cervone DVM, Small Animal Veterinary Clinic, 17 Bd des Filles du Calvaire, Paris, 75003 France  
 Email: [mariocervone@live.it](mailto:mariocervone@live.it)



Creative Commons Non Commercial CC-BY-NC: This article is distributed under the terms of the Creative Commons

Attribution-NonCommercial 3.0 License (<http://www.creativecommons.org/licenses/by-nc/3.0/>) which permits non-commercial use, reproduction and distribution of the work without further permission provided the original work is attributed as specified on the SAGE and Open Access pages (<https://us.sagepub.com/en-us/nam/open-access-at-sage>).

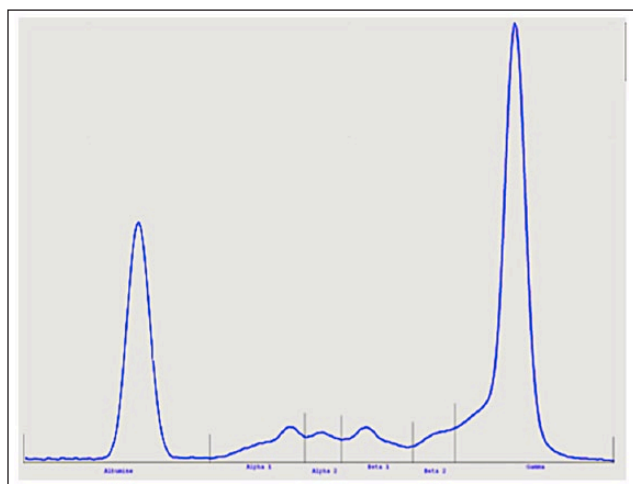
Complete blood count values were within reference intervals (RIs). Biochemistry revealed hyperproteinemia (10.4 g/dl; RI: 6–8 g/dl) and hypoalbuminaemia (2.2 g/dl; RI: 2.5–3.9 g/dl). The serum ionised calcium concentration was normal (1.21 mmol/l; RI: 1.18–1.34). The serum protein electrophoresis revealed a narrow spike in the  $\gamma$  region (5.6 g/dl; RI: 1.2–3.2 g/dl) (Figure 1). Serological testing for feline coronavirus antibodies based on indirect immunofluorescence was negative. Urinalysis (urine specific gravity, urinary dipstick and urinary sediment examination) revealed no abnormalities. Urine protein electrophoresis was not significant, with a urinary protein: creatinine ratio of 0.2. Three-view thoracic radiographs showed a solitary circumscribed mass associated with lobar consolidation in the right caudal lobe, as well as pleural effusion and megaesophagus (Figure 2a,b). Cytological examination of a lung

mass sample obtained by ultrasound-guided fine-needle aspirate biopsy was not conclusive, showing only a few cells exhibiting epithelial morphology. Ultrasound-guided tissue core biopsies were obtained under sedation using an 18 G Tru-Cut needle. Histopathology findings were consistent with bronchial carcinoma. The fibrovascular stroma of the epithelial proliferation appeared heavily infiltrated with lymphocytes and plasma cells (Figure 3). Abdominal ultrasonography showed no abnormalities. A bone marrow aspirate from the right wing of the ilium was obtained, under sedation, using a Mallarmé trocar. Bone marrow cytology indicated a normal myeloid:erythroid ratio associated with infiltration of numerous clustered epithelial cells. The epithelial cells showed a high N/C ratio, fine chromatin and a stripped cytoplasm with a foamy vacuolated background (Figure 4).

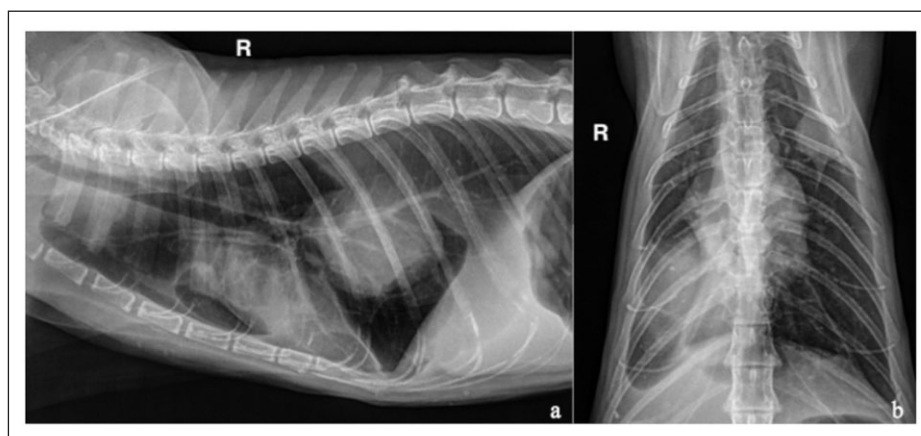
Based on these findings, a diagnosis was made of bronchial carcinoma associated with bone marrow metastases and paraneoplastic monoclonal gammopathy. Pneumonectomy and adjuvant chemotherapy was declined by the owner and palliative treatment with long-acting injectable glucocorticoid (Depo-Medrol; Zoetis, 1 mg/kg SC) was administered. The cat was euthanased 2 months later owing to anorexia and poor general condition.

## Discussion

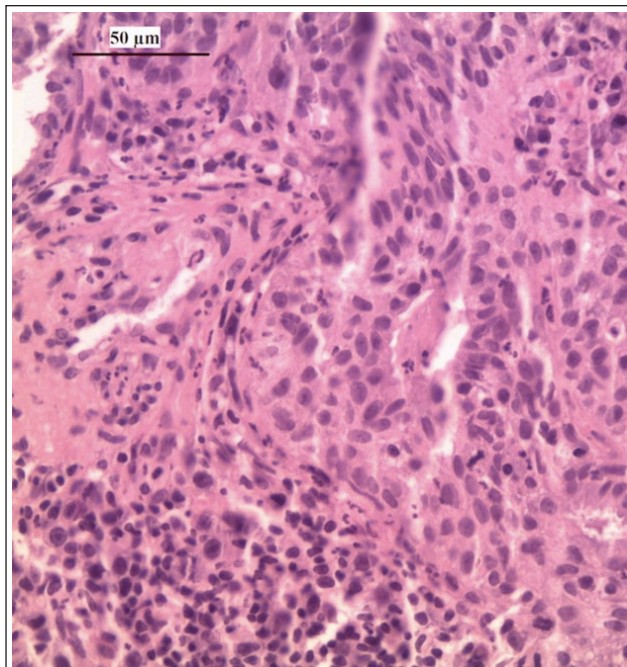
The primary purpose of this clinical case is to report bone marrow metastasis related to bronchial carcinoma in a cat. In a retrospective study of 39 spontaneous feline pulmonary carcinomas,<sup>7</sup> 31 cases (80%) were associated with metastasis. The most frequent sites of metastasis were the lung itself (intrapulmonary metastasis: 66.7%), the pleura (carcinomatosis: 38.5%), regional lymph nodes (33.3%), digits (18.0%)



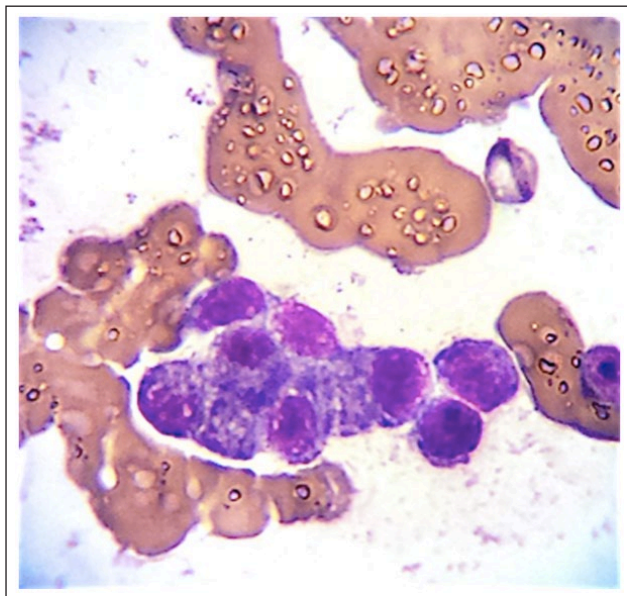
**Figure 1** Protein electrophoresis of serum indicating a narrow spike in the gamma ( $\gamma$ ) region



**Figure 2** Thoracic radiographs. (a) Right (R) lateral recumbent thoracic radiograph showing a solitary circumscribed mass associated with lobar consolidation and pleural effusion. Megaesophagus secondary to aerophagia is also present. (b) The same circumscribed mass in the right caudal lobe of the examined cat



**Figure 3** Formalin-fixed, paraffin-embedded tissue section of lung mass. The original architecture of the organ has disappeared and has been replaced by a cell proliferation consisting of tubular and tubular-alveolar structures, lined by a thick wall of cuboidal cells, with a clear cytoplasm and a hyperchromatic nucleus. These structures are separated by a fibrovascular stroma heavily infiltrated with lymphocytes and plasma cells. *Courtesy of LAPV Amboise, France*



**Figure 4** Bone marrow aspirate (stained with Diff-Quik). Cohesive cluster of pleomorphic neoplastic epithelial cells (X 100). The neoplastic cells have a high N/C ratio, fine chromatin, nucleoli and a stripped cytoplasm with a foamy vacuolated background

and distant visceral organs, including the liver, kidney and skeletal muscle.

In human medicine, lung cancers frequently metastasise to bone, with 22–60% of human patients showing bone marrow micrometastases.<sup>8</sup> Bone marrow micrometastases from canine and feline carcinomas have been demonstrated in one prospective study.<sup>9</sup> In 30 dogs and four cats with various types of carcinoma, bone marrow micrometastases were found in two dogs with advanced disease. As bone marrow cytology is not included in routine staging in veterinary patients with epithelial tumours,<sup>9</sup> the prevalence of carcinomatous metastases in bone marrow may be underestimated in veterinary medicine. In human patients, bone is among the most common sites of cancer metastases,<sup>10</sup> and disseminated tumour cells (DTCs) in the form of neoplastic cells in bone marrow have been reported as a negative prognostic indicator in bladder, colorectal (metastatic and non-metastatic) and prostate cancer, and in non-small cell lung cancer and small cell lung cancer in people.<sup>9</sup> Bone metastases may arise through interaction between tumour cells and bone marrow-derived mesenchymal cells, or they may result from the direct production by tumour cells of hormones and growth factors, such as parathyroid hormone-related peptides (PTHrP), granulocyte macrophage colony stimulatory factor, interleukin (IL)-1, IL-6 and macrophage inflammatory protein-1a.<sup>8,10</sup>

IL-6 is a pleiotropic cytokine, originally cloned as a B-cell stimulatory factor, that is overexpressed in response to injury, inflammation and infection.<sup>10</sup> The role of IL-6 in cancer is complex, and autocrine and paracrine mechanisms are involved. This cytokine has multiple effects on tumour progression; some are the result of its direct action on tumour cells while others are the result of its activity on normal cells in the tumour microenvironment, in particular osteoblasts, osteoclasts, endothelial cells and immune cells.<sup>10</sup> Many tumour cells produce large amounts of IL-6 and express its receptor, which allows them to respond to IL-6 stimulation in an autocrine manner.<sup>10</sup> In the case of lung tumours, IL-6 is able to stimulate tumour cell proliferation, migration and invasion of distant organs.<sup>8</sup>

In human medicine, several studies have shown that DTCs originate from primary tumours, including primary lung carcinomas, and that they can remain in a quiescent state in patients' bone marrow for years, particularly if localised in the haematopoietic stem cell (HSC) niche, which expresses adhesion molecules and secretes factors contributing to tumour cell dormancy. In this way, the HSC niche attracts, protects and induces dormancy of DTCs, which may be released from quiescence and grow as a consequence of a stimulatory microenvironment such as that found in bone.<sup>8</sup>



IL-6 has a direct stimulatory effect on the growth of tumour cells in bone marrow through the activation of several signalling pathways. It stimulates tumour cell proliferation and it may induce bone resorption or formation, depending on the interaction with other factors such as PTHrP and IL-1.<sup>8,10</sup> Thus, DTCs may lie dormant in bone marrow for long periods before being activated to form metastases.<sup>8</sup>

Whereas cytological evaluation of bone marrow in our cat was performed in order to investigate monoclonal gammopathy, the evidence of disseminated carcinomatous cells suggests that bone marrow evaluation should be considered during the staging of cats with carcinoma, particularly given the paucity of data regarding metastasis of epithelial tumours to bone marrow in feline patients. Indeed, despite complete surgical resection, treatment failure frequently occurs owing to undiagnosed metastasis of epithelial tumours at an early stage of the disease.<sup>9</sup> Standard staging of epithelial cancer in human patients is currently performed by bone marrow evaluation, using routine cytology, immunocytochemistry with anti-cytokeratin antibodies and molecular techniques involving reverse transcriptase PCR.<sup>8</sup> In veterinary medicine, while routine cytology remains the standard method for investigation of bone marrow micrometastases in cats, cell-block cytology has also been described,<sup>9</sup> and this approach allows analysis using immunocytochemistry, which may be helpful for prognosis and treatment recommendations.

The second aim of this clinical case is to report monoclonal gammopathy associated with bronchial carcinoma in a cat. Recognised immunoglobulin-producing tumours in cats include multiple myeloma, extramedullary plasmacytoma and lymphoma.<sup>11</sup> Non-neoplastic diseases, such as feline infectious peritonitis, ehrlichiosis, anaplasmosis, leishmaniosis, amyloidosis and lymphoplasmacytic stomatitis, have also occasionally been reported in cats in association with monoclonal gammopathy.<sup>11</sup> In dogs, monoclonal gammopathy is also associated with Waldenström macroglobulinaemia, chronic lymphocytic leukaemia, plasmacytic leukaemia and acute lymphoblastic leukaemia.<sup>12,13</sup> Furthermore, monoclonal gammopathy in dogs has been related to various infectious and inflammatory conditions, including chronic pyodermitis and plasmacytic gastroenterocolitis.<sup>1</sup> Finally, in the absence of known causes of gammopathy in dogs, a diagnosis of monoclonal gammopathy of undetermined significance should also to be considered. However, this disease is rare in veterinary medicine, with only two reported cases.<sup>14,15</sup>

In our cat, while a diagnosis of a concomitant infectious disease was not completely ruled out, these differential diagnoses were not very plausible. A retrospective study of SPE in 155 cats reported the presence of a narrow monoclonal peak for  $\gamma$  globulins associated with

pulmonary carcinoma in one cat.<sup>11</sup> In human patients, a narrow band is occasionally detected on SPE in association with malignant neoplasms of epithelial cell origin,<sup>16</sup> and high serum globulin values are statistically correlated with better median survival in small cell lung cancer.<sup>17</sup> Our case resembles a human case reported in 1967 in which a man with bronchogenic carcinoma and negative for Bence Jones proteinuria had a narrow peak in the  $\gamma$  globulin zone.<sup>16</sup> The pathophysiological origin of this monoclonal gammopathy could be an antibody response to tumour antigens mounted by plasma cell infiltrate, as classically described in the stroma of slow-growing tumours. Alternatively, it could be the result of a stimulated B-cell clone that has escaped normal control mechanisms.<sup>18</sup>

Histological examination of the pulmonary mass in this case revealed the presence of TILs in the stroma of the tissue forming TLS. The histological appearance closely resembled B-cell organisation described in human non-small cell lung carcinomas.<sup>2</sup> TLS are ectopic lymph node-like structures characterised by lymphoid aggregates with high endothelial venules.<sup>19</sup> Tumour-infiltrating B cells may organise into functional lymphoid structures as a consequence of B-cell activation. Furthermore, *ex vivo* tumour-infiltrating B-cell cultures may also be capable of producing high levels of IgG and IgA,<sup>2</sup> and raised IgG has been reported in 77% of non-lymphoproliferative cancers in human patients.<sup>20</sup> While the qualitative analysis of immunoglobulins (IgA, IgG, IgM, IgD) and their  $\kappa$  and  $\lambda$  subunits by immunofixation of serum in agar gel was not performed, the presence of a narrow spike in the  $\gamma$  region on SPE is suggestive of monoclonal immunoglobulin production, particularly of IgG.<sup>11</sup> Thus, we suspect that immunoglobulin secretion by B-cell TILs generated the observed paraneoplastic monoclonal gammopathy.

Interestingly, IL-6 is also a B-cell stimulatory factor.<sup>21</sup> It plays a key role in B-cell differentiation and acts upon activated and proliferating B cells.<sup>22</sup> We thus hypothesise that IL-6 may have played a dual role in the cat we examined: first by supporting the dissemination of micrometastases in bone marrow and, second, by participating in the loop maintenance of B-cell clone activation, resulting in the production of monoclonal immunoglobulins. However, the serum concentration of IL-6 was not measured in our cat and its involvement in tumour progression was consequently not confirmed.

## Conclusions

We report a case of primary bronchial carcinoma associated with bone marrow micrometastasis and monoclonal gammopathy in a cat. To the best of our knowledge, this is the first report of this metastatic pattern and paraneoplastic manifestation of feline bronchial carcinoma.

**Acknowledgements** We would like to thank LAPV-Amboise (France) for their assistance with the histology evaluations, and Dr Edouard Reyes-Gomez (Veterinary School of Maison-Alfort, France) for his assistance in the bone marrow cytology evaluations.

**Funding** The authors received no financial support for the research, authorship, and/or publication of this article.

**Conflict of interest** The authors declared no potential conflicts of interest with respect to the research, authorship, and/or publication of this article.

## References

- Willard MD and Tvedten H. **Immunologic and plasma protein disorders**. In: Willard MD and Tvedten H (eds). *Small animal clinical diagnosis by laboratory methods*. 4th ed. St Louis, MO: Elsevier, 2004, pp 290–305.
- Germain C, Gnjjatic S, Tamzalit F, et al. **Presence of B cells in tertiary lymphoid structures is associated with a protective immunity in patients with lung cancer**. *Am J Respir Crit Care Med* 2014; 189: 832–844.
- Goc J, Fridman WH, Sautès-Fridman C, et al. **Characteristics of tertiary lymphoid structures in primary cancers**. *Oncoimmunology* 2013; 2: e26836.
- Barr F, Gruffydd-Jones TJ, Brown PJ, et al. **Primary lung tumours in the cat**. *J Small Anim Pract* 1987; 28: 1115–1125.
- Morris J and Dobson J. **Respiratory tract**. In: Morris J and Dobson J (eds). *Small animal oncology*. 1st ed. Oxford: Wiley-Blackwell, 2001, pp 144–153.
- Moulton JE, von Tscharnner C and Schneider R. **Classification of lung carcinomas in the dog and cat**. *Vet Pathol* 1981; 18: 513–528.
- D'Costa S, Yoon BI, Kim DY, et al. **Morphological and molecular analysis of 39 spontaneous feline pulmonary carcinomas**. *Vet Pathol* 2012; 49: 971–978.
- Roato I. **Bone metastases: when and how lung cancer interacts with bone**. *World J Clin Oncol* 2014; 5: 149–155.
- Taylor BE, Leibman NF, Luong R, et al. **Detection of carcinoma micrometastases in bone marrow of dogs and cats using conventional and cell block cytology**. *Vet Clin Pathol* 2013; 42: 85–91.
- Ara T and DeClerk YA. **Interleukin-6 in bone metastasis and cancer progression**. *Eur J Cancer* 2010; 46: 1223–1231.
- Taylor SS, Tappin SW, Dodkin SJ, et al. **Serum protein electrophoresis in 155 cats**. *J Feline Med Surg* 2010; 12: 643–653.
- Giraudel JM, Pages JP and Guelfi JF. **Monoclonal gammopathies in the dog: a retrospective study of 18 cases (1986–1999) and literature review**. *J Am Anim Hosp Assoc* 2002; 38: 135–147.
- Fujino Y, Sawamura S, Kurakawa N, et al. **Treatment of chronic lymphocytic leukaemia in three dogs with melphalan and prednisolone**. *J Small Anim Pract* 2004; 45: 298–303.
- Dewhirst MW, Stamp GL and Hurvitz AI. **Idiopathic monoclonal (IgA) gammopathy in a dog**. *J Am Vet Med Assoc* 1977; 170: 1313–1316.
- Hoening M and O'Brien JA. **A benign hypergammaglobulinemia mimicking plasma cell myeloma**. *J Am Anim Hosp Assoc* 1988; 24: 688–690.
- Causey JQ. **IgG paraproteinemia associated with bronchogenic carcinoma**. *Arch Intern Med* 1967; 119: 407–410.
- Mohan A, Goyal A, Singh P, et al. **Survival in small cell lung cancer in India: prognostic utility of clinical features, laboratory parameters and response to treatment**. *Indian J Cancer* 2006; 43: 67–74.
- Michaux JL and Heremans JF. **Thirty cases of monoclonal immunoglobulin disorders other than myeloma or macroglobulinemia. A classification of diseases associated with the production of monoclonal-type immunoglobulins**. *Am J Med* 1969; 46: 562–579.
- Lin H, Balic M, Zheng S, et al. **Disseminated and circulating tumor cells: role in effective cancer management**. *Crit Rev Oncol Hematol* 2011; 77: 1–11.
- Fine JM and Marneux M. **Données récentes sur les gammopathies monoclonales**. *Re Fr Transfus Immunohematol* 1985; 6: 591–600.
- Lee HJ, Park IA, Song IH, et al. **Tertiary lymphoid structures: prognostic significance and relationship with tumor-infiltrating lymphocytes in triple-negative breast cancer**. *J Clin Pathol* 2016; 69: 422–430.
- Hirano T. **Interleukin 6 (IL-6) and its receptor: their role in plasma cell neoplasias**. *Int J Cell Cloning* 1991; 9: 166–184.