


PTEN Is Associated With Worse Local Control in Early Stage Supraglottic Laryngeal Cancer Treated With Radiotherapy

Leonie Bruine de Bruin, MD ; Jan E. Wachtters, MD; Michiel L. Schrijvers, MD, PhD;
Lorian Slagter-Menkema, BSc; Mirjam F. Mastik, BSc; Johannes A. Langendijk, MD, PhD;
Jacqueline E. van der Wal, MD, PhD[‡]; Ed Schuurin, PhD[‡]; Bernard F. A. M. van der Laan, MD, PhD[†]

Objectives: The aim of this study was to establish the prognostic value of the epidermal growth factor receptor (EGFR) and phosphatase and tensin homolog deleted on chromosome 10 (PTEN) expression on local control in patients with early stage supraglottic laryngeal squamous cell carcinoma (LSCC) treated with radiotherapy only.

Study design: Retrospective cohort study.

Methods: Immunohistochemical staining for EGFR and PTEN was performed on pretreatment biopsies of a selected well-defined homogeneous group of 52 patients with T1–T2 supraglottic LSCC treated with radiotherapy between 1990 and 2008. Kaplan–Meier analysis and univariate and multivariate Cox Regression analyses were performed to correlate clinical data and expression levels of EGFR and PTEN with local control.

Results: Kaplan–Meier survival analysis and Cox Regression analysis showed a significant association between PTEN expression and local control (hazard ratio [HR] = 3.26, 95% confidence interval [CI] = 1.14–9.33, $P = .027$) and between lymph node status and local control (HR = 3.60, 95% CI = 1.26–10.31, $P = .017$). Both were independent prognostic factors in a multivariate analysis (HR = 3.28, 95% CI = 1.14–9.39, $P = .027$ and HR = 3.62, 95% CI = 1.26–10.37, $P = .017$, respectively). There was no significant association between EGFR expression and local control (HR = 1.32, 95% CI = 1.17–10.14, $P = .79$).

Conclusion: This study showed an association between both high PTEN expression and the presence of lymph node metastasis and deteriorated local control in early stage supraglottic LSCC treated with radiotherapy.

Key Words: EGFR, PTEN, laryngeal squamous cell carcinoma, radiotherapy, local control.

Level of Evidence: NA

INTRODUCTION

Most early stage (T1–T2) laryngeal squamous cell carcinomas (LSCC) are treated with radiotherapy only. The 5-year local control rates after radiotherapy vary between 43%–95% and 41%–58% for glottic and supraglottic T1–T2 LSCC, respectively.^{1,2} Currently, besides sublocation and stage of the primary tumor, no suitable markers are available for predicting prognosis. Cell biological markers may be helpful to select patients who may benefit from additional treatment and identify new potential targets for therapy.³

This is an open access article under the terms of the Creative Commons Attribution-NonCommercial-NoDerivs License, which permits use and distribution in any medium, provided the original work is properly cited, the use is non-commercial and no modifications or adaptations are made.

From the Department of Otorhinolaryngology/Head and Neck Surgery (L.B.B., J.E.W., M.L.S., L.S.-M., B.F.A.M.L.), Department of Pathology and Medical Biology (L.S.-M., M.F.M., J.E.W., E.S.), and Department of Radiation Oncology (J.A.L.), University Medical Center Groningen, University of Groningen, Groningen, The Netherlands; and the Graduate School of Medical Sciences (Groningen University Institute for Drug Exploration) (L.B.B., J.E.W., M.L.S., L.S.-M., M.F.M., J.A.L., E.S., B.F.A.M.L.), University of Groningen, Groningen, The Netherlands

The authors have no funding, financial relationships, or conflicts of interest to disclose.

[†]Joint senior authorship.

[‡]Present address: Department of Pathology, The Netherlands Cancer Institute/Antoni van Leeuwenhoek, Amsterdam, The Netherlands.

Send correspondence to Ed Schuurin, Department of Pathology and Medical Biology, University Medical Center Groningen, University of Groningen, P.O. Box 30.001, 9700 RB Groningen, The Netherlands. Email: e.schuuring@umcg.nl

DOI: 10.1002/liv.2.272

In cancer, activation of signaling pathways, including the PI3K/AKT antiapoptotic and proliferation pathway, could contribute to tumorigenesis and hence a worse prognosis.^{4–6} The PI3K/AKT pathway can be triggered by activation of the epidermal growth factor receptor (EGFR), a transmembrane glycoprotein consisting of an extracellular ligand binding domain, a transmembrane region, and an intracellular tyrosine kinase domain. Upon binding of the specific ligand, phosphorylation of the intracellular tyrosine kinase occurs, activating the PI3K/AKT pathway.^{4,7} More than 80% of the head and neck squamous cell carcinomas (HNSCC) show EGFR overexpression.⁸ It has been suggested that EGFR plays an important role in response to radiotherapy, resulting in decreased local control.^{9–12} The last decade EGFR has become an important target in cancer therapy with the use of cetuximab, an anti-EGFR antibody.⁴ In HNSCC, the use of cetuximab is approved by the FDA in combination with radiotherapy for patients with locally advanced non-metastatic HNSCC in case chemoradiation is not feasible.¹³ Unfortunately, EGFR expression does not appear to be predictive for response to EGFR inhibitors.¹⁴

Another mechanism for PI3K/AKT pathway activation is the loss of phosphatase and tensin homolog deleted on chromosome 10 (PTEN), a tumor suppressor gene which opposes PI3K/AKT activation.^{5,6} PTEN is the second most mutated tumor suppressor gene after p53 and mutations in PTEN are found in a variety of primary tumors including HNSCC,^{7,15–18} while germline mutations in PTEN

cause Cowden syndrome, characterized by hamartomas and predisposition of breast and thyroid tumors.^{5,6} Besides the role of PTEN in tumorigenesis as an antagonist in the PI3K/AKT pathway, PTEN has also been associated with genome stability including DNA double strand break (DSB) repair by regulating the protein RAD51.^{15,19,20} Theoretically, tumors with loss of function of PTEN are less able to repair damage caused by radiotherapy. Furthermore, effect of radiotherapy is based on the high proliferation rate of tumors in relation to normal tissue. Consistent with this, we previously found overexpression of PTEN was associated with increased radioresistance in a cohort of HNSCC patients postoperatively treated with radiotherapy.¹⁹ The present study was primarily designed to evaluate this association and to establish the prognostic value of EGFR and PTEN expression on local control in an independent well-documented homogeneous series of early stage supraglottic LSCCs treated with radiotherapy only. We also evaluated whether other clinicopathological characteristics were associated with local control.

MATERIALS AND METHODS

Patients

The study population of the present study was composed of a selected well-defined homogenous group of patients with stage T1–T2 histologically confirmed squamous cell carcinoma of the supraglottic larynx treated with radiotherapy with curative intent. This study was restricted to this cohort of supraglottic tumors since previous studies showed differences in biological behavior between glottic and supraglottic tumors.²¹ The same cohort of patients was described in detail previously.^{21,22} Between 1990 and 2008, 1,286 patients were diagnosed with and/or treated for a laryngeal malignancy in our institute. Of all patients demographic and clinicopathological data such as gender, age, T-status, and N-status were retrospectively collected by reviewing the patient charts. The inclusion criteria for this study were 1) histologically proven squamous cell carcinoma; 2) localized in the supraglottic larynx; 3) staged cT1 and cT2; 4) with no evidence for distant metastasis (cM0); 5) were curatively treated with radiotherapy alone; and 6) received no other previous or concurrent treatment modalities. In total, 247 patients with T1–T2 LSCC were retrieved in our database. Because of second primary tumors or previous chemo- and/or radiotherapy, 10 patients were excluded. From this, 237 patients formalin-fixed, paraffin-embedded pretreatment biopsies taken at our institute were collected and revised by an experienced pathologist. Tissue specimens with sufficient neoplastic cells for immunohistochemical staining were available from 141 patients of which 52 were supraglottic tumors. All data from the 52 patients considered appropriate for immunohistochemistry after the exclusionary process were retrieved and collected in an anonymous database. All patients gave approval to use tissue samples for research.

Treatment

All patients were treated with primary radiotherapy as reported previously.^{21,22} In short, in stage T1 tumors, a total dose of 66 Gy, using 2 Gy fractions, five times weekly was given. Stage T2 tumors were generally treated with six fractions weekly, to a total dose of 70 Gy within 6 weeks. In the case of elective radiotherapy to the neck nodes, a total dose of 46 Gy was given to the primary planning target volume, with an additional boost of 70 Gy to the primary tumor and pathologic lymph nodes. In all patients, a planning-computed tomography scan was made in supine position. The target volumes were

delineated as described in previous reports.²³ All patients were treated with 3D-conformal radiotherapy. After completion of treatment, patients were followed at the outpatient clinic for 5 years.

Immunohistochemistry

EGFR and PTEN protein expression was respectively detected using Novocastra monoclonal antibody clone 113 against EGFR (Leica Biosystems, Newcastle, United Kingdom; Cat# NCL-L-EGFR, RRID:AB_563696) and a monoclonal antibody clone 6H2.1 against PTEN (Cascade BioScience, Winchester, United States; Cat# ABM-2052, RRID:AB_2335636). Immunostaining was performed on 4 µm paraffin sections. Antigen retrieval was achieved by heating in a microwave in preheated Tris-HCL buffer (EGFR) and citrate buffer (PTEN). Endogenous peroxidase was blocked by incubation with 0.3% hydrogen peroxidase for 30 minutes.

Slides were stained for 1 hour with the antibody against EGFR (1:100) and PTEN (1:50). Secondary, rabbit anti-mouse antibody was diluted 1:100 in 1% bovine serum albumin in phosphate buffered saline complemented with 1% human AB serum and applied for 30 minutes at room temperature. Tertiary goat anti-rabbit antibody was diluted 1:100 and applied for 30 minutes at room temperature. Staining was visualized with 3,3'-diaminobenzidine tetrahydrochloride and counterstained with hematoxylin.

Evaluation of Immunostaining

Scoring was performed by two independent teams without knowledge of clinical data. The discordant cases were reviewed and scores were reassigned on consensus of opinion. For both antibodies, staining intensity was semi-quantitatively scored as negative (–), weak positive (+/–), positive (+), and strong positive (++) for PTEN, the percentage of positive cells was scored as well. For statistical analysis, any positive EGFR staining above background was considered as high (+/–, +, and ++).¹⁹ For PTEN, tumors were considered high in case of >7.5% positive (+ or ++) cytoplasmic staining.¹⁹

Statistical Analysis

Statistical analysis was performed with IBM SPSS Statistics 23 for Windows. Follow-up time was calculated from the day of diagnosis until the date of the last follow-up. Local recurrence was defined as tumor recurrence at the primary tumor site within 5 years, and was calculated from the date of diagnosis until the day of local recurrence or lost to follow-up. Relations (hazard ratio [HR] and 95% confidence interval [CI]) between recurrence and immunostaining and other clinicopathological characteristics were calculated using univariate Cox proportional hazard analysis and Kaplan–Meier analysis. For multivariate Cox regression, only the variables that appeared statistically significant in univariate analysis were included. *P* values of <.05 were considered statistically significant.

RESULTS

Patient and Immunohistochemical Characteristics

The population showed a preference for the male sex, T2, and lymph node negative tumors (for details, see Table I). Almost all tumors showed high expression of EGFR (92%). Thirteen (25%) patients had a high expression of PTEN with immunohistochemistry. In slides with high expression for PTEN, the median percentage of positive neoplastic cells was 28% (range: 10–85).

Characteristics	No. of Patients (%)
Age—years	
Median (range)	63 (33–95)
Gender	
Female	11 (21.2)
Male	41 (78.8)
cT-stadium	
T1	15 (28.8)
T2	37 (71.2)
cN-stadium	
N0	39 (75.0)
N+	13 (25.0)
EGFR expression	
Low	4 (7.7)
High	48 (92.3)
PTEN expression	
Low	39 (75.0)
High	13 (25.0)

EGFR = epidermal growth factor receptor; N = node; PTEN = phosphatase and tensin homolog deleted on chromosome 10; T = tumor.

No Relation between EGFR Expression and Local Control

Fourteen patients (26.9%) developed a local recurrence after radiotherapy. Kaplan–Meier and Cox regression

Characteristics	No. of Patients with Local Recurrence (%)	Univariate HR (95% CI)	P
Age—years			
<65	8/32 (25.0)	1	
≥65	6/20 (30.0)	1.51 (0.52–4.36)	.45
Gender			
Female	2/11 (18.2)	1	
Male	12/41 (29.3)	1.81 (0.40–8.09)	.44
cT-stadium			
T1	3/15 (20.0)	1	
T2	11/37 (29.7)	1.63 (0.46–5.86)	.45
cN-stadium			
N0	7/39 (17.9)	1	
N+	7/13 (53.8)	3.60 (1.26–10.31)	.017*
EGFR			
Low	1/4 (25.0)	1.32 (1.17–10.14)	.79
High	13/48 (27.1)	1	
PTEN			
Low	7/39 (17.9)	1	
High	7/13 (53.8)	3.26 (1.14–9.33)	.027*

*Signifies statistically significant relation.

CI = confidence interval; EGFR = epidermal growth factor receptor; HR = hazard ratio; N = node; PTEN = phosphatase and tensin homolog deleted on chromosome 10; T = tumor.

analysis did not show a significant relation between EGFR expression and local control in our series of 52 supraglottic laryngeal carcinomas (HR = 1.32, 95% CI = 1.17–10.14, $P = .79$) (Table II and Fig. 1A).

PTEN Overexpression and Lymph Node Status Are Associated with Local Control

In the population with high PTEN expression (n = 13), seven patients (54%) developed a local recurrence, in contrast to 18% in patients with low PTEN expression. Cox regression revealed a significant association between high PTEN expression and local control (HR = 3.26, 95% CI = 1.14–9.33, $P = .027$) (Table II and Fig. 1B).

In the population with positive lymph node status (N+), 7 out of 13 patients (54%) had a local recurrence. In the population with no lymph node metastasis, this percentage was 18%. Cox regression revealed a significant association between N+ and local control (HR = 3.60, 95% CI = 1.26–10.31, $P = .017$) (Table II and Fig. 1C).

Multivariate Cox regression showed that high PTEN expression and lymph node status were independent prognostic factors in a multivariate analysis (HR = 3.28, 95% CI = 1.14–9.39, $P = .027$ and HR = 3.62, 95% CI = 1.26–10.37, $P = .017$, respectively) (Table III).

DISCUSSION

Previously, we reported that overexpression of PTEN was associated with increased radioresistance in a cohort of HNSCC patients postoperatively treated with radiotherapy.¹⁹ In this study, we evaluated the prognostic value of PTEN expression on local control in an independent well-documented homogeneous series of early stage supraglottic LSCCs all treated curatively with radiotherapy only. In this homogeneous cohort of 52 patients, a significant association between PTEN expression and local control was observed.

The last decade the PI3K/AKT signaling pathway has become an important target in cancer therapy including HNSCC with the use of cetuximab, an anti-EGFR antibody applied in advanced nonmetastatic HNSCC in combination with radiotherapy or as a single agent in patients who have had prior platinum-based therapy.¹³ EGFR status as a specific predictive marker for response to EGFR inhibitors is controversial.¹⁴ Numerous studies reported on the prognostic value of immunohistochemical EGFR expression in different tumor types.^{10,19,24} In our homogeneous cohort consisting of early stage supraglottic LSCCs treated with radiotherapy alone, no significant relationship between EGFR expression and local control was found. Conflicting results have been published earlier concerning EGFR overexpression and association with local control in HNSCC. For instance, Ang et al reported worse local control and overall survival in a group of 155 advanced HNSCCs treated with radiation therapy overexpressing EGFR.¹⁰ In contrast, Eriksen et al failed to show a significant relationship between EGFR overexpression and local control in a group of 336 HNSCCs treated with conventional or accelerated radiation therapy.²⁴ There are different reasons for these conflicting

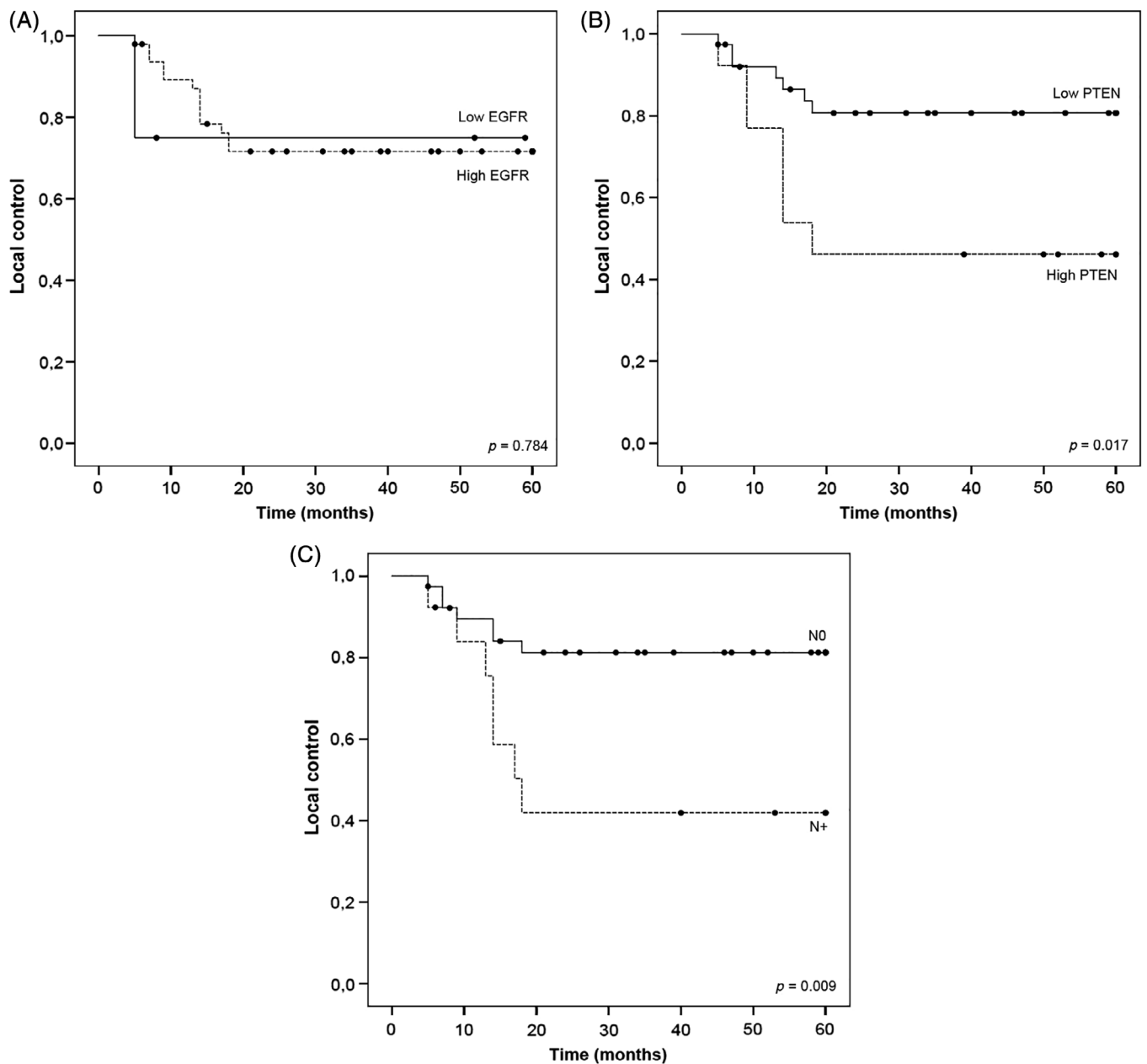


Fig. 1. Kaplan-Meier curves for the relation of EGFR expression (A), PTEN expression (B), and lymph node (N) status (C) with local control. EGFR = epidermal growth factor receptor; PTEN = phosphatase and tensin homolog deleted on chromosome 10.

results. First, the prognostic significance of EGFR has been investigated in heterogeneous HNSCC populations treated with different treatment modalities. Second, there is no general consensus regarding the staining protocols

TABLE III.
Results of Multivariate Cox Regression Analysis for Local Control.

Characteristics	Multivariate HR (95% CI)	<i>P</i>
N+	3.62 (1.26–10.37)	0.017*
High PTEN	3.28 (1.14–9.39)	0.027*

*Signifies statistically significant relation.
CI = confidence interval; HR = hazard ratio; N = node; PTEN = phosphatase and tensin homolog deleted on chromosome 10.

and scoring methods of EGFR.¹⁹ The interpretation of the results in our study is difficult since there were only four cases with low EGFR expression. Compared to other studies on EGFR expression in HNSCC, we found a high percentage of high EGFR cases (92%) versus 53%–88% in HNSCC described in literature.^{19,24–28} There is only one other study concerning EGFR expression in supraglottic laryngeal carcinomas, showing high EGFR expression in 83% and 70% of T1 and T2 tumors, respectively.²⁵ However, they used a different primary antibody and scoring criteria, which makes it difficult to compare. We also performed EGFR immunostaining on a well-defined series of early stage (T1–T2) glottic LSCCs treated with radiotherapy only and found significantly more tumors in the

supraglottic group with high EGFR expression compared to the glottic group (92% vs. 53%) (Wachters et al, unpublished data). This suggests also an association between EGFR expression levels and different tumor locations and supports our decision to restrict our analysis to a homogeneous series of supraglottic LSCCs only.

Besides activation of EGFR, another mechanism for PI3/AKT pathway activation is the loss of PTEN expression. Previously, PTEN expression has been linked to therapeutic outcome in HNSCC.^{19,29–31} In this study, we showed a significant relation between high PTEN expression and worse local control. Low PTEN expression by immunostaining was observed in 75% of patients similar as we observed earlier in HNSCC.¹⁹ Lower percentages of 33%–56% using the same antibody were reported as well,^{32,33} in which supraglottic LSCC appeared to have less often loss of expression than glottic LSCC.³³ This is possibly explained by the more often raised disease of supraglottic LSCC.³³ This percentages are corresponding to mutations and loss of heterozygosity of PTEN gene found in 23%–33% and 10%–40% of HNSCC, respectively.^{16–18} However, a study in non-small cell lung cancer showed that neither methylation nor loss of heterozygosity was a significant predictor of PTEN protein expression with immunohistochemistry.³⁴ Among several types of commercially available PTEN monoclonal antibodies, PTEN monoclonal antibody clone 6.H2.1 was the only one associated with PTEN molecular alterations.³⁵

The results of this study confirmed previously found relation between high expression of PTEN and worse local control in a series of squamous cell carcinomas of the larynx, hypopharynx, oropharynx, and oral cavity treated with primary surgery and postoperative radiotherapy.¹⁹ The explanation for this association was that PTEN functions in DSB repair.²⁰ Cells have evolved several protective responses to counteract the harmful effects of DNA-damage including homologous recombination and nonhomologous end-joining for DSB. Homologous recombination ensures accurate DSB-repair mediated through the so called RAD52 group of proteins which includes RAD51. RAD51 is regulated by PTEN.^{15,19,20} We speculate that tumors with low function of PTEN are less able to repair damage caused by radiotherapy. Other studies on PTEN expression in relation with prognosis in HNSCC have linked, on the contrary, low PTEN to worse prognosis of disease in both surgery and radiotherapy.^{29–31} An explanation for this observation is the counteracting function of PTEN on the PI3K/AKT anti-apoptotic and proliferation pathway that could contribute to tumorigenesis and worse prognosis.^{5,6} Positive lymph node status was associated with the development of local recurrence. This was an unexpected outcome because regional metastasis is not a known risk factor for developing local recurrence and suggests the higher aggressiveness of these tumors in general. It was not in relation with tumor size because there was no difference in outcome between T1 and T2 tumors. The relation of regional metastasis and deteriorated local control should be evaluated in larger series of early stage supraglottic LSCC.

This study was weakened by its small series of only 52 patients. On the other hand, the great strength of this study was the composition of a well-defined homogeneous

cohort consisting of supraglottic LSCCs treated with radiotherapy alone. The relevance to distinguish between supraglottic and glottic LSCC evaluating (prognostic) immunohistochemical expression of antibodies has become clear from previous studies.^{21,22,33,36} Although we performed EGFR immunostaining on a series of early stage glottic LSCC as well, we did not perform PTEN immunostaining on this glottic LSCC series. It was quite difficult to obtain a useful immunohistochemical visualization of PTEN on the supraglottic LSCC biopsies. Therefore, we decided not to sacrifice the mostly small biopsies from the glottic LSCC patients. One of the reasons for radioresistance in HNSCC is accelerated repopulation of tumor cells after exposure to ionizing radiation.^{9,24,25,37} One of the mechanisms contributing to this repopulation is activation of the EGFR/PI3K/AKT pathway. Binding of cetuximab to the EGF receptor leads to internalization and degradation of the antibody-receptor complex, down-regulating EGFR expression.^{9,38} In SCC cell lines, Bonner et al showed that the combination of cetuximab and radiation resulted in decreased cellular proliferation.³⁹ Bonner et al showed that among patients with stage III–IV HNSCC, the addition of cetuximab to radiotherapy resulted in a significant improvement of locoregional control and survival as compared to radiotherapy alone, without enhancing radiation-induced toxicity.^{40,41} Based on the results of this study, cetuximab is now increasingly used in combination with definitive radiotherapy in locally advanced disease in particular for patients in which concurrent chemoradiation is considered not feasible. So far, no studies have been published which compared concomitant cetuximab and radiotherapy in combination with EGFR levels in early stage laryngeal carcinoma.

This study showed a potential role in diagnostic and prognostic terms for PTEN immunohistochemical evaluation in supraglottic LSCC in which patients with supraglottic LSCC with a high PTEN immunohistochemical expression might benefit from altered radiotherapy schedules or additional PTEN inhibiting drugs. Because of the antagonize behavior of PTEN on the PI3/AKT pathway, most of the strategies to target PTEN are focused on PTEN-deficient cancers utilize inhibitors of kinases that lie at the level of PI3K/AKT pathway.⁴² Furthermore, due to the activation of the EGFR/PI3/AKT pathway, PTEN inactivation could theoretically lead to resistance to EGFR inhibitors. Frattini et al showed in a series of colorectal cancer patients that loss of PTEN expression by immunohistochemistry distinguished responder from nonresponder patients to cetuximab.⁴³ Studies in prostate cancer cells showed a comparable relation and PTEN reintroduction restored the cell response to cetuximab.⁴⁴ This supports the suggestion that supraglottic LSCC patients with high PTEN expression might benefit from adding cetuximab to radiotherapy.

CONCLUSION

This study confirmed earlier found association between high PTEN expression and local control in HNSCC. The worse local control found in cases with high PTEN expression might suggest the importance of PI3K-AKT independent functions of PTEN such as DNA-damage repair in radioresponse. PTEN status could have an additive value in

determining the prognosis of early stage supraglottic laryngeal carcinomas, next to the already used clinical factors as lymph node status. These patients might benefit from an alternated radiation schedule, drugs interfering with DNA-damage repair, or adding cetuximab.

BIBLIOGRAPHY

- Nix PA, Greenman J, Cawkwell L, Stafford N. Radioresistant laryngeal cancer: beyond the TNM stage. *Clin Otolaryngol Allied Sci* 2004;29(2):105–114.
- Hartl DM, Ferlito A, Brasnu DF, et al. Evidence-based review of treatment options for patients with glottic cancer. *Head Neck* 2011;33(11):1638–1648.
- Ow TJ, Pitts CE, Kabarriti R, Garg MK. Effective biomarkers and radiation treatment in head and neck cancer. *Arch Pathol Lab Med* 2015;139(11):1379–1388.
- Laurent-Puig P, Lievre A, Blons H. Mutations and response to epidermal growth factor receptor inhibitors. *Clin Cancer Res* 2009;15(4):1133–1139.
- Worby CA, Dixon JE. PTEN. *Annu Rev Biochem* 2014;83:641–669.
- Song MS, Salmena L, Pandolfi PP. The functions and regulation of the PTEN tumour suppressor. *Nat Rev Mol Cell Biol* 2012;13(5):283–296.
- Yokota T. Is biomarker research advancing in the era of personalized medicine for head and neck cancer? *Int J Clin Oncol* 2014;19(2):211–219.
- Grandis JR, Tweardy DJ. Elevated levels of transforming growth factor alpha and epidermal growth factor receptor messenger RNA are early markers of carcinogenesis in head and neck cancer. *Cancer Res* 1993;53(15):3579–3584.
- Zimmermann M, Zouhair A, Azria D, Ozsahin M. The epidermal growth factor receptor (EGFR) in head and neck cancer: its role and treatment implications. *Radiat Oncol* 2006;1:11.
- Ang KK, Berkey BA, Tu X, et al. Impact of epidermal growth factor receptor expression on survival and pattern of relapse in patients with advanced head and neck carcinoma. *Cancer Res* 2002;62(24):7350–7356.
- Chang AR, Wu HG, Park CI, Jun YK, Kim CW. Expression of epidermal growth factor receptor and cyclin D1 in pretreatment biopsies as a predictive factor of radiotherapy efficacy in early glottic cancer. *Head Neck* 2008;30(7):852–857.
- Hofman P, Butori C, Havet K, et al. Prognostic significance of cortactin levels in head and neck squamous cell carcinoma: comparison with epidermal growth factor receptor status. *Br J Cancer* 2008;98(5):956–964.
- Winquist E, Agbassi C, Meyers BM, Yoo J, KKW C, Head and Neck Disease Site Group. Systemic therapy in the curative treatment of head and neck squamous cell cancer: a systematic review. *J Otolaryngol Head Neck Surg* 2017;46(1):29.
- Mahipal A, Kothari N, Gupta S. Epidermal growth factor receptor inhibitors: coming of age. *Cancer Control* 2014;21(1):74–79.
- Liu W, Zhou Y, Reske SN, Shen C. PTEN mutation: many birds with one stone in tumorigenesis. *Anticancer Res* 2008;28(6A):3613–3619.
- Okami K, Wu L, Riggins G, et al. Analysis of PTEN/MMAC1 alterations in aerodigestive tract tumors. *Cancer Res* 1998;58(3):509–511.
- Poetsch M, Lorenz G, Kleist B. Detection of new PTEN/MMAC1 mutations in head and neck squamous cell carcinomas with loss of chromosome 10. *Cancer Genet Cytogenet* 2002;132(1):20–24.
- Shao X, Tandon R, Samara G, et al. Mutational analysis of the PTEN gene in head and neck squamous cell carcinoma. *Int J Cancer* 1998;77(5):684–688.
- Pattje WJ, Schuurings E, Mastik MF, et al. The phosphatase and tensin homologue deleted on chromosome 10 mediates radiosensitivity in head and neck cancer. *Br J Cancer* 2010;102(12):1778–1785.
- Shen WH, Balajee AS, Wang J, et al. Essential role for nuclear PTEN in maintaining chromosomal integrity. *Cell* 2007;128(1):157–170.
- Wachters JE, Schrijvers ML, Slagter-Menkema L, et al. Prognostic significance of HIF-1 α , CA-IX, and OPN in T1-T2 laryngeal carcinoma treated with radiotherapy. *Laryngoscope* 2013;123(9):2154–2160.
- Wachters JE, Schrijvers ML, Slagter-Menkema L, et al. Phosphorylated FADD is not prognostic for local control in T1-T2 supraglottic laryngeal carcinoma treated with radiotherapy. *Laryngoscope* 2017;127(9):E301–E307.
- Beetz I, Schilstra C, Burlage FR, et al. Development of NTCP models for head and neck cancer patients treated with three-dimensional conformal radiotherapy for xerostomia and sticky saliva: the role of dosimetric and clinical factors. *Radiother Oncol* 2012;105(1):86–93.
- Eriksen JG, Steiniche T, Askaa J, Alsner J, Overgaard J. The prognostic value of epidermal growth factor receptor is related to tumor differentiation and the overall treatment time of radiotherapy in squamous cell carcinomas of the head and neck. *Int J Radiat Oncol Biol Phys* 2004;58(2):561–566.
- Eriksen JG, Steiniche T, Overgaard J, Danish Head and Neck Cancer study group (DAHANCA). The role of epidermal growth factor receptor and E-cadherin for the outcome of reduction in the overall treatment time of radiotherapy of supraglottic larynx squamous cell carcinoma. *Acta Oncol* 2005;44(1):50–58.
- Bentzen SM, Atasoy BM, Daley FM, et al. Epidermal growth factor receptor expression in pretreatment biopsies from head and neck squamous cell carcinoma as a predictive factor for a benefit from accelerated radiation therapy in a randomized controlled trial. *J Clin Oncol* 2005;23(24):5560–5567.
- Fischer C, Zlobec I, Stockli E, et al. Is immunohistochemical epidermal growth factor receptor expression overestimated as a prognostic factor in head-neck squamous cell carcinoma? A retrospective analysis based on a tissue microarray of 365 carcinomas. *Hum Pathol* 2008;39(10):1527–1534.
- Smid EJ, Stoter TR, Bloemena E, et al. The importance of immunohistochemical expression of EGFR in squamous cell carcinoma of the oral cavity treated with surgery and postoperative radiotherapy. *Int J Radiat Oncol Biol Phys* 2006;65(5):1323–1329.
- Lee JI, Soria JC, Hassan KA, et al. Loss of PTEN expression as a prognostic marker for tongue cancer. *Arch Otolaryngol Head Neck Surg* 2001;127(12):1441–1445.
- Yang JQ, Liang Z, Wu M, Sun YM, Liu HX. Expression of p27 and PTEN and clinical characteristics in early laryngeal squamous cell carcinoma and their correlation with recurrence. *Int J Clin Exp Pathol* 2015;8(5):5715–5720.
- Snietura M, Jaworska M, Mlynarczyk-Liszka J, et al. PTEN as a prognostic and predictive marker in postoperative radiotherapy for squamous cell cancer of the head and neck. *PLoS One* 2012;7(3):e33396.
- Fury MG, Drobnjak M, Sima CS, et al. Tissue microarray evidence of association between p16 and phosphorylated eIF4E in tonsillar squamous cell carcinoma. *Head Neck* 2011;33(9):1340–1345.
- Mastrorikolis NS, Tsiambas E, Papadas TA, et al. Deregulation of PTEN expression in laryngeal squamous cell carcinoma based on tissue microarray digital analysis. *Anticancer Res* 2017;37:5521–5524.
- Marsit CJ, Zheng S, Aldape K, et al. PTEN expression in non-small-cell lung cancer: evaluating its relation to tumor characteristics, allelic loss, and epigenetic alteration. *Hum Pathol* 2005;36(7):768–776.
- Pallares J, Bussaglia E, Martinez-Guitarte JL, et al. Immunohistochemical analysis of PTEN in endometrial carcinoma: a tissue microarray study with a comparison of four commercial antibodies in correlation with molecular abnormalities. *Mod Pathol* 2005;18(5):719–727.
- Guney K, Ozbilim G, Derin AT, et al. Expression of PTEN protein in patients with laryngeal squamous cell carcinoma. *Auris Nasus Larynx* 2007;34:481–486.
- Baujart B, Bourhis J, Blanchard P, et al. Hyperfractionated or accelerated radiotherapy for head and neck cancer. *Cochrane Database Syst Rev* 2010;12:CD002026.
- Szabo B, Nelhubel GA, Karpati A, et al. Clinical significance of genetic alterations and expression of epidermal growth factor receptor (EGFR) in head and neck squamous cell carcinomas. *Oral Oncol* 2011;47(6):487–496.
- Bonner JA, Raisch KP, Trummell HQ, et al. Enhanced apoptosis with combination C225/radiation treatment serves as the impetus for clinical investigation in head and neck cancers. *J Clin Oncol* 2000;18(21 suppl):47S–53S.
- Bonner JA, Harari PM, Giral J, et al. Radiotherapy plus cetuximab for squamous-cell carcinoma of the head and neck. *N Engl J Med* 2006;354(6):567–578.
- Bonner JA, Harari PM, Giral J, et al. Radiotherapy plus cetuximab for locoregionally advanced head and neck cancer: 5-year survival data from a phase 3 randomised trial, and relation between cetuximab-induced rash and survival. *Lancet Oncol* 2010;11(1):21–28.
- Dillon LM, Miller TW. Therapeutic targeting of cancers with loss of PTEN function. *Curr Drug Targets* 2014;15:65–79.
- Fratini M, Saletti P, Romagnani E, et al. PTEN loss of expression predicts cetuximab efficacy in metastatic colorectal cancer patients. *Br J Cancer* 2007;97(8):1139–1145.
- Bouali S, Chretien AS, Ramacci C, Rouyer M, Becuwe P, Merlin JL. PTEN expression controls cellular response to cetuximab by mediating PI3K/AKT and RAS/RAF/MAPK downstream signaling in KRAS wild-type, hormone refractory prostate cancer cells. *Oncol Rep* 2009;21(3):731–735.