

## Mid-range outcomes in 64 consecutive cases of multilevel fusion for degenerative diseases of the lumbar spine

Marc Röllinghoff, Klaus Schlüter-Brust, Daniel Groos, Rolf Sobottke, Joern William-Patrick Michael, Peer Eysel, Karl Stefan Delank

Department of Orthopaedic and Trauma Surgery, University of Cologne, Germany

### Abstract

In the treatment of multilevel degenerative disorders of the lumbar spine, spondylodesis plays a controversial role. Most patients can be treated conservatively with success. Multilevel lumbar fusion with instrumentation is associated with severe complications like failed back surgery syndrome, implant failure, and adjacent segment disease (ASD). This retrospective study examines the records of 70 elderly patients with degenerative changes or instability of the lumbar spine treated between 2002 and 2007 with spondylodesis of more than two segments. Sixty-four patients were included; 5 patients had died and one patient was lost to follow-up. We evaluated complications, clinical/radiological outcomes, and success of fusion. Flexion-extension and standing X-rays in two planes, MRI, and/or CT scans were obtained pre-operatively. Patients were assessed clinically using the Oswestry disability index (ODI) and a Visual Analogue Scale (VAS). Surgery performed was dorsolateral fusion (46.9%) or dorsal fusion with anterior lumbar interbody fusion (ALIF; 53.1%). Additional decompression was carried out in 37.5% of patients. Mean follow-up was 29.4±5.4 months. Average patient age was 64.7±4.3 years. Clinical outcomes were not satisfactory for all patients. VAS scores improved from 8.6±1.3 to 5.6±3.0 pre- to post-operatively, without statistical significance. ODI was also not significantly improved (56.1±22.3 pre- and 45.1±26.4 post-operatively). Successful fusion, defined as adequate bone mass with trabeculation at the facets and transverse processes or in the intervertebral segments, did not correlate with good clinical outcomes. Thirty-five of 64 patients (54%) showed signs of pedicle screw loosening, especially of the screws at S1. However, only 7 of these 35 (20%) complained of corresponding back pain. Revision surgery was required in 24 of 64 patients (38%). Of these, indications were adjacent segment disease (16 cases), pedicle screw loosening (7 cases), and infection (one case). At follow-up of 29.4 months, patients with radiographic ASD

had worse ODI scores than patients without (54.7 vs. 36.6;  $P < 0.001$ ). Multilevel fusion for degenerative disease still has a high rate of complications, up to 50%. The problem of adjacent segment disease after fusion surgery has not yet been solved. This study underscores the need for strict indication guidelines to perform lumbar spine fusion of more than two levels.

### Introduction

The concept of transpedicular fixation of the lumbar spine is far from new.<sup>1</sup> Internal fixation devices using transpedicular screws have evolved rapidly over the past two to three decades. When considering operative treatment, multilevel degenerative diseases of the lumbar spine pose a significant problem regarding length of spondylodesis and considerations above the level of fusion.<sup>2,4</sup> Unfortunately, spinal fusion alters the normal biomechanics of the spine, and loss of motion at the fused levels is compensated for by increased motion at the remaining, non-fused segments.<sup>5</sup> All lumbar fusion techniques are associated with serious complications like adjacent segment disease (ASD), failed back surgery syndrome (FBSS), implant failure, and/or pseudarthrosis.<sup>6,9</sup> As a result, disc arthroplasty and dynamic stabilization techniques have evolved, with the hope that technology can prevent degeneration of adjacent segments.<sup>10</sup> The prevalence of ASD has been reported in more than 30%<sup>3,9,11</sup> of patients undergoing lumbar fusion. Predisposing patient factors commonly proposed for this include age, obesity, pre-existing degeneration of the adjacent discs, menopause, and sacral inclination.<sup>10,12,13</sup> Predisposing surgical factors include length of fusion, implant stiffness, radical decompression, loss of lumbar lordosis, and sagittal and coronal imbalance.<sup>14</sup> The number of lumbar spinal fusions performed has increased dramatically in recent years,<sup>15</sup> with clinical outcomes showing superior results.<sup>16,17</sup> However, few studies address the problem of unsatisfactory results with high complication rates.<sup>8,11,18,19</sup> Fritzell *et al.*<sup>8</sup> attempted to evaluate results as well as complications after multilevel fusion with mid-range follow-up, using clinical and radiographic assessments. The aim of the current study was to identify well-defined and validated criteria to examine patients undergoing multilevel fusion for degenerative spine disease, with special emphasis on serious complications. It underscores that indications for this surgical intervention should be limited.

Correspondence: Marc Röllinghoff, Department of Orthopaedic Surgery, University of Cologne, Joseph-Stelzmann Straße 9, 50924 Cologne, Germany. E-mail: marc.roellinghoff@gmx.de

Key words: lumbar spine, multilevel fusion, complication, degenerative disease, adjacent segment disease, implant loosening, topping off.

Received for publication: 19 November 2009.

Revision received: 18 December 2009.

Accepted for publication: 31 December 2009.

Conflict of interest: the authors report no conflicts of interest.

This work is licensed under a Creative Commons Attribution 3.0 License (by-nc 3.0).

©Copyright Röllinghoff *et al.*, 2010  
Licensee PAGEPress, Italy  
Orthopedic Reviews 2010; 2:e3  
doi:10.4081/or.2010.e3

### Materials and Methods

#### Patients

Between 2002 and 2007, 70 patients underwent multilevel fusion of at least three segments for degenerative lumbar spine disease. Sixty-four were included in our retrospective study (22 male, 42 female). Five patients died from circulatory collapse without requiring revision surgery, and one patient (1.4%) was lost to follow-up. Inclusion criteria for the study were: 1) multiple verifiable degenerative changes of the lumbar spine (Table 1); 2) low back pain (LBP) lasting longer than one year; 3) previous conservative treatment; and 4) dorsal spondylodesis of three or more segments.

#### Operative procedure

The indication for multilevel fusion was multiple verifiable degenerative changes of the lumbar spine. Spinal canal stenosis was determined by magnetic resonance imaging or computed tomography in combination with clinical examination. Instability of intervertebral segments was defined as sagittal translation of 5 mm or more.<sup>20</sup> The operation was performed by one of three senior spine surgery specialists. All patients were treated with a standard surgical procedure using the same transpedicular fixation device: the ART instrumentation system (Advanced Medical Technologies AG, Nonweiler, Germany). Thirty patients underwent dorsolateral spondylodesis with allogenic bone graft from a femoral head, 34 patients dorsal spondylodesis and anterior lumbar interbody fusion (ALIF), and 24 patients underwent additional decompression. All patients (n=64) were operated in the prone position, with the 24

**Table 1. Admission diagnoses of the patient population (n=64).**

Diagnosis	N
Spinal stenosis	18
Degenerative scoliosis	14
Degenerative instability	13
Osteochondrosis	11
Bechterew's disease	4
Spondylolisthesis	3
Collapsing Spine	1
Total	6

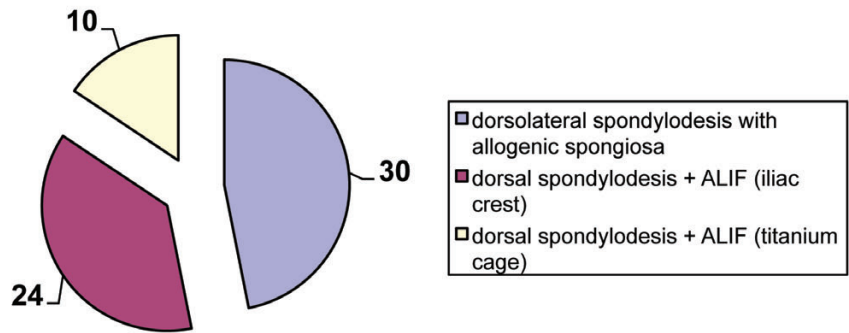
requiring decompression positioned prone with the hips in approximately 100° of flexion.<sup>21</sup> Standard surgical technique was categorized into three groups: 1) dorsolateral spondylodesis with pedicle screws plus rods with allogenic femoral head graft over decorticated facets and transverse processes at the level of fusion; 2) dorsal spondylodesis with pedicle screws combined with ALIF and autologous iliac bone graft in the intervertebral segments along the length of fusion; and 3) dorsal spondylodesis with pedicle screws combined with ALIF and titanium cage in the intervertebral segments along the length of fusion. Twenty-four cases required additional decompression because of spinal canal or foraminal stenosis. Decompression included bilateral laminotomy and foraminotomy at the levels of stenosis. As a rule, patients over 70 years and patients with serious cardiac disease underwent dorsolateral spondylodesis alone, and younger patients without serious concomitant illness underwent dorsal spondylodesis with ALIF. Figure 1 provides a comprehensive overview of operative treatment performed.

### Follow-up

The mean age at the time of surgery was 64.7±4.3 years (range 44-80 years), with a mean follow-up of 29.4±5.4 months (range 12.6-66.8 months). Because our clinic is a participant of the international "Spine Tango" spine register, the "Spine Tango" questionnaire, based on the Oswestry Disability Index (ODI) and a Visual Analogue Scale (VAS), was used for clinical assessments pre-operatively, post-operatively, and after a mean of 29.4 months. A 10 mm VAS was used to evaluate outcome regarding LBP. Unbearable pain intensity was recorded as 10, and 0 indicated no pain at all. The ODI is one of the most commonly used clinical outcome measures for individuals with low back pain. It is a valid, reliable, and responsive condition-specific assessment tool that is suitable for use in clinical practice.<sup>22</sup>

### Radiographs

Flexion-extension as well as standing X-rays of the lumbar spine in two planes were carried out for all patients. Because of the increased

**Figure 1. Overview of the performed operative treatments.****Table 2. Visual Analogue Scale (VAS) and Oswestry Disability Index (ODI) results of the patient population (n=64) pre-operatively, post-operatively (day of discharge), and after a mean of 29 months.**

	Pre-operatively	Post-operatively	After 29 months
VAS	8.6±1.3	7.5±1.7 <sup>1</sup>	5.6±3.0 <sup>1</sup>
ODI	56.1±22.3	54.7±17.3 <sup>1</sup>	45.1±26.4 <sup>1</sup>

<sup>1</sup>P>0.05

radiation exposure, routine CT scans were performed only when pseudarthrosis or implant failure was suspected. Post-operative radiographs were evaluated for quality of intervertebral osseous fusion and implant position. Seams visualized around pedicle screws were considered a sign of implant loosening. Successful fusion was defined as the presence of adequate intervertebral or dorsolateral bone mass with trabeculation at the facets and transverse processes, without movement on flexion-extension radiographs.

Adjacent disc degeneration was graded using the Weiner classification.<sup>23</sup> Radiographic ASD was defined by the development of spondylolisthesis to more than 4 mm, segmental kyphosis over 10°, complete collapse of the disc space, or by a deterioration in the Weiner classification of 2 or more grades.<sup>10</sup> In addition to radiographic analysis, the patients' medical records were analyzed to determine the nature and extent of post-operative complaints. Clinical ASD was defined as symptomatic spinal stenosis, mechanical back pain, or symptomatic sagittal or coronal imbalance.

### Statistical analysis

The radiographs were analyzed independently by one of the authors and a consultant radiologist. All results were assessed by two different people and averaged when necessary. The data were expressed as mean ± standard deviation (SD). Comparison between two groups was made with the Mann-Whitney-Wilcoxon test. Results were considered significant when the P-value was less than 0.05. All statistical analyses were performed using SPSS 15.0 (SPSS 15.0, Inc. Chicago, Illinois, USA).

## Results

Of the 64 patients included in the study, 22 were male with an average age of 61 years, and 42 were female with an average age of 65 years. For most patients, three (n=19) or four (n=15) spine segments were treated (Figure 2). The clinical outcome was not satisfactory for all patients. Only 50% were pleased with the outcome after surgery. Table 2 shows the results of the VAS and ODI scales. Neither decreased significantly post-operatively or after a mean of 29 months (P>0.05).

Evidence of radiographic ASD was noted in 24 of the 64 patients (37.5%), of whom 16 were symptomatic (66.6%). Most adjacent segment(s) degeneration occurred proximal to the performed fusion (91.7%, 22 of 24). Distally, there was one case at L4/L5 and another at L5/S1.

Altogether, there was a high rate of complications (Table 3). Thirty-five of 64 patients (54%) showed signs of pedicle screw loosening, especially of the screws at S1 (74%). However, only 7 of these 35 patients (20%) complained of corresponding back pain. Twenty-eight of 64 patients had signs of pedicle loosening without back pain. In 24 of 64 patients (38%), revision surgery was necessary (Table 4). Of these 24, there were 16 cases of ASD (67%), 7 cases of persistent back pain with implant loosening (29%), and one case of deep infection (4%). There was no significant difference in either clinical or radiographic outcome and complication rates between the dorsolateral spondylodesis group and the dorsal spondylodesis group with ALIF. Pedicle

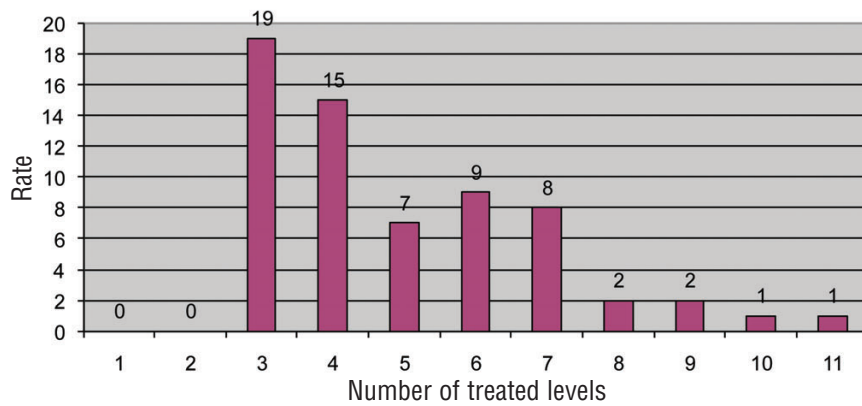


Figure 2. Number of treated levels

screw breakage occurred in 3 patients at L5 and S1, without clinical relevance. We observed 3 cases of screw displacement lateral to the vertebral body, also without clinical relevance. Good clinical outcome was not guaranteed by successful fusion showing adequate bone mass with trabeculation at the facets and transverse processes or in the intervertebral segments. There was no significant correlation between a solid osseous fusion in the performed spondylosis and VAS or ODI scores. Implant loosening and breakage occurred in cases where the fusion was deemed successful as well as in those considered unsuccessful. The type of fusion (i.e. posterior alone or 360° fusion) did not affect the occurrence of sensory/motor damage or adjacent segment disease. Patients with radiographic ASD had worse ODI scores than the patients without at follow-up of 29.4 months (54.7 vs. 36.6;  $P < 0.001$ ).

## Discussion

A major finding of our study is that the complication rates after multilevel lumbar fusion are still quite high. Thirty-eight percent of the patients had complications requiring further procedures. Sixty-seven percent of these were because of adjacent segment disease (ASD), and 29% because of persistent back pain with implant loosening (Table 4). Comparing the dorsolateral spondylosis and the 360° fusion groups, we did not identify significant differences in clinical or radiographic outcomes and complication rates. These findings correlate with those of Fritzell *et al.*,<sup>8</sup> who found no significant association between clinical outcome and complications after two years with three different lumbar fusion techniques. In the remaining literature, clinical/radiological outcomes and complication rates after multilevel fusion are recorded inconsistently. There are studies presenting statistically significant clinical improvement according to ODI and VAS with few complications.<sup>24,26</sup> However, there are

others with even higher complication rates than ours, ranging from 27-51% per technique, with re-operation rates from 10-40%.<sup>11,18,19,27</sup>

We identified radiographic signs of implant loosening in 54% of the patients (35 of 64). Only 11% (7 of 64) of these patients showed clinical signs of implant fatigue, deeming re-fusion necessary. In 43% (28 of 64) of patients, the pedicle screws showed radiographic signs but no clinical signs of loosening. Screw fatigue occurred only at the cranial or caudal margins of the fusion, with 26 of 35 cases (74%) occurring in the S1 screws. Implant loosening is caused by leverage, particularly when the instrumentation ends at the sacrum. Apart from screw fatigue, at follow-up, most patients showed successful fusion with adequate bone mass with trabeculation at the facets and transverse processes or in the intervertebral segments. In the literature, fusion rates vary between 77 and 100% for lumbar fusion.<sup>25,28-30</sup> Sixteen percent of our patients (10 of 64) exhibited sensory damage with paresthesias in the lower limb. Eleven percent of patients (7 of 64) had motor damage with foot extension ( $n=3$ ), foot flexion ( $n=2$ ), and hip flexion ( $n=2$ ) paralysis. Of these neurological complications, 6 occurred after iliac crest grafting, 4 after spinal canal decompression, 4 after correction of extreme lumbar scoliosis, and 3 developed one year after surgery because of adjacent segment spinal canal stenosis. Autologous bone graft harvesting from the iliac crest is often connected with persistent pain, meralgia paresthetica, or deep wound infection.<sup>31</sup> Despite high morbidity rates, however, autologous iliac crest graft also leads to good fusion rates in anterior lumbar interbody fusion. Our general complication rate of 13% (thrombosis, pulmonary embolism, wound infection) corresponds to that given in the literature after fusion surgery.<sup>8</sup>

Of all reported complications after monosegmental and multilevel lumbar spine fusion, the most common is ASD, followed by implant failure, or pseudarthrosis.<sup>6,9</sup> Posterior surgery has been blamed for ASD. An increased incidence

Table 3. Overview of complications after multilevel fusion.

	N	%
Implant loosening	35	54
Pedicle screw breakage	3	4
Pedicle screw displacement	3	4
ASD without pain	8	12
ASD with pain	16	25
Sensory damage	10	16
Motor damage	7	11
Iliac crest pain	5	8
Wound infection	5	8
Thrombosis	2	3
Pulmonary embolus	1	2
Defecation problems	1	2
Urination problems	1	2

Table 4. List of revision surgeries required after multilevel fusion.

Re-surgery	N	%
	24	38
Indication		
Adjacent segment disease	16	67
Back pain with implant loosening	7	29
Deep infection	1	4
Revision surgery		
Extension spondylosis	16	67
Implant change	6	25
Implant removal	2	8

of degenerative changes at the level adjacent to the fused segment has been reported by many authors. Wiltse *et al.*<sup>32</sup> and Kumar *et al.*<sup>9</sup> found an increased incidence of ASD when pedicle screws were used. Etebar and Cahill<sup>13</sup> and Schlegel *et al.*<sup>14</sup> found that instrumentation increased ASD compared to historical controls. Circumferential fusion (360°), which increases the stiffness of the fused segment, does not increase the incidence of ASD compared to dorsolateral spondylosis.<sup>10</sup> In the present study, 25% (16 of 64) of patients developed clinically significant ASD. There was radiographic evidence of adjacent segment degeneration without corresponding pain in another 16% (10 of 64) a mean 29 months after surgery. Altogether, 41% of patients (26 of 64) showed adjacent segment degeneration on radiographs. These findings correlate with the findings of Cheh *et al.*<sup>10</sup> and Penta *et al.*,<sup>4</sup> in which 42% and 32% of patients showed adjacent segment degeneration after lumbar fusion.

Although a number of studies have reported good clinical outcomes after lumbar fusion,<sup>24,26,29</sup> our clinical results were clearly unsatisfactory for patients. Only 50% were pleased with the outcome. VAS and ODI scores did not signifi-

cantly improve after a mean of 29 months. Although there was a tendency towards better VAS and ODI scores post-operatively, the standard deviation for both was too high. This poor clinical outcome could be related to the relatively high average age of 64 years and the increased risk for osteoporosis. In our study, there were two major developments requiring revision surgery. For 11% of patients, it was implant fatigue, and for 25%, it was ASD. Other studies have had similar findings. Six months after transpedicular stabilization, Ohlin *et al.*<sup>18</sup> identified a 40% risk of radiographic evidence for implant loosening or fatigue. Cheh *et al.*<sup>10</sup> found an increased risk of ASD for patients over 50 and for longer fusions. Clearly, the problem of adjacent level instability after fusion surgery has not yet been solved. New implant systems such as those that combine rigid spondylodesis with dynamic instrumentation to the adjacent segment ("topping off") are promising. However, to date no publications offer evidence of reduced ASD rates with use of these implant systems.

## Conclusions

This study underscores the need for strict indication guidelines to perform lumbar spine fusion of more than two levels. Multilevel fusion has a high risk of major complications with re-operation rates up to 40%. Back pain from implant fatigue and/or adjacent segment disease (ASD) is one major reason for poor clinical outcomes after surgery. Patients with radiographic ASD had significantly worse ODI scores than the patients without. There were no significant differences in clinical or radiographic outcomes and complication rates between the dorsolateral spondylodesis and the 360° fusion groups.

## References

- Boucher HH. A method of spinal fusion. *J Bone Joint Surg Br* 1959;41-B:248-59.
- Frymoyer JW, Hanley EN Jr, Howe J, Kuhlmann D, Matteri RE. A comparison of radiographic findings in fusion and non fusion patients ten or more years following lumbar disc surgery. *Spine* 1978;4:435-40.
- Lee CK. Accelerated degeneration of the segment adjacent to a lumbar fusion. *Spine* 1998;13:375-7.
- Penta M, Sandhu A, Fraser RB. Magnetic resonance imaging of disc degeneration ten years after anterior lumbar interbody fusion. *Spine* 1995; 20:743-7.
- Lee CK, Langrana NA. Lumbosacral spinal fusion: a biomechanical study. *Spine* 1984; 9:574-81.
- Blumenthal S, Gill K. Complications of the Wiltse pedicle screw fixation system. *Spine* 1993;18:1867-71.
- Bohnen IM, Schaafsma J, Tonino AJ. Results and complications after posterior lumbar spondylodesis with the variable screw placement spinal fixation system. *Acta Orthop Belg* 1997;63:67-73.
- Fritzell P, Hägg O, Nordwall A, Swedish Lumbar Spine Study Group. Complications in lumbar fusion surgery for chronic low back pain: comparison of three surgical techniques used in a prospective randomized study. A report from the Swedish Lumbar Spine Study Group. *Eur Spine J* 2003; 12:178-89.
- Kumar MN, Jacquot F, Hall H. Long-term follow-up of functional outcomes and radiographic changes at adjacent levels following lumbar spine fusion for degenerative disc disease. *Eur Spine J* 2001;10:309-13.
- Cheh G, Bridwell KH, Lenke LG, et al. Adjacent segment disease following lumbar/thoracolumbar fusion with pedicle screw instrumentation: a minimum 5-year follow-up. *Spine* 2007;32:2253-7.
- Esses SI, Sachs BL, Dreyzin V. Complications associated with the technique of pedicle screw fixation. A selected survey of ABS members. *Spine* 199318:2231-8.
- Aota Y, Kumano K, Hirabayashi S. Postfusion instability at the adjacent segments after rigid pedicle screw fixation for degenerative lumbar spinal disorders. *J Spinal Disord* 1995; 6:464-73.
- Etebar S, Cahill DW. Risk factors for adjacent-segment failure following lumbar fixation with rigid instrumentation for degenerative instability. *J Neurosurg* 1999; 90:163-9.
- Schlegel JD, Smith JA, Schleusener RL. Lumbar motion segment pathology adjacent to thoracolumbar, lumbar, and lumbosacral fusions. *Spine* 1996; 21:970-81.
- Davis H. Increasing rates of cervical and lumbar spine surgery in the United States 1979-1990. *Spine* 1994;19:1117-23.
- Gibson JN, Grant IC, Waddell G. The Cochrane review of surgery for lumbar disc prolapse and degenerative lumbar spondylosis. *Spine* 1999; 24:1820-32.
- Turner JA, Ersek M, Herron L, Haselkorn J, Kent D, Ciol MA, Deyo R. Patient outcome after lumbar spinal fusion. *JAMA* 1992; 268:907-11.
- Ohlin A, Karlsson M, Düppe H, Hasseriuss R, Redlund-Johnell I. Complications after transpedicular stabilization of the spine. A survivorship analysis of 163 cases. *Spine* 1994;19:2774-9.
- Okuyama K, Abe E, Suzuki T, et al. Posterior lumbar interbody fusion: a retrospective study of complications after facet joint excision and pedicle screw fixation in 148 cases. *Acta Orthop Scand* 1999; 70:329-34.
- Park P, Garton HJ, Gala VC. Adjacent segment disease after lumbar or lumbosacral fusion: review of the literature. *Spine* 2004;29:1938-44.
- Schöllner D, Szöke N. A new positioning board in the preparation for surgery. *Z Orthop Ihre Grenzgeb* 1985;123:422-3.
- Vianin M. Psychometric properties and clinical usefulness of the Oswestry Disability Index. *J Chiropr Med* 2008; 7:161-3.
- Weiner DK, Distill B, Studenski S, Martinez S, Lomasney L, Bongiorno D. Does radiographic flexibility correlate with flexibility of the lumbar spine? *J Am Geriatr Soc* 1994; 42:257-63.
- Riesner HJ, Matzen KA, Mlinaric M, Wild A. Therapeutic efficiency in multisegmental fusions of the lumbar spine. *Z Orthop Unfall* 2008;146:444-51.
- Rompe JD, Eysel P, Hopf C. Clinical efficacy of pedicle instrumentation and posterolateral fusion in the symptomatic degenerative lumbar spine. *Eur Spine J* 1995;4: 231-7.
- Zouboulis P, Karageorgos A, Dimakopoulos P, et al. Functional outcome of surgical treatment for multilevel lumbar spinal stenosis. *Acta Orthop* 2006;77:670-6.
- Greiner-Perth R, Boehm H, Allam Y, Elsaghir H, Franke J. Reoperation rate after instrumented posterior lumbar interbody fusion: a report on 1680 cases. *Spine* 2004;29:2516-20.
- Epstein NE. Fusion rates and SF-36 outcomes after multilevel laminectomy and noninstrumented lumbar fusions in a predominantly geriatric population. *J Spinal Disord Tech* 2008;21:159-64.
- Lemcke J, Klötzer S, Klötzer R, Meier U. PLIF and ALIF for the degenerative spondylolisthesis of the lumbar spine. *Z Orthop Ihre Grenzgeb* 2007;145:48-54.
- Zdeblick TA. A prospective, randomized study of lumbar fusion. Preliminary results. *Spine* 1993;18:983-91.
- Banwart JC, Asher MA, Hassanein RS. Iliac crest bone graft harvest donor site morbidity. A statistical evaluation. *Spine* 1995;20:1055-60.
- Wiltse LL, Radecki SE, Biel HM, et al. Comparative study of the incidence and severity of degenerative change in the transition zones after instrumented versus noninstrumented fusions of the lumbar spine. *J Spinal Disord* 1999;12:27-33.