



The Rates of Cement Leakage Following Vertebroplasty in Osteoporotic versus Metastatic Disease

Ahmed Saad¹ Rajesh Botchu² Steven James²

¹Department of Orthopedics, Royal Orthopaedic Hospital, Birmingham, United Kingdom

²Department of Musculoskeletal Imaging, Royal Orthopaedic Hospital, Birmingham, United Kingdom

Address for correspondence Rajesh Botchu, MBBS, MS, Department of Musculoskeletal Radiology, The Royal Orthopedic Hospital, Bristol Road South, Northfield, Birmingham, United Kingdom (e-mail: drbrajesh@yahoo.com).

Indian J Radiol Imaging 2022;32:46–50.

Abstract

Introduction Percutaneous vertebroplasty is used for symptomatic osteoporotic fractures and osteolytic neoplasms. We performed a retrospective study to analyze the pattern of leaks in the two cohorts.

Material and Methods Vertebroplasties performed over a 7-year period at a tertiary orthopaedic center were included in the study and divided into osteoporotic and neoplastic groups. The incidence and pattern of cement leaks in each group were documented and analyzed.

Results There were 75 leaks of a cohort of 211 vertebroplasties with a relatively equal proportion in osteoporotic and neoplastic groups. The incidence of discal leaks was comparable between the two groups. Lateral and posterior leaks were more common in the neoplastic group.

Conclusion We report the incidence and type of leaks in osteoporotic and neoplastic groups. Understanding the fracture pattern and preoperative management are both essential in preventing cement leakage. Using highly viscous cement or allowing the cement to harden prior to injection, with use of low pressure, decreases the risk and incidence of cement leakage.

Keywords

- ▶ vertebroplasty
- ▶ osteoporotic
- ▶ neoplastic
- ▶ leak

Introduction

Percutaneous vertebroplasty (PVP), first described in 1987,¹ is an effective procedure for the treatment of symptomatic osteoporotic vertebral fractures.^{2,3} It is known to provide adequate pain relief to 70 to 100% of patients, as well as aiding in spinal stability.^{4,5} More recently, this procedure has also been utilized in the treatment of osteolytic lesions.^{6,7} The procedure of the PVP involves injecting polymethylmethacrylate (PMMA) (bone cement) directly into the vertebra,

providing a structural reinforcement to the compressed fracture (▶ **Fig. 1**). However, this procedure is not without its drawbacks, and cement leakage accounts for most of the symptomatic complications, reported in the literature in-between 11 and 73% of cases.^{4,5,8} In light of an aging population, fractures of osteoporotic and metastatic nature are expected to increase, potentially leading to an increased burden in procedural complications⁹. The aim of this study was to determine the differences in rates of cement leakage in osteoporotic versus metastatic vertebral fractures

published online
April 19, 2022

DOI <https://doi.org/10.1055/s-0042-1744122>.
ISSN 0971-3026.

© 2022. Indian Radiological Association. All rights reserved.

This is an open access article published by Thieme under the terms of the Creative Commons Attribution-NonDerivative-NonCommercial-License, permitting copying and reproduction so long as the original work is given appropriate credit. Contents may not be used for commercial purposes, or adapted, remixed, transformed or built upon. (<https://creativecommons.org/licenses/by-nc-nd/4.0/>)

Thieme Medical and Scientific Publishers Pvt. Ltd., A-12, 2nd Floor, Sector 2, Noida-201301 UP, India

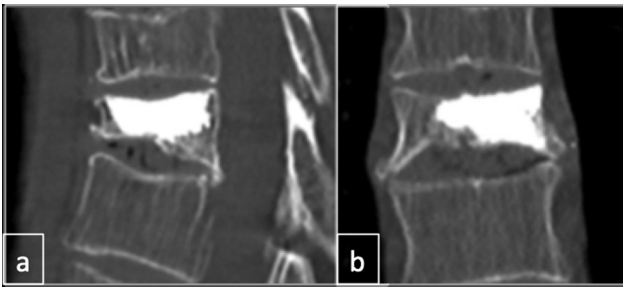


Fig. 1 Osteoporotic fracture with vertebroplasty and no cement leak.

following vertebroplasty, to identify potential risk factors in the development of this complication.

Methods

We performed a retrospective search using our electronic spinal database software, picture archiving and communication system, and pathology database, as well as our paper patient medical records (in the absence of electronic data), to identify all vertebroplasty procedures over a 5 year period. Data were collected to identify the specific indications for the procedures and rates of post-operative cement leakage (POCL). All the images were reviewed by a consultant musculoskeletal radiologist with over 15 years of experience within our department. All procedures were performed by one interventional musculoskeletal radiologist. Patients who underwent cementoplasty at other sites, e.g., sacrum and pelvis, were excluded from the study. All procedures were performed using CONFIDENCE System (DePuy Spine). This study was approved by our institutional review board.

Results

We identified 211 patients who underwent a vertebroplasty procedure. Of this cohort, there were 107 metastatic and 104 osteoporotic vertebral collapses. A total of 23.2% ($n=49$) cases developed a POCL and were included in our study (► **Table 1**). Of them, our data went on to show a female predominance, with a ratio of 1.5 to 1 males and an average age of 74 years (range 40–101).

The primary sites of metastasis included breast carcinoma ($n=11$), multiple myeloma ($n=8$), cholangiocarcinoma ($n=1$), vascular leiomyosarcoma ($n=1$), endometrial cancer ($n=1$), renal cell cancer ($n=1$), and four cases of carcinomas with an unknown primary (► **Table 2**).

Table 1 Total number of leaks, osteoporotic, versus metastatic

Groups	Total
Cancer cases total	37
Osteoporotic cases total	12
Total	49

Table 2 Metastatic vertebral fractures primaries

Cancer type	<i>n</i>
Breast cancer	10
Lung cancer	2
Cholangiocarcinoma	1
Prostate cancer	3
Thymic cancer	1
Vascular leiomyosarcoma	1
MM	8
Bladder cancer	1
Lymphoma	1
Endometrial	1
Seminoma	1
Unknown primary	4
Renal cell cancer	3
Total	37

Abbreviation: MM, multiple myeloma.

Cement Leakage Rates

Of the total 49 cases that went on to develop POCL, there was a higher predominance in the neoplastic group ($n=37$, 75.5%) in comparison to the osteoporotic cohort ($n=12$, 24.5%), and this was statistically significant (Fisher's test, p -value 0.042). As a whole, a greater number of leaks were found involving the thoracic ($n=25$) and lumbar ($n=23$) vertebrae (► **Table 3**).

Overall, the most common type of vertebral leaks identified was discal, constituting approximately 48.9% ($n=24$) of all leaks, of which 17 were found in metastatic lesions and seven in osteoporotic fractures. Inferior leaks were identified in 38.8% ($n=19$) of cases, of which the majority ($n=15$) were found in metastatic lesions. Posterior leaks were found to be the clinically most significant, likely due to the proximity of the spinal cord and respective nerve roots, and constituted 10.2% ($n=5$) of all cases, of which four were identified in metastatic lesions (► **Figs. 2 and 3**).

Less commonly identified was a lateral leak ($n=1$) included in the metastatic cohort (► **Fig. 4**) (► **Tables 4 and 5**). Only one case of leak required subsequent surgical intervention (surgical removal of cement).

Table 3 Spinal level of leak

Total level	<i>n</i>
Cervical spine	1
Thoracic	25
Lumbar	23
Total	49

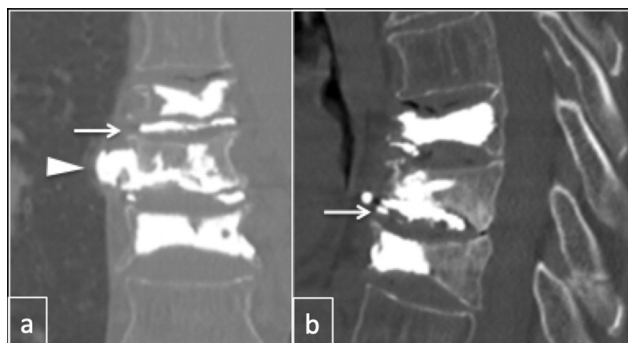


Fig. 2 Osteoporotic fractures with vertebroplasty showing discal leak (arrow) and showing lateral cement leak (arrow head).

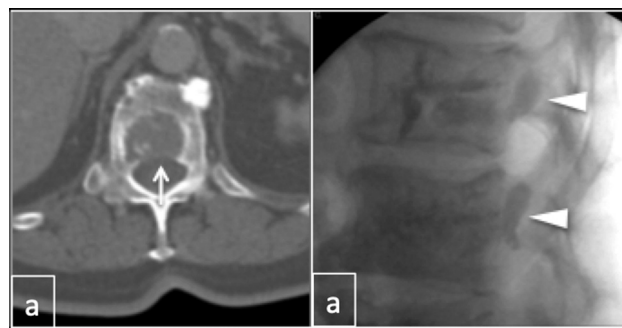


Fig. 3 Bladder carcinoma metastasis showing defect in posterior wall (arrow) and posterior cement leak (arrow head).

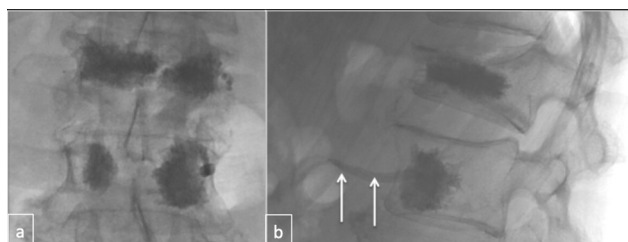


Fig. 4 Osteoporotic fractures treated with vertebroplasty and a small amount of cement in the anterior vertebral vein (arrow).

Table 4 Type of leak following PVP in metastatic fractures

Leaks cancer	n
Discal	17
Inferior	15
Lateral	1
Posterior	4
Total	37

Abbreviation: PVP, percutaneous vertebroplasty.

Table 5 Type of leak following PVP in osteoporotic fractures

Leaks osteoporotic	n
Discal	7
Lateral	4
Posterior	1
Total	12

Abbreviation: PVP, percutaneous vertebroplasty.

Discussion

Vertebral compression fractures (VCFs) are the most common fragility fractures reported in the literature, affecting approximately 1.4 million patients globally¹⁰. They occasionally present with severe physical limitations and back pain with the subsequent effect on the patients' quality of life. Moreover, when present in multiple adjacent locations, they can lead to progressive kyphosis in the thoracic spine, degrading the pulmonary function and increasing the morbidity and mortality in such patients.^{11,12}

There are many different causes of VCFs; however, osteoporosis accounts for the majority of cases due to the decreased bone density in such patients. Another important cause includes spinal metastasis, which presents in at least 75% of all bony metastasis^{13,14}. Metastatic spread is commonly observed in relation to breast, prostate, and lung cancers¹⁵ and most commonly involves the thoracic (60–80%), followed by the lumbar vertebrae (20%), correlating well with our study.

The management of patients with osteoporotic vertebral fractures varies and usually involves a multidisciplinary approach with the targeted treatment of osteoporosis with the use of pharmacological agents such as calcium, vitamin D, and vitamin D analogs, as well as analgesics to reduce pain, accompanied by bed rest and external bracing. On the contrary, the treatment of spinal metastases is more challenging, requiring local and systemic therapies, such as radiotherapy, surgical stabilization, or in more advanced cases, palliation.

In both instances, PVP has been shown to clinically improve acute and chronic pains and, additionally, is considered successful in providing spinal stabilization in VCFs. It is usually indicated in patients who have shown failure to respond to medical therapy within a 4-to-6-week course. In some neuro-oncology centers, PVP is included in treatment algorithms for the acute management of spinal metastases.^{2,16}

PVP is a minimal-invasive procedure that involves the injection of PMMA into the fracture site under continuous radiological (fluoroscopic) guidance, with the aim to fuse the fragments, thereby providing strength to the vertebrae along with instant pain relief. Most of the complications following PVP are considered rare with documented values of less than 10% in the literature,⁵ and these may include infection, bleeding, or spinal stenosis.¹⁷ Another complication of PVP, which is typically asymptomatic, is the extravasation of cement into adjacent structures (cement leakage) occurring in approximately 30 to 80% of all cases.¹⁸ When symptomatic, patients with cement leakage most commonly present with pain, due to cement compression (transient radiculopathy) or, more acutely, pain directly from the exothermic

heat related to the cement polymerization, on adjacent nerves.¹⁷ More serious fatal complications can manifest as pulmonary embolization, from the extension of cement into the nearby epidural and vertebral veins.¹ Extravasation of cement can occur from vertebral body deficiencies, fractures of specific parts to the cortex, or through the vertebral venous system, each of which may differ in clinical presentation and severity.¹⁹ Studies have shown that the rates of leakage associated with the presence of cortical fractures are higher than with intervertebral clefts (IVC), with or without fractures.^{20,21} Reasons for this are numerous and may stem from the characteristics of the vertebral venous system.^{22,23} Studies have shown that in a fractured vertebra with IVC secondary occlusion via thrombosis or embolization of the venous system may occur.^{24,25} Moreover, often there is more controlled cement filling when compared with cortical fractures, with less amount of cement required to stabilize the vertebrae in IVC, furthermore reducing the risk of venous cement leakage.²⁶ It is, therefore, important for clinicians to be aware of the defects within the vertebral cortex preoperatively, to oversee the potential risks of cement leakage.

The difference in leak rates and site of leak between metastatic and osteoporotic fractures is sparse in the literature^{27,28} and was studied in this cohort to show a higher incidence of cement leakage in metastatic disease. This is due to the presence of increased incidence of defect in the posterior wall in neoplastic cases. Moreover, our study has shown that the most common site of cement leakage is intradiscal, which correlates well with previous reports.^{20,21,29}

Within our tertiary department, high viscosity cement (HVC) is almost always used. Studies have shown that HVC is associated with significantly lesser rates of leaks in comparison to low viscosity cement, especially in metastatic vertebral collapse.³⁰ Moreover, the working time (injection time of cement) is longer with HVC and, hence, decreases the risk of leakage.^{30,31}

The approach to cement injection also plays a critical factor in reducing the rates of cement leakage. The standard technique has historically been a bipedicular approach^{32,33}; however, in most recent years, more studies have advocated the use of a unipedicular approach, reducing the operative time, radiation exposure, and risk of cement leakage.^{34,35} Moreover, the insertion of needle into the trocar at the end of the procedure might cause injection of further cement into the vertebra; hence, caution should be taken while performing this if there is evidence of leak during the procedure^{36,37}

Conclusion

Cement leakage (posterior and lateral) is more common with metastatic disease than with osteoporotic fractures. Understanding the fracture pattern and preoperative management are both essential in preventing cement leakage. Using a unipedicular approach, planning needle insertion in the anteroinferior parts of the vertebra, and utilizing highly viscous cement or allowing the cement to harden prior to

injection, with use of low pressure, decrease the risk and incidence of cement leakage.

Funding

None.

Conflict of Interest

None declared.

References

- Hulme PA, Krebs J, Ferguson SJ, Berlemann U. Vertebroplasty and kyphoplasty: a systematic review of 69 clinical studies. *Spine* 2006;31(17):1983–2001
- Deramond H, Depriester C, Galibert P, Le Gars D. Percutaneous vertebroplasty with polymethylmethacrylate. Technique, indications, and results. *Radiol Clin North Am* 1998;36(03):533–546
- Diamond TH, Champion B, Clark WA. Management of acute osteoporotic vertebral fractures: a nonrandomized trial comparing percutaneous vertebroplasty with conservative therapy. *Am J Med* 2003;114(04):257–265
- Garfin SR, Yuan HA, Reiley MA. New technologies in spine: kyphoplasty and vertebroplasty for the treatment of painful osteoporotic compression fractures. *Spine* 2001;26(14):1511–1515
- Watts NB, Harris ST, Genant HK. Treatment of painful osteoporotic vertebral fractures with percutaneous vertebroplasty or kyphoplasty. *Osteoporos Int* 2001;12(06):429–437
- Alvarez L, Pérez-Higueras A, Quiñones D, Calvo E, Rossi RE. Vertebroplasty in the treatment of vertebral tumors: postprocedural outcome and quality of life. *Eur Spine J* 2003;12(04):356–360
- Barr JD, Barr MS, Lemley TJ, McCann RM. Percutaneous vertebroplasty for pain relief and spinal stabilization. *Spine* 2000;25(08):923–928
- Shapiro S, Abel T, Purvines S. Surgical removal of epidural and intradural polymethylmethacrylate extravasation complicating percutaneous vertebroplasty for an osteoporotic lumbar compression fracture. Case report. *J Neurosurg* 2003;98(1, Suppl):90–92
- Hu Y, Hart D. Complications of vertebroplasty and kyphoplasty. *Tech Reg Anesth Pain Manage* 2007;11:164–170
- Alexandru D, So W. Evaluation and management of vertebral compression fractures. *Perm J* 2012;16(04):46–51
- Cummings SR, Melton LJ. Epidemiology and outcomes of osteoporotic fractures. *Lancet* 2002;359(9319):1761–1767
- Kado DM, Browner WS, Palermo L, Nevitt MC, Genant HK, Cummings SR. Study of Osteoporotic Fractures Research Group. Vertebral fractures and mortality in older women: a prospective study. *Arch Intern Med* 1999;159(11):1215–1220
- Tatsui H, Onomura T, Morishita S, Oketa M, Inoue T. Survival rates of patients with metastatic spinal cancer after scintigraphic detection of abnormal radioactive accumulation. *Spine* 1996;21(18):2143–2148
- Berrettoni BA, Carter JR. Mechanisms of cancer metastasis to bone. *J Bone Joint Surg Am* 1986;68(02):308–312
- Elnoamany H. Percutaneous selective vertebroplasty: state of the art management in well-confined metastatic vertebral lesions. *Asian Spine J* 2016;10(05):869–876
- Weill A, Chiras J, Simon JM, Rose M, Sola-Martinez T, Enkaoua E. Spinal metastases: indications for and results of percutaneous injection of acrylic surgical cement. *Radiology* 1996;199(01):241–247
- Jay B, Ahn SH. Vertebroplasty. *Semin Intervent Radiol* 2013;30(03):297–306

- 18 Vallejo R, Benyamin R. Vertebral augmentation techniques for the treatment of vertebral compression fractures: a review. *Reg Anesth Pain Manag* 2010;14(03):133–141
- 19 Liu T, Li Z, Su Q, Hai Y. Cement leakage in osteoporotic vertebral compression fractures with cortical defect using high-viscosity bone cement during unilateral percutaneous kyphoplasty surgery. *Medicine (Baltimore)* 2017;96(25):e7216
- 20 Lee IJ, Choi AL, Yie MY, et al. CT evaluation of local leakage of bone cement after percutaneous kyphoplasty and vertebroplasty. *Acta Radiol* 2010;51(06):649–654
- 21 Mousavi P, Roth S, Finkelstein J, Cheung G, Whyne C. Volumetric quantification of cement leakage following percutaneous vertebroplasty in metastatic and osteoporotic vertebrae. *J Neurosurg* 2003;99(1, Suppl):56–59
- 22 Tanigawa N, Kariya S, Komemushi A, et al. Cement leakage in percutaneous vertebroplasty for osteoporotic compression fractures with or without intravertebral clefts. *AJR Am J Roentgenol* 2009;193(05):W442–5
- 23 Kim YC, Kim YH, Ha KY. Pathomechanism of intravertebral clefts in osteoporotic compression fractures of the spine. *Spine J* 2014;14(04):659–666
- 24 He D, Yu W, Chen Z, Li L, Zhu K, Fan S. Pathogenesis of the intravertebral vacuum of Kümmell's disease. *Exp Ther Med* 2016;12(02):879–882
- 25 Chou LH, Knight RQ. Idiopathic avascular necrosis of a vertebral body. Case report and literature review. *Spine* 1997;22(16):1928–1932
- 26 Tomé-Bermejo F, Piñera AR, Duran-Álvarez C, et al. Identification of risk factors for the occurrence of cement leakage during percutaneous vertebroplasty for painful osteoporotic or malignant vertebral fracture. *Spine* 2014;39(11):E693–E700
- 27 Wong W, Mathis JM. Vertebroplasty and kyphoplasty: techniques for avoiding complications and pitfalls. *Neurosurg Focus* 2005;18(03):e2
- 28 Chiras J, Depriester C, Weill A, Sola-Martinez MT, Deramond H. Percutaneous vertebral surgery: techniques and indications. [in French]. *J Neuroradiol* 1997;24:45–59
- 29 Capel C, Fichten A, Nicot B, et al. Should we fear cement leakage during kyphoplasty in percutaneous traumatic spine surgery? A single experience with 76 consecutive cases. *Neurochirurgie* 2014;60(06):293–298
- 30 Rapan S, Jovanović S, Gulan G, Boschi V, Kolarević V, Dapić T. Vertebroplasty—high viscosity cement versus low viscosity cement. *Coll Antropol* 2010;34(03):1063–1067
- 31 Georgy BA. Feasibility, safety and cement leakage in vertebroplasty of osteoporotic and malignant compression fractures using ultra-viscous cement and hydraulic delivery system. *Pain Physician* 2012;15(03):223–228
- 32 Zhang ZF, Huang H, Chen S, et al. Comparison of high- and low-viscosity cement in the treatment of vertebral compression fractures: a systematic review and meta-analysis. *Medicine (Baltimore)* 2018;97(12):e0184
- 33 Georgy BA. Clinical experience with high-viscosity cements for percutaneous vertebral body augmentation: occurrence, degree, and location of cement leakage compared with kyphoplasty. *AJNR Am J Neuroradiol* 2010;31(03):504–508
- 34 Nieuwenhuijse MJ, Muijs SP, van Erkel AR, Dijkstra SP. A clinical comparative study on low versus medium viscosity polymethyl-metacrylate bone cement in percutaneous vertebroplasty: viscosity associated with cement leakage. *Spine* 2010;35(20):E1037–E1044
- 35 Gao W, Mi S, Gao J. [Percutaneous vertebroplasty to treat osteoporotic vertebral compression fractures combined with intravertebral clefts by unilateral approach]. *Zhongguo Xiu Fu Chong Jian Wai Ke Za Zhi* 2012;26(11):1330–1335
- 36 Chen YC, Zhang L, Li EN, et al. Unilateral versus bilateral percutaneous vertebroplasty for osteoporotic vertebral compression fractures in elderly patients: a meta-analysis. *Medicine (Baltimore)* 2019;98(08):e14317
- 37 Schmidt R, Cakir B, Mattes T, Wegener M, Puhl W, Richter M. Cement leakage during vertebroplasty: an underestimated problem? *Eur Spine J* 2005;14(05):466–473