

C A S E R E P O R T

A rare case of subcutaneous traumatic index finger both extensor tendons rupture. Results of WALANT extensor digiti minimi transfer and literature review

Luigi Murena, Alice Elleni, Alessandro De Luca, Gianluca Canton

Orthopaedics and Traumatology Unit, Cattinara Hospital, Department of Medical, Surgical and Life Sciences, Trieste University, Trieste (Italy)

Abstract. Traumatic subcutaneous index finger both extensor tendons ruptures are rare injuries. Aim of the present paper is to review the literature about this uncommon lesion and to describe a case occurred to a 56 years old woman after a wrist forced hyperflexion trauma. An extensor digiti minimi (EDM) tendon transfer and a Pulvertaft tenodesis on the index EDC to the middle EDC using wide awake local anesthesia no tourniquet (WALANT) technique was performed after 7 days. The advantage of the technique is to allow immediate visualization of active motion and to evaluate proper tendon tensioning. In the reported case the patient recovered full function at 2 months and resumed manual working activity at 4 months. No complications occurred. (www.actabiomedica.it)

Key words: tendon transfer, WALANT, index extensor tendon rupture

Introduction

Subcutaneous ruptures of extensor tendons of the hand are relatively common injuries. The most commonly reported causes are wrist deformities, arthritis and inflammatory arthropathy predisposing to intrinsic weakness and chronic attrition, finally leading to mechanical failure. Conversely, purely traumatic subcutaneous ruptures of the extensor tendons are rare and become even less common when simultaneous ruptures of both extensor tendons of the index finger are considered, with a few number of cases reported in the literature (1,7). The cause has been identified in hyperflexion of the wrist and index finger causing excessive tensile force on both extensor tendons (7). Aim of the present paper is to report the results of WALANT extensor digiti minimi (EDM) transfer for a case of purely traumatic subcutaneous index finger both extensor tendons rupture and to review the literature about this rare lesion.

Case report

A 56-year-old women working as a nurse in a trauma department reported sudden pain in her right hand while moving a heavy patient from bed to chair. In detail, she reported a sudden hyperflexion of the wrist which got stuck under the patient body for a few seconds. Clinical evaluation performed at the emergency department revealed the impossibility to actively lift the index finger, with full passive ROM and painful swelling at the fourth compartment extensors retinaculum. Intrinsic muscles function was maintained and no neurovascular impairment was noted. The patient underwent hand and wrist X-rays that excluded fractures, dislocations or any degenerative changes or signs of inflammatory arthritis. Thus, diagnosis of purely traumatic subcutaneous index finger extensor tendons rupture was made.

Surgery was performed 7 days after trauma. The patient was placed supine with the right hand on a ra-

diolucent table. According to WALANT technique, a solution of 40 cc of 1% lidocaine with 1:200.000 epinephrine was injected in the subcutaneous tissue at the level of the planned incisions at the fourth extensor compartment and at the metacarpophalangeal joint of the little finger. Surgical intervention was performed in two steps. First, a longitudinal 4 cm dorsal incision centered on the fourth extensor tendons compartment was performed. After retinaculum incision, the fourth compartment was explored revealing a complete musculotendinous avulsion of the index finger extensor digitorum communis (EDC) and extensor indicis proprius (EIP) tendons. Moreover, a partial lesion at the radial side of middle finger EDC was noted (Fig. 1).

A tenodesis of the index finger EDC to the middle finger EDC was performed using a Pulvertaft technique, followed by reinforcing Vycril 3/0 stitches

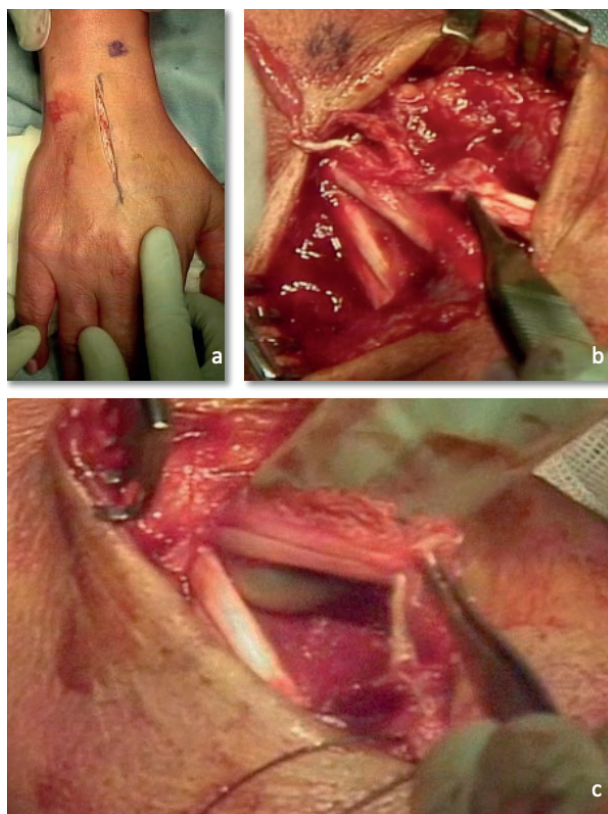


Figure 1. a) Dorsal longitudinal incision centered on the fourth extensor tendon compartment. b) Lesions of the index finger extensor digitorum communis (EDC) and extensor indicis proprius (EIP) tendons. c) The lesion at the radial side of middle finger EDC.

on the middle finger EDC partial lesion. Direct repair of the EIP tendon was not possible. Thus, a tendon transfer of the EDM was chosen. A second 2 cm skin incision was performed at the metacarpophalangeal joint of the little finger. The EDM tendon was identified, dissected and transferred proximally through the first incision. A Pulvertaft technique was used to suture the EDM tendon on the distal stump of the EIP (Fig.2). At the end of the procedure, the patient was asked to actively move the index finger in flexion and in extension to assure correct tension and mechanical stability of the repair. After irrigation with saline solution, the wounds were closed in layers and the right hand immobilized in a palmar cast with wrist extended at 60 degrees and long fingers in intrinsic plus position.

Post-operative indications included cast immobilization for 6 weeks, prolonged for more two weeks at night and during manual work. The patient was allowed to start active mobilization of the index and middle finger at two weeks while maintaining the cast. At 4 weeks, active assisted physical therapy of the fingers and wrist were allowed while temporarily removing the cast. At 6 weeks, light activities of daily living and unlimited mobilizations were allowed. At 2 months follow-up the patient presented full active and passive ROM with full extension strength recovery and no pain (Fig. 3). No complications were noted. The patient was able to resume her work as a nurse at 4 months follow-up.

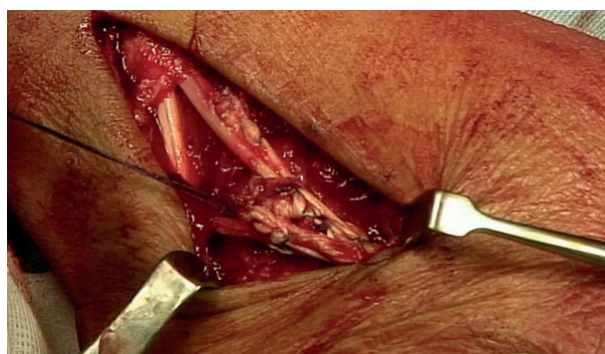


Figure 2. Tenodesis of the index finger EDC on the middle finger EDC followed by reinforcing Vycril 3/0 stitches on the middle finger EDC partial lesion. A Pulvertaft technique was used to suture the EDM tendon on the distal stump of the EIP.

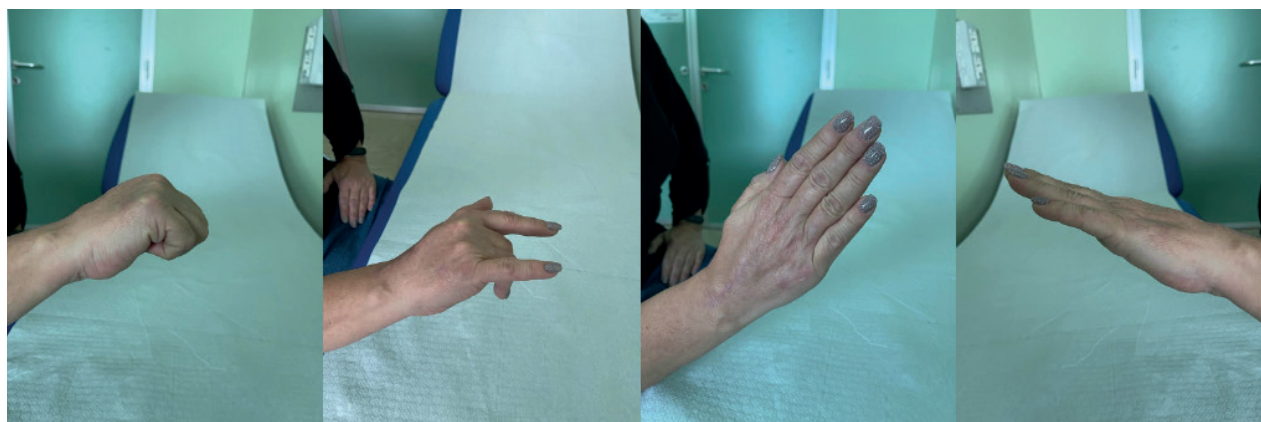


Figure 3. Clinical pictures showing full recovery of active range of motion and independent use of index and middle finger at 2 months follow-up.

Discussion

Complete traumatic subcutaneous index finger both extensor tendons rupture is a rare lesion, with few cases reported in the literature. Stuart and Briggs reported in 1993 a closed extensor tendon rupture and a distal radial fracture with the use of a gymnast wrist support (2). Takami et al. in 1995 described ten cases of closed extensor tendons rupture. The authors describe five cases due to entangling of a work glove in a rotating machine, four cases of entangling of a wrist support in parallel bars during gymnastics practice, and one case of traumatic injury while practicing judo (3). Mudgal et al. in 2007 reported the case of a male engineer whose hand became entangled in a high-speed drill (4). Sunagawa et al. in 2009 described a case occurring after a fall on the wrist in full flexion (5). Martinez-Martinez et al. in 2014 assumed as traumatic mechanism the combination of finger flexion and wrist flexion in pronation in two cases with no known risk factors, a man pulling his hand out of his pants pocket and a woman carrying a shopping bag (6). In the case described in the present paper, the mechanism of tendon rupture is similar to that identified by Takami and Martinez-Martinez, a low-energy trauma occurring to the wrist in a position of forced wrist and fingers flexion.

In a complete tendon rupture at the musculotendinous junction, direct repair is rarely possible. Side to side suturing using the Pulvertaft technique or tendon transfer remain the best possible surgical options.

Takami et al. treated five patients by side-to-side suture and three by tendon transfer (3). Mudgal et al. described a tendon transfer of the flexor carpi radialis tendon to the distal ends of the extensor indicis tendons (4). Stuart and Briggs published a case in which the EIP tendon was bruised and ruptured at the musculotendinous junction, while the EDC was found to be intact. In this case, a tenodesis of the distal stump of the ruptured tendon to the intact EDC was performed. Sunagawa et al. described a case of direct repair of the EIP and tenodesis of the EDC to the middle finger (5). Martinez-Martinez et al. described a case in which the superficial flexor tendon of the fourth finger was transferred through the interosseous membrane to be sutured with the distal end of the EIP tendon (6). Komura et al. described two cases, the first was sutured to the middle EDC while in the second case a tendon transfer of the EDM to the EIP was performed (8).

In the case described in the present paper, since both index extensor tendons were injured, two different techniques for the two tendon stumps were chosen (tenodesis of the index EDC to the middle finger EDC tendon and EDM transfer to the EIP stump). The primary goal is to obtain independent functional recovery of the ruptured tendons. In fact, it is important to emphasize that in active patients and manual workers, independent extension is the most important factor influencing subjective postoperative results (9). Moreover, young patients with an active working life deserve a repair that provides the force necessary to perform full flexion-extension movements with the

lowest risk of re-tear. The good results reported in the present case seem to confirm this statement and compare favorably to the literature, where most authors report good functional results and fully restored ROM in almost all cases, with few exceptions (13).

Finally, the choice to perform the procedure under WALANT gave the advantage of determining the optimal tension of the repair during the operation and to assess repair stability throughout active full ROM, whereas under regional or general anesthesia tension is determined solely by the surgeon based on the passive range of motion. Moreover, WALANT hand surgery has many advantages including reduced operative time due to the absence of a tourniquet and the elimination of conventional postoperative recovery, as well as a more efficient workflow in the operating room (10-12,14). The good results of the case reported in the present paper as well as of other authors experience about tendon repair or transfer performed under WALANT seem to confirm the value of the technique.

Conflict of Interest: Each author declares that he or she has no commercial associations (e.g. consultancies, stock ownership, equity interest, patent/licensing arrangement etc.) that might pose a conflict of interest in connection with the submitted article

Statement of Informed Consent: Informed consent from the patient to published the case (included images, case history and data) was obtained.

References

- de Jong JP, Nguyen JT, Sonnema AJ, Nguyen EC, Amadio PC, Moran SL. The incidence of acute traumatic tendon injuries in the hand and wrist: a 10-year population-based study. *Clin Orthop Surg* 2014; 6:196-202.
- Stuart PR, Briggs PJ. Closed extensor tendon rupture and distal radial fracture with use of a gymnast's wrist support. *Br J Sports Med* 1993; 27: 92-3.
- Takami H, Takahashi S, Ando M, et al. Traumatic rupture of the extensor tendons at the musculotendinous junction. *J Hand Surg Am* 1995; 20:474-7
- Mudgal CS, Mudgal S. Closed traumatic rupture of the extensor digitorum communis and extensor indicis proprius at the musculo- tendinous junction. *J Hand Surg Eur* 2007; 32: 675-6.
- Sunagawa T, Harada A, Ochi M. Traumatic closed index extensor tendon rupture: a case report. *J Hand Surg Eur* 2009; 34:554-5
- Martinez-Martinez F, Moreno-Fernandez JM, Rotella PS, Santonja-Medina F, Medina-Quiros M, Garcia-Lopez A. Spontaneous rupture of extensor tendons of the index finger. A report of two cases. *Hand (N Y)* 2015 ;10:570-3.
- Miyashima, Y., Uemura, T., Yokoi, T. et al. Traumatic index extensor tendon attenuation mimicking closed tendon rupture: two case reports. *BMC Musculoskelet Disord* 2020; 21, 672
- Komura S, Yokoi T, Nonomura H. Traumatic closed index extensor tendon rupture at the musculotendinous junction: a report of two cases. *Hand* 2011; 6:90-2.
- Bezuhly M, Sparkes GL, Higgins A, Neumeister MW, Lalonde DH. Immediate thumb extension following extensor indicis proprius-to-extensor pollicis longus tendon transfer using the wide-awake approach. *Plast Reconstr Surg*. 2007; 119:1507-1512.
- Kurtzman JS, Etcheson JI, Koehler SM. Wide-awake Local Anesthesia with No Tourniquet: An Updated Review. *Plast Reconstr Surg Glob Open* 2021;9:e3507.
- Lalonde, Donald H. Wide-Awake Extensor Indicis Proprius to Extensor Pollicis Longus Tendon Transfer. *The Journal of Hand Surgery* 2014; 39: 2297-2299.
- Lalonde, D.; Martin, A. Epinephrine in Local Anesthesia in Finger and Hand Surgery: The Case for Wide-awake Anesthesia. *Journal of the American Academy of Orthopaedic Surgeons* 2013; 21:443-447.
- Lalonde D, Martin A. Tumescence local anesthesia for hand surgery: improved results, cost effectiveness, and wide-awake patient satisfaction. *Arch Plast Surg* 2014; 41:312-316.
- O'Neill N, Abdall-Razak A, Norton E, et al. Use of Wide-Awake Local Anaesthetic No Tourniquet (WALANT) in upper limb and hand surgery: A systematic review protocol. *Int J Surg Protoc*. 2020; 13;20:8-12.

Received: 16 November 2021

Accepted: 22 January 2022

Correspondence:

Alice Elleni

Orthopaedics and Traumatology Unit, Cattinara Hospital, Department of Medical, Surgical and Life Sciences, Trieste University,

Strada di Fiume 447 - 34149, Trieste (Italy)

Tel. +390403994730

Fax +390403994544

Email: alice.elleni@gmail.com