

Meningomyelocele on Exposure to Clozapine During Perinatal Period

Use of antipsychotics in pregnancy is based on a risk-benefit analysis. Clozapine is generally used in treatment-resistant schizophrenia, and it is often less used in pregnancy. Safety of clozapine is not well studied in pregnant women. We report a case where a woman on clozapine along with folic acid supplementation gave birth to an infant with neural tube defect (NTD).

Clozapine readily crosses the placenta and is found in amniotic fluid and fetal blood.^[1] A few case reports and case series have reported macrocephaly, floppy infant syndrome, cardiac arrhythmias, and neonatal seizure as teratogenic effects of clozapine.^[2,3] We report a rare case where an NTD was detected in a new-born exposed to clozapine during the antenatal period.

CASE HISTORY

A 30-year-old woman, who had a weight of 60 kg and height of 160 cm (BMI 23), was on clozapine 225 mg for more than 2 years for treatment of schizophrenia. She was found to be pregnant after four months of amenorrhea while on clozapine 225 mg, haloperidol 2.5 mg, and multivitamin tablets (containing vitamin A 2500 IU, vitamin D3 200 IU, vitamin B1 2 mg, vitamin B2 2 mg, vitamin B6 0.5 mg, niacinamide 25 mg, calcium pantothenate 10 mg, vitamin C 50 mg and 0.2 mg of folic acid). She was symptomatic even on the regime.

Following the detection of pregnancy, clozapine was stopped, and she was on haloperidol 10 mg/day for 15 days. As the schizophrenia symptoms were worsening, within a month, clozapine was restarted and maintained at 150 mg/day.

On ultrasonography in the fifth month and at term, fetal ventriculomegaly was noticed. As her symptoms were manageable on clozapine 150 mg/day, it was continued until delivery. At the 36th week, she developed gestational diabetes and was treated with insulin.

At term, she delivered a male baby. During labor, the baby had shoulder dystocia and had a low Apgar score at one and nine minutes. At birth, the baby weighed 3.49 kg, the height was 46 cm, and the head circumference was 34.5 cm. The baby had a lumbar swelling and was diagnosed to have lumbar meningomyelocele, an open NTD [Figure 1]. The baby was admitted in the intensive care unit for further care.

DISCUSSION

This case is one where an NTD is detected on in-utero exposure to clozapine. NTD on exposure to olanzapine, another atypical antipsychotic, has been reported.^[4]

In our case, the mother was on 225 mg/d of clozapine and 2.5 mg/d of haloperidol throughout her first trimester, a critical period of organogenesis. Neural tube formation occurs between the third and fourth weeks of embryogenesis.^[5] Failure of closure within this period results in NTD. In a study of 11 cases who were on clozapine, two babies had congenital anomalies: one had craniosynostosis and gastroschisis, and the other baby had horseshoe kidney.^[6] Macrocephaly has been reported with clozapine and olanzapine.^[2]

According to the National Birth Defect Prevention Study, risk factors for NTDs include family history of NTD, obesity, pregestational diabetes, low folate, and anticonvulsant use: Together, these factors account for less than 50% of NTD.^[7] Folic acid has been observed to be critical in neural tube development. Our patient, the mother, was on multivitamin supplementation containing 0.2 mg of folic acid, for about two years until her pregnancy was detected. Hence, a deficiency of folate is less likely. There are studies which have shown that vitamin supplementation during the periconceptional period reduces the risk of NTD (OR ≥ 1.7), while folic acid supplementation was slightly more protective against spina bifida.^[8]

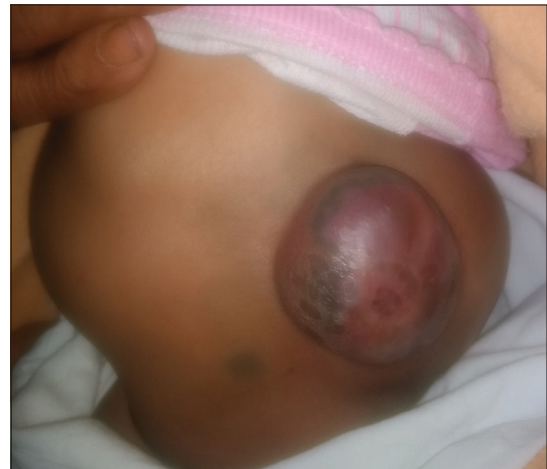

Figure 1: Swelling over the lumbosacral region

Overweight is a risk factor for NTD. It is known that atypical antipsychotics cause weight gain, and low serum folate levels, along with overweight, may put infants of women with clozapine at high risk for NTD.^[9] Amount of overall weight gain during pregnancy and serum folate levels are not available for this patient. Maternal diabetes is also a risk factor for NTD. This case had no diabetes before conception and was diagnosed to have gestational diabetes at the third trimester.

Clozapine is less studied in pregnancy or animal studies. NTD may be an effect of clozapine interfering in organogenesis. Clinicians must be vigilant about such cases. Further prospective studies are warranted to determine the safety of clozapine in pregnancy. Clozapine should be used only in difficult cases and in such situations, monitoring should be ensured.

Financial support and sponsorship

Nil.

Conflicts of interest

There are no conflicts of interest.

**Prakruthi Narayanaswamy, K. S. Shaji¹,
T. P. Sumesh¹**


Department of Psychiatry, Sri Devaraj Urs Medical College,
Tamaka, Kolar, Karnataka, ¹Department of Psychiatry,
Government Medical College, Thrissur, Kerala India

Address for correspondence: Dr. Prakruthi Narayanaswamy
Department of Psychiatry, Sri Devaraj Urs Medical College, Tamaka,
Kolar, Karnataka, India.
E-mail: drprakruthi.psy@gmail.com

REFERENCES

1. Barnas C, Bergant A, Hummer M, Saria A, Fleischhacker WW. Clozapine concentrations in maternal and fetal plasma, amniotic fluid, and breast milk. *Am J Psychiatry* 1994;151:945.
2. Boden R, Lundgren M, Brandt L, Reutfors J, Kieler H. Antipsychotics during pregnancy: Relation to fetal and maternal metabolic effects. *Arch Gen Psychiat* 2012;69:715-21.
3. Karakula H, Szajer K, Rpila B, Grzywa A, Chuchra M. Clozapine and pregnancy-a case history. *Pharmacopsychiatry* 2004;37:303-4.
4. Arora M, Praharaj SK. Meningocele and ankyloblepharon following in utero exposure to olanzapine. *Eur Psychiatry* 2006;21:345-6.
5. Wilde JJ, Petersen JR, Niswander L. Genetic, epigenetic, and environmental contributions to neural tube closure. *Annu Rev Genet* 2014;48:583-611.
6. Kulkarni J, Worsley J, Gilbert H, Gavrilidis E. A prospective cohort study of antipsychotic medications in pregnancy: The first 147 pregnancies and 100 one year old babies. *PLoS One* 2014;9:e94788.
7. Agopian AJ, Tinker SC, Lupo PJ, Canfield MA, Mitchell LE. Proportion of neural tube defects attributable to known risk factors. *Birth Defects Res A Clin Mol Teratol* 2013;97:42-6.
8. Carmichael SL, Yang W, Shaw GM. Periconceptional nutrient intakes and risks of neural tube defects in California. *Birth Defects Res A Clin Mol Teratol* 2010;88:670-8.
9. Koren G, Cohn T, Chitayat D, Kapur B, Remington G, Reid DM, et al. Use of atypical antipsychotics during pregnancy and the risk of neural tube defects in infants. *Am J Psychiatry* 2002;159:136-7.

This is an open access journal, and articles are distributed under the terms of the Creative Commons Attribution-NonCommercial-ShareAlike 4.0 License, which allows others to remix, tweak, and build upon the work non-commercially, as long as appropriate credit is given and the new creations are licensed under the identical terms.

Access this article online	
Website: www.ijpm.info	Quick Response Code 
DOI: 10.4103/IJPSYM.IJPSYM_298_18	

How to cite this article: Narayanaswamy P, Shaji KS, Sumesh TP. Meningomyelocele on exposure to clozapine during perinatal period. *Indian J Psychol Med* 2019;41:398-9.

© 2019 Indian Psychiatric Society - South Zonal Branch | Published by Wolters Kluwer - Medknow