

REVIEW ARTICLE

Remarkable efficiency of surgical shave excision of keloids followed by intralesional injection of Bleomycin. A retrospective study of 314 cases

Olivier Vanhooetghem Dermatology Department, CHU UCL Site
Sainte Elisabeth, Namur, Belgium**Correspondence**Olivier Vanhooetghem, Dermatology
Department, CHU UCL Site Sainte Elisabeth,
Namur, Belgium.Email: ovanhooetghem@hotmail.com**Abstract**

The aim of this study was to determine the efficiency of a keloid treatment consisting of intradermal surgical shave excision followed by intralesional injections of Bleomycin. A retrospective study performed in the Department of Dermatology, CHU UCL Namur Sainte Elisabeth Clinic, Belgium between 2018 and 2019, on 314 patients with keloids—average age: 32 years (range 19–62). Patients were treated first by surgical shave excision and then after reepithelialization, monthly Bleomycin injections were used until the itching and/or pain ceased and the keloid disappeared. The satisfaction index based on Vancouver Scar Scale on the 314 patients was as follows: 87% of the patients were very satisfied with complete flattening (276 patients), 11% were moderated satisfied with significant flattening (32 patients), and 2% show recurrences (6 patients). Pain and itching disappear totally (100% of patients) based on Visual Analogue Scale. The absence of recurrence within 24 months of the last injection, leads us to believe that this can be a first choice and low-cost treatment, whatever the phototype and the size of the lesion. This treatment can be given in all regions of the world, including in non-industrialized or developing countries.

KEYWORDS

Bleomycin, intralesional, keloid, scar, shave surgery

1 | INTRODUCTION

Every surgical procedure leads to the problem of skin healing, which is unpredictable and requires informing the patient objectively on the impossibility of being able to guarantee a perfect final result. A keloid is defined as an intra-dermis proliferative tumor, arising from an inadequate response of connective tissue after a trauma, in patients with a predisposition.¹ Clinically, a keloid is a hard-intra-dermis mass where the epidermis is thinned, smooth, and straight. Keloids can become

pruriginous and/or hypersensitive. They generally appear 3–6 months after the trauma, often spread with a crab leg-like shape and then extend beyond the site of the initial lesion without involution over time. Normal healing occurs in three overlapping steps, but in keloids, the 2nd phase, called “proliferative”, lasts longer, and fibroblasts proliferate around neo-vessels to form a dense mass of collagen.² This hyperactivity lasts several months and is explained by a reduction in the activity of collagenases involving a defect in resorption and an excess in collagen production. These two phenomena are not

This is an open access article under the terms of the [Creative Commons Attribution-NonCommercial-NoDerivs](https://creativecommons.org/licenses/by-nc-nd/4.0/) License, which permits use and distribution in any medium, provided the original work is properly cited, the use is non-commercial and no modifications or adaptations are made.

© 2022 The Author. *Dermatologic Therapy* published by Wiley Periodicals LLC.

independent from one another. Collagen type I and III are synthesized approximately 20 times higher in keloids than in normal skin.³ The appearance of keloids, along with itching and pain, and their tendency to recurrence have pushed practitioners to suggest various surgical and conservative techniques.⁴

Here, we introduce our procedure, which proves efficient and satisfactory while preventing recurrence.

2 | METHODS

This is a retrospective monocentric study made between 2018 and 2019, of 314 patients with keloids (average age: 32 years; range age: 19–62) (85.3% of cases submitted by surgeons) who have been presenting for minimum 5 years, therefore excluding hypertrophic scars, with single or multiple and diversely located lesions (face-including neck-28%, members 11%, chest 31%, and back 30%). 61% of the patients included in this study presented with phototype VI according to Fitzpatrick scale, and 39% presented with other phototypes. Exclusion criteria are as follows: hypertrophic scars, keloids under 5 years old, being under 18 years of age, pregnant or breastfeeding, and any patient having benefited from a previous treatment.

The first step of the treatment takes place under local anesthesia by injection of lidocaine with adrenalina 2%. Every lesion is treated by intralesional excision into the reticular dermis by “shave” (Figures 1–4). Local aluminum chloride at 33% is applied to control bleeding. Electrocoagulation is avoided. Patients are re-examined 1 month later. Creams or unguents are avoided so spontaneous wound healing is favored. A bandage protects the wound from potential trauma. Reepithelialization is observed in about 4 weeks.

The second step of the treatment consists of intralesional injections of diluted Bleomycin (15 U of Bleomycin are mixed with 20 cc of physiological serum used for dilution, and 20 cc of lidocaine with adrenalina 2%). The final solution is stored in the fridge. A total of 1–2 ml (depending of the size of the lesion) of the Bleomycin solution is

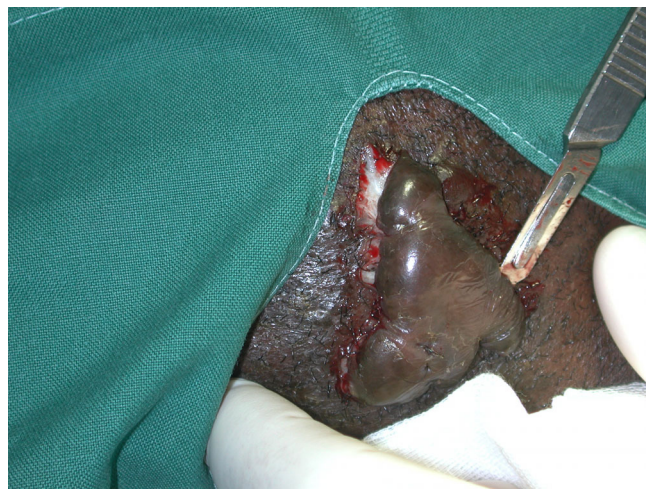

FIGURE 2 Shave surgery

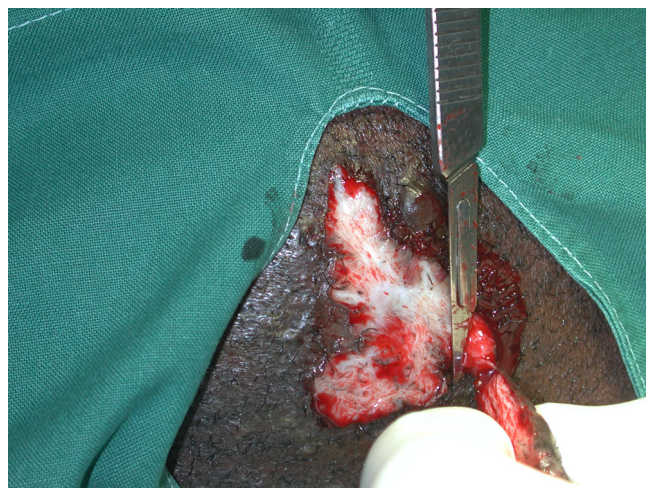


FIGURE 3 End of shave surgery

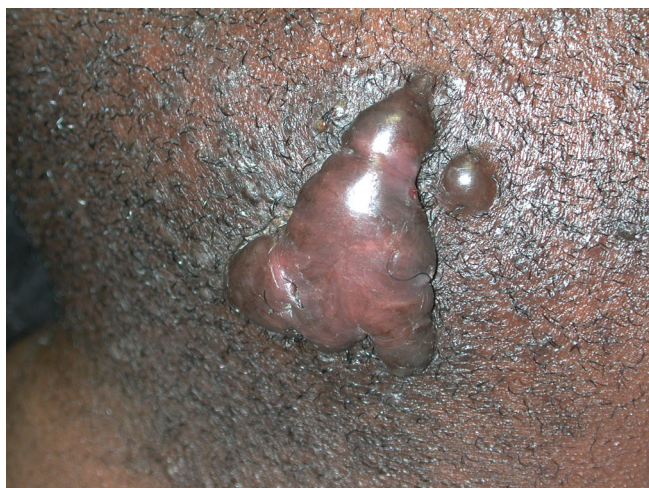

FIGURE 1 Keloid before shave surgery

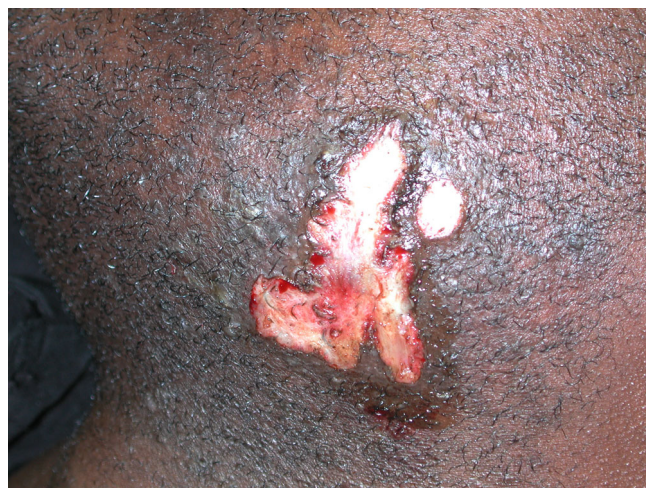

FIGURE 4 Scar at the end of shave surgery

injected into the reticular dermis of the keloid using a 30-G needle fixed to a tuberculin syringe in one sitting. Consecutive injections are made within a month of each other according to evaluation of the keloid and the degree of itching. Patients were followed up for 24 months after the last injection (Figures 5-8).

3 | RESULTS

On 314 patients who had a reticular intradermal surgical shave excision treatment, 7% had one intralesional injection of Bleomycin after surgery (23 patients), 21% had two injections (67 patients), 64% had three injections (199 patients), 6% had four injections (19 patients), and 2% had five injections (6 patients). The satisfaction index based on Vancouver Scar Scale⁵ for the 314 patients was as followed after 2 years follow-up: 87% of the patients were very satisfied with

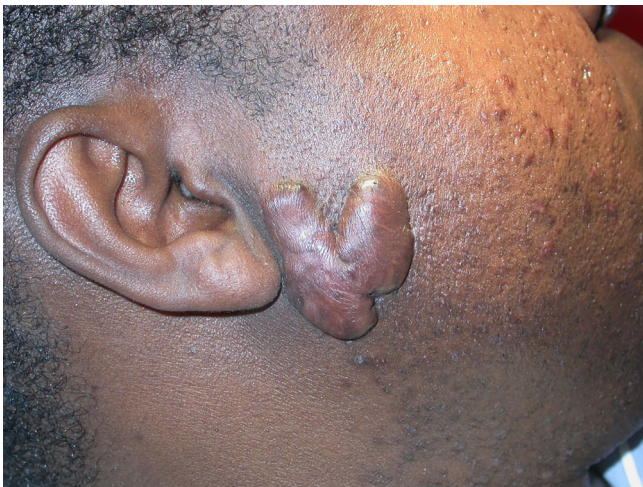

FIGURE 5 Keloid before treatment

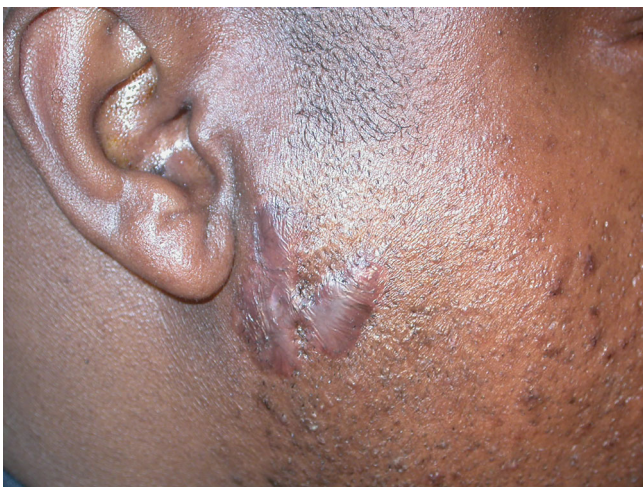

FIGURE 6 Scar 20 months later and three injections of Bleomycin

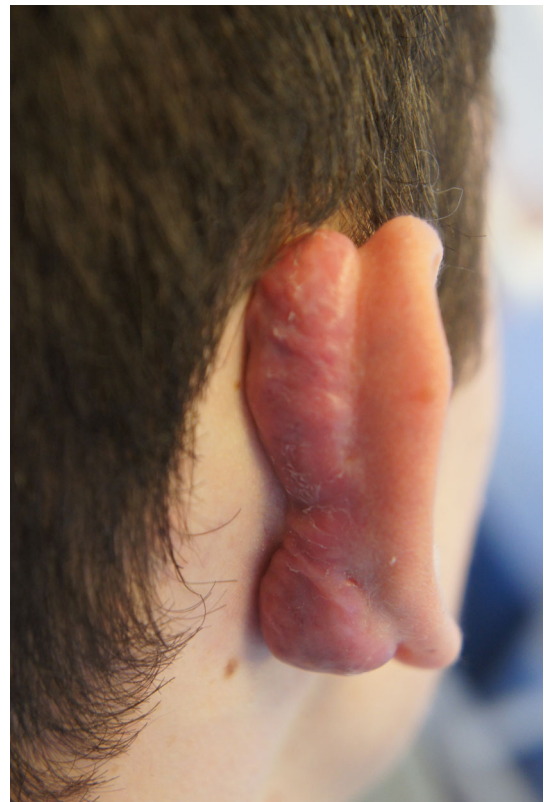

FIGURE 7 Keloid before treatment

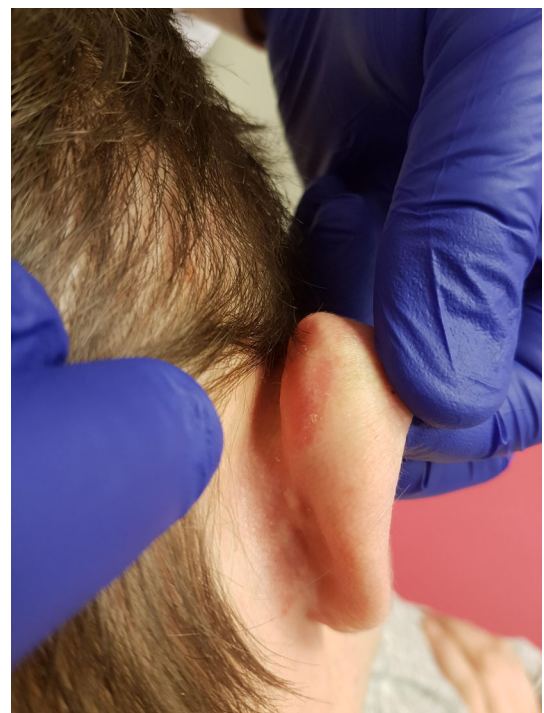

FIGURE 8 Scar 18 months later and two injections of Bleomycin

complete flattening (276 patients), 11% were moderated satisfied with significant flattening (32 patients), and 2% show recurrences (6 patients). These six patients with recurrences were given a second shave excision surgery, after which three patients are satisfied by the result after two injections with moderated flattening; one patient shows a second recurrence, but the tumor size is reduced to 2/3, and the patient remains fairly satisfied with minimal flattening without any injections. The last two patients were lost to follow-up. Pain and itching disappear totally (100% of patients) based on Visual Analogue Scale (VAS).⁶

4 | DISCUSSION

The excisional shave, which precedes the injection of Bleomycin, is performed at the base of the keloid into the papillary dermis, an approach that reduces the risk of recurrence. We have not chosen the simple and full excision of keloids as this technique has a recurrence rate of 40%–100% with resulting lesions being larger than the original ones.⁷ “Shave” provides a weaker stimulation of collagen production than occurs with deeper excision, and the thickness of the originating lesion is reduced, which improves the efficiency of later injections. Second line healing is very quick, but oily creams should not be used to avoid excessive cicatrization. Keloids appear due to a healing defect presenting anomalous fibroblasts, which produce an excess of disorganized collagen types I and III. The hyperactivity of these fibroblasts could be associated with hyper expression of the growth factor beta-1 (TGF- β 1).³ Bleomycin is a cytostatic molecule that acts to inhibit DNA or RNA synthesis and provoke the production of oxygen. Bleomycin inhibits lysyl oxidase, an enzyme involved in the expression of TGF- β 1 and the collagen maturation, hence reducing the quantity of collagen in the keloid tumor and the activity of fibroblasts radicals.⁸ The resulting necrosis depends on two factors: the dose of Bleomycin and the depth of the injections. The scientific literature describes a large number of different intralesional injection treatment that yield variable results.⁹ The efficacy of “shave” followed by intralesional injections of Bleomycin is not known. Studies have shown that in mono therapies, intralesional injections or multiple needle punctures of Bleomycin have an efficiency.^{10–13} Bodokh and Brun¹⁴ observe a reduction in pain and itching in 84% of keloids in 31 patients treated with intralesional injections of Bleomycin. In our study pain and itching disappear totally (100% of patients) based on VAS.⁶ Our experience shows a low rate of recurrence estimated at 2%. Most patients benefit from three injections (64%) and two injections (21%) within a 1-month period between injections. 87% of patients are very satisfied with complete flattening and have no recurrence within an average of 24 months after the last injection; 11% of patients are moderated satisfied with the aesthetic result but with moderated flattening, and 2% of patients suffer from a recurrence (six patients with regrowing scar identical to the previously surgical shave excision). Of these, after a second surgical treatment and two injections three patients were satisfied, only one patient suffers from a lower recurrence, but the lesion was clinically reduced to 2/3 of the initial lesion size. The patient did not opt for further treatment because minimal flattening.

Secondary effects with this technique are rare. Cases of dermal atrophy after treating with Bleomycin or hyperpigmentation in site of injection are described.^{11,15} The injection of the chemical into the medium dermis avoids atrophy.¹⁵ Because of the use of lower doses of Bleomycin, we did not have any systemic toxic effect and we have not observed any secondary cutaneous effects.

5 | CONCLUSION

Although our study requires a larger test group, the results are promising. The shave technique associated with intralesional injections of Bleomycin meets patients' expectations. It is simple, efficient, and quick and lacks secondary effects, except for the pain connected with the injection and a residual hyperpigmentation, which is transitory and dependent upon the phototype. The absence of recurrence within 24 months of the last injection, without any compression bandage or healing cream, leads us to believe that this can be a first choice and low-cost treatment, whatever the phototype and the size of the lesion. This treatment can be given in all regions of the world, including in non-industrialized or developing countries.

CONFLICT OF INTERESTS

The author has no conflicts of interest, including specific financial interests and relationships and affiliations relevant to the subject of this manuscript.

AUTHOR CONTRIBUTIONS

The content of the paper “Remarkable efficiency of surgical shave excision of keloids followed by intralesional injection of Bleomycin. A retrospective study of 314 cases.” Vanhooteghem O, MD, has not been published or submitted for publication elsewhere. Author have read and approved the manuscript in keeping with the latest guidelines of the International Committee of Medical Journal Editors.

INFORMED CONSENT

Patients gave written informed consent to publish the case including clinical image (available on request).

DATA AVAILABILITY STATEMENT

The data that support the findings of this study are available from the corresponding author upon reasonable request.

ORCID

Olivier Vanhooteghem  <https://orcid.org/0000-0001-7191-2566>

REFERENCES

1. Halim AS, Emami A, Salahshourifar I, Kannan TP. Keloid scarring: understanding the genetic basis, advances, and prospects. *Arch Plast Surg*. 2012;39:184-189.
2. Gauglitz GG, Korting HC, Pavicic T, Ruzicka T, Jeschke MG. Hypertrophic scarring and keloids: pathomechanisms and current and emerging treatment strategies. *Mol Med*. 2011;17:113-125.
3. Arno AI, Gauglitz GG, Barret JP, Jeschke MG. New molecular medicine-based scar management strategies. *Burns*. 2014;40:539-551.

4. Arno AI, Gauglitz GG, Barret JP, Jeschke MG. Up-to-date approach to manage keloids and hypertrophic scars: a useful guide. *Burns*. 2014; 40:1255-1266.
5. Baryza MJ, Baryza GA. The Vancouver scar scale: an administration tool and its interrater reliability. *J Burn Care Rehabil*. 1995;16: 535-538.
6. Reich A, Heisig M, Phan NQ, et al. Visual analogue scale: evaluation of the instrument for the assessment of pruritus. *Acta Derm Venereol*. 2012;92:497-501.
7. Lee KK, Mehrany K, Swanson NA. Surgical revision. *Dermatol Clin*. 2005;23:141-150, vii.
8. Crooke ST, Bradner WT. Bleomycin, a review. *J Med*. 1976;7: 333-428.
9. Perdanasari AT, Torresetti M, Grassetti L, et al. Intralesional injection treatment of hypertrophic scars and keloids: a systematic review regarding outcomes. *Burns Trauma*. 2015;3:14.
10. España A, Solano T, Quintanilla E. Bleomycin in the treatment of keloids and hypertrophic scars by multiple needle punctures. *Dermatol Surg*. 2001;27:23-27.
11. Saray Y, Güleç AT. Treatment of keloids and hypertrophic scars with dermojet injections of bleomycin: a preliminary study. *Int J Dermatol*. 2005;44:777-784.
12. Aggarwal H, Saxena A, Lubana PS, Mathur RK, Jain DK. Treatment of keloids and hypertrophic scars using bleom. *J Cosmet Dermatol*. 2008; 7:43-49.
13. Huu ND, Huu SN, Thi XL, et al. Successful treatment of intralesional bleomycin in keloids of Vietnamese population. *Open Access Maced J Med Sci*. 2019;7:298-299.
14. Bodokh I, Brun P. Treatment of keloid with intralesional bleomycin. *Ann Dermatol Venereol*. 1996;123:791-794.
15. Payapvipapong K, Niumpradit N, Piriyanand C, Buranaphalin S, Nakakes A. The treatment of keloids and hypertrophic scars with intralesional bleomycin in skin of color. *J Cosmet Dermatol*. 2015;14: 83-90.

How to cite this article: Vanhooetghem O. Remarkable efficiency of surgical shave excision of keloids followed by intralesional injection of Bleomycin. A retrospective study of 314 cases. *Dermatologic Therapy*. 2022;35(5):e15425. doi:[10.1111/dth.15425](https://doi.org/10.1111/dth.15425)